Comparative Effectiveness Review
Number 195

Management of Uterine Fibroids

Comparative Effectiveness Review
Number 195

Management of Uterine Fibroids

Prepared for:
Agency for Healthcare Research and Quality
U.S. Department of Health and Human Services
5600 Fishers Lane
Rockville, MD 20857
www.ahrq.gov

Contract No. 290-2015-00003-I

Prepared by:
Vanderbilt Evidence-based Practice Center
Nashville, TN

Investigators:
Katherine E. Hartmann, M.D., Ph.D.
Christopher Fonnesbeck, Ph.D.
Tanya Surawicz, M.P.H.
Shanthi Krishnaswami, M.B.B.S., M.P.H.
Jeffrey C. Andrews, M.D.
Jo Ellen Wilson, M.D., M.P.H.
Digna Velez-Edwards, Ph.D., M.S.
Shannon Kugley, M.L.I.S.
Nila A. Sathe, M.A., M.L.I.S.

AHRQ Publication No. 17(18)-EHC028-EF
December 2017

Key Messages

Purpose of Review
To review treatment effectiveness and the risk of leiomyosarcoma (LMS) in women with fibroids.

Key Messages

- Gonadotropin-releasing hormone (GnRH) agonists, mifepristone, ulipristal, and uterine artery embolism (UAE) reduce fibroid size, and improve symptoms and quality of life. High intensity focused ultrasound reduces fibroid size, but impact on quality of life was not measured. Myomectomy and hysterectomy also improve quality of life. Direct comparisons of interventions provide little evidence.
- For women in their 30s, the chance of needing retreatment for fibroids within the next 2 years was 6–7 percent after medical treatment or myomectomy and 44 percent after UAE. For older women, the chance was 9–19 percent after medical treatment or UAE and 0 percent after myomectomy.
- Using data from160 studies, risk of unexpected LMS ranged from less than 1 to 13 of 10,000 surgeries.
- Survival time appears shorter with power morcellation; however, confidence intervals are wide and overlap with other surgical approaches.

This report is based on research conducted by the Vanderbilt Evidence-based Practice Center (EPC) under contract to the Agency for Healthcare Research and Quality (AHRQ), Rockville, MD (Contract No. 290-2015-00003-I). The findings and conclusions in this document are those of the authors, who are responsible for its contents; the findings and conclusions do not necessarily represent the views of AHRQ. Therefore, no statement in this report should be construed as an official position of AHRQ or of the U.S. Department of Health and Human Services.

None of the investigators have any affiliations or financial involvement that conflicts with the material presented in this report.

The information in this report is intended to help health care decisionmakers—patients and clinicians, health system leaders, and policymakers, among others—make well-informed decisions and thereby improve the quality of health care services. This report is not intended to be a substitute for the application of clinical judgment. Anyone who makes decisions concerning the provision of clinical care should consider this report in the same way as any medical reference and in conjunction with all other pertinent information, i.e., in the context of available resources and circumstances presented by individual patients.

This report is made available to the public under the terms of a licensing agreement between the author and the Agency for Healthcare Research and Quality. This report may be used and reprinted without permission except those copyrighted materials that are clearly noted in the report. Further reproduction of those copyrighted materials is prohibited without the express permission of copyright holders.

AHRQ or U.S. Department of Health and Human Services endorsement of any derivative products that may be developed from this report, such as clinical practice guidelines, other quality enhancement tools, or reimbursement or coverage policies, may not be stated or implied.

This report may periodically be assessed for the currency of conclusions. If an assessment is done, the resulting surveillance report describing the methodology and findings will be found on the Effective Health Care Program Web site at www.effectivehealthcare.ahrq.gov. Search on the title of the report.

Persons using assistive technology may not be able to fully access information in this report. For assistance, contact epc@ahrq.hhs.gov.

Suggested citation: Hartmann KE, Fonnesbeck C, Surawicz T, Krishnaswami S, Andrews JC, Wilson JE, Velez-Edwards D, Kugley S, Sathe NA. Management of Uterine Fibroids. Comparative Effectiveness Review No. 195. (Prepared by the Vanderbilt Evidence-based Practice Center under Contract No. 290-2015-00003-I.) AHRQ Publication No. 17(18)-EHC028-EF. Rockville, MD: Agency for Healthcare Research and Quality; December 2017. www.effectivehealthcare.ahrq.gov/reports/final.cfm. doi: https://doi.org/10.23970/AHRQEPCCER195.

Preface

The Agency for Healthcare Research and Quality (AHRQ), through its Evidence-based Practice Centers (EPCs), sponsors the development of systematic reviews to assist public- and private-sector organizations in their efforts to improve the quality of health care in the United States. These reviews provide comprehensive, science-based information on common, costly medical conditions, and new health care technologies and strategies.

Systematic reviews are the building blocks underlying evidence-based practice; they focus attention on the strength and limits of evidence from research studies about the effectiveness and safety of a clinical intervention. In the context of developing recommendations for practice, systematic reviews can help clarify whether assertions about the value of the intervention are based on strong evidence from clinical studies. For more information about AHRQ EPC systematic reviews, see www.effectivehealthcare.ahrq.gov/reference/purpose.cfm.

AHRQ expects that these systematic reviews will be helpful to health plans, providers, purchasers, government programs, and the health care system as a whole. Transparency and stakeholder input are essential to the Effective Health Care Program. Please visit the Web site (www.effectivehealthcare.ahrq.gov) to see draft research questions and reports or to join an email list to learn about new program products and opportunities for input.

If you have comments on this systematic review, they may be sent by mail to the Task Order Officer named below at: Agency for Healthcare Research and Quality, 5600 Fishers Lane, Rockville, MD 20857, or by email to epc@ahrq.hhs.gov.

Gopal Khanna, M.B.A.
Director
Agency for Healthcare Research and Quality

Arlene S. Bierman, M.D., M.S.
Director
Center for Evidence and Practice Improvement
Agency for Healthcare Research and Quality

Stephanie Chang, M.D., M.P.H.
Director
Evidence-based Practice Center Program
Center for Evidence and Practice Improvement
Agency for Healthcare Research and Quality

Elise Berliner, Ph.D.
Task Order Officer
Center for Evidence and Practice Improvement
Agency for Healthcare Research and Quality

Acknowledgments

The authors gratefully acknowledge the following individuals for their contributions to this project: Ms. Sanura Latham and Ms. Jessica Kimber were invaluable resources for assisting with data extraction and validation, helping to locate studies, and tracking and distributing project materials. Dr. Mamata Raj assisted with screening studies. Dr. Jill Huppert and Dr. Christine Chang (AHRQ) assisted with subject matter perspective and readability. We sincerely appreciate their dedicated work, as well as the input of our Task Order Officer; Associate Editor, Timothy Carey, M.D., M.P.H.; and Key Informants and Technical Experts.

Key Informants

In designing the study questions, the EPC consulted several Key Informants who represent the end-users of research. The EPC sought the Key Informant input on the priority areas for research and synthesis. Key Informants are not involved in the analysis of the evidence or the writing of the report. Therefore, in the end, study questions, design, methodological approaches, and/or conclusions do not necessarily represent the views of individual Key Informants.

Key Informants must disclose any financial conflicts of interest greater than $10,000 and any other relevant business or professional conflicts of interest. Because of their role as end-users, individuals with potential conflicts may be retained. The Task Order Officer and the EPC work to balance, manage, or mitigate any conflicts of interest.

The list of Key Informants who provided input to this report follows:

Carla Dionne, M.P.H., M.B.A.
National Uterine Fibroids Foundation
Colorado Springs, CO

James Gardner, M.D., M.B.A.
Cook Incorporated
Bloomington, IN

Tina Groat, M.D., M.B.A., FACOG
United Healthcare
Plano, TX

Phyllis Leppert, M.D., Ph.D.
Duke University Medical Center
Durham, NC

Mary Ann Lumsden, M.D., FRCOG*
University of Glasgow
Glasgow, Scotland, UK
Wanda K. Nicholson, M.D., M.P.H., M.B.A.
University of North Carolina
Chapel Hill, NC

Allison O'Neill, Ph.D., M.A.
Food and Drug Administration
Silver Spring, MD

Christopher Ronk, Sc.D.
Food and Drug Administration
Silver Spring, MD

Ann Shortliffe, R.N.
University of North Carolina
Chapel Hill, NC

Elizabeth Stewart, M.D.
Mayo Clinic
Rochester, MN

*Provided input on Draft Report

Technical Expert Panel

In designing the study questions and methodology at the outset of this report, the EPC consulted several technical and content experts. Broad expertise and perspectives were sought. Divergent and conflicting opinions are common and perceived as healthy scientific discourse that results in a thoughtful, relevant systematic review. Therefore, in the end, study questions, design, methodologic approaches, and/or conclusions do not necessarily represent the views of individual technical and content experts.

Technical Experts must disclose any financial conflicts of interest greater than $10,000 and any other relevant business or professional conflicts of interest. Because of their unique clinical or content expertise, individuals with potential conflicts may be retained. The TOO and the EPC work to balance, manage, or mitigate any potential conflicts of interest identified.

The list of Technical Experts who provided input to this report follows:

William Catherino, M.D., Ph.D.
Uniformed Services University of the Health Sciences
Bethesda, MD

Tommasco Falcone, M.D.
Cleveland Clinic
Cleveland, OH

Kimberly Kho, M.D., M.P.H.*
University of Texas Southwestern Medical Center
Dallas, TX
*Provided input on Draft Report

Mary Ann Lumsden, M.D., FRCOG*
University of Glasgow
Glasgow, Scotland, UK

Evan Myers, M.D., M.P.H.
Duke University Medical Center
Durham, NC

James Segars, M.D.
Johns Hopkins University School of Medicine
Baltimore, MD

Ann Shortliffe, R.N.
University of North Carolina
Chapel Hill, NC

James Spies, M.D., M.P.H.*
Georgetown University
Washington, DC

Ganesa Wegienka, Ph.D.*
Henry Ford Health System
Detroit, MI

Lauren Wise, Sc.D.*
Boston University School of Public Health
Boston, MA

*Provided input on Draft Report

Peer Reviewers

Prior to publication of the final evidence report, EPCs sought input from independent Peer Reviewers without financial conflicts of interest. However, the conclusions and synthesis of the scientific literature presented in this report do not necessarily represent the views of individual reviewers.

Peer Reviewers must disclose any financial conflicts of interest greater than $10,000 and any other relevant business or professional conflicts of interest. Because of their unique clinical or content expertise, individuals with potential nonfinancial conflicts may be retained. The TOO and the EPC work to balance, manage, or mitigate any potential nonfinancial conflicts of interest identified.

The list of Peer Reviewers follows:

Raymond Anchan, M.D., Ph.D.
Harvard Medical School
Boston, MA

Valerie King, M.D., M.P.H.
Oregon Health & Science University
Portland, OR

Management of Uterine Fibroids

Structured Abstract

Objectives. We assessed the evidence about management of uterine fibroids. Specifically, we sought to determine effectiveness of interventions, risks of harm, and whether individual or fibroid characteristics influence outcomes.

Data sources. We searched MEDLINE® via PubMed® and Embase® to identify publications, as well as reviewed the reference lists of included studies.

Methods. We included studies published in English from January 1985 to September 2016. We identified randomized clinical trials to assess outcomes and harms of interventions. We used data from trials in a meta-analysis to estimate probability and timing of subsequent interventions for fibroids based on initial type of intervention. To describe risk of unrecognized leiomyosarcoma, we included studies that allowed calculation of prevalence of leiomyosarcoma discovered at the time of surgery for masses believed to be fibroids. We also identified publications that indicated operative approaches to removal of leiomyosarcoma tissue and built models to estimate survival. We extracted data, assessed risk of bias, and rated the strength of evidence for informing care.

Results. Of 97 included randomized trials, 43 studies assessed medications, 28 assessed procedures, and 37 assessed surgeries. Gonadotropin-releasing hormone (GnRH) agonists, mifepristone, and ulipristal reduced fibroid size and improved fibroid-related symptoms, including bleeding and quality of life (moderate strength of evidence [SOE] except quality of life for GnRH agonist [low SOE]). Several other medications have promise but are not supported by sufficient evidence. Uterine artery embolization (UAE) (high SOE) as well as high intensity focused ultrasound (low SOE) are effective for decreasing fibroid size/volume. Few other outcomes are well investigated for high intensity focused ultrasound. UAE studies reported improved outcomes for bleeding (moderate SOE), and quality of life (moderate SOE). Myomectomy and hysterectomy improved quality of life (both low SOE). Few well-conducted trials directly compared different treatment options. No studies were designed to evaluate expectant management, and evidence is insufficient to guide clinical care. Subsequent intervention ranged from 0 to 44 percent in studies that followed women after initial fibroid treatment. At 2-year followup, subsequent intervention rates were lowest for initial medical management and higher for UAE and myomectomy, especially among younger women. No individual characteristics of women or their fibroids were definitely associated with likelihood of intervention benefits or patient satisfaction. These findings were limited by the number and size of available studies. Using data from 160 studies, we estimated that among 10,000 women having surgery for presumed fibroids, between 0 and 13 will have a leiomyosarcoma detected. Of the surgical approaches, the 5-year survival after leiomyosarcoma diagnosis was 30 percent with power morcellation (95% Bayesian credible interval [BCI]: 13% to 61%), 59 percent with scalpel morcellation (BCI: 33% to 84%), and 60 percent with intact removal (BCI: 24% to 98%).

Conclusion. A range of interventions are effective for reducing fibroid size and improving symptoms. Some medications and procedures also improve quality of life. Few studies directly compare interventions. The risk of encountering a leiomyosarcoma at the time of fibroid surgery is low, and the method of fibroid removal may influence survival. Evidence to guide choice of

intervention is likely best when applied in the context of individual patient needs and preferences.

Contents

Evidence Summary **ES-1**
Introduction **1**
Condition 1
Management of Uterine Fibroids 1
Medications 1
Procedures 2
Surgery 3
Additional Management Concerns 3
Scope and Key Questions 4
Scope 4
Key Questions 5
Analytic Framework 5
Organization of This Report 6
Methods **8**
Topic Refinement and Review Protocol 8
Finding and Selecting Studies 8
Published Literature 8
Gray Literature 9
Inclusion and Exclusion Criteria 10
Data Extraction and Management 11
Outcomes 11
Outcome Measures 12
Quality (Risk of Bias) Assessment of Individual Studies 13
Data Synthesis 14
Grading the Strength of Evidence 15
Strength of Evidence Assessments 15
Overall Strength of Evidence 15
Peer Review and Public Commentary 16
Results **17**
Content of the Literature About Effectiveness 19
Key Question 1. Effectiveness of Treatment for Uterine Fibroids 20
Key Points 20
Expectant Management: Overview 21
Expectant Management: Results 22
Medical Management: Overview 24
Medical Management: Results 25
GnRH Agonists 25
Progesterone Receptor Agents: Anti-Progestins, Selective Receptor Modulators, and Levonorgestrel IUD 30
Estrogen Receptor Agents and Combined Hormonal Therapy 40
Tranexamic Acid 42
Procedures for Fibroid Intervention: Overview 42
Procedures: Results 42
Uterine Artery Embolization or Occlusion 43
High Intensity Focused Ultrasound for Fibroid Ablation 51
Radiofrequency Fibroid Ablation 52
Surgical Intervention: Overview 53
Surgical Interventions: Results 53
Endometrial Ablation 53

Myomectomy 54
Hysterectomy 57
Comparative Effectiveness Studies 60
Content of Literature for Comparing Effectiveness of Interventions 60
Analysis of Subsequent Treatment Following Initial Treatment for Uterine Fibroids 67
Key Question 2. Influence of Patient/Fibroid Characteristics on Effectiveness 68
Key Points 68
Description of Studies 68
Detailed Synthesis of Effect Modifiers 69
Summary of Effect Modification 70
Key Question 3. Risk of Leiomyosarcoma When Mass Thought To Be a Fibroid 70
Key Points 70
Overview 70
Description of Studies 71
Detailed Synthesis 71
Summary 73
Key Question 4. Influence of Morcellation and Patient/Fibroid Characteristics on Leiomyosarcoma Survival 73
Key Points 73
Description of Studies 74
Detailed Synthesis 74
Discussion 78
Key Findings 78
Strength of Evidence 78
Findings in Relation to What Is Known 82
Existing Systematic Reviews 82
Applicability 85
Implications for Clinical and Policy Decisionmaking 86
Limitations of the Systematic Review Process 88
Limitations of the Evidence Base 89
Research Recommendations 91
Conclusions 93
References 94
Abbreviations 94

Tables

Table A. Final health outcomes reported in medication studies ES-4
Table B. Final health outcomes reported in studies of procedures ES-5
Table C. Final health outcomes reported in surgical studies ES-5
Table D. Strength of evidence and summary of findings for intervention effects on fibroid volume, fibroid-related bleeding, and quality of life ES-14
Table 1. Literature search strategy: interventions for uterine fibroids 9
Table 2. Literature search strategy: morcellation and risk of cancer dissemination 9
Table 3. Inclusion criteria 11
Table 4. Strength of evidence grades and definitions 16
Table 5. Characteristics of studies included for Key Question 1 20
Table 6. Change in fibroid and uterine size with expectant management by study arm 22
Table 7. Change in bleeding characteristics with expectant management by study arm 23
Table 8. Change in fibroid and uterine size with GnRH agonists by study arm 26
Table 9. Change in bleeding characteristics with GnRH agonists by study arm 29
Table 10. Change in fibroid and uterine size with mifepristone by study arm 32

Table 11. Change in bleeding characteristics and hemoglobin with mifepristone by study arm 33
Table 12. Number of mifepristone-treated women with indicated endometrial status upon biopsy 35
Table 13. Change in fibroid and uterine size with ulipristal acetate by study arm 37
Table 14. Change in median PBAC score with ulipristal acetate by study arm 39
Table 15. Change in fibroid and uterine size with estrogen receptor agents by study arm 41
Table 16. Change in fibroid volume with uterine artery embolization by study arm 43
Table 17. Change in bleeding outcomes with uterine artery embolization by study arm 45
Table 18. Change in quality of life (SF-36) with uterine artery embolization by study arm 46
Table 19. Patient satisfaction with uterine artery embolization 48
Table 20. Subsequent fibroid treatment following uterine artery embolization by study arm 48
Table 21. Pregnancy and fertility status following uterine artery embolization 50
Table 22. Change in uterine fibroid volume following HIFU by study arm 51
Table 23. Change in hemoglobin with endometrial ablation by method 54
Table 24. Randomized trial comparisons across categories of interventions 60
Table 25. Satisfaction in studies of uterine artery embolization versus hysterectomy 65
Table 26. Transfusion by intervention category 67
Table 27. Estimated probability of subsequent treatment by age at up to 24 months of followup 68
Table 28. Leiomyosarcoma prevalence estimates 72
Table 29. Strength of evidence for expectant management 78
Table 30. Strength of evidence for GnRH treatment 78
Table 31. Strength of evidence for progesterone antagonist and selective receptor modulators 79
Table 32. Strength of evidence for estrogen receptor agents 79
Table 33. Strength of evidence for uterine artery embolization or occlusion 80
Table 34. Strength of evidence for HIFU for fibroid ablation 81
Table 35. Strength of evidence for surgery 81
Table 36. Strength of evidence for direct comparisons of interventions 81

Figures

Figure 1. Analytic framework 6
Figure 2. Literature flow diagram for Key Question 1 and Key Question 2 17
Figure 3. Literature flow diagram for Key Question 3 18
Figure 4. Literature flow diagram for Key Question 4 19
Figure 5. Risk of leiomyosarcoma at surgery for presumed fibroids 73
Figure 6. Estimated survival after surgical intervention for leiomyosarcoma by morcellation approach .. 76

Appendixes

Appendix A. Search Strategy
Appendix B. Population, Intervention, Comparator, Outcomes, Timing, and Setting
Appendix C. Screening Forms
Appendix D. Reasons for Exclusion
Appendix E. Risk of Bias Form and Summary
Appendix F. Registered Study Protocols
Appendix G. Study Outcome Data
Appendix H. Estimates of Subsequent Treatment
Appendix I. Summary of Existing Systematic Reviews

Evidence Summary

Introduction

Uterine fibroids (i.e., leiomyomata) are common benign smooth muscle tumors of the uterus. Most women will develop one or more uterine fibroids during their reproductive lifespan.[1] In the United States, an estimated 26 million women between the ages of 15 and 50 have uterine fibroids.[1-4] More than 15 million of them will experience associated symptoms or health concerns.[5,6] On average, African American women are younger at onset of fibroids, and have larger and more numerous tumors.[1,3] They are also more likely to have surgical interventions for fibroids.[7] Over the reproductive lifetime prevalence becomes more similar so that by age 49, more than 70 percent of white women and 84 percent of African American women have fibroids documented by imaging or surgical records.[1]

The personal and societal costs of diminished quality of life, disruption of usual activities and roles, lost work time, and healthcare expenditures are substantial. Including all types of interventions, direct annual healthcare costs in the United States are projected to exceed $9.4 billion.[8] Lost wages, productivity, and short-term disability are estimated to total more than $5 billion, perhaps as much as $17 billion, with roughly $4,624 in costs per woman in the first year of diagnosis.[8,9]

Treatment options differ in fundamental aspects such as cost, invasiveness, recovery time, risks, likelihood of long-term resolution of symptoms, need for future care for fibroids, and influence on future childbearing. Thus synthesis of available evidence is crucial to assist women and their care providers in making well-informed and personalized decisions.

One concern affecting surgical treatment is the risk of discovering a leiomyosarcoma, a cancer of the uterine muscle, rather than a fibroid at surgery. These are rare but ominous: an average of 1,600 new cases occur in the United States each year. They have poor outcomes with an average 5-year survival of 36 percent if cancer is not isolated to the uterus.

Scope

To inform clinical decisions about care we focused on evidence from randomized controlled trials (RCTs) that assess currently available interventions for women of any age with fibroids. We also sought to identify factors that might influence likelihood of favorable results or harms from treatments. We included studies evaluating medications (including intrauterine devices [IUDs] as they deliver medication), procedures, and surgeries for the management of uterine fibroids. We considered more invasive interventions that are typically performed in an operating room or require at least a brief hospital stay as surgical and interventions that can typically be conducted in an office or as same-day surgery as procedures.

We also summarized data from women who were followed within trials without active intervention. In light of recent uncertainty about the risk of cancer dissemination following morcellation of fibroids, this review also includes literature to estimate the prevalence of leiomyosarcoma and influence of morcellation on survival in women with leiomyosarcoma.

Key Questions

Key Question 1. What is the comparative effectiveness (benefits and harms) of treatments for uterine fibroids, including comparisons among these interventions?

Key Question 2. Does treatment effectiveness differ by patient or fibroid characteristics (e.g., age; race/ethnicity; symptoms; menopausal status; imaging characteristics; vascular supply to fibroids; or number, size, type, location, or total volume of fibroids)?

Key Question 3. What is the risk of encountering a leiomyosarcoma for masses believed to be uterine fibroids at the time of myomectomy or hysterectomy?

Key Question 4. Does survival after leiomyosarcoma differ by patient or fibroid characteristics (e.g., age; race/ethnicity; symptoms; menopausal status; imaging characteristics; vascular supply to fibroids; or number, size, type, location, or total volume of fibroids) or by surgical approach to morcellation?

Methods

We searched MEDLINE® via PubMed® and Embase® to identify publications in English from January 1985 to September 2016. We also checked the reference lists of included studies. We dually reviewed each publication against *a priori* inclusion/exclusion criteria. For Key Question (KQ) 1 and KQ2, we identified RCTs to assess benefits or harms of medical, procedural, or surgical interventions compared with an alternative intervention or inactive control, including expectant management, placebos, or sham procedures. Eligible studies for KQ1 or KQ2 had to report one or more patient-centered outcomes or fibroid characteristics at baseline and in followup (e.g., symptom improvement, bleeding pattern, pain, quality of life). We did not present studies reporting only intermediate outcomes such as technical success, conversion to alternate procedure, estimated blood loss during procedure, wound healing status, length of stay, and readmission or reoperation, except in the discussion of specific harms (see analytic framework in full report).

We extracted data, assessed risk of bias, and rated the strength of the evidence for informing care using standard Agency for Healthcare Research and Quality (AHRQ) systematic review methods. We used followup data across all trials of medical management, UAE, or myomectomy that included subsequent treatment to estimate probabilities of selecting subsequent treatment. The probability of the occurrence of subsequent treatment events was estimated using a Poisson model, where the rate of occurrence was assumed to be a function of patient age and study followup time, on a logarithmic scale.

To understand risk of leiomyosarcoma and the influence of morcellation on survival (KQ3 and KQ4) we conducted dual review and data extraction from observational studies, and trials with relevant data. Our models included the effect of the mean age of women in each study and the year in which it was published as candidate covariates and we stratify by prospective versus

retrospective study design. For KQ3, we structured a search to encompass the papers included in a 2015 review and meta-analysis[10] that estimated the prevalence of leiomyosarcoma among tumors presumed to be fibroids. We updated the search, used comparable eligibility criteria, and calculated new estimates for the prevalence of leiomyosarcoma identified at the time of surgery for presumed fibroids including both the prior studies and newly identified papers. To be included, papers were required to provide data to calculate the proportion of surgeries for fibroids that revealed leiomyosarcoma. We calculated meta-estimates of the probability of leiomyosarcoma for all relevant studies and by study characteristics.

For KQ4 we conducted a broad search and reviewed potentially eligible papers for those that included data about leiomyosarcoma diagnosis and survival as well as the proportion of women exposed to morcellation who were subsequently diagnosed with leiomyosarcoma or disseminated leiomyosarcoma (meaning presence or recurrence of leiomyosarcoma beyond the initial operative tissue specimen). We extracted data to allow comparison of survival for three groups: those with power morcellation, those with sharp (scalpel) morcellation, and those with no morcellation (the uterus was removed intact). We generated Kaplan-Meier survival curves using event times when they were available in order to compare survival time by method of surgical removal of the specimen.

Results

The first AHRQ systematic review on the management of uterine fibroids was published in 2001 and included 30 randomized trials of interventions to treat fibroids.[11] A more recent AHRQ review in 2007 identified 29 additional trials.[12] Across reviews, most studies had poor quality and typically reported only on technical success of the intervention with abbreviated followup of outcomes. Longer-term outcomes such as quality of life, fertility, sexual function, improvement in symptoms and satisfaction with care were rarely reported. These reviews served to answer key questions about epidemiologic correlates of fibroids, to demonstrate lack of evidence about natural history of disease, provided models of lifetime incidence and need for treatment and included cohort studies as a surrogate for trials to examine preliminary evidence of effectiveness and predictors of outcomes.

In the intervening years, the literature has grown to include 121 publications from 97 unique trials (see main report for full reference list). Newer studies have been of somewhat higher quality—18 in this report were judged good quality trials, 27 fair, and 52 poor quality. More interventions have been assessed for longer followup periods, up to 5 years. Patient-reported outcomes are more common, reported in 63 percent of studies, as are data to determine what sequences of interventions are most likely to be chosen subsequently by women with reference to their prior treatment allocation in trials (48 studies). More trials also provide more data to examine whether particular desired outcomes are more likely to be achieved among women with specific characteristics. Six studies provided information about factors such as age, menopausal status, and fibroid characteristics that may modify outcomes or risk of adverse events.

Clinical trials are not powered to detect harms. To address the current pressing concerns of potential for cancer dissemination at the time of surgery for fibroids, we identified a separate literature of 160 publications to examine risk that a mass believed to be a fibroid was found to be a leiomyosarcoma. We also sought data within 28 papers that allowed estimation of the risk of progression of leiomyosarcoma by type of morcellation used, estimating aggregate mortality by surgical methods used. Lastly, we combed these papers for data about whether characteristics of women or the masses believed to be fibroids were associated with leiomyosarcoma presence or

modified the likelihood that morcellation during a surgery for fibroids would be associated with harm.

KQ1: Effectiveness of Treatments for Fibroids

The included RCTs reported effectiveness more often than harms. We summarize our results below by category of intervention, providing data about adverse events when available and statistically informative. We categorized interventions using the publication authors' description. Interventions include expectant management or placebo; medications to improve or resolve symptoms or reduce size of fibroids (including those delivered via IUDs); procedures (uterine artery occlusion via embolization, ligation, or coagulation; and fibroid ablation (e.g., high intensity focused ultrasound, radiofrequency); and surgery (including endometrial ablation; hysterectomy via abdominal, vaginal, and laparoscopic approaches and those with robotic assistance; and myomectomy via laparotomy, laparoscopy, hysteroscopy, or with robotic assistance).

Evidence Map for KQ1

We summarize the number of studies reporting final health outcomes, number of participants and duration of followup for medications (Table A), procedures (Table B), and surgeries (Table C). Complete outcomes data are available in the Systematic Review Data Repository.

Table A. Final health outcomes reported in medication studies

Intervention	Outcome Category	Studies Reporting N	Baseline Participants N	Duration of Followup, Range in Months[a]
GnRH Agonists[b]	Symptom status	13	785	<1 to 36
	Sexual function	1	60	0
	Fibroid characteristics	18	912	<1 to 36
	Subsequent treatment for fibroids	1	51	6
Progesterone Receptor Agents[c] (mifepristone, ulipristal, levonorgestrel IUD)	Symptom status	18	1,916	0 to 18
	Pregnancy outcomes	1	220	9
	Sexual function	1	220	9
	Fibroid characteristics	18	1,916	0 to 18
	Subsequent treatment for fibroids	8	1,224	3 to12
Estrogen Receptor Agents[d] (raloxifene, tamoxifen, HRT)	Symptom status	6	201	2 to 60
	Fibroid characteristics	6	201	2 to 60
	Subsequent treatment for fibroids	1	10	60
Other Medications (cabergoline, tranexamic acid, tibolone)	Symptom status	3	178	0.23 to 3
	Fibroid characteristics	2	55	0.23
	Subsequent treatment for fibroids	1	30	0.23

GnRH = gonadotropin-releasing hormone; HRT = hormone replacement therapy; IUD = intrauterine device; N = number

[a]Duration of followup is defined as months elapsed from end of active treatment to evaluation of outcome(s)
[b]Includes only those GnRH studies discussed in the GnRH report section
[c]Anti-progestins, selective receptor modulators, and levonor-gestrel IUD
[d]Selective receptor modulators, antagonists, and HRT (transdermal estradiol plus cyclic oral medroxyprogesterone acetate)

Table B. Final health outcomes reported in studies of procedures

Intervention	Outcome Category	Studies Reporting N	Baseline Participants N	Duration of Followup, Range in Months[a]
Uterine Artery Embolization	Symptom status	14	963	3 to 60
	Fibroid characteristics	21	1204	3 to 60
	Subsequent treatment for fibroids	11	784	6 to 60
	Satisfaction with outcomes	8	584	6 to 60
Radiofrequency Fibroid Ablation	Symptom status	2	76	0 to 24
	Fibroid characteristics	2	76	0 to 24
High Intensity Focused Ultrasound for Fibroid Ablation[b]	Symptom status	2	53	1 to 24
	Sexual function	1	50	<1
	Fibroid characteristics	5	216	1 to 24

N = number
[a]Duration of followup is defined as months elapsed from procedure to evaluation of outcome(s); [b]High intensity focused ultrasound includes procedures guided by magnetic resonance imaging

Table C. Final health outcomes reported in surgical studies

Intervention	Outcome Category	Studies Reporting N	Baseline Participants N	Duration of Followup, Range in Months[a]
Endometrial Ablation	Symptom status	1	96	12
	Subsequent treatment for fibroids	1	96	12
Myomectomy	Symptom status	4	285	3 to 24
	Pregnancy outcomes	5	447	12 to 36
	Sexual function	1	52	6
	Fibroid recurrence	5	494	6 to 40
	Subsequent treatment for fibroids	3	219	24 to 36
	Satisfaction with outcomes	4	339	3 to 24
Hysterectomy	Symptom status	1	30	24
	Satisfaction with outcomes	5	317	1 to 24
Hysterectomy or Myomectomy	Symptom status	2	71	12 to 60
	Pregnancy outcomes	1	20	12
	Fibroid characteristics	1	51	60
	Subsequent treatment for fibroids	2	115	12 to 60
	Satisfaction with outcomes	2	115	12 to 60

N = number
[a]Duration of followup is defined as months elapsed from surgery to evaluation of outcome(s)

To synthesize anticipated effects of interventions based on this literature, we group trial arms in text and tables to be able to describe outcomes of those interventions together. Throughout this report, we refer to whether or not a study assessed ***change*** in specific measures including fibroid characteristics like size or volume, symptoms (bleeding or pain), and quality of life. Indicating the study assessed change means it evaluated the characteristic or symptom at baseline and again

at one or more times after treatment. Noting that a study or studies assessed change is not equivalent to noting a beneficial effect or statistical significance in changes. Rather, noting measurement of change in a parameter establishes the total count of studies that addressed this outcome.

Expectant Management

We did not identify any studies intentionally designed to determine outcomes of no intervention, also called expectant management or watchful waiting. However, 16 small RCTs compared a treatment to no intervention, typically trials that compared a medication with placebo. Of these trials two were of good quality, six were fair, and eight were poor quality. The evidence, based on an average followup time of five months (range: 3 to 12 months), suggests the size of fibroids does not meaningfully change over these short timespans. One study reported a four percent reduction in size and those that reported volume measures documented an average increase in size of about 9 cm^3, which is about one-fifth the size of a golf ball. The two studies that followed postmenopausal women for a full year did not detect an increase in total volume of fibroids.

Likewise, bleeding characteristics, such as days of bleeding and severity of bleeding as measured by hemoglobin, heaviness of periods, and severity of heavy bleeding episodes, did not change meaningfully during followup for those without active management. The proportion of the 514 women enrolled in these trials who presented specifically with problem bleeding, as opposed to other fibroid-related symptoms, is not known. However, the data suggests that women with fibroids should not expect that bleeding patterns will worsen over the near term.

Summary/Strength of Evidence (SOE): None of these studies were designed to evaluate expectant management. The number of women in the literature followed without intervention is small, and these participants may be fundamentally different from other women with fibroids since they were willing to risk randomization to no intervention. For these reasons, the evidence is insufficient to inform choice of expectant management over other options.

Medical Management

We identified 43 studies assessing effectiveness of medical treatment (including progesterone delivered by IUD) for uterine fibroids. Ten studies had placebo or no treatment comparison groups. Approximately one third were industry sponsored. The longest duration of followup after the end of treatment was 60 months in one study. Women included in the studies were predominately premenopausal (39 studies). Four studies evaluated therapies in postmenopausal women. We assessed four as good quality, 12 as fair quality, and 27 as poor quality for effectiveness outcomes.

GnRH (Gonadotropin-Releasing Hormone)Agonists

Eighteen studies (reported in twenty publications) addressed GnRH agonists, which included seven studies of “add-back” therapy (addition of a second agent to a GnRH agonist). The studies included 912 participants, and followup was typically limited to the immediate end of treatment. Only six studies followed women post-treatment, for 3 to 6 months. GnRH agonists reduce the size of fibroids, with reductions in volume of fibroids documented between 64 and 175 cm^3 and reductions in the total volume of the uterus between 131 and 610 cm^3.

Six studies reported complete absence of bleeding during treatment, three noting statistical significance for clinically important reduction from baseline. No study reported an increase in

bleeding or worsening in hemoglobin or hematocrit. Individual women in several studies discontinued treatment because bleeding became more irregular or did not decrease.

Pain symptoms improved by GnRH treatment in four studies included pelvic pressure, pelvic and abdominal pain, and dysmenorrhea. Two studies reported similar improvements but without statistical comparisons of baseline to followup. Studies consistently reported significant improvement in measures of quality of life symptoms (days of bleeding, heavy menstrual bleeding, pelvic pressure, pelvic pain, urinary frequency, and constipation). Harms associated with GnRH included onset of menopausal symptoms, unfavorable changes in lipid profile, declines in cognitive function and memory, and bone loss, although some of these can be ameliorated with hormonal add-back therapy. Extended followup of women after they discontinue GnRH agonists is limited.

Summary/SOE: Moderate strength of evidence supports that GnRH agonists (with and without add-back therapy) reduce the size of fibroids, the overall size of the uterus, and bleeding symptoms. Low strength of evidence suggests that fibroid-related quality of life improves with and without add-back therapy.

Progesterone Receptor Agents: Anti-Progestins, Selective Receptor Modulators, and Levonorgestrel IUD

Seven studies provided data about outcomes of the anti-progestin mifepristone treatment. Average length of time for off-medication followup was 11 months with the longest untreated followup being 18 months. All studies observed a decrease in the size of fibroids at the completion of the period of active treatment. The magnitude of change in size of the largest fibroid ranged from a decrease of 37 cm^3 to 95 cm^3, with an average decrease of 71 cm^3 among the 575 women receiving mifepristone. Total uterine volume also decreased across women receiving mifepristone.

All studies of mifepristone that assessed bleeding reported reduced heaviness of bleeding. Two comparisons found mifepristone superior to placebo. Women were more or equally likely to have decreased bleeding or absent menses on the lower doses compared with the higher doses. Each of six studies that evaluated pelvic pain before and at conclusion of treatment noted substantial improvements (present in 68% to100% at baseline compared with 9% to 28% after 3 months of treatment); findings were similar at the conclusion of 6 to 9 months of treatment and maintained post-treatment in roughly 60 percent to 90 percent of women in three RCTs with longer term followup. Four studies reporting the outcome consistently noted significant improvements in quality of life measures. Some studies suggested fibroids do resume growth after treatment. Few participants in these trials pursued other treatment during or after active treatment. Harms included spotting, elevations in liver function enzymes, and endometrial hyperplasia.

Six studies investigated treatment with ulipristal, a selective progesterone receptor modulator. All studies found ulipristal effective for reducing the size of individual fibroids and the overall fibroid burden as measured by total fibroid or uterine volume. Ulipristal, as intended, resulted in absent menses for the majority of women during treatment (range: 62% to 100%) and improved or stabilized hematocrit or hemoglobin. The exception was among women who had submucous fibroids who, in one study, had less improvement in bleeding. Compared with placebo, all ulipristal doses improved fibroid-related quality of life, and two of the six trials also documented improvement in pain. Durability of effect at 6 months was assessed in two studies:

one found minimal resumption of fibroid growth (8.1%) after completion of treatment regardless of ulipristal dose. A second found that the 10 mg dose sustained fibroid size reduction while there was increase in size on the 5 mg dose that was similar to placebo. Ulipristal was associated with hot flashes, hyperplasia, and increases in liver function enzymes, although it is not clear if these effects persist after treatment ends.

Levonorgestrel (LNG) IUD improved bleeding (the only outcome of interest reported); however, the single available trial was of poor quality including lack of participant masking.

Summary/SOE: There is moderate strength of evidence that both mifepristone and ulipristal effectively reduce the size of fibroids and bleeding symptoms, while improving quality of life. Duration of effects is uncertain. Evidence is insufficient to choose between higher and lower doses. Evidence was insufficient to assess the effectiveness of the LNG-IUD on any outcomes

Estrogen Receptor Agents

Six studies included agents that act at the estrogen receptor. Three studies, two of fair quality and one of poor quality, investigated raloxifene (which acts as an anti-estrogen in breast and endometrial tissue) in comparison with placebo. Fibroid size decreased by 4.4 cm^3 to 34.2 cm^3 in two studies of raloxifene and did not change size in another raloxifene study (To put this in perspective, 40 cm^3 is the volume of a golf ball). In raloxifene studies with premenopausal women, neither bleeding pattern (in 3 studies) nor hemoglobin levels (in one study) were improved compared with placebo. Among postmenopausal women, the percent of treatment cycles without bleeding was similar and the number of episodes of spotting and severity of bleeding were similar among women in the treated and control group.

A single poor quality study evaluated tamoxifen, which acts as an anti-estrogen within breast tissue and as an estrogen ligand in the endometrium. Tamoxifen use in premenopausal women did not influence length or severity of bleeding compared with placebo. Change in fibroid characteristics was not reported. Women receiving tamoxifen had less pain after four months of treatment compared with placebo.

Two poor quality RCTs had a total of 42 women receiving hormone replacement therapy (HRT) (transdermal estrogen replacement plus cyclic oral medroxyprogesterone acetate) after menopause. They compared hormone therapy to tibolone (not available in United States) for menopausal symptom management with attention to whether treatment increased size of fibroids. Growth was approximately 10 cm^3, which is a quarter the size of a golf ball. In the longer study there was no further growth between 6 and 12 months.

No studies reported any serious adverse effects.

Summary/SOE: Studies provide low strength of evidence that, if prescribed to women with fibroids for other conditions such as breast cancer prophylaxis, raloxifene will not cause significant growth of existing fibroids or exacerbate bleeding. Evidence is insufficient to assess if tamoxifen or HRT does or does not promote fibroid growth.

Procedures for Uterine Fibroids

We identified 28 studies assessing procedures for uterine fibroids. Most studies compared similar procedures, two compared different procedures, and nine compared procedures against surgery or medications. The longest duration of followup after the end of treatment was 5 years in two studies. Participants were predominately premenopausal. We assessed 6 studies as good quality, 8 as fair quality, and 14 as poor quality for effectiveness outcomes.

Uterine Artery Embolization (UAE) and Occlusion

We identified 21 studies that randomized women to UAE or uterine artery occlusion. We assessed five studies as good quality, eight as fair quality, and eight as poor quality for effectiveness outcomes. Fibroid and uterine volume decreased significantly and consistently following UAE (up to 12 months postprocedure) regardless of the embolization agent or size of particles used to occlude the fibroid arteries. Longer-term followup reports from the Embolization for the Treatment of Symptomatic Uterine Fibroid Tumors Study, called the EMMY Trial, confirmed that fibroid and uterine volume reductions persist up to 5 years after UAE; however, 28 percent (23/81) of women underwent subsequent hysterectomy. Subsequent treatment was reported in 11 trials with length of followup ranging from 6 to 60 months (Table 23 in the full report). Hysterectomy was the most frequent intervention (8.9%) followed by repeat embolization (4.2%), myomectomy (3.6%), medication or IUD (1.1%) and endometrial ablation (0.1%).[13-23]

For UAE, bleeding effects were consistent, with declines in bleeding or bleeding-related measures reported in seven studies. Pain improved in up to 84 percent of women in two studies reporting this outcome. Only eight studies of UAE measured quality of life, which consistently improved postprocedure with durability in the two studies with longer-term followup. Treatment satisfaction was high in seven studies reporting this outcome.

No women receiving UAE required transfusion. Risk of major complications during and following UAE ranged from 1.2 to 6.9 percent around the time of the procedure up to about 5 percent by 2 years. The probability of "major complications" as defined by authors was high in two studies that reported long-term followup (21% at 5 years in the Randomised comparison of uterine artery embolisation with surgical treatment in patients with symptomatic uterine fibroids Study, termed the REST Trial, and 16.8% at 32 months in a second study) in large part because they considered any subsequent procedure a complication, while other authors did not. Fertility outcomes were not evaluated in the UAE-only trials. When available, pregnancy outcomes after UAE are presented in the sections that compare UAE to other procedures or surgeries.

Trials of uterine artery occlusion were small, and a variety of intervention methods were described, which prohibits conclusions.

Summary/SOE: There was high strength of evidence that UAE is effective for reducing the size of fibroids and total uterine volume. Moderate strength of evidence finds that bleeding and quality of life is improved following embolization. The effect of UAE on reproductive outcomes is not well studied and evidence is insufficient to guide care or determine safety.

High Intensity Focused Ultrasound for Fibroid Ablation

Six studies (reported in 7 publications) assessed high intensity focused ultrasound (HIFU) for fibroid ablation, but only one fair quality pilot study (n=20) used magnetic resonance imaging (MRI) guidance, which is used in the United States. The other studies were rated as poor quality primarily due to lack of masking participants and outcome assessors to the intervention received. In four studies reporting effects on fibroid size, the magnitude of fibroid volume reduction was greater at 12 months after ultrasound destruction than at 1 month post-treatment. One year after treatment fibroid volume decreased by averages of 90 and 170 cm^3 in two studies. Studies did not report on bleeding, pain, or pregnancy outcomes. One study addressed quality of life but did not report baseline data, and one reported improvements in sexual function. One study reported no transfusions among 48 participants. No study reported major complications.

Summary/SOE: HIFU reduced fibroid and uterine size, but strength of evidence is low because of short followup and poor quality of overall study design. Evidence related to patient reported outcomes is insufficient.

Radiofrequency Fibroid Ablation

Two RCTs, both assessed as poor quality, addressed radiofrequency ablation of fibroids. Both studies reported the technique was successful in delivering treatment to 5 percent or more of the targeted fibroid volume. Studies provided limited data on effects of ablation on bleeding, quality of life, and subsequent pregnancies, but did not report pain outcomes and noted no major complications.

Summary/SOE: The strength of evidence for radiofrequency ablation is insufficient to inform care.

Surgical Management

We identified 37 randomized trials with at least one arm that assessed surgical intervention (endometrial ablation, myomectomy, or hysterectomy) for uterine fibroids. One compared myomectomy to hysterectomy, the remainder evaluated outcomes in women treated by UAE, uterine artery occlusion, HIFU, or medication. The longest duration of followup after the end of treatment was 60 months in two studies. Women included in the studies were predominately premenopausal. We assessed nine as good quality, 11 as fair quality, and 17 as poor quality for effectiveness outcomes.

Endometrial Ablation

One fair quality study addressed endometrial ablation and reported significant decreases in bleeding after both rollerball and thermal balloon ablation, with similar rates of reintervention (9%) in both groups. More women in the rollerball group had complications. More than a third of women receiving each intervention noted dissatisfaction with ablation results on a single item with three levels of satisfaction. Dissatisfaction was associated with failure to achieve amenorrhea.

Myomectomy

Fifteen RCTs reported health outcomes after myomectomy and five additional studies provided information about harms. We assessed four studies as good quality, six as fair quality, and 10 as poor quality. Studies did not report changes in fibroid characteristics (e.g., proportion of fibroids removed at myomectomy, decrease in uterine volume). One small study reported improved bleeding patterns one year after surgery in 12 of 15 women. Another described change in undefined symptoms with relief reported by 51 of 88 women. Fibroid recurrence, reported in five studies, ranged from 2.5 percent to 25 percent with duration of followup ranging from 6 to 60 months. Two additional studies reported no recurrences at 6 month followup. Laparoscopic myomectomy was associated with faster return to usual activity than comparator surgeries in three studies and with improved quality of life compared with hysterectomy in one study. Laparoscopic myomectomy was also associated with better fertility and pregnancy outcomes over other myomectomy techniques in one study (n=136), but outcomes were comparable in another RCT (n=131). Transfusion rates were most often zero (1,040 participants in 10 studies). Six studies reported 25 transfusions among 502 participants treated by myomectomy, and seven did not report transfusion. Intraoperative conversion from myomectomy to another procedure

ranged from 0 to 17 percent in eight studies (n=658). Harms associated with myomectomy included transfusion and pelvic organ injury. Harms did not differ among techniques.

Summary/SOE: Myomectomy is associated with improved quality of life (low strength of evidence). Since myomectomy removes fibroids, the effect on fibroid size is not measured, and strength of evidence is not graded. Evidence is insufficient to determine if myomectomy meaningfully improves bleeding patterns or anemia. Myomectomy is an option for women desiring future fertility, though evidence is insufficient to define potential benefit.

Hysterectomy

We identified 14 RCTs assessing hysterectomy (via abdominal, vaginal or laparoscopic-assisted approaches) in women with uterine fibroids. Seven reported harms only (i.e., did not report final health outcomes for effectiveness). Assessment duration (where clearly reported) in comparative studies ranged from 15 days to 24 months. We assessed five as good quality, three as fair quality, and six as poor quality for effectiveness outcomes. Among seven studies reporting health outcomes, one noted a decrease in hemoglobin postoperatively, and two reported increases in hemoglobin levels 24 months after surgery. Pain symptoms improved in three RCTs reporting outcomes of fibroid-related pain. Time to return to usual activity after hysterectomy averaged 30 to 40 days in three studies. One study reported faster recovery (mean 22 days) after laparoscopic hysterectomy. Women reported good or very good satisfaction postoperatively, though one study reported worsened physical health compared with baseline measures at 5-year followup.

The percent of women needing transfusion following hysterectomy ranged from 0 to 20 percent in 890 women from 11 studies. An event of organ perforation occurred in one study, but overall risk across studies cannot be calculated since bowel and bladder injury were not uniformly reported across studies.

Summary/SOE: Hysterectomy de facto reduces uterine size and bleeding; the strength of this evidence cannot be graded. There is low strength of evidence that hysterectomy improves quality of life.

Direct Comparisons of Interventions

In total, 17 studies compared the effectiveness of two or more interventions. We identified four studies designed to compare outcomes across two or more of drugs (e.g., GnRH vs. ulipristal acetate). Overall these studies were small and inadequately powered for providing definitive evidence of greater effectiveness.

Two studies compared HIFU to other interventions, with greater tumor destruction after radiofrequency ablation compared with HIFU, and comparable sexual function after HIFU or myomectomy, but faster recovery in the HIFU groups.

Other direct comparisons of procedures included comparisons of UAE to myomectomy or hysterectomy. Technical success and quality of life were similar between UAE and myomectomy but reintervention rates were higher with UAE. Because of low power to detect differences, the evidence is insufficient to determine if pregnancy outcomes are better after myomectomy compared to UAE. Likewise ovarian reserve was assessed in only one study comparing UAE to hysterectomy. Symptom relief and quality of life outcomes were generally similar between UAE and hysterectomy (regardless of surgical approach), with faster recovery associated with UAE. Subsequent treatment rates were higher in the UAE group than in the hysterectomy group at each time point in followup; however, the majority of women randomly assigned to have UAE avoided hysterectomy for the duration of followup, which included 5

years of surveillance in the largest study. Fewer than one in three women with UAE required additional treatment.

Summary/SOE: Because of low power to detect differences, the evidence is insufficient to determine if outcomes differ in direct comparisons of procedure or medications

Analysis of Subsequent Treatment Following Initial Treatment for Uterine Fibroids

From data reported in 38 studies, we estimated the probabilities of receiving additional treatment for fibroids after randomization to initial treatment with medical management, UAE, or myomectomy. For women in their 30s, the model predicted that the probability of subsequent intervention for fibroids over 2 years varied from 6 to7 percent after medical treatment or myomectomy, to 44 percent after UAE. For women in their 40s and 50s, modelled 2-year reintervention rates were 9 to19 percent following medical treatment or UAE, and 0 percent after myomectomy.

Overall, fewer than half of women had another intervention within 24 months. UAE was most often followed by myomectomy among those in their 30s, and by hysterectomy among those in their 50s. Younger women who initially had myomectomy were most likely to have repeat myomectomies over the 2 years of followup. After medical treatment, very few women in any age group had subsequent treatment within 2 years.

KQ2: Influence of Patient/Fibroid Characteristics on Effectiveness

Among 97 randomized clinical trials of interventions, none were explicitly designed to address whether intervention effectiveness varied by patient or fibroid characteristics. Six studies provided some information about influence of characteristics on outcomes within or across arms (two of medications, two comparing UAE and surgery, one of myomectomy vs. no treatment, and one assessing the effects of baseline characteristics on outcomes among women who received high intensity focused ultrasound or radiofrequency ablation). None were statistically powered to examine effect modification by characteristics to answer questions such as: do those with fewer or smaller fibroids do better that those with more or larger fibroids? do women using hormonal contraceptive have different outcomes over time after this treatment compared to those who don't? and does baseline BMI determine results? As a result there is little data that can be used to guide care based on individual or fibroid characteristics.

KQ3: Risk of Leiomyosarcoma When Mass Thought to Be a Fibroid

We replicated and updated the search from a recently published meta-analysis of prevalence of leiomyosarcoma among women treated for benign uterine fibroids.[10] We added 27 studies (26 cohort studies and 1 RCT) published since the conduct of the prior meta-analysis. We fit a Bayesian binomial random effects model to update the estimate of prevalence of identifying a leiomyosarcoma at the time of surgery for presumed fibroids. The most inclusive estimated prevalence, from 68 prospective studies where conflicting data were clarified, is 0.02 percent (95% credible interval, 0.00 to 0.09%). When we limit the analysis to retrospective studies, the estimate is 0.09 percent (95% credible interval, 0.05 to 0.13%). Lack of precision means these estimates are not credibly different. In other words, using data from 160 studies, an unexpected leiomyosarcoma will be identified in fewer than one and up to 13 of every 10,000 surgeries performed for symptomatic fibroids.

KQ4: Factors Affecting Leiomyosarcoma Survival

Survival time for women with leiomyosarcoma for whom power morcellation was used was reduced compared with women for whom sharp morcellation (with a scalpel) was used and with those for whom the uterus was removed intact. From our meta-analysis, power morcellation has expected 5-year survival of 30 percent (95% Bayesian credible interval [BCI] 13% to 61%); scalpel morcellation, 59 percent (BCI: 33% to 84%); and intact removal, 60 percent (BCI: 24% to 98%).Though confidence bounds overlap, this analysis suggests method of morcellation may contribute to overall lethality of this aggressive form of cancer among those diagnosed with leiomyosarcoma after hysterectomy or myomectomy for fibroids. Evidence was insufficient to conclude whether patient and fibroid characteristics affected survival in women with leiomyosarcoma.

Discussion

Evidence about effectiveness of treatment is synthesized across arms of studies that used the intervention in order to describe outcomes by intervention. If a study included different types of interventions, each is included in the related synthesis and discussion.

KQ1. Effectiveness of Treatments for Fibroids

Insufficient evidence suggests that expectant management results in minimal change over followup periods of a year or less. Our findings are compatible with a prior review that included observational cohorts. [12] Outcomes are likely to differ by menopausal status, and longer term studies are needed.

Among medical therapies, GnRH agonists, mifepristone, and ulipristal reduced fibroid size and improved fibroid-related symptoms including bleeding and quality of life (moderate SOE, except for quality of life for GnRH agonist (low SOE)). Several other medications have promise but are not supported by sufficient evidence. Evidence is insufficient to detect differences by medication dose, duration of treatment, long term effectiveness and harms. Evidence is lacking for common clinical approaches such as non-steroidal anti-inflammatory drugs, oral contraceptives and is insufficient for the LNG-IUD.

With notable exceptions, the majority of surgical studies did not follow patients beyond the postoperative period. Therefore, many studies did not report patient-specific, or symptom related outcomes such as change in fibroid-related pain or bleeding. Many of the studies with surgical or procedural interventions reported intermediate outcomes only, such as technical success, hospital length of stay, or estimates of blood loss related to the surgery (e.g., postoperative hemoglobin, intra- or postoperative transfusion). Despite these limitations, we found that uterine artery embolization (UAE) (high SOE) as well as HIFU (low SOE) are effective for decreasing fibroid size/volume. Few other outcomes are well investigated for HIFU. UAE studies reported improved bleeding outcomes (moderate SOE), pain, and quality of life (moderate SOE). Myomectomy improves quality of life (low SOE). Hysterectomy improves quality of life (low SOE) and de facto resolves bleeding and bulk symptoms.

Table D summarizes the strength of evidence for the effectiveness of interventions on fibroid/uterine volume, fibroid-related bleeding, and quality of life because these were most frequently reported outcomes in the eligible studies for KQ1. For the complete assessment of strength of evidence, including risk of bias, study limitations, reporting bias, precision, consistency and directness of results, see the summaries presented in the full report.

Table D. Strength of evidence and summary of findings for intervention effects on fibroid volume, fibroid-related bleeding, and quality of life

Intervention Category Total N Participants	Key Outcome(s)	Strength of Evidence	Key Findings
Expectant management N=514	Change in fibroid size or uterine volume	Insufficient	Few women followed in 16 study arms; findings inconsistent; data inadequate to project course of watchful waiting (followup from 3-12 months)
	Change in bleeding	Insufficient	As above
	Quality of life	Insufficient	As above
GnRH agonist N=912	Change in fibroid size and uterine volume	Moderate	Consistent reductions in size or volume
	Change in bleeding	Moderate	Bleeding outcomes (e.g., menorrhagia, perceived blood loss, days of bleeding) consistently improved
	Quality of life	Low	Consistent improvements in arms reporting varied measures of quality of life
Mifepristone N=690	Change in fibroid size or uterine volume	Moderate	Consistent reductions in size or volume in study arms reporting these outcomes
	Change in bleeding	Moderate	Consistent improvements in bleeding outcomes (e.g., hemoglobin, amenorrhea, hypermenorrhea) in arms reporting these outcomes
	Quality of life	Moderate	Quality of life improved in study arms reporting varied measures of quality of life
Ulipristal N=1,095	Change in fibroid size and uterine volume	Moderate	Improvements in arms reporting these outcomes, with reductions generally maintained over 6 month followup
	Change in bleeding	Moderate	Bleeding outcomes (e.g., amenorrhea, hemoglobin) consistently improved in study arms reporting these outcomes
	Quality of life	Moderate	Improvement in fibroid-related quality of life in study arms reporting varied measures of quality of life
LNG-IUD N=30	Change in bleeding	Insufficient	Limited data in one small study with high risk of bias
Estrogen receptor agents (raloxifene, tamoxifen) N=117	Change in fibroid size and uterine volume	Low	Lack of effect on fibroid size with raloxifene
	Change in bleeding	Low	No changes in bleeding patterns or hemoglobin with raloxifene
Uterine artery embolization and occlusion N=1,376	Change in fibroid size and uterine volume with UAE	High	Consistent reduction in size in study arms reporting these outcomes, with two studies reporting continued effects for 5 years
	Change in bleeding with UAE	Moderate	Improvements in bleeding outcomes (e.g., days of bleeding, hemoglobin, patient-rated bleeding) in study arms reporting these outcomes
	Quality of life with UAE	Moderate	Improvements in study arms reporting varied

Intervention Category Total N Participants	Key Outcome(s)	Strength of Evidence	Key Findings
			measures of quality of life
	Change in bleeding, fibroid size with uterine artery occlusion	Insufficient	Heterogeneity of intervention methods prohibits conclusions
HIFU for fibroid ablation N=264	Change in fibroid size and uterine volume	Low	Reduction in study arms reporting these outcomes
Radiofrequency fibroid ablation N =75	Change in bleeding	Insufficient	Limited data available to assess outcome
Endometrial ablation N=96	Change in bleeding	Insufficient	Limited data available to assess outcome
Myomectomy N=2,257	Change in fibroid size and uterine volume	N/A	N/A
	Change in bleeding	Insufficient	Few studies reported outcome; improvement in heavy bleeding noted in one study
	Quality of life	Low	Improvements in study arms reporting varied measures of quality of life
Hysterectomy N=1,116	Change in fibroid size and uterine volume	N/A	N/A
	Change in bleeding	N/A	N/A
	Quality of life	Low	Improvements in study arms reporting varied measures of quality of life

GnRH = gonadotropin-releasing hormone; HIFU = high intensity focused ultrasound; LNG-IUD = levonorgestrel intrauterine device; NA = not applicable, not measured; SOE = strength of evidence

Comparative Effectiveness

Studies comparing different categories of intervention were rare. Most were single studies of the specific comparison investigated. Two studies compared UAE to myomectomy; 3 studies compared UAE to hysterectomy; and four studies compared different drugs, but because of quality and size of these single comparison studies, evidence is insufficient to guide choices between medications and procedures.

Subsequent Intervention

For each of these interventions (uterine artery embolization, myomectomy, and medical management) and the subsequent treatment possibilities, the meta-analysis estimates 44 percent of women in their 30s received subsequent intervention after UAE. The findings are intriguing but inadequate to guide care about the sequence of treatments that may have the best outcomes

because the overall quality of trials is limited and few women were followed long enough to identify treatment patterns. It is likely that much fewer than half of women will choose subsequent treatment in the near-term after an initial intervention. However, we can also speculate that the priorities which led women to participate in the initial trials reflected the intensity of treatments they were most interested in pursuing so it is not surprising surgeries were most followed by other procedures promptly (within 6 months) by those were not satisfied with initial results while those who enrolled in medication trials were less likely to pursue more aggressive options. Because of the limited roster of studies that followed women for 6, 12, or 24 months, this analysis does not substitute for study of treatment trajectories in which all initial treatments can be followed by all possible combinations of next treatments.

KQ2. Influence of Patient/Fibroid Characteristics on Effectiveness

Overall, data are inadequate to assist women in choosing one intervention over another based on her individual characteristics or the characteristics of her fibroids. Too few studies were adequately powered to determine within arms if one subgroup or another has superior outcomes within a treatment. Such information is required as a first step towards using individual characteristics to inform treatment choice.

KQ3. Risk of Leiomyosarcoma When Mass Thought To Be a Fibroid

Overall, from 160 studies, we conclude that in every 10,000 who have surgery for fibroids, between 0 to 13 women, may be found to have a leiomyosarcoma. This is within the range of the point estimates that others have produced. [10,24,25] Our analysis includes a larger sample size, more prospective studies, and more recently published data. One advantage to prospective studies is that they employ standardized approaches for inclusion and data collection and apply quality controls for histopathology. Participants in prospective studies were somewhat younger than those in retrospective studies (mean age 38.5 versus 43.4 years, respectively). Among prospective studies 57 percent focused on myomectomy findings; 36 percent on hysterectomy, and 6 percent included both types of surgery. Among retrospective studies 32 percent focused on myomectomy; 49 percent hysterectomy, and 19 percent both. Because leiomyosarcoma risk increases with age [25,26], differences in age distribution and potentially in surgery type would be expected to result in a lower prevalence estimated by our models.

The literature investing the prevalence of leiomyosarcoma in presumed fibroids has grown rapidly and this continues to inform risk estimates. Unfortunately, the published literature does not contain enough detail to stratify risks by age, menopausal status, or surgical approach. Similarly, the literature lacks information on individual or fibroid characteristics that could discriminate those at high risk from those with lower risk. Thus the available data produces wide confidence intervals for broad groups of women when estimating rare outcomes. See “Limitations of the Evidence Base” in the full report for further discussion.

KQ4. Factors Affecting Leiomyosarcoma Survival

At this time, definitive data that power morcellation is associated with poor long-term outcomes in the presence of unsuspected leiomyosarcoma is limited. In our meta-analysis of 24 studies that provide data about use of morcellation in three categories: none, scalpel, or power; we find that power morcellation may be a determinant of death from leiomyosarcoma. Some

recent estimates in the literature find otherwise. As noted above, we cannot discern from the available literature any patient or fibroid characteristics that predict survival.

Uncertainty in estimates of prevalence and evolving data about methods for tissue extraction and their consequences call for explorations of ethical and shared decision making topics to offer coherent care recommendations that support patients' and surgeons' autonomy.

Applicability

Overall, our findings are widely applicable to the general population of women seeking treatment for uterine fibroids. For KQs 1 and 2 we set inclusion criteria for this review to women of any age with uterine fibroids with patient outcome data beyond intermediate outcomes only. We excluded studies in pregnant women, and restricted our synthesis to treatments currently available in the United States. Over 40 percent of the studies were conducted in European countries and another 27 percent were conducted in the United States or Canada. Although the outcomes collected may differ by country and by healthcare setting, the interventions were selected to be comparable so that the results reported in this review are expected to apply to women with fibroids in the United States.

Evaluation of expectant management was not an explicit aim of any trial. Sixteen studies with placebo arms or no treatment arms that included 514 women served as a surrogate. This population is not an ideal substitute as participants in the trials presumably hoped to receive active treatment and may report their status differently than women willing to be randomized to watchful waiting. This could restrict applicability but since the majority of studies included a plausible level of participant masking, they would be unlikely to know if they were on an active agent.

Medical management of fibroids was assessed in over 2,800 predominately premenopausal women from 43 studies (15 industry-sponsored and 11 conducted in the United States). Procedures, including UAE, HIFU, and radiofrequency fibroid ablation were evaluated in 28 studies including almost 2,000 women. Surgical studies evaluated hysterectomy, myomectomy, and endometrial ablation in over 3,000 women. Although none of the surgical studies were conducted in the United States, the surgical procedures are comparable to those widely available to women in the United States.

Data in these studies were inadequate to assess applicability based on patient characteristics (age, race/ethnicity, pregnancy intention, or menopausal status) or fibroid characteristics (size, position, and number) that could influence effectiveness outcomes.

While there are limitations in the literature as discussed below, the information that is available from these trials is relevant to contemporary practice. In summary, this review is generally applicable to women in the United States seeking one of the many treatment choices currently available for fibroids.

For KQ3 and 4: Data can only be systematically obtained from published research or publically available research. Those represented in the literature may differ from the universe of women having surgery for fibroids in the US. The literature about risk and outcomes of leiomyosarcoma does not separate cases well by type or surgery or menopausal status. Prospective studies which include a greater representation of myomectomy patients may be more applicable for discussing risk among younger women.

Limitations of the Systematic Review Process

Methodologic choices constrain the findings of this report. We chose to focus on publications in the English-language literature, to restrict to randomized clinical trials for the comparative effectiveness synthesis (KQs 1 and 2), and to review only those studies that included at least one intervention that is available in the United States. Similar reviews have documented in the past that language restrictions do not increase risk of omitting high quality trials. This is especially true for the topic of fibroids because the fibroid research community is small. Our technical expert panel and authors are familiar with prior and ongoing work and helped assure relevant studies have not been overlooked. Restricting to trials allowed us to sharply focus on proof of effectiveness. Because all individuals whose outcomes were assessed in these studies were randomly assigned to the intervention received, provider and patient biases in intervention choice are reduced and risk of confounding, difficult to fully assess or adjust for in cohort studies, is minimized. Random assignment to intervention arm in trials reduces bias and allows aggregation and summary of the findings by study arm, as presented in this report.

Restricting the review to randomized controlled trials limited ability to detect the full range of harms since studies were generally not designed or powered to evaluate harms, and many had a short duration of follow up.

Our analysis of subsequent intervention after a first intervention could be biased by the types of studies that reported this data and by differences in the willingness of women to be randomized to different types of intervention.

For meta-estimates related to leiomyosarcoma risk, available evidence based on pathology specimens for estimating presence of leiomyosarcoma in a mass believed to be a fibroid is accruing rapidly and will likely continue after the production of this report. Our estimates and that of Pritts and colleagues[10] find that the estimates are lower in data from more contemporary prospective cohorts of women having surgery compared to retrospectively collected data. This may be explained by inaccuracies in retrospectively collected data even when pathology specimen banks are used to index a full population of surgical patients. On the other hand, it is important to note that prospectively collected data may enroll younger patients and a larger proportion undergoing myomectomies. As a rule, data for estimating rare events is volatile, which is demonstrated by the changes in prevalence estimates when we exclude studies that included hysteroscopy.

The risk of inaccuracy is especially true in understanding and estimating the degree to which morcellation method influences survival when a woman is found to have a leiomyosarcoma that was believed to be a fibroid. More nuanced data is needed to be able to include exact ages and uniform staging data at an individual level and to account for secular trends in aggressiveness of treatment and range of modalities used in treating leiomyosarcomas.

Focusing on interventions available in the United States, and excluding those that cannot be obtained here could neglect a promising intervention but does restrict the report to data that is of immediate value to women and their care providers who must make decisions among available options. We have included some interventions that are not widely available in the United States such as HIFU without MRI guidance. For any woman, her geographic location, local provider training or insurance coverage may restrict the availability of some options.

Limitations of the Evidence Base

While the literature about the effectiveness of uterine fibroids treatment has grown since the last evidence report in 2007, significant gaps in knowledge persist. The 97 studies unique intervention arms enrolled 9,179 women, an average of 98 women per study with a range of 16 to 451. Individual studies were often small and powered to address a single continuous outcome such as hematocrit or score on a quality of life scale.

Our analytic framework was created by expert consensus to reflect the outcomes that matter to women when making decisions. The available literature has substantial gaps in collecting this information as indicated by the number of studies that addressed each of our eight primary outcomes. Fibroid characteristics and symptom status were the most frequently reported outcomes, addressed in 65 percent and 59 percent of the studies respectively, though assessment techniques and measures varied. Other key outcomes including quality of life and satisfaction with outcomes (39%), sexual function (12%), and future reproductive outcomes (8%) were addressed in only a handful of studies. Detailed descriptions of subsequent treatment were reported in 29 percent of the included trials.

Little continuity exists in approaches to measuring outcomes and use of unvalidated measures is common. When data are combined across studies for a particular intervention, risk of serious rare harms cannot be fully assessed. In many instances ability to synthesize evidence across studies is absent, weak because of biased collection methods (e.g., assessors not blind to intervention), or difficult to aggregate across studies because of use of different metrics.

Paucity of "similar" articles (populations, settings, patient characteristics, and outcomes measured) also precludes efforts to pool data about characteristics of the study populations as they contribute to predicting outcomes. No studies were appropriately powered to understand whether specific groups of patients, such as those closer to menopause or with a specific symptom pattern have outcomes that are modified by those characteristics. Lastly, the lack of direct comparisons limits the information this can provide to help a woman or her care provider make an evidence-driven selection among choices in the context of the patient's priorities.

Limitations about leiomyosarcoma data: Because cases are rare and detailed age data for non-cases is lacking, only rough models of risk by age can be produced. [25] We need more prospective studies that include nuanced data such as patient and fibroid characteristics, patient age, menopausal status and surgical approach, hormonal exposures and genetic factors so that we can give more accurate estimates to patients.

Future Research

Key components of study design, analysis, and reporting remain the leading weaknesses of the literature for each topic addressed in this review. Overall, the literature identified is limited by the following gaps and problems discussed in detail in the full report. Future research should aim to remediate these concerns:

- Ability to assess internal and external validity
- Study populations of adequate size for assessing key outcomes
- Use of standard nomenclature and validated measures
- Analysis methods matched to the outcomes of interest
- Direct comparisons of treatment options
- Formal development of patient centered outcome measures for fibroid care

A range of content priorities also need to be addressed. These include the burden of disease and societal costs from loss of ability to function well in the usual family or occupational roles. Transitions associated with appearance of uterine fibroids, growth patterns, and influences on growth (e.g., concurrent medical conditions like diabetes, use of medications like hormonal contraception, influence of lactation and duration) are high-priority topics, as are predictors of symptom development and resolution. Variation in care-seeking behaviors, differences in severity at presentation, and health and quality of life outcomes are other matters that investigators should attempt to address. Likewise reproductive outcomes such as fertility and risk of future pregnancy complications are very important to women as they make decisions about fibroid treatment and the current literature is insufficient to guide choices. In addition, the current literature cannot address from trials whether disparities between white and black women in the age at appearance of fibroids and in the number and size of fibroids also foreshadows different treatment outcomes and durability of results.

In current practice, women without symptoms may forego intervention because of the general belief that care should be aimed at improving symptoms or addressing a specific clinical concern such as difficulty conceiving or recurrent pregnancy loss. Although foregoing intervention can be wise in the absence of data that the intervention will prevent future difficulties, research on the natural history of fibroids and likelihood of developing symptoms or other health effects is limited. No data is available to indicate whether use of therapeutics short of surgery might forestall or prevent future changes in fibroids or appearance of symptoms. The concept of preventive strategies is appealing. However, as long as the etiology of fibroids remains unclear, preliminary trials are not assessing lifestyle interventions, and the prospect for dietary management, nutritional supplementation, exercise, hormonal management, or other prevention trials is slim.

The clinical research agenda will likely depend on new translational research and large-scale epidemiology studies. Much remains to be learned that will require large-scale prospective observational studies of sufficient size and rigor to support time-to-event analysis of outcomes, such as that being conducted in the COMPARE Uterine Fibroids 10,000 woman registry supported by AHRQ and PCORI. These studies may afford greater power to examine effect modification and to determine trajectories of care over a reproductive lifespan for women with fibroids. Additionally, such studies will be better able to estimate both common and rare harms, including the risk of occult leiomyosarcoma. Research effort must be focused on documenting first the course and consequences of uterine fibroids using optimal imaging strategies. We must then deploy more robust statistical techniques across aggregated data in order to understand the modifiers of that course and of the effectiveness of treatment, so that we can offer women an accurate account of the likely outcome of intervention choices based on their individual status.

Conclusions

A range of interventions are effective for reducing fibroid size and improving symptoms. Some medications and procedures also improve quality of life. Direct comparisons among treatment options remain sparse. No studies have explicitly evaluated expectant management, which is a crucial missing piece of the evidence about whether symptoms relapse and remit. The literature must come to include uniformly longer followup to determine whether women's objectives for treatment were met by the intervention received. Few women have only one concern driving their desire for intervention, yet remarkably many trials are directed at evaluating a single outcome. Likewise concerns about harms, such as drug side effects, serious

surgical complications, and risk of undetected leiomyosarcoma, need to exploit larger and more nuanced data to be able to better determine what individual and fibroid characteristics best predict adverse events to better inform personalized care.

Across management options, we must note that lack of evidence is not equivalent to evidence of no benefit or of harm. Evidence to inform probability of risk or benefit based on patient characteristics is lacking. Uncontrolled studies are not a substitute since they are notably biased for overestimating the degree of benefit subsequently reported in randomized trials. Indeed, not uncommonly, trials negate the findings of what in this case is largely retrospective and case series research. The current state of the literature does not permit definitive conclusions about comparative benefit, harm, or relative costs to achieve similar results across the range of available options and lacks strength of evidence for interventions such as use of continuous birth control pill regimens, progesterone containing IUDs, and endometrial ablation that are often used in routine clinical practice.

Given how common and concerning fibroids can be to women and their care providers, a redoubled emphasis on promoting high-quality fibroid research in the United States is imperative. Women need better information to guide their choices.

References

1. Baird DD, Dunson DB, Hill MC, Cousins D, Schectman JM. High cumulative incidence of uterine leiomyoma in black and white women: ultrasound evidence. American journal of obstetrics and gynecology. 2003;188(1):100-107. PMID: 12548202.
2. Wise LA, Palmer JR, Stewart EA, Rosenberg L. Age-specific incidence rates for self-reported uterine leiomyomata in the Black Women's Health Study. Obstetrics and gynecology. 2005;105(3):563-568. PMID: 15738025. doi:10.1097/01.AOG.0000154161.03418.e3.
3. Laughlin SK, Baird DD, Savitz DA, Herring AH, Hartmann KE. Prevalence of uterine leiomyomas in the first trimester of pregnancy: an ultrasound-screening study. Obstetrics and gynecology. 2009;113(3):630-635. PMID: 19300327. doi:10.1097/AOG.0b013e318197bbaf.
4. Monte LM ER. Fertility of Women in the United States: June 2012. Current Population Reports. 2014:P20-575.
5. Myers ER, Barber MD, Gustilo-Ashby T, Couchman G, Matchar DB, McCrory DC. Management of uterine leiomyomata: what do we really know? Obstetrics and gynecology. 2002;100(1):8-17. PMID: 12100798.
6. Wegienka G, Baird DD, Hertz-Picciotto I, et al. Self-reported heavy bleeding associated with uterine leiomyomata. Obstetrics and gynecology. 2003;101(3):431-437. PMID: 12636944.
7. Templeman C, Marshall SF, Clarke CA, et al. Risk factors for surgically removed fibroids in a large cohort of teachers. Fertility and sterility. 2009;92(4):1436-1446. PMID: 19019355. doi:10.1016/j.fertnstert.2008.08.074.
8. Cardozo ER, Clark AD, Banks NK, Henne MB, Stegmann BJ, Segars JH. The estimated annual cost of uterine leiomyomata in the United States. American journal of obstetrics and gynecology. 2012;206(3):211.e211-219. PMID: 22244472. doi:10.1016/j.ajog.2011.12.002.
9. Hartmann KE, Birnbaum H, Ben-Hamadi R, et al. Annual costs associated with diagnosis of uterine leiomyomata. Obstetrics and gynecology. 2006;108(4):930-937. PMID: 17012456. doi:10.1097/01.aog.0000234651.41000.58.
10. Pritts EA, Vanness DJ, Berek JS, et al. The prevalence of occult leiomyosarcoma at surgery for presumed uterine fibroids: a meta-analysis. Gynecological surgery. 2015;12(3):165-177. PMID: 26283890. doi:10.1007/s10397-015-0894-4.

11. Matchar DB, Myers ER, Barber MW, et al. Management of uterine fibroids. Evidence report/technology assessment (Summary). 2001(34):1-6. PMID: 11236283.

12. Viswanathan M, Hartmann K, McKoy N, et al. Management of uterine fibroids: an update of the evidence. Evidence report/technology assessment. 2007(154):1-122. PMID: 18288885.

13. Shlansky-Goldberg RD, Rosen MA, Mondschein JI, Stavropoulos SW, Trerotola SO, Diaz-Cartelle J. Comparison of polyvinyl alcohol microspheres and tris-acryl gelatin microspheres for uterine fibroid embolization: results of a single-center randomized study. Journal of vascular and interventional radiology : JVIR. 2014;25(6):823-832. PMID: 24788209. doi:10.1016/j.jvir.2014.03.009.

14. Jun F, Yamin L, Xinli X, et al. Uterine artery embolization versus surgery for symptomatic uterine fibroids: a randomized controlled trial and a meta-analysis of the literature. Archives of gynecology and obstetrics. 2012;285(5):1407-1413. PMID: 22048783. doi:10.1007/s00404-011-2065-9.

15. Yu SC, Lok I, Ho SS, Tong MM, Hui JW. Comparison of clinical outcomes of tris-acryl microspheres versus polyvinyl alcohol microspheres for uterine artery embolization for leiomyomas: results of a randomized trial. Journal of vascular and interventional radiology : JVIR. 2011;22(9):1229-1235. PMID: 21802314. doi:10.1016/j.jvir.2011.05.011.

16. Manyonda IT, Bratby M, Horst JS, Banu N, Gorti M, Belli AM. Uterine artery embolization versus myomectomy: impact on quality of life--results of the FUME (Fibroids of the Uterus: Myomectomy versus Embolization) Trial. Cardiovascular and interventional radiology. 2012;35(3):530-536. PMID: 21773858. doi:10.1007/s00270-011-0228-5.

17. Moss JG, Cooper KG, Khaund A, et al. Randomised comparison of uterine artery embolisation (UAE) with surgical treatment in patients with symptomatic uterine fibroids (REST trial): 5-year results. BJOG : an international journal of obstetrics and gynaecology. 2011;118(8):936-944. PMID: 21481151. doi:10.1111/j.1471-0528.2011.02952.x.

18. Bilhim T, Pisco JM, Duarte M, Oliveira AG. Polyvinyl alcohol particle size for uterine artery embolization: a prospective randomized study of initial use of 350-500 mum particles versus initial use of 500-700 mum particles. Journal of vascular and interventional radiology : JVIR. 2011;22(1):21-27. PMID: 21106390. doi:10.1016/j.jvir.2010.09.018.

19. van der Kooij SM, Hehenkamp WJ, Volkers NA, Birnie E, Ankum WM, Reekers JA. Uterine artery embolization versus hysterectomy in the treatment of symptomatic uterine fibroids: 5-year outcome from the randomized EMMY trial. American journal of obstetrics and gynecology. 2010;203(2):105.e101-113. PMID: 20579960. doi:10.1016/j.ajog.2010.01.049.

20. Ruuskanen A, Hippelainen M, Sipola P, Manninen H. Uterine artery embolisation versus hysterectomy for leiomyomas: primary and 2-year follow-up results of a randomised prospective clinical trial. European radiology. 2010;20(10):2524-2532. PMID: 20526776. doi:10.1007/s00330-010-1829-0.

21. Mara M, Maskova J, Fucikova Z, Kuzel D, Belsan T, Sosna O. Midterm clinical and first reproductive results of a randomized controlled trial comparing uterine fibroid embolization and myomectomy. Cardiovascular and interventional radiology. 2008;31(1):73-85. PMID: 17943348. doi:10.1007/s00270-007-9195-2.

22. Pinto I, Chimeno P, Romo A, et al. Uterine fibroids: uterine artery embolization versus abdominal hysterectomy for treatment--a prospective, randomized, and controlled clinical trial. Radiology. 2003;226(2):425-431. PMID: 12563136. doi:10.1148/radiol.2262011716.

23. Spies JB, Allison S, Flick P, et al. Spherical polyvinyl alcohol versus tris-acryl gelatin microspheres for uterine artery embolization for leiomyomas: results of a limited randomized comparative study. Journal of vascular and interventional radiology : JVIR. 2005;16(11):1431-1437. PMID: 16319148. doi:10.1097/01.rvi.0000179793.69590.1a.

24. Food and Drug Administration. Quantitative Assessment of the Prevalence of Unsuspected Uterine Sarcoma in Women Undergoing Treatment of Uterine Fibroids: Summary and Key Findings. 2014.

25. Brohl AS, Li L, Andikyan V, et al. Age-Stratified Risk of Unexpected Uterine Sarcoma Following Surgery for Presumed Benign Leiomyoma. The oncologist. 2015. PMID: 25765878. doi:10.1634/theoncologist.2014-0361.

26. Koivisto-Korander R, Martinsen JI, Weiderpass E, Leminen A, Pukkala E. Incidence of uterine leiomyosarcoma and endometrial stromal sarcoma in Nordic countries: results from NORDCAN and NOCCA databases. Maturitas. 2012;72(1):56-60. PMID: 22377186. doi:10.1016/j.maturitas.2012.01.021.

Introduction

Condition

Uterine fibroids (i.e., leiomyomata) are common benign smooth muscle tumors of the uterus. The etiology is not well understood, and a variety of factors including race/ethnicity, parity, and age at menarche have been examined. By age 49, more than 70 percent of white women and 84 percent of African American women have fibroids documented by imaging or surgical records.[1] In the United States, an estimated 26 million women between the ages of 15 and 50 have uterine fibroids. [1-3,1-3,5,6,27,28] Fibroids may be asymptomatic, or can produce health effects that include profound bleeding and anemia, pelvic pressure or pain, urinary frequency, abnormal bowel function, pain with intercourse, as well as effects on fertility and pregnancy outcomes.[29] More than 15 million US women will experience associated symptoms or health concerns.[5,6] A disproportionate number of black women have symptoms in part due to earlier age at onset of fibroids with larger and more numerous tumors.[1-3,27,28,29] Black women are also more likely to have surgical interventions for fibroids.[7]

Symptoms from fibroids can result in considerable personal and societal costs including diminished quality of life, disruption of usual activities and roles, lost work time, and substantial healthcare expenditures. Across types of interventions, direct annual healthcare costs in the United States are projected to exceed $9.1 billion. Lost wages, productivity, and short-term disability are estimated to total another $5 to $17 billion annually, with roughly $4,624 in costs per woman in the first year of diagnosis.[8,9]

Management of Uterine Fibroids

Asymptomatic fibroids do not require intervention. Discussion of management options for *symptomatic* fibroids is among the most frequent conversations in gynecology and primary care and is the most common reason for gynecologic surgery.[30,31] These discussions are shaped by future reproductive goals.[32,33] Treatment options differ in fundamental aspects such as cost, invasiveness, recovery time, risks, likelihood of long-term resolution of symptoms, need for future care for fibroids, and influence on future childbearing. Thus synthesis of available evidence is crucial to assist women and their care providers in making well-informed and personalized decisions.

This report is organized from least invasive to more invasive treatment options: expectant management, then medical treatment, and then outpatient procedures and major surgeries.

Medications

In any given year, a greater proportion of women with symptomatic fibroids receive medical therapy than surgery.[9] Though no medications have been specifically cleared by the U.S. Food and Drug Administration (FDA) for fibroid treatment, several medications are used off-label for fibroid symptoms. Those commonly used in clinical practice include birth control pills, stool softeners, and nonsteroidal anti-inflammatory agents. Others are characterized as gonadotropin-releasing hormone releasing hormone (GnRH) agonists, progesterone receptor agents, estrogen receptor agents, and antifibrinolytics. Because the mechanism of action is the progesterone it

contains, we include the levonorgestrel (LNG) intrauterine device (IUD) as a progesterone medication in this review.

GnRH agonists down-regulate ovarian production of estrogen and progesterone and decrease stimulation of hormone receptors. This "medical menopause" decreases fibroid growth, promotes uterine involution, and reliably produces amenorrhea. This improves bulk symptoms, bleeding and the anemia associated with fibroids. Estrogenic add-back therapy may be used with a GnRH agonist to offset unwanted side effects such as hot flashes, vaginal dryness, and decrease in bone density. GnRH agonists include the injectable leuprolide , goserelin (an implant) and triptorelin.

Progesterone receptor agents modulate progesterone activity. *Mifepristone* competitively binds to the intracellular progesterone receptor, blocking the effects of progesterone and reducing fibroid size. Two things may limit its use: Mifepristone exhibits antiglucocorticoid activity, and only physicians with a prescriber's agreement with the manufacturer can obtain the drug in the United States.[34] *Ulipristal acetate* is a selective progesterone receptor modulator that is structurally similar to mifepristone, but has less antiglucocorticoid activity. [35-37] It has been FDA cleared since 2010 for emergency contraception. Ulipristal is cleared in Europe for long term medical management and preoperative therapy for fibroids. *Levonorgestrel-IUD* releases 20 µgr of levonorgestrel daily. It reduces bleeding by inhibiting endometrial proliferation.

Estrogen receptor agents: Selective estrogen receptor modulators bind to estrogen receptors to mimic or block estrogen activity, and have differential effects across tissue types (e.g., bone, brain, liver). *Tamoxifen* was introduced to block estrogen action in the treatment of breast cancer, but has estrogen –like effects on the uterus. *Raloxifene* has estrogen-like effects on bone, but anti-estrogen effects in the breast and uterus. It is used to treat osteoporosis and prevent breast cancer, and reduce fibroid size.

Combined hormonal replacement treatment (HRT): The transdermal estradiol patch plus a progestin can be used to reduce menopausal symptoms in women with fibroids. Combined birth control pills can be used to reduce bleeding and pain in pre-menopausal women.

Antifibrinolytics: *Tranexamic acid* improves blood clotting and is used to reduce heavy menstrual bleeding and to minimize postoperative blood loss.

Procedures

We considered those interventions that can typically be conducted in an office or as same-day surgery as procedures. These include uterine artery embolization or occlusion, high intensity focused ultrasound (HIFU) and radiofrequency fibroid ablation.

Uterine artery occlusion and embolization are techniques to interrupt the blood supply to uterine fibroids, which causes infarction and cell death within the fibroid, thus reducing fibroid size and symptoms. **Uterine artery embolization (UAE)** involves placement of a catheter through a blood vessel in the groin, using techniques similar to cardiac catheterization. Selected arteries are then blocked by introducing an embolization agent to close off the blood flow to the fibroid(s). UAE is an interventional radiology procedure, usually performed as an outpatient in an imaging suite. This procedure is an option for women who wish to avoid surgery, are poor candidates for surgery, or who wish to retain their uterus. It is not currently recommended for women who wish to have future pregnancies

Uterine artery occlusion is an older, less selective technique to directly occlude the main uterine vessels with sutures or coagulation at the time of open or laparoscopic surgery. Generally, occlusion is more invasive (requiring general anesthesia and an operating suite) and

less selective than embolization. In one study, the authors describe "occlusion" as the use of vascular coils placed via uterine artery catheterization, which does not require surgery.[38]

High intensity focused ultrasound (HIFU), guided by ultrasound or MRI, directs a focused ultrasound beam to the fibroid. This induces thermal destruction of the target tissue. When MRI is used, the procedure is conducted in an MRI suite using a system that integrates real-time MRI and thermometry with an ultrasound unit specially designed to focus ultrasound waves. In 2004, the FDA approved one system (Magnetic Resonance Guided Focused Ultrasound (MRgFUS) for ablation of uterine fibroid tissue in pre- or perimenopausal women with symptomatic uterine fibroids with a uterine size of less than 24 weeks.

Radiofrequency ablation uses a laparoscopic approach to map fibroids with ultrasound, which are then ablated with an instrument that delivers the radiofrequency energy into the fibroid. One system is FDA cleared for use in the United States.

Surgery

We classify more invasive interventions that are typically performed in an operating room or require at least a brief hospital stay as surgical approaches. These include endometrial ablation, myomectomy, and hysterectomy.

Endometrial ablation is a procedure that destroys (ablates) the uterine lining (endometrium) using one of these techniques: laser, radiofrequency, thermal balloon, electricity (cautery, roller-ball), freezing, or microwave. The goal of endometrial ablation is to reduce or eliminate uterine bleeding. Pregnancy is not recommended after endometrial ablation, and tubal occlusion may be performed in conjunction with the procedure.

A **myomectomy** excises the fibroid(s) and repairs any defect in the uterine wall, while preserving the uterus. For this reason, myomectomy is an option for women who desire future pregnancies or who wish to retain their uterus. After myomectomy, fibroids could recur, which could lead to subsequent intervention(s).[39] The surgical approach may be through an open abdominal incision (laparotomy) or a smaller open incision (minilaparotomy). A laparoscope can be used to remove the fibroid(s) through small incisions in the abdominal wall (laparoscopic) or a hysteroscope can be used to reach the fibroid(s) through the cervix (hysteroscopic). Myomectomy can be completed with or without a morcellator. Myomectomy can also be combined with endometrial ablation or uterine artery embolization.

Hysterectomy- the complete surgical removal of the uterus- is a definitive treatment for symptomatic fibroids in women who have completed childbearing. Hysterectomy does not require removal of the fallopian tubes and ovaries. Surgery that removes the entire uterus plus fallopian tubes and ovaries is properly called "total hysterectomy with bilateral salpingo-oophorectomy." Surgery that leaves the uterine cervix intact is called supracervical hysterectomy. The surgical approach may be through an open abdominal incision (laparotomy), though the vagina (vaginal) or with the use of a laparoscope (laparoscopic). The open incision may be reduced in size (minilaparotomy). The laparoscopic procedure may be exclusive (total laparoscopic hysterectomy), or may include a vaginal procedure (laparoscopic assisted vaginal hysterectomy). Hysterectomy procedures can be completed with or without a morcellator.

Additional Management Concerns

Although it is not a separate procedure, it is important to discuss **morcellator** use for fibroid removal. Morcellation reduces the fibroid tissue to smaller fragments that can then be removed through smaller incisions. For several decades, power morcellators have been used to

facilitate hysterectomy and myomectomy via less invasive laparoscopic approaches. Fragments can be removed directly through a port or using a flexible bag system that can then be removed through a port. One technique creates the fragments inside the bag system before removal. Several morcellation devices have FDA approval; all currently are included in a 2014 FDA safety communication that advises **against** using power morcellators "in the majority of women undergoing myomectomy or hysterectomy for treatment of fibroids" due to the risk of disseminating cancer in women with occult leiomyosarcoma. The FDA estimated the risk of occult leiomyosarcoma to be 20 (range: 11 to 38) per 10,000 women undergoing surgery for presumed fibroids.[40,24] As a result of this advisory, women and surgeons are choosing more invasive treatments for fibroid removal, with the attendant increases in costs, risk of harm, and recovery time.[41,42]

Leiomyosarcomas are rare: an average of 1,600 new cases occur in the United States each year.[43] However, they have poor outcomes with an average 5-year survival of 36 percent if cancer has spread to the pelvis and not isolated to the uterus. The primary means of dissemination of leiomyosarcoma is believed to be hematogenous. More than half of women with leiomyosarcomas develop distant metastasis before local recurrence in the pelvis, and most progress to higher stage disease regardless of order of spread.[44,45]

If the leiomyosarcoma is disrupted during removal, both visible and microscopic particles may be spilled. If spillage worsens stage and survival, then removing a leiomyosarcoma by power morcellation would have a poorer outcome than using scalpel morcellation, and both of these would be inferior to removing the uterus and tumor intact.

Scope and Key Questions

Scope

To best inform clinical decisions about care we focused on evidence from randomized trials that assessed effectiveness of currently used interventions for women of any age with fibroids. We also sought to identify factors that might modify likelihood of favorable results or harms from treatments. We included studies evaluating medications, procedures, and surgeries for the management of uterine fibroids. For expectant management, we summarize data from women who were followed within trials without active intervention. In order to inform women and providers, accurate estimates are needed regarding the prevalence of leiomyosarcoma and risks of dissemination after morcellation.

This review does not cover preoperative adjunctive treatments such as GnRH agonists or intraoperative techniques, like use of cell savers that have established effectiveness as preoperative or adjunctive interventions to minimize blood loss or otherwise improve short-term operative outcomes. We also do not review trials comparing operative devices (such laparoscopic instruments for ligation versus cautery of the uterine vessels) if the trial included only intermediate outcomes. Except in the context of factors assessed at the time of imaging that may help identify risk of dissemination of leiomyosarcoma, we do not address diagnostic accuracy of imaging. We did however seek to examine conventional fibroid characteristics as assessed by imaging and how they relate to achieving desired outcomes.

Key Questions

Key Question 1. What is the comparative effectiveness (benefits and harms) of treatments for uterine fibroids, including comparisons among these interventions?

Key Question 2. Does treatment effectiveness differ by patient or fibroid characteristics (e.g., age; race/ethnicity; symptoms; menopausal status; imaging characteristics; vascular supply to fibroids; or number, size, type, location, or total volume of fibroids)?

Key Question 3. What is the risk of encountering a leiomyosarcoma for masses believed to be uterine fibroids at the time of myomectomy or hysterectomy?

Key Question 4. Does survival after leiomyosarcoma differ by patient or fibroid characteristics (e.g., age; race/ethnicity; symptoms; menopausal status; imaging characteristics; vascular supply to fibroids; or number, size, type, location, or total volume of fibroids) or by surgical approach to fibroid morcellation?

Analytic Framework

The analytic framework provides context for our Key Questions (KQs) and illustrates the population, intermediate outcomes, final health outcomes, and interest in a specific set of harms that guided the literature search and synthesis of evidence (Figure 1).

Figure 1. Analytic framework

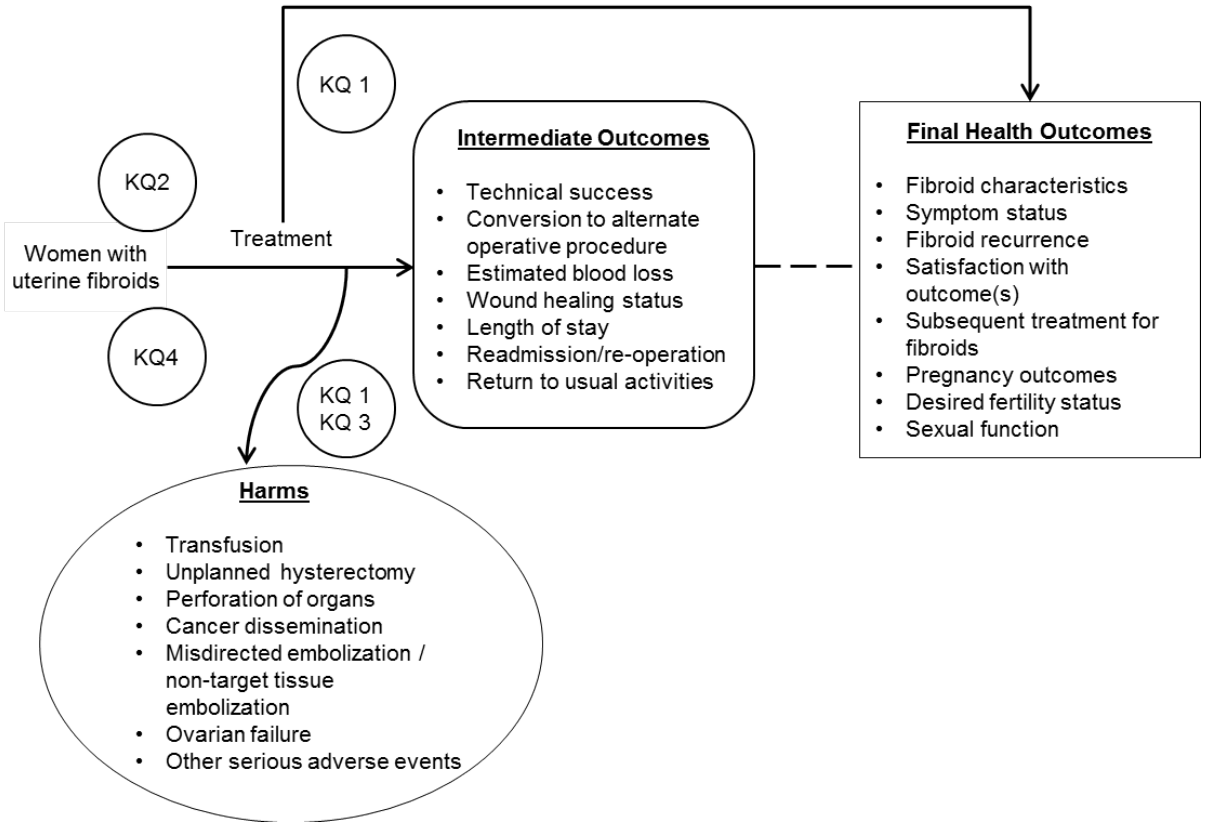

KQ = Key Question

Organization of This Report

The overall structure of the report arranges findings in order to address the most common questions of women and care providers, as follows.

1. What are the options for managing fibroids and what are typical outcomes? Meaning, if a woman chooses a type of intervention, how is that choice likely to turn out? Will fibroids change, will symptoms improve, will quality of life improve, and will she be satisfied with this choice? These questions are answered by arranging all the outcome data about a particular drug, procedure, or surgery together and showing the aggregate expectations for available outcomes such as change in fibroids or change in bleeding. When multiple studies included an outcome we used tables to summarize this data. When few studies addressed the outcome (such as future pregnancy outcomes, or harms), we address these outcomes in text. (KQ1a)

2. If a woman chooses an option, how likely is it that she will need additional intervention in the near future? We modeled subsequent intervention by category of initial intervention to address this question. We note that women choosing to participate in randomized controlled trials of different types of interventions may differ in key ways that cannot be defined from the literature (KQ1b).

3. What information is available that directly compares one type of intervention compared to other types of interventions? This question is best answered by review of truly comparative studies, for instance those that examine medication versus procedure, or procedure versus a particular surgery. If study data speak only to the question of choosing a dose, choosing a drug within a category, or choosing a surgical approach (e.g., laparoscopic vs. open) we included those studies in our summary of results for each category of intervention (KQ1c), as it primarily informs the first question above (i.e., effects from a given type of drug or surgery). In this section at the end of KQ1 we address genuine comparisons of different management approaches (Comparative Effectiveness Studies) because this is what women and care providers are considering. They are weighing whether one type of intervention is better on average than another choice, or if equivalent, do patient values and priorities make it easier to choose knowing they are equivalent.

4. Is there anything about a woman or her fibroids that can help determine what is likely to work well? We attempted to identify characteristics in the literature that may address this question (KQ2).

5. If a woman has a mass thought to be a fibroid, what is the likelihood that she has a leiomyosarcoma? Are there factors which would influence survival of a woman with leiomyosarcoma? We then address the risk of leiomyosarcoma (KQ3) and then present information about individual and fibroid characteristics and surgical approach that may modify leiomyosarcoma survival (KQ4).

Methods

In this chapter, we document the procedures that the Vanderbilt Evidence-based Practice Center (EPC) used to develop this comparative effectiveness report. We first describe the development of the topic and scope of review, including formulation of Key Questions (KQs). We present our strategy for identifying relevant literature, our inclusion and exclusion criteria, and the process we used to abstract relevant information and synthesize evidence. We also discuss our criteria for summarizing the risk of bias for individual studies and the overall strength of the evidence for each intervention category with respect to selected high-priority outcomes. Detailed records about EPC methods are available at the Agency for Healthcare Research and Quality (AHRQ) Effective Health Care Program Web site (http://www.effectivehealthcare.ahrq.gov) and key documents related to conduct of this report are included in the appendices.

Topic Refinement and Review Protocol

The EPC engaged in a public process to refine the original topic submission, draft the KQs, and develop a systematic review protocol. A panel of 10 Key Informants provided input via teleconferences and individual communication. Key Informants represented the fields of gynecology, patient advocacy, and regulatory and industry stakeholders. The draft KQs were posted on the Agency for Healthcare Research and Quality Effective Health Care Web site for public review and critique for three weeks. Comments did not necessitate any significant changes to the KQs, review scope, or inclusion criteria. The EPC then recruited a panel of nine technical experts to provide high-level content and methodologic expertise throughout the review. The technical expert panel members represented the fields of gynecology, interventional radiology, reproductive endocrinology, and epidemiology. The final protocol was registered with PROSPERO (registration CRD42015025929) and posted on the Effective Health Care Web site (http://www.effectivehealthcare.ahrq.gov).

Finding and Selecting Studies

Published Literature

We searched MEDLINE® via PubMed® to identify publications (Table 1 and Table 2). The full search strategy is presented in Appendix A. We limited the search to literature published after January 1985 in order to encompass modern surgical methods including the widespread introduction of laparoscopy as well as current nonsurgical interventions and medications. We conducted a literature search update during the time of peer review of the draft report and include relevant studies identified through September 2016. We also checked the reference lists of included studies, and incorporated relevant, eligible studies identified by peer reviewers or public commenters. A portal was available 3/14/2016 to 4/11/2016 on the Effective Health Care Web site to receive scientific information and regulatory information on medications, procedures, and devices used to treat uterine fibroids.

Table 1. Literature search strategy: interventions for uterine fibroids

Search	Query	Results
#1	((leiomyoma[mh]) OR (fibroma[mh] AND (uterine diseases[mh] OR uterus[mh]))	17,656
#2	(Uterine[tiab] AND (fibroma*[tiab] OR fibroid*[tiab] OR leiomyoma*[tiab] OR myoma*[tiab] OR fibromyoma*[ti-ab]) OR (submucous fibroid*[tiab] OR submucosal fibroid*[tiab] OR Intramural fibroids [tiab]) NOT medline[sb]	985
#3	#1 OR #2	18,621
#4	("Mifepristone"[Mesh] OR "ulipristal"[Supplementary Concept] OR "Anti-Inflammatory Agents, Non-Steroidal"[Mesh] OR "Antifibrinolytic Agents"[Mesh] OR "Goserelin"[Mesh] OR "cetrorelix"[Supplementary Concept] OR "Selective Estrogen Receptor Modulators"[Mesh] OR "Levonorgestrel"[Mesh] OR "Nafarelin"[Mesh] OR "Triptorelin Pamoate"[Mesh] OR "Leuprolide"[Mesh])	90,459
#5	(Mifepristone[tiab] OR Ulipristal acetate[tiab] OR NSAID[tiab] OR antifibrinolytic[tiab] OR Goserelin[tiab] OR cetrorelix acetate[tiab] OR Selective estrogen receptor modulators[tiab] OR SERM[tiab] OR mirena[tiab] OR lng-ius[tiab] OR levonorgestrel-releasing intrauterine system[tiab] OR management[tiab] OR leuprolide[tiab] OR triptorelin[tiab] OR nafarelin[tiab]) NOT medline[sb]	92,082
#6	#4 OR #5	182,541
#7	therapy[sh:noexp] OR drug therapy[mh] OR drug therapy[sh] OR complementary therapies[mh] OR cam[sb] OR Treatment outcome[mh]	4,576,056
#8	surgery[sh] OR surgical procedures, operative[mh] OR embolization, therapeutic[mh]	3,058,662
#9	(Hysterectomy[tiab] OR myomectomy[tiab] OR hysteroscopy[tiab] OR emboliz*[tiab] OR ablation[tiab] OR magnetic resonance guided[tiab] OR focused ultrasound[tiab] OR artery occlusion[tiab] OR UAE[tiab] OR morcellat*[tiab] OR electrosurg*[tiab] OR cryoablation[tiab] OR myolysis[tiab]) NOT medline[sb]	16,834
#10	#8 OR #9	3,075,456
#11	#6 OR #7 OR #10-	6,846,698
#12	#3 AND #11	10,260

Notes: "Drug therapy"[mh] includes hormone therapy; "Surgical procedures, operative"[mh] includes ultrasound ablation, embolization, and hysterectomy; **Search lines:** #3=uterine fibroid concept; #6 drug treatment concept; #7=therapy or treatment general concept; #10=surgical and procedural interventions concept; #11=any intervention; #12=any intervention or treatment and fibroid

Table 2. Literature search strategy: morcellation and risk of cancer dissemination

	PubMed (3/13/15) Query	Results
#1	morcellation	445
#2	morcellat* AND uterine	256
#3	morcellat*	562
#4	("Electrosurgery/adverse effects"[Mesh]) OR "Uterine Myomectomy/adverse effects"[MeSH] OR morcellat*	1,251
#5	("Electrosurgery/adverse effects"[Mesh] AND uterine) OR "Uterine Myomectomy/adverse effects"[MeSH] OR morcellat*	742

Gray Literature

We searched Web sites of organizations likely to conduct research, issue guidance, or generate policies relevant to management of uterine fibroids and government and regulatory agency Web sites for information on morcellation. We searched ClinicalTrials.gov for information about relevant ongoing trials and to confirm that we obtained any available publications of results from completed trials.

Inclusion and Exclusion Criteria

We included studies evaluating expectant management, medications, procedures, and surgeries to treat fibroids in women of any age (Table 3). An assessment of the literature suggested that limiting the search to studies published in or after 1985 did not omit critical literature and eliminated a number of treatments that are not used in contemporary care. We detail the acceptable criteria for patients/participants, interventions, comparators, outcomes, timing, and setting (PICOTS) in Appendix B.

For KQ1 and KQ2 we restricted the literature to randomized controlled trial (RCTs) evaluating the benefits or harms of a medical, procedural, or surgical intervention compared with an inactive control, including expectant management, placebos, or alternate intervention. We limited inclusion to RCTs because they are (1) superior to cohorts for providing direct evidence about effectiveness and comparative effectiveness of interventions; (2) clearly define the patient population; (3) standardize the intervention(s) provided; and (4) uniformly, prospectively assess the intended outcomes. During topic scoping and refinement of the KQs, we documented a substantial increase in the quality and volume of publications from RCTs since the prior review.[12]

Eligible studies for KQ1 or KQ2 had to report one or more patient-centered outcomes (e.g., symptom improvement, blood loss, pain, quality of life or harms) or fibroid characteristics (e.g., size) at both baseline and followup. We did not include studies reporting intermediate outcomes only. Studies reporting only outcomes related to healthcare delivery (e.g., costs, access) were not included. Cost data are linked with operative time and clinician skill sets, which may be affected by a number of factors. Older cost data also have limited utility. We excluded studies in pregnant women. We excluded studies that compared surgical technique or device only (e.g., one type of morcellator vs. a different type). We excluded studies that evaluated a drug not approved for use in the United States except when the study also included a relevant comparator (e.g., studies with a placebo (expectant management) comparison arm or an alternate medication approved for use in the United States).

For KQ3 and KQ4, we included nonrandomized cohort studies and observational studies that provided data to calculate the proportion of fibroid or uterine specimens found to include leiomyosarcoma (KQ3) or the proportion of women exposed to use of power, scalpel, or no morcellation who were followed for survival (also described as dissemination and disease progression) after an identified leiomyosarcoma (KQ4).

A 2015 systematic review conducted by Pritts and colleagues[10] estimated the risk of encountering a leiomyosarcoma at the time of fibroid surgery (KQ3). We updated the search and used similar eligibility criteria to identify papers published from six months prior to the end of their search in 2014. We prioritized an unbiased denominator of women at risk; therefore, we excluded studies with incomplete documentation of pathology.

To address the characteristics that influence survival after leiomyosarcoma, including surgical approach to morcellation, (KQ4) we created a broad search for literature with data about leiomyosarcoma diagnosis and survival. To be included, papers had to provide method of removal of the fibroid (intact/no morcellation, sharp morcellation, power morcellation) and followup time with disease and survival status. We excluded studies with incomplete documentation of pathology and those studies in which morcellation method was not described.

Table 3. Inclusion criteria

Category	Criteria
Population	Women with uterine fibroids (KQs 1-4)
Design	• Randomized controlled trial (KQs 1, 2) • Randomized controlled trials or cohort studies (KQs 3, 4)
Other	• Original research (KQs 1-4) • Publication language: English (KQs 1-4) • Publication year: 1985-2016 (KQs 1-4) • Reports one or more— o Patient-centered uterine fibroid treatment/intervention outcome (KQs 1, 2) o Harm or adverse event from uterine fibroid treatment/intervention (KQs 1, 2) o Data to estimate occult leiomyosarcoma prevalence (KQ3) o Data to estimate risk of leiomyosarcoma dissemination or cancer progression following uterine fibroid treatment (KQ4) • Sufficient detail of methods and results to enable data extraction (KQs 1-4) • Reports outcome data by target population or intervention (KQs 1-4)

KQ = Key Question

Study Selection

We conducted two levels of screening using dual review and explicit inclusion and exclusion criteria (Table 3). We- documented study selection using an abstract screening form and full text screening form (Appendix C). The abstract screening form contained questions about the primary exclusion and inclusion criteria for initial screening. Exclusion of abstract required two team members to classify, independently, the publication as ineligible. We retrieved and reviewed all articles that were not excluded based on the title and abstract screening. We used a more detailed form (full-text screening form) to examine the full-text of references that met criteria for inclusion in abstract review. Two team members independently reviewed eligibility, and we resolved conflicting assessments in team discussions.

Data Extraction and Management

We created data extraction forms to collect detailed information about study characteristics, participant characteristics, intervention(s), comparator(s), reported outcomes (benefits and harms), tools used for outcome measures, length of followup, study results, and elements required for risk of bias assessment. We extracted additional information, when reported, to assess whether the effectiveness of interventions differed by patient or fibroid characteristics.

We assigned codes to document reasons for exclusion and recorded these in an EndNote® (Thomson Reuters, New York, NY) bibliographic database. We used Microsoft Excel to record information about each included publication. We prepared the study outcomes that were used in the meta-analysis for submission to the Systematic Review Data Repository (SRDR).

Outcomes

We extracted the- value at baseline, end of treatment, and last followup by arm for each eligible outcome and each measure reported in the paper. For medication treatment, the end of treatment was typically defined by the treatment duration. Surgical and procedural trials often reported estimated intermediate outcomes such as blood loss, operative time, length of stay, pain, and transfusions. Trials of procedures and medications frequently evaluated need for further intervention and quality of life. Medication studies typically assessed patient symptoms (e.g.,

pain, uterine bleeding) and fibroid characteristics (e.g., fibroid volume, fibroid size, uterine volume). We sought to collect outcomes uniformly within the predefined groupings of "Final Health Outcomes" illustrated in the Analytic Framework (Figure 1). However if data were not provided for a final outcome (e.g., satisfaction with outcomes, desired fertility status) in any of the publications for the category of intervention, there is not a header for that outcome in the related text.

We tabulated the incidence of harms and serious adverse events reported in the studies included in KQ1. We limited extraction of harms to a pre-specified list (Figure 1) and recorded the frequency, including "0", during or after the intervention and at last followup. We extracted these data by arm and did not include comparative rates of harms within studies as studies were not powered to detect differences in harms and did not include sufficient duration of followup. For this same reason, we did not assess the quality of harms reporting within these studies. We categorized the following as serious or major adverse events: death, life-threatening complication, deep vein thrombosis, pulmonary embolism, cardiovascular complication, pulmonary complication, and uterine artery dissection.

Outcome Measures

Fibroid Characteristics

Fibroid characteristics may include the number, size, volume, and blood flow at baseline and followup, and at followup may include those left in situ or identified by authors as appearance of a new fibroid. Some literature relates imaging findings and symptom profiles, but the correlation between fibroid size, number, total volume and symptom status is inconsistent. Women with large fibroids can have minimal symptoms, and those with small fibroids may have significant symptoms.

Fibroid-Related Bleeding

Measurements of fibroid-related bleeding in this literature vary. Some studies measured self-reported bleeding characteristics, such as days of bleeding and severity of bleeding. Other measures included hemoglobin, presence of amenorrhea, change in bleeding scores, or an operational definition of menorrhagia.

Fibroid-Related Pain

Fibroid-related symptoms including dysmenorrhea, pelvic pain, pelvic pressure, urinary frequency, and constipation were measured with varied approaches including 100-point Visual Analog Scales (VAS). Lower scores indicate improved symptoms. Some studies assessed pain from daily diaries, symptom logs, or by asking patients to grade their pain on a 0 to 5 point scale during followup clinical exams.

Quality of Life

Quality of life was measured with several tools: The Uterine Fibroid Symptom and Quality of Life Questionnaire (UFS-QOL) is a validated measurement tool that includes 37 patient-reported items in two scales, the Symptom Severity Scale (eight items) and the Health Related Quality of Life Scale (HRQoL) (29 items).[46] The Symptom Severity Scale assesses severity of fibroid-related symptoms (including items that reflect bleeding characteristics, pressure, urinary frequency, and fatigue). The scale is reported as 0 to 100, with a higher score representing

greater severity of symptoms. The HRQoL scale includes subscales to assess concern, activities, energy/mood, control, self-consciousness, and sexual function. The HRQoL scale is also reported as scores from 0 to 100, with higher scores reflecting better quality of life. The UFS-QOL is responsive to treatment for uterine fibroids and is a useful outcome measure for uterine-sparing fibroid treatments.[47] Approximately half of the studies that reported quality of life (9/19) used the UFS-QOL.

The Short Form 36 (SF-36) is a validated, patient-reported survey that assesses general physical and mental health status. It addresses eight concepts: vitality, physical functioning, bodily pain, general health perceptions, physical role function, social role function, and mental health. Scores are reported from 0 to 100 with higher scores indicating greater functioning. .[48] The European Quality of Life 5D (EQ-5D™) is a general measure of five domains of health-related quality of life (mobility, self-care, usual activities, pain/discomfort, and anxiety/depression); a single weighted index score is calculated with a score of 1 representing full health and less than 1 indicating reduced health status.[49]

Sexual Function

Sexual function was measured using the following validated instruments: the UFS-QOL, the Brief Index of Sexual Functioning for Women (BISF-W), and the Sexual Activity Questionnaire (SAQ). The USF-QOL includes a sexual function subscale. Scores higher than baseline indicate improved outcome. The BISF-W consists of 22 questions that measure the following seven aspects of sexual life: desire, arousal, frequency of activity, receptiveness, pleasure/orgasm, relational satisfaction, and problems affecting sexuality. The total scores range from −16 to +75; higher scores indicate higher quality of sexual function with the exception of the problem dimension. The SAQ is a nine-item measure of three dimensions: pleasure from sexual intercourse (desire, enjoyment, and satisfaction), discomfort during intercourse, and habit (frequency). Higher scores for pleasure and habit and lower scores for discomfort are considered good. Total scores range from 0 to 27.

Pregnancy and Fertility

We considered the following as measures of pregnancy and fertility: number and outcome of pregnancies (e.g., live birth, miscarriage), ovarian failure or ovarian reserve, documented adhesive disease (scarring) reducing fertility, and time to pregnancy. To ascertain a pregnancy success rate, publications must include the number of participants who wished to become pregnant (denominator) as well as the number of pregnancies achieved. We considered loss of fertility as an outcome, which includes conversion from myomectomy to hysterectomy in reproductive-age women.

Reintervention and Recurrence

We defined reintervention as the sum of all repeat procedures or surgeries (e.g., uterine artery embolization [UAE], myomectomy, hysterectomy) due to any cause, including complications or technical failure. We reported recurrence as subsequent treatment for fibroids for persistent or recurrent symptoms and not for complications of the initial intervention.

Quality (Risk of Bias) Assessment of Individual Studies

We evaluated the methodologic quality of studies using guidance from the Methods Guide for Effectiveness and Comparative Effectiveness Reviews.[50] We used prespecified items from

"Assessing the Risk of Bias of Individual Studies in Systematic Reviews of Health Care Interventions"[51] to evaluate the methodologic quality of RCTs. Two senior investigators evaluated each included study independently in six specific domains of assignment of bias (Appendix E). Discordance at the level of any domain was resolved through discussion to reach a final adjudicated assignment. We established thresholds to assign an overall rating of "low", "moderate", or "high" risk of bias (Appendix E).[52] Studies with all six domains rated as low risk of bias as well as those with only a single fault for not masking those doing MRI imaging, were classified as low risk of bias. For semantic clarity, we refer to these as good quality studies. Studies with moderate risk of bias for one or two domains were deemed fair quality and studies with moderate risk of bias in three or more domains or high risk in any domain are referred to as poor quality studies.

Data Synthesis

We provided a qualitative synthesis and summarize data from studies meeting our review criteria for KQ 1 and 2.

For the outcome of having subsequent treatment for fibroids, we estimated the probabilities after randomization to initial treatment with medical management, including intrauterine devices (IUDs); UAE; or myomectomy. Subsequent treatments were grouped into six categories: 1) no intervention; 2) IUD; 3) UAE; 4) high intensity focused ultrasound [HIFU] for fibroid ablation; 5) myomectomy; and 6) hysterectomy. We extracted sufficient data to fit models for three initial interventions: UAE, myomectomy, and medical management across mean age in the treatment arm (centered at age 40) and followup time in months (6, 12 or 24 months). The probability of a subsequent intervention was assumed to be a function of both age and followup time. As some studies did not report the average age in constituent study arms, we imputed the missing values jointly with the model, using a Student-t distribution to characterize the distribution of ages across studies. Note that this assumes reported ages are missing completely at random and are not omitted for any reason related to the underlying event probabilities.

Specifically, we were interested in estimating:

$$\phi_{ijk} = \Pr(I_F = j | I_0 = i, T_F = t_k, A = a_k)$$

where I_0 is an initial intervention, which takes a specific value i for each candidate intervention type. I_F is the followup intervention that may take any of the six values of j listed above, a_k is the mean age for the treatment arm of study k (centered at age 40), and t_k is corresponding followup time in months, which generally will be 6, 12 or 24 months. Hence, the probability of a subsequent intervention was assumed to be a function of both age A and followup time T_F.

The rates of subsequent intervention for each intervention category were estimated using a Poisson model:

$$y_{ijk} \sim Poisson(\phi_{ijk} n_{ik})$$

where y_{ijk} is the number of individuals is study with initial intervention i that underwent subsequent intervention j, and n_{ik} the corresponding number of women in study k that received initial intervention i.

The quantities of interest are the transition probabilities π_{ij} corresponding to each of the initial candidate interventions *i*. These probabilities were modeled on the logarithmic scale as a function of age and followup length covariates as:

$$log(\phi_{ijk}) = \theta_{ij} + X_k\beta_{ij} + \epsilon_k$$

where θ_{ij} is a baseline transition probability (on the logit scale), X_k a matrix of study-arm-specific covariates, β_{ij} the corresponding coefficients, and ϵ_k a mean-zero random effect for study *k*, which accounts for the correlation among arms within the same study.

An attractive benefit to using Bayesian inference for this model is that it is easy to generate predictions from the model, via the posterior predictive distribution. We present estimates of the distribution of the expected rate of women requiring a particular followup intervention; this factors in both residual uncertainty in the rate estimates, as well as the sampling uncertainty of the intervention.

For KQ 3, we fit a Bayesian binomial random effects model to update the estimate of prevalence of leiomyosarcoma, consistent with the inclusion methods of the Pritts and colleagues systematic review.[10]

For KQ 4, to estimate survival for each surgical intervention, we fit parametric survival models using a Bayesian hierarchical approach, using the data extracted from publications that made it available. To account for heterogeneity among studies, we included a study-level random effect in the hierarchical baseline survival parameter. A simple exponential survival function was found to be a poor fit to the data, therefore we fit a Weibull survival function that resulted in an adequate fit.

Grading the Strength of Evidence

Strength of Evidence Assessments

We followed *AHRQ Methods Guide for Effectiveness and Comparative Effectiveness Reviews* and updated guidance for grading the strength of a body of evidence.[52] We assessed and graded "domains" using established concepts of the quantity and quality of evidence, and coherence or consistency of findings. We focused on evidence that addressed final outcomes in which there was sufficient literature and did not grade all possible outcomes. We did not assess the strength of evidence for harms.

Two senior staff independently graded the body of evidence; discordance was resolved in meetings of the full team. We assessed strength of evidence for the effect of medical, procedural, and surgical interventions on fibroid volume, bleeding, and quality of life. We assigned an overall evidence grade based on the ratings for the following domains: study limitations, directness, consistency, precision, and reporting bias.

Overall Strength of Evidence

We summarize the four grades (high, moderate, low, and insufficient) used for the overall assessment of the body of evidence in Table 4 (adapted from the AHRQ Methods Guide updated guidance for grading the strength of a body of evidence[52]). Typically, when only one study was available for an outcome or comparison of interest, we graded the evidence as insufficient.

Table 4. Strength of evidence grades and definitions[a]

Grade	Definition
High	We are very confident that the estimate of effect lies close to the true effect for this outcome. The body of evidence has few or no deficiencies. We believe that the findings are stable (i.e., another study would not change the conclusions).
Moderate	We are moderately confident that the estimate of effect lies close to the true effect for this outcome. The body of evidence has some deficiencies. We believe that the findings are likely to be stable, but some doubt remains.
Low	We have limited confidence that the estimate of effect lies close to the true effect for this outcome. The body of evidence has major and/or numerous deficiencies. We believe that additional evidence is needed before concluding either that the findings are stable or that the estimate of effect is close to the true effect.
Insufficient	We have no evidence, we are unable to estimate an effect, or we have no confidence in the estimate of effect for this outcome. No evidence is available or the body of evidence has unacceptable deficiencies, precluding reaching a conclusion.

[a] Excerpted from Berkman et al. (2013)[52]

Peer Review and Public Commentary

Researchers and clinicians with expertise in treating uterine fibroids and individuals representing stakeholder and user communities provided external peer review of this report. The draft report was posted on the AHRQ Web site for four weeks to elicit public comment. We addressed all reviewer comments, revised the text as appropriate, and documented changes and revisions to the report in a disposition of comments report that will be made available three months after AHRQ posts the final review on the AHRQ Web site.

Results

This chapter presents the evidence to address our four Key Questions (KQs): KQ1, effectiveness of interventions; KQ2, factors that modify effectiveness; KQ3, risk of leiomyosarcoma at the time of fibroid surgery; and KQ4, influence of patient or fibroid characteristics or morcellation approach on survival after leiomyosarcoma. When a final outcome is not discussed it means that the literature did not provide evidence to help understand whether the intervention had any effect on that outcome.

For KQ1 and KQ2, we screened 11,169 records and excluded 7,945 at the time of abstract review. We retrieved the full text of 1,313 publications; 1,192 were excluded for one or more reasons. We identified 121 publications representing 97 unique studies (Figure 2). We included 160 studies for KQ3 (Figure 3) and 28 unique studies (24 of which contributed data to the survival analysis) for KQ4 (Figure 4). In all, we retained 311 publications, representing 285 unique studies, to address one or more KQs in this review. We did not receive any scientific information submissions through the portal on the Effective Health Care Web site.

Appendix D includes a list of excluded publications and reason for exclusion.

Figure 2. Literature flow diagram for Key Question 1 and Key Question 2

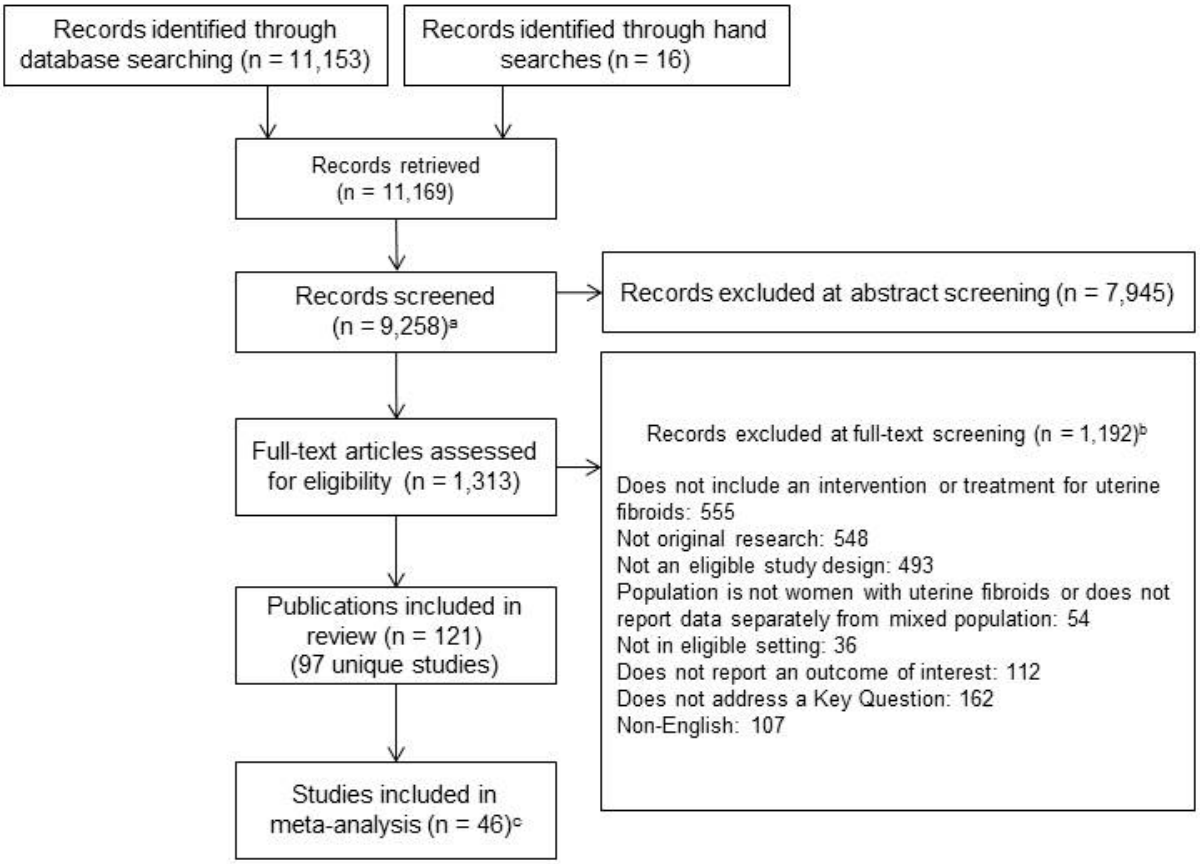

[a] Excluding publications older than 1985 (n = 1911).
[b] Records could be excluded for more than one reason.
[c] Subset of studies that met additional criteria for inclusion in quantitative analysis of estimated probability of subsequent treatment

Figure 3. Literature flow diagram for Key Question 3

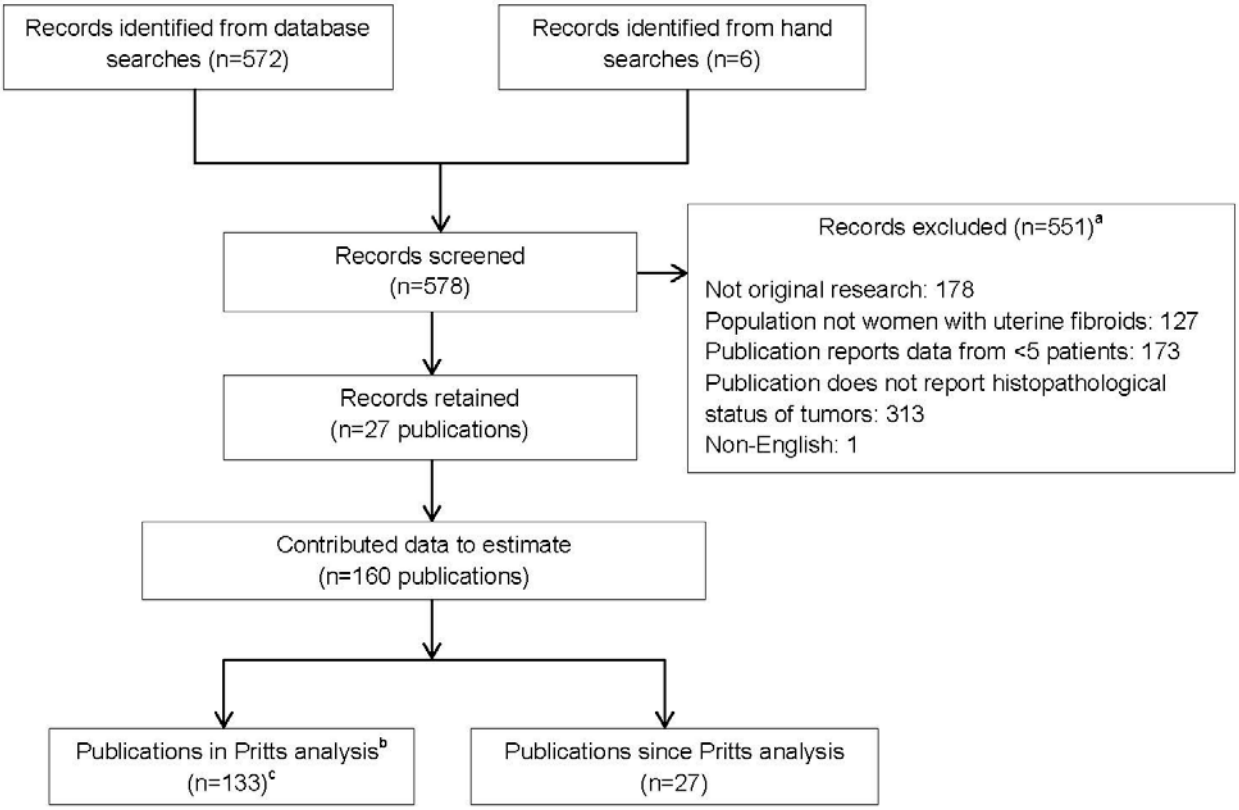

[a]Records could be excluded for more than one reason.

[b]Pritts EHA, Parker WH, Brown J, et al. Outcome of occult urine leiomyosarcoma after surgery for presumed uterine fibroids: a systematic review. J Minim Invasive Gynecol. 2015 Jan;22(1):26-33.

[c]One publication (Silva et al. 2000) contributed data from a retrospective and prospective component. The Pritts analysis counted the publication as two studies; the publication is counted as one study in our updated analysis.

Figure 4. Literature flow diagram for Key Question 4

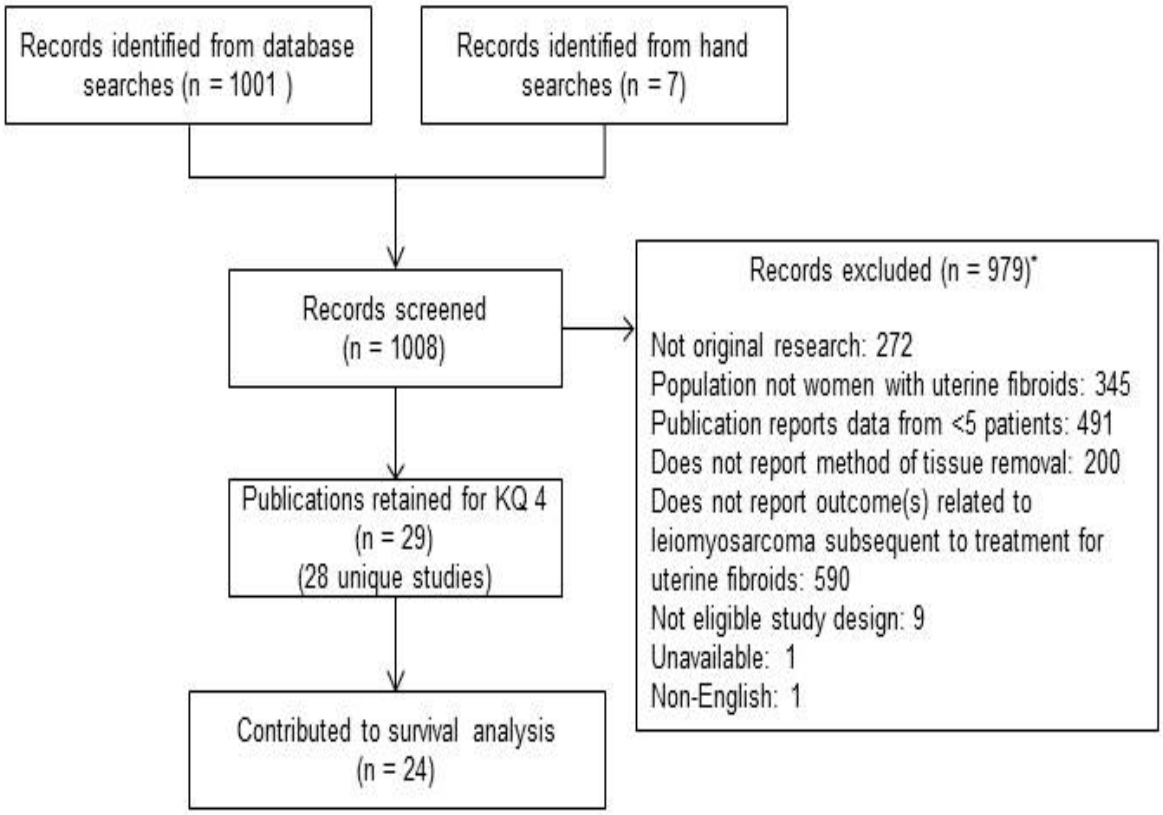

*Records could be excluded for more than one reason.

Content of the Literature About Effectiveness

We included 97 unique randomized controlled trials (reported in 121 publications).[13-23,36,38,53-160] These studies included 9,179 women with the majority of studies conducted in Europe (Table 5). Forty three studies included a medical intervention (including intrauterine devices [IUDs]);[54,59,64-67,75,79,84,87,88,94,98,102,103,106,108,115,116,118,119,122-124,128,129,136-140,142-153] 28 assessed a procedural intervention;[13-16,18,20,22,23,38,53,57,58,60,62,68,78,81,92,104,105,108,113,114,117,127,155,156,158] and 37 assessed surgical treatments.[14,16,20,22,56,57,63,68,72,76,77,80,85,86,89,90,95,100,101,107,110,112-114,120,121,125,126,130-132,134,135,137,141,148,160] We included two studies for their expectant management arms only, because the intervention arms used tibolone [139] or asoprisnil [103], neither of which are approved for use in the United States). Eleven studies compared interventions from more than one category (e.g., procedure vs. surgery).[14,16,20,22,57,68,104,113,114,137,148]

Table 5. Characteristics of studies included for Key Question 1

Characteristic		Med vs. Exp	Med vs. Med	Med vs. Surg	Proc vs. Exp	Proc vs. Proc	Proc vs. Surg	Surg vs. Exp	Surg vs. Surg	All
Studies (N)		**14**	**27**	**2**	**1**	**18**	**9**	**1**	**25**	**97**
Location	North America[a]	8	9	0	1	7	0	0	0	25
	Europe	5	11	2	0	4	7	1	15	45
	Asia	0	3	0	0	7	2	0	8	20
	Middle East	1	4	0	0	0	0	0	1	6
	South America	0	0	0	0	0	0	0	1	1
Decade of Publication	1985 to1995	2	6	1	0	0	0	0	0	9
	1996 to 2005	5	8	1	0	3	2	0	10	29
	2006 to 2016	7	13	0	1	15	7	1	15	59
Study Quality	Good	2	2	0	0	4	2	0	8	18
	Fair	5	7	0	1	4	3	0	7	27
	Poor	7	18	2	0	10	4	1	10	52
Participants	Randomized	1,159	2,570	114	20	1,171	962	181	3,002	9,179

Note: None of the included studies compared medication with procedure or procedure with expectant management
Exp = expectant management; Med = medical; N = number; Proc = procedural; Surg = surgical

[a]Includes studies conducted in the United States, Canada, and Cuba.

We assessed risk of bias for all studies included for KQ1. We considered 18 (18.6%) of these studies to have low risk of bias (good quality), 27 (27.8%) to have moderate risk of bias (fair quality), and 52 (53.6%) to have high risk of bias (poor quality). The most common shortcoming was failure to blind assessors or participants to treatment status. For most studies we assessed risk of bias from the published report only; we also identified the study protocol for 19 of the included studies (Appendix F).We enumerate the risk of bias assessments and source of bias for all studies in Appendix E.

Key Question 1. Effectiveness of Treatment for Uterine Fibroids

Key Points

This summary reflects synthesis of outcomes across arms of studies that used the intervention. If a study included different types of interventions, each arm is included in the related synthesis and discussion. Assessment of harms was limited to those reported by randomized trials and these are reported in the text.

<u>Expectant Management</u>

- The number of women followed without intervention is small (n=514) and data is insufficient to project the outcomes of expectant management (insufficient strength of evidence).

<u>Medications</u>

- Gonadotropin-releasing hormone (GnRH) agonists reduced the size of fibroids and the overall size of the uterus (moderate strength of evidence).

- GnRH agonists, with or without add-back therapy, improved bleeding symptoms, (moderate strength of evidence) and improved quality of life (low strength of evidence)
- Mifepristone reduced fibroid size and improved bleeding outcomes and improved quality of life (moderate strength of evidence).
- Ulipristal reduced fibroid size, improved bleeding outcomes and improved quality of life measures (moderate strength of evidence).
- Raloxifene did not change fibroid size and did not cause changes in hemoglobin in postmenopausal women (low strength of evidence).

Uterine Artery Embolization (UAE) or Occlusion

- UAE reduces the size of fibroids (high strength of evidence) with data from two long term studies demonstrating effectiveness up to 5 years.
- Bleeding outcomes and fibroid-related quality of life measures also improved following UAE (moderate and moderate strength of evidence, respectively).
- Data are inadequate to comment on other methods of occlusion (insufficient strength of evidence).

High Intensity Focused Ultrasound (HIFU) for Fibroid Ablation

- HIFU reduces fibroid and uterine size (low strength of evidence).
- The effects on bleeding, quality of life outcomes, or other patient reported outcomes are unknown (insufficient strength of evidence).

Myomectomy

- Fibroid-related quality of life improved following myomectomy (low strength of evidence).

Hysterectomy

- Fibroid-related quality of life improved following hysterectomy (low strength of evidence).

Direct comparative effectiveness:

- Because of the small number of women studied there was insufficient strength of evidence for outcomes of ulipristal versus GnRH, and UAE versus Myomectomy

Estimation of Subsequent Treatment for Uterine Fibroids

- Modelling estimates that for women in their 30s, the probability of subsequent intervention for fibroids over 2 years varied from 6-7 percent after medical treatment or myomectomy to 44 percent after UAE. For women in their 40s and 50s, modelled 2-year reintervention rates were 9-12 percent following medical treatment or UAE, and 0 percent after myomectomy.

Expectant Management: Overview

We did not identify any studies intentionally designed to determine outcomes of no intervention, also called expectant management or watchful waiting. However, 16 randomized controlled trials (RCTs)(reported in 17 publications) included 514 women in expectant management arms (defined as no treatment, placebo or sham treatment, or minimal intervention such as multivitamin use) compared to active treatment.[36,59,61,65,67,74,79,103,106,107,118,123,128,129,139,147,150,156] Two of these trials were of good quality, six fair, and eight poor. Expectant management arms assessed changes in fibroid or uterine size (13 studies),[36,65,74,79,103,106,118,123,128,139,147,150,156] bleeding patterns (4 studies),[65,74,79,147]

pain, pressure, or symptom severity (8 studies),[36,65,74,103,106,129,147,156] sexual function (3 studies),[65,103,147] and pregnancy outcome (1 study).[107]

Expectant Management: Results

The majority of women evaluated for expectant management came from 14 drug trials.[36,65,67,74,79,103,106,118,123,128,129,139,147,150] Other no-intervention groups include one study arm from a myomectomy trial to evaluate pregnancy outcomes[107] and one from a placebo-controlled pilot study of MRI-guided focused ultrasound (MRgFUS).[156] The studies were small and almost half (7 of 16) did not report masking those conducting or interpreting the imaging measurements to group status. The placebo-controlled trials did describe credible placebos, which diminishes concern that imaging measures would be modified by participant report of their intervention status. Unless knowledge of study arm was directly available to those interpreting measures from imaging, the effect of bias may not be substantial.

Expectant Management and Fibroid Characteristics

The overall evidence suggests the size of fibroids does not meaningfully change over short timespans, based on an average followup time of 5 months (range, 3 to 12 months) (Table 6). Neither of the two studies[128,139] with women who were postmenopausal and followed for a full year detected an increase in total volume of fibroids.

Table 6. Change in fibroid and uterine size with expectant management by study arm[a]

Author (Year)	Intervention	N	Treatment months (Imaging)	Followup Months	Fibroid Size Baseline; Followup, cm^3 mean ± SD or median [IQR]/(range)	Change, cm^3	Uterine Size Baseline; Followup, cm^3 mean ± SD or median [IQR]	Change, cm^3
Jacoby V et al. (2016)[156]	Sham procedure	7	3 (MRI)	3	313.0 ± 157.0 NR	0 p=NS	692.0 ± 254.0 671.0 ± NR	↓21.0 (3%) p=NR
Esteve J et al. (2013)[65]	Placebo	47	3 (US)	3	119.0 ± 95.0 123.0 ± 84.0	↑4.0 p=NR	428.0 ± 211.0 439.0 ± 210.0	↑11.0 p=NR
Donnez J et al. (2012)[74]	Placebo + iron	48	3 (US)	3	62.0 [25 to 159] NR	NR*	319.0 [216.0 to 496.0] NR	median ↑5.9% p=NR
Nieman L et al. (2011)[161]	Placebo	14	3 (MRI)	3	149.0 ± 121.0 159.0 ± NR	↑10.4 p=NR	NR NR	NR
Levens E et al. (2008)[36]	Placebo	6	3 (MRI)	3	290.0 (12 to 4,112) NR	↑6.0% p=NR	NR NR	NR
Chwalisz K et al. (2007)[103]	Placebo	31	3 (US)	3	NR NR	↓4.0% p=NR	NR NR	↑1.0% p=NR
Fiscella K et al. (2006)[106]	Placebo	20	6 (US)	6	NR NR	NR	449.0 ± 236.0 NR	↑73.0 p=NS
Jirecek S et al. (2004)[118]	No treatment	12	3 (US)	3	68.0 ± 48.0 78.0 ± 62.0	↑10.3 p=0.09	NR NR	NR
Palomba S et al. (2002)[123]	Multivitamin	29	6 (US)	6	49.0 ± 15.0 55.0 ± 18.0	↑6.3 p<0.05	196.0 ± 57.0 202.0 ± 53.0	↑6.1 p<0.05
Palomba S et al. (2001)[128]	Placebo	31	12 (US)	12	139.0 ± 56.0 NR	No change p=NS	317.0 ± 114.0 NR	No change p=NS
Sadan O et al. (2001)[129]	Placebo	10	6 (US)	6	NR NR	NR	486.0 ± NR NR	NR p=NS

Author (Year)	Intervention	N	Treatment months (Imaging)	Followup Months	Fibroid Size Baseline; Followup, cm^3 mean ± SD or median [IQR]/(range)	Change, cm^3	Uterine Size Baseline; Followup, cm^3 mean ± SD or median [IQR]	Change, cm^3
Gregoriou O et al. (1997)[139]	No treatment	20	12 (US)	12	118.4 ± NR 117.5 ± NR	↓0.9 p=NS	NR NR	NR
Friedman A et al. (1991)[147]	Placebo	64	5.5 (US/MRI)	5.5	206.0 ± 42.0 NR	No significant change	492.0 ± 51.0 517.0 ± NR	↑25.0 (5%) p=NS
Friedman A et al. (1989)[150]	Placebo	20	6 (US)	6	NR NR	NR	426.0 ± 43.0 429.0 ± 52.0	↑3.0 p=NS

cm^3 = cubic centimeters; IQR = interquartile range; MRI = magnetic resonance imaging; N = number; NR = not reported; NS = not significant; SD = standard deviation; US = ultrasound

[a]Single study may contribute more than one entry if more than one arm received the intervention. Table does not include Eder S et al. (2013)[67] or Casini ML et al. (2006)[107] as these studies do not report uterine or fibroid size/volume.

Expectant Management and Bleeding

Bleeding characteristics, measured by bleeding (days and severity) or hemoglobin, did not change meaningfully during followup for those with expectant management (Table 7). Some studies reported no statistically significant change in other bleeding outcomes such as heaviness of periods,[139] monthly hemoglobin measures within normal range,[162] and number and severity of heavy bleeding episodes over 12 months.[128]

Some groups with expectant management experienced modest improvements; 6.3 percent of one placebo group had resolution of intermenstrual bleeding over three months.[65] Symptom severity score improved slightly in the placebo group after 12 weeks (4.2 ± 6.5).[79] In a double-blind study of women who presented with heavy menstrual bleeding, 26 of 37 (70%) in the expectant management group reported resolution or improvement at final visit (24 weeks after enrollment).[147]

The proportion of the 514 women enrolled in these trials who presented specifically with problem bleeding, as opposed to other fibroid-related symptoms, is not known. However, the data suggest that women with fibroids should not expect that bleeding patterns will worsen over the near term.

Table 7. Change in bleeding characteristics with expectant management by study arm*

Author (Year)	Intervention	N	Treatment Months	Followup Months	Bleeding Baseline; Followup mean ± SD or median [IQR]	Change	Hemoglobin Baseline; Followup, g/dL mean ± SD	Change
Jacoby V et al. (2016)[156]	Sham procedure	7	3	3	NR NR	NR	12.0 ± 2.0 NR	NR p=NS
Eder S et al. (2013)[67]	Placebo	139	6	6	MBL, ml 177.3 173.0	↓4.3 p=NR	NR NR	NR p=NR
Esteve J et al. (2013)[65]	Placebo	47	3	3	NR NR	NR	11.8 ± 1.6 11.8 ± NR	0 p=NS
Donnez J et	Placebo +	48	3	3	PBAC	↓59	9.6 ± 1.2	↑3.1 ± 1.7

Author (Year)	Intervention	N	Treatment Months	Followup Months	Bleeding Baseline; Followup mean ± SD or median [IQR]	Change	Hemoglobin Baseline; Followup, g/dL mean ± SD	Change
al. (2012)[74]	iron				376 [241 to 608] 336 [115 to 543]	IQR [-216 to -58] p=NR	12.6 ± 1.3	p=NR
Nieman L et al. (2011)[79]	Placebo	14	3	3	NR NR	NR	12.3 ± 1.4 12.2 ± 1.1	↓0.1 p=0.82
Levens E et al. (2008)[36]	Placebo	6	3	3	NR NR	NR	NR NR	↓0.9 p=NS
Chwalisz K et al. (2007)[103]	Placebo	31	3	3	NR NR	NR	>12.0 NR	↓0.34 p=NR
Fiscella K et al. (2006)[106]	Placebo	20	6	6	NR NR	NR	12.2 11.6	↓0.6 p=0.11
Palomba S et al. (2002)[123]	Multivitamin	29	6	6	Bleeding, days 3.9 ± 1.3 4.0 ± 1.3	↓0.1 p=NS	13.9 ± 1.7 13.8 ± 1.6	↓0.1 p=NS
Palomba S et al. (2002)[123]	Multivitamin	29	6	6	Severity (VAS) 6.1 ± 2.1 6.0 ± 2.1	↓0.1 p=NS	NR NR	NR
Sadan O et al. (2001)[129]	Placebo	10	6	6	NR NR	NR	NR NR	↑1.0% p=NS
Friedman A et al. (1991)[147]	Placebo	64	5.5	5.5	NR NR	NR	12.6 ± 0.3 12.3 ± 0.2	↓0.3 p=NR
Friedman A et al. (1989)[150]	Placebo	20	6	6	NR NR	NR	12.3 ± 0.3 11.3 ± 0.6	↓1.0 p=NS

g/dL = grams per deciliter; IQR = interquartile range; ml = milliliters; MBL = menstrual blood loss; NR = not reported; NS = not significant; PBAC = pictorial blood loss assessment chart; SD = standard deviation; VAS = visual analog scale

*a single study may contribute more than one entry if more than one arm received the intervention.

These findings of minimal change over followup periods of a year or less are compatible with a prior review that included observational cohorts.[12] The number of women in the literature followed without intervention is small (n=514) and these participants may be fundamentally different from other women with fibroids since they were willing to risk randomization to no intervention. Because none of these studies were designed to evaluate expectant management, the overall quality of the research is poor to inform choice of expectant management over other options and strength of the evidence is insufficient.

Medical Management: Overview

We sought studies that addressed whether medications can reduce symptoms or delay the need for other management. Our intended scope was wide, including common clinical interventions such as continuous oral contraceptives to avoid menstrual periods, nonsteroidal anti-inflammatory agents to improve bleeding or dysmenorrhea, and agents such as stool softeners to prevent constipation from bulky fibroids. However, we identified RCTs for five types of clinically less common medications: GnRH agonists**,** progesterone receptor agents,

estrogen receptor agents, hormone replacement therapy, and antifibrinolytic treatment. We did not review trials in which medications were used as adjuncts and in which all participants were scheduled for surgery.[163] We excluded medications that cannot be prescribed in the United States.

Medical Management: Results

We identified 43 studies (48 publications) assessing effectiveness of medical treatment for uterine fibroids[54,55,59,61,64-67,75,79,84,87,88,94,98,102,103,106,108,115,116,118,119,122-124,128,129,136-140,142-153,157,164] We rated four studies as good quality (low risk of bias), 12 as fair (moderate risk of bias), and 27 as poor quality (high risk of bias). Common reasons for classification as poor quality included: no description or unclear description of randomization method (4 studies),[98,118,138,145] no report of assessment of medication adherence,[128] and failure to blind outcome assessors.[94,98]

Eleven studies included a placebo or no treatment comparison group[36,65,67,74,106,118,123,128,129,147,150]. Eight studies compared two or more medications[73,84,87,102,124,133,136,149,153] and 10 compared doses of the same drug.[54,64,66,75,79,88,119,123,140,146] Several studies evaluated dose schedules or regimens that change over time. Another eight studies[94,98,122,138,142,144,145,151] examined the role of an additional drug (i.e., add-back) given to decrease the side effects of the primary GnRH treatment. Six studies of medical interventions are discussed in other sections of this report: the placebo arm of two studies are discussed in the section on expectant management, because the active agents (tibolone, asoprisnil) are not approved for use in the United States; [139] [103]; two studies are discussed in the section on comparison of effectiveness across intervention categories[84,102]; and two studies that compared a GnRH agonist to surgery[137,148] are summarized in the surgical intervention section.

Approximately 35 percent of the medication studies (15/43) were industry sponsored.[54,59,64-67,73-75,98,103,137,140,142,147] [137] The duration of followup ranged from no additional followup after the end of treatment with the medication to 5 years after conclusion of the medication. Women included in the studies were predominantly premenopausal (39 studies). Four studies[124,128,136,139] enrolled postmenopausal women.

We have organized this section to first present the evidence about effectiveness for each category of drug when an important outcome has been measured by multiple studies. We also note if several specific doses or routes of delivery of the drug (e.g., injection vs. oral) have been investigated. We reserve discussion of direct comparisons between categories of medications to the end of the section.

To summarize outcomes we move from changes in the fibroids, to changes in symptoms, including bleeding characteristics, pain, and sexual function. When reported we also summarize fertility status and pregnancy outcomes as well as satisfaction with treatment and subsequent treatments over time. Only hemoglobin/hematocrit laboratory values, severity of uterine bleeding, and standardized quality of life and functional status measures were reported using validated approaches.

GnRH Agonists

Eighteen studies reported in 20 publications evaluated GnRH agonists.[73,87,94,98,116,122,133,138,140,142-147,149-151,153] Thirteen studies (2 good [101, 108,] 2 fair [124, 136,] and 9 poor quality [73,87,94,98,116,122,133,138,140,142-147,149-151,153]) evaluated leuprolide (seven with an add-back

agent), three poor quality studies[98,137,149] included goserelin, and two poor quality studies used triptorelin as the GnRH agonist. [68,126,]

A total of 912 participants were randomized to GnRH treatment; study size ranged from 16 to 101 women. This small study size limits power for discerning differences across treatment groups and virtually prohibits meaningful evaluation of factors that may influence outcomes within groups. In general, study size was selected to detect differences in fibroid size and bleeding characteristics that are measured as continuous variables. The clinical significance of small to modest changes in fibroid size is unknown. Few studies were specifically designed to assess if treatment improved patient reported outcomes such as quality of life, sexual function, or satisfaction with treatment.

As in much of the fibroid literature, lack of followup over time is a limitation. Most studies completed their followup of participants when treatment ended. Only seven studies[98,143,146,147,149,150,153] followed women from 3 to 9 months after end of treatment, limiting the information about how durable the effects may be. Only one study re-contacted participants 3 years after treatment and found 23/59 (39%) had undergone hysterectomy.[137]

Effects of GnRH Agonist Treatment on Fibroid Characteristics

GnRH agonists reduce the size of fibroids, with reductions in volume of fibroids documented between 64 and 175 cm^3 and reductions in the total volume of the uterus between 131 and 610 cm^3 (Table 8). As a point of reference, the volume of a golf ball is 40 cm^3. It may be that change in size is related to initial size, in other words bigger fibroids have more capacity to shrink, but these studies are not able to assess that hypothesis. The duration of treatment was not directly related to reduction in volume in this literature. Two studies that measured fibroids more than once across the course of treatment found the change in the first round of imaging to be the greatest,[146,147] but another small study reported the largest volume reduction two months after treatment ended.[153]

Table 8. Change in fibroid and uterine size with GnRH agonists by study arm[a]

Author (Year)	Dose, mg	N	Treatment Months (Imaging)	Last Followup Months	Fibroid Size Baseline; Followup, cm^3 mean ± SD or median [IQR]	Change, cm^3 mean ± SD or median [IQR]	Uterine Size Baseline; Followup, cm^3 mean ± SD or median [IQR]	Change cm^3 mean ± SD or median [IQR]
Goserelin								
Morris E et al. (2008)[98]	3.6 SQ/month	23	6 (US)	12	NR NR	Mean % change ± SEM ↓61 ± 3.3 p<0.05	NR NR	Mean % change ± SEM ↓58 ± 2.1 p<0.05
Costantini S et al. (1990)[149]	3.6 SQ/month	21	6 (US)	12	192 ± 126 98 ± 86	↓94.0 p=NR	253 ± 52 122 ± 50	↓131 p=NR
Leuprolide								
Donnez J et al. (2012)[73]	3.75 SQ/month	101	3 (US)	3	3 largest fibroids 59 [28 to 156] NR	↓53%, [-69% to -36%] p=NR	200 [138 to 272] NR	↓47% [-57% to -37%] p=NR

Author (Year)	Dose, mg	N	Treatment Months (Imaging)	Last Followup Months	Fibroid Size Baseline; Followup, cm^3 mean ± SD or median [IQR]	Change, cm^3 mean ± SD or median [IQR]	Uterine Size Baseline; Followup, cm^3 mean ± SD or median [IQR]	Change cm^3 mean ± SD or median [IQR]
Donnez J et al. (2012)[73]	3.75 SQ/month	44[b]	3 (US)	8.7	3 largest fibroids 41 [24 to 73] 33 [17 to 65]	↓17%, [-41% to +19%] p=NR	172 [128 to 239] 131 [105 to 182]	↓11% [-22% to -1%] p=NR
Palomba S et al. (2008)[94]	11.25 IM each 3 months	55	6 (US)	6	NR NR	NR	565 ± 89 NR	↓NR p<0.05
Hazlina N et al. (2005)[153]	3.75 IM or SQ/ month	17	3 (US)	12	NR NR	↓43.0% p<0.01	NR NR	NR
Palomba S et al. (2002)[122]	3.75 SQ/month	50	6 (US)	6	189 ± 54 NR	↓NR p<0.05	446 ± 105 NR	↓NR p<0.05
Takeuchi H et al. (2000)[133]	1.88 SQ/month	33	5.2 (US)	5.2	Largest fibroid 172 ± 166 108 ± 139	↓64 p<0.01	NR NR	NR
Palomba S et al. (1998)[138]	3.75 SQ/ month	25	6 (US)	6	308 ± 65 133 ± 34	↓175 p<0.01	996 ± 170 386 ± 95	↓610 p<0.01
Scialli A et al. (1995)[142]	3.75 SQ/month	32[c]	6 (US)	6	NR NR	NR	454 ± 102 195 ± 36	↓259 p<0.05
Carr B et al. (1993)[145]	1.0 SQ/day	9	3 (MRI)	3	345 ± 177 301 ± 161	↓44 p=NS	1278 ± 205 937 ± 188	↓341 p<0.04
Watanabe Y et al. (1992)[146]	1.88 SQ/ month	20	5.5 (US)	12	NR NR	↓54.0% (n=9) p<0.01	553 ± 499 295 ± 351	↓258 p<0.01
Watanabe Y et al. (1992)[146]	3.75 SQ/month	21	5.5 (US)	12	NR NR	↓43.0% (n=7) p<0.01	452 ± 224 271 ± 314	↓181 p<0.01
Friedman A et al. (1991)[147]	3.75 SQ/month	60	5.5 (US/MRI)	12	Largest fibroid 143 ± 43 86 ± NR	↓57 p<0.001	522 ± 52 289 ± NR	↓233 p<0.001
Friedman A et al. (1989)[150]	3.75 SQ/ month	18	6 (US)	9	NR NR	NR	505 ± 93 305 ± 57	↓200 p<0.05
Friedman A et al. (1993)[144]	3.75 SQ/month	51	3 (US)	12	NR NR	NR	820 ± 127 NR	↓36.0% p<0.05
Friedman A et al. (1988)[151]	0.5 SQ/day	7	6 (US)	6	NR NR	NR	601 ± 62 294 ± 46	↓307 p<0.01
Triptorelin								
Parsanezhad M et al. (2010)[87]	3.6 SQ/ month[c]	27	3 (US)	3	95 ± NR 64 ± NR	−33.2% p=0.02	NR NR	NR
Broekmans F et al. (1996)[140]	500 x 1 wk, 100 x 7 wks, variable dose (5, 20, or 100) x 18 wks	24	2 (MRI)	2	NR	↓31.1% p≤0.001	931 ± NR 692 ± NR	↓239 p≤0.001
		24	6 (MRI)	6	NR	↓36.1% p≤0.001	931 ± NR 525 ± NR	↓406 p≤0.001

Abbreviations: cm^3 = cubic centimeters; IM = intramuscular; IQR = interquartile range; mg = milligrams; MRI = magnetic resonance imaging; N = number; NR = not reported; SD = standard deviation; SEM = standard error of mean; SQ = subcutaneous; Rx = treatment; US = ultrasound; wk = week

[a]Single study may contribute more than one entry if more than one arm received the intervention. Parazzini F et al. ((1999)[137] only reports baseline number/size of fibroids for goserelin (n=59)
[b]Subset from the PEARL II trial who did not have surgery following 3 months of treatment
[c]Uterine volume [a]t baseline and after 6 month of leuprolide treatment among 32 individuals from both arms

Seven studies provided information on durability of treatment effects on fibroid size from 3 to 9 months after the end of treatment.[73,143,146,147,149,150,153] All of these reported increases or regrowth often back to pre-treatment levels.[73,143,146,147,149,150,153] A single study reported that two doses (1.88 mg and 3.75 mg) of GnRH were equally effective in reducing uterine volume.[146] Use of add-back raloxifene to GnRH agonists -resulted in greater reduction in fibroid size but no change in fibroid related symptoms.[122] Add-back therapy of tibolone was protective for bone mineral density without interfering with fibroid size reduction.[98] Only one trial found that effects can be maintained over 2 years.[143] Two thirds of 51 women continued GnRH treatment while 17 (33%) discontinued treatment, three for other medication options, five had myomectomies, and nine had hysterectomy.

Effects of GnRH Agonist Treatment on Bleeding

GnRH agonists produce hypogonadism and many women completely stop bleeding (Table 9). Of the 20 published reports, five reported absence of bleeding, three noting statistical significance for clinically important reduction from baseline. One study reported reduction in days of bleeding[98] without a statistical test, and four reported improvement in hemoglobin levels with three of the four reporting significance. No study reported an increase in bleeding or worsening in measures such as hemoglobin or hematocrit within a treatment group. In several studies, some women discontinued treatment because bleeding became more irregular or did not decrease.

The symptoms and side effects of hypogonadism caused by GnRH are often treated with add-back hormonal therapy. GnRH plus add-back therapy was evaluated in eight studies and the effects on bleeding were mixed. Women who received medroxyprogesterone (MPA) as add-back therapy had improved hemoglobin levels reported in two small trials.[142,151] A single trial that evaluated raloxifene as add-back therapy in conjunction with leuprolide acetate noted no difference in the proportion of women who continued to bleed after six cycles of raloxifene (6.3%) vs. placebo (8.3%).[122]Another small study that compared estrogen-progestin to progestin only add-back with leuprolide acetate depot reported improved hemoglobin levels in both groups.[144].Women receiving goserelin plus tibolone had significantly higher mean number of days of bleeding (6.3 days) compared with the goserelin and placebo group (2.9 days).[98] In another 6-month study of leuprolide acetate with or without tibolone, both groups had reductions in the number of women reporting bleeding, but a small number of women continued to bleed with the add-back of tibolone compared with none in the placebo arm.[138] Bleeding outcomes were not assessed in the third study.[94]

Table 9. Change in bleeding characteristics with GnRH agonists by study arm[a]

Author (Year)	Dose, mg	N	Treatment Months	Last Followup Months	Bleeding Baseline; Followup mean ± SD or median [IQR]	Change, mean or median [IQR]	Hemoglobin Baseline; Followup (g/dL) mean ± SD or median (IQR)	Mean Change
Goserelin								
Morris E et al. (2008)[98]	3.6 implant/ month	23	6	12	4.3 days 2.9 days	NR	NR NR	NR
Costantini S et al. (1990)[149]	3.6 SQ/month	21	6	12	NR 0 days by 8 weeks	NR	NR NR	NR
Leuprolide								
Donnez J et al. (2012)[73]	3.75 IM/month	93 82	3	3	PBAC score 297 [189 to 443] 0 [0 to 1]	↓274 [-430 to -161]	12.1 ± 1.8 12.7 ± 1.6	↑0.6 p=NR
Donnez J et al. (2012)[73]	3.75 IM/month	43[b]	3	8.7	PBAC score 273 [186 to 474] 239 [103 to 458]	↓115 [-161 to -19]	NR NR	NR
Palomba S et al. (2008)[94]	11.25 IM each 3 months	55	6	6	Menorrhagia[b] 7.7 ± 1.6 0.0 ± 0.0	↓7.7 p=0.001	NR NR	NR
Hazlina N et al. (2005)[153]	3.75 IM or SQ/ month	18	3	9	NR NR	NR	11.59 ± 2.19 11.69 ± 1.81	↑0.1 p=NR
Palomba S et al. (2002)[122]	3.75 SQ/month	46	6	6	Menorrhagia[c] 7.8 ± 1.9 0.0 ± 0.0	↓7.8 p<0.05	NR NR	NR
Palomba S et al. (1998)[138]	3.75 SQ/month	25	6	6	Menorrhagia[c] 8.2 ± 0.9 0.0 ± 0.0	p<0.01	NR NR	NR
Scialli A et al. (1995)[142]	3.75 SQ/month	14 13	12	12	NR NR	NR	10.3 ± 0.8 11.2 ± 0.6	↑0.9 p<0.05
Watanabe Y et al. (1992)[146]	3.75 SQ/month	21	5.5	12	NR 0 days by 4 weeks	NR	NR NR	NR
Friedman A et al. (1991)[147]	3.75 SQ/month	60	5.5	12	NR NR	NR	12.6 ± 0.2 13.1 ± 0.2	↑0.5 p<0.05
Friedman A et al. (1989)[150]	3.75 SQ/month	18	6	9	NR NR	NR	12.3 ± 0.4 13.0 ± 0.3	↑0.7 p=NS
Friedman A et al. (1988)[151]	0.5 SC/day	7	6	6	NR NR	NR	12.7 ± 0.3 14.1 ± 0.2	↑1.4 p<0.001

g/dL = grams per deciliter; IM = intramuscular; IQR = interquartile range; mg = milligrams; NR = not reported; NS = not significant; PBAC = pictorial blood loss assessment chart; SD = standard deviation; SQ = subcutaneous

[a]Single study may contribute more than one entry if more than one arm received the intervention. Multiple values for N indicate the number of patients at baseline and followup;
[b]Subset from the PEARL II trial who did not have surgery following 3 months of treatment.
[c]Menorrhagia score, values from 0 to 10 where 0 indicates no bleeding.

Effect of GnRH Agonist Treatment on Fibroid-Related Pain

Compared to baseline, GnRH treatment significantly improved pain symptoms including pelvic pressure,[94,98,122,143] pelvic and abdominal pain,[94,98,122,143] and dysmenorrhea.[98] Other studies reported similar improvements but without statistical comparisons of baseline to followup.[144,147]

Effects of GnRH Agonist Treatment on Grouped Symptoms

Palomba and colleagues have conducted multiple studies treating women for 6 months with leuprolide and placebo or a comparator arm not available in the United States.[94,122,138] Within the leuprolide arms of these studies, women experienced a significant improvement in fibroid-related symptoms that were scored on a 1 to 10 point validated scale that includes menorrhagia, pelvic pressure, pelvic pain, urinary frequency, and constipation. Total scores and each individual scale item were improved, in each study bleeding and constipation completely resolved and other scores improved by 3 to 5 points, a substantial and likely clinically significant change. Mood and quality of life were also improved by treatment.[94] In studies with raloxifene add-back, similar improvements were documented in both the raloxifene and placebo add-back groups.[122]

Using a similar, but not identical, five-item scale, Friedman and colleagues also demonstrated improvements in menorrhagia, bulk symptoms, pelvic pressure, urinary frequency, and pelvic pain that were sustained over 1 and 2 years of treatment with leuprolide and either estrogen and progestin add-back or just progestin add-back; with an overall advantage for the combined estrogen and progestin add-back group.[143,144]

Harms Reported in Studies of GnRH Agonist Treatment

Because of estrogen suppression, GnRH is associated with onset of menopausal symptoms,[94,98,138,147] unfavorable changes in lipid profile,[138,144] and bone loss (ranging from 2.6% to 5.5%).[98,138,143] These effects increase motivation for investigating add-back therapy. Estrogen and progesterone together normalized adverse lipid effects, while progesterone only did not.[144] Addition of raloxifene protects bone[138] and estrogen-progestin or progestin add-back stabilized bone loss when initiated after a 12-week period of GnRH only.[144]

Six months of treatment with leuprolide was associated with declines in cognitive function and memory as measured by the Mini-Mental Status Exam and the Wechsler Memory Scale..[94]

GnRH Agonists Summary

GnRH agonists reduce the size of fibroids and the overall size of the uterus. Both with and without add-back therapy, bleeding symptoms, hemoglobin, fibroid-related pain and other symptoms improve over baseline. Add-back medication relieves associated menopausal symptoms and can ameliorate bone loss and lipid changes. Only one trial examined outcomes of treatment after more than 24 months. Extended followup of women after they discontinue GnRH agonists is not available, thus information about potential harms to guide care is limited.

Progesterone Receptor Agents: Anti-Progestins, Selective Receptor Modulators, and Levonorgestrel IUD

This section includes 14 studies designed to test the effectiveness of medications that work through progesterone pathways.[36,54,55,59,61,64-66,73-75,79,88,106,115,119,157,165] They include seven studies

of mifepristone,[64-66,75,88,106,119] ; six of ulipristal,[36,54,59,73,74,79,157]; and a single study of a progesterone-containing IUD.[152]

Mifepristone

Seven studies (eight publications) provide data about outcomes of mifepristone treatment.[64-66,75,88,106,119] This literature is dominated by two teams: a group led by Carbonell and colleagues who conducted five of the included studies in Cuba; and by Eisinger and Fiscella at University of Rochester School of Medicine who conducted two included studies.[106,115,119] Overall, 5 good quality and 2 poor quality trials provided information on 690 women. Two studies compared a 5 mg dose to placebo,[65,106] one study compared 2.5 mg and 5 mg doses,[64] the remainder compared 5 mg and 10 mg doses. Four groups included followup after treatment with mifepristone had ended. Average length of time for off-medication followup was 11 months with the longest untreated followup being 18 months.[66,166]

Effects of Mifepristone on Fibroid Characteristics

All studies observed a decrease in the size of fibroids at the completion of active treatment. The decrease in size of the largest fibroid ranged from 37 cm^3 to 95 cm^3, with an average of 71 cm^3 among the 575 women studied (Table 10).[64-66,75,88] Likewise, total uterine volume decreased in all groups receiving mifepristone.[64-66,75,88,106,115,119] This was consistent across doses from 2.5 mg to 10 mg each day, with statistically significant reductions at 5 mg and 10 mg doses documented in three trials.[88,106,119] Because most trials were designed to compare doses, authors often did not provide statistical comparisons within groups from baseline to followup.

In the studies designed to determine if changes in fibroid size were durable, all four trials reported no statistically significant change in the size of the largest fibroid or uterine volume after completion of treatment.[64,66,75,115] However , while volume of the largest fibroid remained smaller than baseline at nine months of followup off medication, the total uterine volume was slightly increased over baseline. With 12 and 18 months of followup, fibroid and uterine volume tended to increase, often above baseline,[66,75] suggesting that treatment suspends fibroid growth but does not have lasting effects to forestall future growth of fibroids.

It is also important to note in these studies that the number of women available at followup was often fewer than at enrollment. This loss to followup includes those who did not continue medication or who did not improve and had subsequent treatments including surgery. Since intention-to-treat analyses with last uterine volume carried forward were not done, this means as the women are lost to follow up, the measures may under-represent changes in fibroids if we speculate that those who were lost could be more likely to have increase in size over time.

Table 10. Change in fibroid and uterine size with mifepristone by study arm[a]

Author (Year)	Dose, mg	N	Treatment Months (Imaging)	Last Followup, months	Largest Fibroid Size Baseline; Followup(s), cm^3 mean ± SD	Mean Change, cm^3	Uterine Size Baseline; Followup, cm^3 mean ± SD	Mean Change, cm^3
Carbonell J et al. (2013)[64]	2.5	110 102 90	3 (US)	- 3 12	136 ± 129 98 ± 107 129 ± 157	↓38 p=NR ↓7 p=NS	455 ± 314 372 ± 272 495 ± 321	↓83 p=NS ↑40 p=NS
Carbonell J et al. (2013)[64]	5	110 106 100	3 (US)	- 3 12	112 ± 118 60 ± 67 99 ± 91	↓62 p=NR ↓13 p=NS	426 ± 305 332 ± 243 489 ± 265	↓94 p=NS ↑40 p=NS
Esteve J et al. (2013)[65]	5	58	3 (US)	3	125 ± 95 88 ± 79	↓37 p=NR	458 ± 236 354 ± 202	↓104 p=NR
Carbonell J et al. (2013)[66]	5	35 31 9	9 (US)	- 9 27	115 ± 100 55 ± 41 169 ± 86	↓60 p=NR ↑54 p=NS	542 ± 362 361 ± 175 715 ± 433	↓181 p=NR ↑173 p=NS
Carbonell J et al. (2013)[66]	10	35 34 9	9 (US)	- 9 27	263 ± 471 90 ± 77 255 ± 156	↓38 p=NR ↓8 p=NS	866 ± 578 533 ± 570 892 ± 412	↓333 p=NR ↑26 p=NS
Esteve J et al. (2012)[75]	5	74 74 74	6 (US)	- 6 18	133 ± 176 81 ± 102 138 ± 117	↓52 p=NR ↑5 p=NS	573 ± 480 417 ± 271 666 ± 219	↓156 p=NR ↑93 p=NS
Esteve J et al. (2012)[75]	10	70 70 70	6 (US)	- 6 18	108 ± 103 56 ± 61 128 ± 108	↓52 p=NR ↑20 p=NS	544 ± 353 379 ± 259 596 ± 299	↓165 p=NR ↑52 p=NS
Carbonell Esteve J et al. (2008)[88]	5	50 50	3 (US)	3	172 ± 161 77 ± 125	↓95 p<0.001	481 ± 257 305 ± 192	↓176 p<0.001
Carbonell Esteve J et al. (2008)[88]	10	50 49	3 (US)	3	187 ± 184 103 ± 124	↓84 p<0.001	552 ± 499 332 ± 200	↓220 p=0.002
Fiscella K	5	22	6	6	NR	NR	719 ±	↓200

Author (Year)	Dose, mg	N	Treatment Months (Imaging)	Last Followup, months	Largest Fibroid Size Baseline; Followup(s), cm^3 mean ± SD	Mean Change, cm^3	Uterine Size Baseline; Followup, cm^3 mean ± SD	Mean Change, cm^3
et al. (2006)[106]			(US)		NR		663 519 ± NR	p=0.02
Eisinger S et al. (2003)[119]	5	19	6 (US)	6	NR NR	NR	832 ± 443 435 ± NR	↓397 p<0.001
Eisinger S et al. (2003)[119]	10	20	6 (US)	6	NR NR	NR	850 ± 380 438 ± NR	↓412 p<0.001

cm^3 = cubic centimeters; mg = milligrams; N = number NR = not reported; NS = not significant; SD = standard deviation; US = ultrasound

[a]Single study may contribute more than one entry if more than one arm received the intervention. Multiple values for N indicate the number of patients at baseline and followup(s); Eisinger SH et al. ((2005)[115] reports similar results (52-53% reduction in uterine volume) for 12 months of treatment, but combines 5 mg and 10 mg groups.

Effects of Mifepristone on Bleeding

All studies that assessed bleeding reported heaviness of bleeding was reduced by treatment (Table 11). Those that made comparison found the active drug superior to placebo.[65,106] Women were as likely to have decreased bleeding or absent menses on the lower doses compared with the higher doses.[66,88,115] When bleeding occurred it was often described as spotting or staining.[64,65,75]

Table 11. Change in bleeding characteristics and hemoglobin with mifepristone by study arm[a]

Author (Year)	Dose, mg	N	Treatment Months	Last Followup Months	Bleeding Measure	Baseline; Followup(s) percent or mean ± SD	Change
Carbonell J et al. (2013)[64]	2.5	102	3	12	Percent with hemoglobin <10 g/dL	37.3% 14.7%	p=0.02
Carbonell J et al. (2013)[64]	5	106	3	12	Percent with hemoglobin <10 g/dL	40.9% 6.6%	p=0.02
Esteve J et al. (2013)[65]	5	58	3	3	Hemoglobin (g/dL)	11.0 ± 2.0 11.7 ± 2.1	↑0.7 p=0.023
Carbonell J et al. (2013)[66]	5	31	9	9	Percent with amenorrhea	NR 100.0%	NR
Carbonell J et al. (2013)[66]	10	34	9	9	Percent with amenorrhea	NR 80.0%	NR
Esteve J et al. (2012)[75]	5	74 74 74	6	- 6 18	Hypermenorrhea score[a]	8.3 ± 2.2 0.1 ± 0.5 6.6 ± 2.2	p<0.01
Esteve J et al. (2012)[75]	10	70 70 70	6	- 6 18	Hypermenorrhea score[a]	8.9 ± 1.8 0.1 ± 0.3 6.2 ± 2.6	p<0.01

Author (Year)	Dose, mg	N	Treatment Months	Last Followup Months	Bleeding Measure	Baseline; Followup(s) percent or mean ± SD	Change
Carbonell J et al. (2008)[88]	5	50	3	3	Hypermenorrhea percent	78.0% 4.0%	NR
Carbonell J et al. (2008)[88]	10	49	3	3	Hypermenorrhea percent	66.0% 6.1%	NR
Carbonell J et al. (2008)[88]	5	50	3	3	Percent with amenorrhea	NR 90.0%	NR
Carbonell J et al. (2008)[88]	10	49	3	3	Percent with amenorrhea	NR 89.8%	NR
Fiscella K et al. (2006)[106]	5	22	6	6	Hemoglobin (g/dL)	12.0 ± NR 13.5 ± NR	↑1.5 p<0.001
Eisinger S et al. (2003)[115]	5	19	12	- 6 12	Percent with amenorrhea	0% 63.0% 75.0%	NR
Eisinger S et al. (2003)[115]	10	20	12	- 6 12	Percent with amenorrhea	0% 60.0% 40.0%	NR

g/dL = grams per deciliter; mg = milligrams; N = number; NR = not reported; SD = standard deviation

[a]Single study may contribute more than one entry if more than one arm received the intervention.
[b] Hypermenorrhea evaluated by a self-reported visual analog scale from 0 to 10 where 0 represented an absence of symptoms and 10 indicated the maximum value

Effects of Mifepristone on Fibroid-Related Pain

Each of six publications that evaluated pelvic pain before treatment and at conclusion of treatment noted substantial improvements.[64-66,75,88,106] At baseline, 68 to 100 percent of women in these trials reported pelvic pain. By three months of treatment, this was reduced to a range of 9 to 28 percent with those in the lower dose groups having lower or equivalent prevalence of pelvic pain.[64,65,88] Similar findings persisted at conclusion of 6 and 9 months of treatment. Once off treatment, prevalence of pelvic pain remained meaningfully lower, with 6.3- 37.0 percent of women affected at 9 months,[64,66] 16.2 to 18.6 percent at 12 months,[75] and 10 to 11 percent at 18 months.[66] The Rochester group reported change in pain using the McGill Pain Questionnaire and documented a steady decline from a high score of approximately 20 to about 6 points during the 6 months of treatment.[106] Strength of evidence was not graded for pain.

Effects of Mifepristone Treatment on Quality of life

Four studies (374 women) reported quality of life metrics: for the three that used the UFS-QOL, composite scores improved,[64-66] as much as 50 of a possible 100 points (with placebo controls improving by 17 points). Dose was not convincingly related to quality of life scores.[64,66] The study that used the Short Form 36 subscales documented improvements in energy and fatigue, health status, and pain domains.[106] Statistically significant improvements from baseline were noted in these aspects across studies at one or more doses:

- Symptoms[64,65,106]
- Concern[64,65,106]
- Activity[64,65]
- Inhibition/Self-consciousness[64,106]
- Control[64,65]

- Sexual function[64,106]
- Energy and mood[64,65]

Other Effects of Mifepristone Treatment

In the Cuban studies, improvements were observed for other symptoms including pelvic pressure, urinary symptoms, lumbar pain, rectal pain, and dyspareunia. In each case, the proportion with the symptom dropped by one to two-thirds or more. Improvement was sustained with less than 6 percent increase in prevalence over the additional 9 to 18 months of followup. [64-66,75,88] The Rochester group also reported that improvements in pelvic pressure, urinary frequency, low back pain, rectal pain, and pain with intercourse improved across treatment with active drug compared with placebo, with significant benefits for reducing pain with intercourse.[106]

Harms Reported in Studies of Mifepristone Treatment

No unanticipated adverse drug effects were identified in these trials. All trials conducted surveillance for the most serious known risk of harm, which is development of endometrial hyperplasia. All seven trials (eight publications) conducted an endometrial biopsy at an interim point or at the completion of treatment, unless the subject declined. [64-66,75,88,106,115,119] In four of these studies, biopsies were conducted at more than one followup time point.[64,66,75,115,119] The proportion of participants with at least one post-treatment biopsy result ranged from 73 percent to 99 percent. The total number of biopsies subsequent to treatment in all studies combined was 782.

Two placebo controlled studies with 5 mg mifepristone as the active intervention reported no hyperplasia in either group after 3 or 6 months of treatment.[65, 106] One study compared 5 mg to 2.5 mg mifepristone and reported no hyperplasia in either group after 3 months of treatment.[64] Four studies (reported in five publications) compared 10 mg to 5 mg mifepristone with treatment durations of 3 months,[88] 6 months,[75,119] 9 months,[66] and 12 months.[115] One study[119] reported an additional 6-month continuation, with a revised report of pathology at the 6-month timepoint.[115] Table 12 summarizes the number of women across the four studies who had biopsies with the indicated findings at specific timepoints.[66,75,88,115,119] There were no reported cases of atypical hyperplasia. The counts of simple hyperplasia at 3 months of treatment were 2/92 (2%) for 5 mg dosage and 2/118 (2%) for 10 mg dosage. The counts of simple hyperplasia at 6 months of treatment were 2/85 (2%) for 5 mg dosage and 6/100 (6%) for 10 mg dosage. Data for 9 months and 12 months are sparse. In aggregate, there were 13 cases of simple hyperplasia detected among 446 biopsies.

Table 12. Number of mifepristone-treated women with indicated endometrial status upon biopsy

Pathology Report	3 months[66,75,88]		6 months[66,75,115,119]		9 months[66]		12 months[115]	
	5 mg (3 studies)	10 mg (3 studies)	5 mg (3 studies[a])	10 mg (3 studies[a])	5 mg (1 study)	10 mg (1 study)	5 mg (1 study)	10 mg (1 study)
PAEC	14	32	22	39	5	11	0	0
Simple hyperplasia	2	2	2	6	0	0	0	1
Atypical hyperplasia[b]	0	0	0	0	0	0	0	0
Normal[c]	76	84	61	55	8	6	11	9
Total N women	92	118	85	100	13	17	11	10

mg = milligrams; PAEC = benign progesterone modulator associated endometrial changes

[a] Three studies reported in four publications;
[b] Endometrial intraepithelial neoplasia has replaced atypical hyperplasia as the preferred term;
[c] Normal secretory or proliferative endometrium, other benign descriptor, or insufficient sample.

All seven trials also monitored liver function enzymes as elevations have been reported but not overt or sustained liver damage. .The percentages of women with elevated transaminases following mifepristone treatment ranged from 5.0 to 12.7 percent in the Cuban studies. [64-66,75,88]. The maximum values when reported did not exceed 100 IU. Increases in liver enzymes were also noted in zero and 8 percent of the women in two U.S. studies [119].[106] Abnormal liver enzymes were similar between the group treated with mifepristone (49/652, 7.5%) and the group who received placebo (5/67, 7.5%). There were no reports of any liver damage.

Mifepristone Summary

Moderate evidence from 5 fair and 2 poor quality studies supports that mifepristone reduces size of fibroids and overall uterine volume and improves quality of life. Heaviness of bleeding is reduced during treatment and measures of anemia improve. Information is unavailable to contribute to dose selection between higher and lower doses.

Some evidence suggests fibroids do resume growth after treatment; however, the majority of women achieve symptomatic relief for a year or more after cessation of active treatment. Few participants in these trials pursued subsequent treatment during medical management or in the time after concluding active treatment suggesting that treatment with mifepristone can provide sufficient management of fibroid-related symptoms.

Ulipristal Acetate

Six trials, reported in nine publications, investigated use of ulipristal acetate as a treatment for fibroids, enrolling 691 women in the ulipristal arms. Two small, poor quality trials were conducted at National Institutes of Health[36,79] and four in research networks in Europe (the PEARL trials), of which two were good and two fair quality.[54,55,59,61,73,74,157] The two earliest studies[36,79] followed participants to the end of 12 weeks of treatment with active drug. Two trials reported on drug efficacy in women seeking surgery for management of heavy bleeding and fibroids.[73,74] PEARL I randomized women to 5 or 10 mg doses or placebo for three months[74] and PEARL II randomized women to 5 or 10 mg doses or leuprolide acetate.[73] The PEARL III study assessed up to four courses of 10 mg dose for 12 weeks[59] followed with a daily progestin (norethisterone acetate) or placebo. PEARL IV compared 5 and 10 mg doses in women for four repeated 12 week cycles.[157] There was a drug-free interval following each treatment cycle, with the next treatment round resuming at the start of the second menstrual cycle. Final followup was conducted three months after the completion of medication.[54,157]

Effects of Ulipristal on Fibroid Characteristics

All six studies found ulipristal effective for reducing the size of individual fibroids and the overall fibroid burden as measured by total fibroid and uterine volume (Table 13). A single course of 5 or 10 mg reduced fibroids size by 17 to 38 percent;[36,54,59,79] a repeated course of treatment reduced volume of the three largest fibroids by 54 to 58 percent from baseline to completion of both cycles.[59]

A study that monitored women in ulipristal trial arms who did not go on to have surgery found minimal resumption of fibroid growth (8.1%) that was not statistically significant at six

months after completion of treatment regardless of ulipristal dose.[73] A related trial with similar design found that the 10 mg dose sustained lack of fibroid growth beyond six months while there was increase in size on the 5 mg dose that was similar to placebo.[74] Durability of effects remains unknown. Extended followup after treatment cessation is needed because fibroid growth patterns may differ for women in these trials who did proceed to surgery.

Table 13. Change in fibroid and uterine size with ulipristal acetate by study arm[a]

Author (Year)	Dose, mg	N (Imaging)	Treatment Months	Last Followup Months	Fibroid Size Baseline; Followup(s), cm^3 median [IQR] or (range)	Change, cm^3 percent or median [IQR]	Uterine Size Baseline; Followup, cm^3 Median [IQR]	Change, cm^3 median [IQR]
Donnez J et al. (2015)[54,157] PEARL IV	5	228 (US)	11	14	3 largest fibroids 43 [24 to 94] NR	↓72% [-88% to -33%]	177 [113 to 270] NR	NR
Donnez J et al. (2015)[54,157] PEARL IV	10	223 (US)	11	14	3 largest fibroids 44 [27 to 117] NR	↓73% [-88% to -47%]	175.22 [116.6 to 267.6] NR	NR
Donnez J et al. (2015)[54,157] PEARL IV	5	228 (US)	11	14	N with ≥ 25% fibroid volume reduction	135/166 (81%)	NR NR	NR
Donnez J et al. (2015)[54,157] PEARL IV	10	223 (US)	11	14	N with ≥ 25% fibroid volume reduction	150/170 (88%)	NR NR	NR
Donnez J et al. (2014)[59] PEARL III	10	209 (US)	2.5	5.5	3 largest fibroids* 54 [24 to 129] NR	NR	200 [125 to 291] NR	NR
Donnez J et al. (2012)[74] PEARL I	5	95 (US)	3	3	101 [40 to 205] NR	↓21.2% [-41% to -1%]	338 [236 to 503] NR	↓12% [-28% to +3%]
Donnez J et al. (2012)[74] PEARL I	5	49[b] (US)	3	8.7	81 [33 to 167] 65 [24 to 164]	↑7% [-23% to +31%]	NR NR	NR
Donnez J et al. (2012)[74] PEARL I	10	94 (US)	3	3	97 [32 to 181] NR	↓12.3% [-39% to +4%]	326 [213 to 453] NR	↓12% [-28% to +6%]
Donnez J et al. (2012)[74] PEARL I	10	41[b] (US)	3	8.7	62 [36 to 156] 56 [27 to 121]	↓13% [-44% to +15%]	NR NR	NR
Donnez J et al. (2012)[73] PEARL II	5	93 (US)	3	3	3 largest fibroids 80 [30 to 151] NR	↓36% [-58% to -11%]	199 [150 to 315] NR	↓20% [-40% to -3%]
Donnez J et al. (2012)[73] PEARL II	5	45[c] (US)	3	8.7	3 largest fibroids 52 [27 to 89] 29 [10 to 55]	↓45% [-75% to -12%]	168 [133 to 259] 162 [108 to 203]	↓22% [-38% to -6%]

Author (Year)	Dose, mg	N (Imaging)	Treatment Months	Last Followup Months	Fibroid Size Baseline; Followup(s), cm^3 median [IQR] or (range)	Change, cm^3 percent or median [IQR]	Uterine Size Baseline; Followup, cm^3 Median [IQR]	Change, cm^3 median [IQR]
Donnez J et al. (2012)[73] PEARL II	10	95 (US)	3	3	3 largest fibroids 48 [24 to 111] NR	↓42% [-69% to -14%]	198 [121 to 298] NR	↓22% [-45% to 0%]
Donnez J et al. (2012)[73] PEARL II	10	46[b] (US)	3	8.7	3 largest fibroids 32 [18 to 71] 18 [7 to 48]	↓55% [-75% to +2%]	172 [111, 260] 136 [109, 193]	↓15% [-25% to +5%]
Nieman LK et al. (2011)[79]	10	14 (MRI)	2.8	5.8	NR Decreased in 10/13 women	↓17%	NR NR	NR
Nieman LK et al. (2011)[79]	20	14 (MRI)	2.8	5.8	NR Decreased in 11/13 women	↓24%	NR NR	NR
Levens ED et al. (2008)[36]	10	6 (NR)	3	3	116 (20 to 963) NR	↓36%	NR NR	NR
Levens ED et al. (2008)[36]	20	6 (NR)	3	3	411 (102 to 1343) NR	↓21%	NR NR	NR

cm^3 = cubic centimeters; IM = intramuscular; IQR = interquartile range; mg = milligrams; MRI = magnetic resonance imaging; N = number; NR = not reported; US = ultrasound

[a] Single study may contribute more than one entry if more than one arm received the intervention;
[b] Subset from PEARL I study who did not have surgery following initial 3 months of treatment;
[c] Subset from PEARL II study who did not have surgery following initial 3 months of treatment.

Effects of Ulipristal on Bleeding

Ulipristal, as intended, resulted in absent menses for the majority of women during treatment (range 62 to 100%) and the large majority reported improved bleeding (Table 14).[36,54,73,74,79] This was also documented by improved or stable hematocrit or hemoglobin levels.[36,54,79] Cessation of bleeding at onset of treatment was prompt, ranging from a mean of 4 to 7 days.[54,59,73] Absence of bleeding was achieved more consistently with higher doses.[54,73,79]

Other Effects of Ulipristal

Compared with placebo, all ulipristal doses resulted in improved overall fibroid-related quality of life or subscale scores as measured by the UFS-QOL scale[36,79] though some time points lack statistical testing. Similar improvements were seen in fibroid-related quality of life as measured by the Short Form 36 (SF-36),[74]and two trials also documented improvement in pain.[54,74]

Harms Reported in Studies of Ulipristal Treatment

Among 978 biopsies at completion of treatment, six cases of confirmed hyperplasia (one with atypia) were reported (0.6%). The two smallest studies reported modest elevations of liver function enzymes during treatment; one larger trial documented change in liver function

enzymes was comparable to those taking placebo. About 2 to 10 percent of women taking ulipristal experienced hot flashes.

Ulipristal Summary

Moderate evidence supports the effectiveness of ulipristal for reducing the size of fibroids and improving bleeding and quality of life. Bleeding is reduced with most women reporting absence of menses and measures of anemia stabilized or improved during treatment. Evidence is insufficient to contribute to dose selection between higher and lower doses. Data on extended followup are lacking to gauge whether fibroids resume growth after treatment. Use of a progestin for 10 days to prompt onset of menses shortened the time between treatment cycles in a single study.

Table 14. Change in median PBAC score with ulipristal acetate by study arm[a]

Author (Year)	Dose, mg	N	Treatment Months	Last Followup Months	Baseline Followup, median [IQR]	Change, median [IQR]
Donnez J et al. (2015) [54,157] PEARL IV	5	218	11	14	224 [148 to 357] After cycle 1 123 [45 to 313] After cycle 2 92 [44 to 253] After cycle 4 77.5 [NR]	After cycle 1 ↓87 [-167 to +13] After cycle 2 ↓95 [-216 to +9]
Donnez J et al. (2015) [54,157] PEARL IV	10	214	11	14	215 [151 to 373] After cycle 1 129 [56 to 285] After cycle 2 99 [37 to 202] After cycle 4 76 [NR]	After cycle 1 ↓85 [-209 to -12] After cycle 2 ↓110 [-236 to -50]
Donnez J et al. (2014)[59] PEARL III	10	201	2.5	5.5	216 [126 to 376] 31 [11 to 100]	↓120 [-255 to -45]
Donnez J et al. (2012)[74]	5 + iron supplementation	95	3	3	386 [235 to 627] 0 [0 to 5]	↓329 [-571 to -205]
Donnez J et al. (2012)[74]	5 + iron supplementation	50[b]	3	8.7	321 [219 to 536] 234 [102 to 450]	↓81 [-195 to +27]
Donnez J et al. (2012)[74]	10 + iron supplementation	94	3	3	330 [235 to 537] 0 [0 to 0]	↓326 [-527 to -226]
Donnez J et al. (2012)[74]	10 + iron supplementation	41[b]	3	8.7	272 [212 to 433] 174 [46 to 321]	↓161 [-256 to +13]
Donnez J et al. (2012)[73]	5	93	3	3	286 [190 to 457] 0 [0 to 2]	↓268 [-412 to -172]
Donnez J et al. (2012)[73]	5	43[b]	3	8.7	299 [213 to 391] 236 [143 to 387]	↓73 [-242 to +65]
Donnez J et al. (2012)[73]	10	95	3	3	271 [183 to 392] 0 [0 to 0]	↓268 [-387 to -179]
Donnez J et al. (2012)[73]	10	45[c]	3	8.7	244 [173 to 351] 141 [103 to 311]	↓96 [-155 to -62]

IQR = interquartile range; mg = milligrams; N = number; NR = not reported; PBAC = pictorial blood loss assessment chart

[a] Single study may contribute more than one entry if more than one arm received the intervention.

[b] Subset from PEARL I study who did not have surgery following initial 3 months of treatment
[c] Subset from PEARL II study who did not have surgery following initial 3 months of treatment

Levonorgestrel (LNG) Intrauterine Device

One small, poor quality study compared a daily oral progestin (norethindrone acetate) with LNG-IUD for improving bleeding patterns among 60 premenopausal women with uterine fibroids. [152] No placebo was used and women were not blind to intervention group.

Effects of LNG-IUD on Fibroid Characteristics

The study did not report changes in fibroid volume.

Effects of LNG-IUD on Bleeding

Participants used the Visual Blood Scoring system,[167] a standardized pictorial method for reporting blood loss in a diary over the course of treatment. Visual blood loss scores improved by 6 months in both groups, with greater improvement in the LNG-IUD group (p=0.03). Improvement in hemoglobin likewise occurred in both groups with a statistically greater improvement among those with an IUD.

Other Effects of LNG-IUD

Women with the LNG-IUD were more satisfied and more likely to continue treatment than women taking norethindrone acetate. This study did not report harms of LNG-IUD.

LNG-IUD Summary

This trial suggests the LNG- IUD can improve bleeding even among women whose fibroid symptoms were considered appropriate for surgical intervention. However, the quality of the study was poor and thus evidence to guide care is inadequate. Based on the criteria for this review, evidence is insufficient for effects of LNG-IUD on bleeding, fibroid size, and quality of life.

Estrogen Receptor Agents and Combined Hormonal Therapy

Six studies included agents that act at the estrogen receptor.[118,123,124,128,129,136] Three studies (two fair and one poor quality) investigated raloxifene in 73 women compared to placebo. [118,123,128]Two were conducted in Italy by Palomba and colleagues with a total of 160 participants,[123,128] and the third, a smaller study with 25 women in Austria.[118] Two of these studies focused on premenopausal women; one enrolled only post-menopausal women.[128] A single poor quality pilot study (n=20) evaluated tamoxifen. [129] Two small poor quality trials conducted in Italy (n=38) and Turkey (n=46) had arms that provided estrogen plus progestin replacement to postmenopausal women with fibroids.[124,136]

Effects of Estrogen Receptor Agents on Fibroid Characteristics

Fibroid size decreased by 4.4 cm^3 to 34.2 cm^3 in two studies of raloxifene and did not change size in another raloxifene study (to put this in perspective, 40 cm^3 is the volume of a golf ball). Change in fibroid characteristics was not reported in the trial of tamoxifen (Table 15).

Table 15. Change in fibroid and uterine size with estrogen receptor agents by study arm[a]

Author (Year)	Dose, mg	N	Treatment Months (Imaging)	Followup Months	Fibroid Size Baseline; Followup(s), cm^3 mean ± SD	Change, cm^3	Uterine Size Baseline; Followup, cm^3 mean ± SD or (range)	Change, cm^3
Raloxifene								
Jirecek S et al. (2004)[118]	180	13	3 (US)	3	59.0 ± 48.1 54.4 ± 47.9	↓4.4 p=0.03	NR NR	NR
Palomba S et al. (2002)[123]	60	29	6 (US)	6	51.7 ± 18.9 57.4 ± 23.7	↑5.7 p<0.05	203.9 ± 58.4 209.5 ± 59.3	↑5.6 p<0.05
Palomba S et al. (2002)[123]	180	30	6 (US)	6	47.4 ± 16.3 47.7 ± 21.8	↑0.3 p=NS	206.7 ± 61.0 207.5 ± 64.4	↑0.8 p=NS
Palomba S et al. (2001)[128]	60	31	12 (US)	12	127.1 ± 38.2 NR	↓27.0% p<0.05	295.5 ± 81.0 NR	↓40.0% p<0.05
Tamoxifen								
Sadan O et al. (2001)[129]	20	10	6 (US)	7	NR NR	NR	334 (130 to 712) NR	NR p=NS

cm^3 = cubic centimeters; mg = milligrams; N = number; NR = not reported; NS = not significant; SD = standard deviation

[a] Single study may contribute more than one entry if more than one arm received the intervention.

Effects of Estrogen Receptor Agents on Bleeding

In studies of raloxifene with premenopausal women, neither bleeding pattern[118,123,128] nor hemoglobin levels[123] improved compared with placebo, and a lower versus higher dose had similar results for days and severity of bleeding.[123] Among postmenopausal women, most women remained amenorrheic (83% in the raloxifene group and 86% in the placebo group at 9 months); the number of episodes of spotting and severity of bleeding were similar among women in the treated and control group. In the pilot study, tamoxifen use in premenopausal women also did not influence length or severity of bleeding compared with placebo.[129]

Effects of Estrogen Receptor Agents on Other Symptoms

Only the small pilot tamoxifen comparison to placebo assessed pain; 70 percent of participants had pain at enrollment. The treatment group reported significantly less pain after four months of treatment but not earlier.[129] The study did not report on improvement in other symptoms or quality of life.

Risk of Harms With Estrogen Receptor Agents

These studies reported no drug-related adverse events, and withdrawal from treatment for perceived side effects or adherence was rare and equal to placebo groups.[118,123,128] Simple ovarian cysts occurred in raloxifene treated women which resolved once off medication.[118] Endometrial thickening occurred with tamoxifen, and biopsies in this very small study were normal.[129] However, these randomized controlled trails were not designed or powered to detect all harms related to this therapy.

Combined Hormone Replacement Therapy

Two poor quality RCTs had a total of 42 women receiving transdermal estrogen plus cyclic oral medroxyprogesterone acetate after menopause. [124,136]They compared hormone therapy to tibolone (not available in United States) for menopausal symptom management with attention to whether treatment increased size of fibroids. Combined estrogen plus progestin therapy resulted in timed cyclic bleeding as intended among postmenopausal women.[136] In the HRT arm fibroid size increased by approximately 10 cm^3 after 6 months.[124] In the longer study there was no further growth between 6 and 12 months.[136]

Summary of Estrogen Receptor Agents

These agents were related to no or small decreases in fibroid size without improvement in bleeding among those who were premenopausal.

These studies provide a low strength of evidence that raloxifene is unlikely to prompt significant fibroid growth or to exacerbate bleeding if they are needed to treat women with fibroids for other conditions such as breast cancer prophylaxis. Two small studies of combined hormone replacement therapy did not find any changes in fibroid size after 6 or 12 months of therapy. This is insufficient to gauge if estrogen plus progestin therapy for menopausal symptoms does or does not promote fibroid growth.

Tranexamic Acid

We include one study, a pooled analysis of data from two independent trials of tranexamic acid treatment versus placebo for heavy uterine bleeding.[67] We did not include the primary studies that contributed data to the pooled analysis because those studies did not meet our review inclusion criteria (outcomes were not reported by fibroid status). The pooled analysis included a subset of women with uterine fibroids from each study. Women with fibroids who received tranexamic acid reported statistically significant ($p<0.001$) reductions in menstrual blood loss at treatment cycle three compared with placebo. We did not rate the quality or risk of bias for the pooled analysis or the primary studies from which the data was drawn.

Procedures for Fibroid Intervention: Overview

In this section we include studies of procedures to treat uterine fibroids including uterine artery embolization (UAE) and occlusion, high intensity focused ultrasound (HIFU) for fibroid ablation, and radiofrequency fibroid ablation. The literature discussed in this section includes studies focusing on UAE only, with the exception of UAE compared with laparoscopic occlusion of the uterine arteries. Studies comparing UAE to surgery are discussed in the section about direct comparisons.

Procedures: Results

We include 28 studies addressing UAE, HIFU including MRgFUS, and radiofrequency fibroid ablation.[13-23,38,53,57,58,60,62,68,70,71,78,81,82,91-93,96,97,99,104,105,108,109,111,113,114,117,127,155,156,158] Studies included 2,149 women and were conducted in 15 different countries, most frequently in the United States (7 studies) or China (6 studies).) Many (15) of these [14,15,18,22,23,53,58,62,81,92,105,108,117,127,155] did not report source of funding. Three studies, two comparing embolic agents[13,78] and one that evaluated radiofrequency fibroid ablation,[57] were industry supported. Nine studies compared a procedural intervention to hysterectomy or

myomectomy.[14,16,20,22,57,68,104,113,114] The longest duration of followup after the end of treatment was 5 years in two studies.

Uterine Artery Embolization or Occlusion

We identified 21 studies (reported in 34 publications) that randomized women to UAE or uterine artery occlusion.[13-23,38,62,70,71,78,82,91-93,96,97,99,104,105,108,109,111,113,114,117,127,155,158]. Of 18 studies of UAE (30 publications), ten studies compared an embolization agent to a different agent or different size,[13,15,18,23,62,78,92,117,155,158] seven studies compared UAE to surgery,[14,16,20,22,104,113,114] and one compared UAE to a GnRH agonist (goserelin).[108] We assessed six studies to be good quality, six were of fair quality and six were poor quality.

We identified three studies (one fair quality and 2 poor quality) reported in four publications that assessed uterine artery occlusion. Two studies (reported in three publications) compared transcatheter[38] or laparoscopic[83,105] uterine artery occlusion to UAE; one compared laparoscopic bipolar coagulation alone to laparoscopic bipolar coagulation plus laparoscopic ligation of uterine nerves to determine if the addition of laparoscopic uterine nerve ablation would improve postoperative pain and dysmenorrhea .[127]

Much of the information on safety and long-term outcomes of UAE is from two large trials (EMMY[114] and REST[104]). The duration of followup ranged from 2 months to 60 months after treatment, with an average of 15 months.

Effects of UAE on Fibroid Characteristics

Fibroid and uterine volume decreased consistently and significantly following UAE (up to 12 months postprocedure) regardless of the embolization agent or size of particles used to occlude the fibroid arteries (Table 16). Additional longer-term followup reports from the EMMY trial confirm that fibroid and uterine volume reductions persist up to 5 years after UAE; however in four studies with two to five years of followup, the proportion of women seeking subsequent treatment following UAE ranged from 19 percent to 38 percent Appendix G includes additional tables with data on changes in uterine volume.

Table 16. Change in fibroid volume with uterine artery embolization by study arm[a]

Author (Year)	Embolic Agent	N (Imaging)	Followup, months	Baseline; Followup cm^3 mean ± SD or (range)	Change, cm^3 mean or percent ± SD
Wang X et al. (2015)[155]	PVA particles (200 µm)	65 (US)	6	114.9 ± 13.0 23.9 ± 9.4	↓91 p<0.05
Wang X et al. (2015)[155]	PVA particles (500 µm)	65 (US)	6	116.4 ± 12.6 44.7 ± 10.7	↓71.7 p<0.05
Shlansky-Goldberg R et al. (2014)[13]	PVA particles	28 (MRI)	3	NR 104.2 ± 116.1	↓76.9 ± 135.8 p=NR
Shlansky-Goldberg R et al. (2014)[13]	TAG microspheres	28 (MRI)	3	NR 117.1 ± 179.5	↓27.4 ± 42.3 p=NR
Song Y et al. (2013)[62]	Gelatin sponge particles	30 (MRI)	3	265.3 ± 339.0 112.1 ± 167.4	↓153.2 p=NR
Song Y et al. (2013)[62]	PVA particles	30 (MRI)	3	184.1 ± 141.3 97.2 ± 88.7	↓86.9 p=NR
Yu S et al. (2011)[15]	PVA particles	30 (US)	9	197.7 ± 179 NR	NR ↓44.3% ± 52.4%

Author (Year)	Embolic Agent	N (Imaging)	Followup, months	Baseline; Followup cm^3 mean ± SD or (range)	Change, cm^3 mean or percent ± SD
Yu S et al. (2011)[15]	TAG microspheres	30 (US)	9	181.3 ± 140.0 NR	NR ↓55.0% ± 30.0%
Worthington-Kirsch R et al. (2011)[78]	PVA particles	22 (MRI)	6	130 ± 69 NR	NR[b] NR
Worthington-Kirsch R et al. (2011)[78]	TAG microspheres	24 (MRI)	6	96 ± 50 NR	NR[b] NR
Bilhim T et al. (2011)[18]	PVA particles, large	76 (MRI)	6	193.0 ± NR 98.0 ± NR	↓95.0 ↓49.2%
Bilhim T et al. (2011)[18]	PVA particles, small	77 (MRI)	6	210.0 ± NR 91.0 ± NR	↓119.0 ↓56.7%
Siskin G et al. (2008)[92]	PVA microspheres	27 (MRI)	1	190.6 (0.4 to 670.7) 140.8 (NR)	↓49.8 ↓26.2%
Siskin G et al. (2008)[92]	TAG microspheres	26 (MRI)	1	196.9 (14.1 to 536.6) 161.4 (NR)	↓35.5 ↓18.0%
Mara M et al. (2008)[21]	TAG microspheres	38 (MRI)	6	166.0 ± NR 69.0 ± NR	↓97.0 ↓58.7%
Vilos G et al. (2006)[108]	PVA particles	10 (US)	12	257.3 ± 302.9 34.9 ± 42.4	↓222.4 ↓86.0%
Vilos G et al. (2006)[108]	PVA; goserelin 24 hours post UAE	12 (US)	12	225.7 ± 182.9 94.7 ± 88.9	↓131.0 ↓58.0%
Spies J et al. (2005)[23]	PVA particles	17 (MRI)	3	142.4 ± 126.6 NR	↓29.6 ± 19.1 NR
Spies J et al. (2005)[23]	TAG microspheres	19 (MRI)	3	150.1 ± 178.9 NR	↓39 ± 27 NR
Spies J et al. (2004)[117]	TAG microspheres	54 (MRI)	3	138.4 ± 139.5 NR	NR ↓56.5% ± 22.2%
Spies J et al. (2004)[117]	PVA particles	46 (MRI)	3	162.4 ± 169.3 NR	NR ↓42.5% ± 25.8%
Pinto I et al. (2003)[22]	PVA particles	38 (MRI and US)	6	84.4 (1.8 to 408) 45.5 (0.5 to 408)	↓38.9 ↓46.0%
Volkers N et al.(2007)[99,114]	PVA particles	87 72 73 66 62 (US)	- 1.5 6 12 24	121.5 ± 150 70.5 ± 105 54.4 ± 95 41.6 ± 78 40.1 ± 87	NA ↓14.8% ↓42.1% ↓54.5% ↓60.5%

cm^3 = cubic centimeters; MRI = magnetic resonance imaging; µm = micrometers; NA = not applicable; PVA = polyvinyl alcohol; SD = standard deviation; TAG = trisacryl gelatin; UAE = uterine artery embolization; US = ultrasound

[a] Single study may contribute more than one entry if more than one arm received the intervention. Multiple values for N indicate the number of patients at baseline and followup(s);
[b] Data reported in figure only

Effects of UAE on Bleeding

Changes in bleeding were reported as incidence of amenorrhea, change in bleeding score using a scale from −5 to +5, and self-reported dysmenorrhea or menorrhagia (Table 17).

Table 17. Change in bleeding outcomes with uterine artery embolization by study arm[a]

Author (Year)	Embolic Agent	N	Outcome	Followup, months	Baseline; Followup(s), mean ± SD or median (range)	Change, mean ± SD
Song Y et al. (2013)[62]	Gelatin sponge particles	30	Bleeding Questionnaire[b]	3	8.1 ± NR 2.0 ± NR	NR
Song Y et al. (2013)[62]	PVA particles	30	Bleeding Questionnaire[b]	3	7.9 ± NR 2.5 ± NR	NR
Spies J et al. (2004)[117]	PVA particles	46	Bleeding Questionnaire[c]	3	NR NR	↑3.3 ± 1.5 p=NR
Spies J et al. (2004)[117]	TAG microspheres	54	Bleeding Questionnaire[c]	3	NR NR	↑3.2 ± 1.9 p=NR
Spies J et al. (2005)[23]	PVA particles	17	Bleeding Questionnaire[c]	3	NR 3.1 ± 1.7	NR
Spies J et al. (2005)[23]	TAG microspheres	19	Bleeding Questionnaire[c]	3	NR 4.0 ± 1.4	NR
Ruuskanen A et al. (2010)[20]	Microspheres		Days of menstrual flow	24	4.9 ± 2.4 3.3 ± 4.4	↓1.6 p=NR
Rashid S et al. (2010)[82,104]	NR	75 69	Days of menstrual flow	6 12	NR NR NR	↓1.4 ± 3.7 p<0.05 ↓1.7 ± 3.8 p<0.05
Cunningham E et al. (2008)[38]	Microspheres	8	Bleeding, mean change in AMSS	3	NR NR	↓58.0% p=NR
Cunningham E et al. (2008)[38]	Vascular coils	6	Bleeding, mean change in AMSS	3	NR NR	↓63.0% p=NR
Ruuskanen A et al. (2010)[20]	Microspheres	27	Hemoglobin, g/L	24	131.4 ±13.9 NR	↑9.5 ±13.9 p=NR
Volkers N et al. (2007)[99,114]	PVA particles	81	Hemoglobin, g/dL	24	NR NR	↑1.37 p=NR
Volkers N et al. (2007)[99]	PVA particles	88 81 80 81 81	Days of heavy menstruation	- 1.5 6 12 24	3 (1 to 28) 2 (0 to 14) 2 (0 to 7) 1 (0 to 10) 0 (0 to 6)	NA NR NR NR NR

AMSS = Aberdeen Menorrhagia Severity Scale; g/dL = grams per deciliter; g/L = grams per liter; NA = not applicable; NR = not reported; PVA = polyvinyl alcohol; SD = standard deviation; TAG = trisacryl gelatin; UAE = uterine artery embolization

[a] Single study may contribute more than one entry if more than one arm received the intervention. Multiple values for N indicate the number of patients at baseline and followup(s);
[b] Questionnaire range from 0 (no impact) to 10 (severe impact);
[c] 11-point questionnaire range from -5 (markedly worse) to +5 (markedly improved)

Effects of Uterine Artery Embolization or Occlusion on Fibroid-Related Pain

Most women who underwent uterine artery occlusion via laparoscopic bipolar coagulation reported improvement in dysmenorrhea symptoms at 6 months after procedure (76.2% of women who were treated by coagulation of uterine vessels alone). [127] At baseline, 73 women (90.1%) in the UAE arm of the EMMY trial complained of lower abdominal pain. At 24 months of followup, 84.9 % of women reported moderate improvement of pain.[99] In another study, nine of

the 27 women (33%) in the UAE arm reported dysmenorrhea at baseline while only four (15%) complained of dysmenorrhea at the 2 year followup, thus showing a reduction of 56 % from baseline.[20]

Other Treatment Effects of Uterine Artery Embolization or Occlusion

Quality of Life

Overall improvement in symptoms and physical well-being following UAE were reported using UFS-QOL, SF-36, and European Quality of Life 5D (EQ-5D™) scores. Quality of life was not reported following laparoscopic bipolar coagulation or transcatheter uterine artery occlusion[38,83,105 127]

Quality of Life: UFS-QOL

After UAE, significant improvement in symptoms was reported by the UFS-QOL in a small study (n=36) [23] The 2014 study by Shlansky-Goldberg and colleagues[13] reported changes in total quality of life or symptom and subscores on the UFS-QOL in figures only. Changes in the total quality of life score were reported in figures only in another small study (n=44) comparing UAE with trisacryl gelatin microspheres to UAE with polyvinyl alcohol particles.[78] Total quality of life scores improved at 3 months after uterine artery embolism in both groups (UAE with trisacryl gelatin microspheres: 36.0 ± 25.5 and UAE with polyvinyl alcohol particles: 23.1 ± 23.4, p-values not reported).[117] A 2012 study was powered to detect a 10-point difference in quality of life outcomes among premenopausal women with symptomatic fibroids following abdominal myomectomy or UAE.[16] Authors reported significant improvements from baseline in overall quality of life and severity scores after UAE (p=NR).[16]

Quality of Life: SF-36

Four trials reported SF-36 quality of life outcome measures following UAE. Two assessed at 6 months,[14,155] and two, the REST[104] and EMMY[93] trials, up to 60 months (Table 18). At 6 months, both trials identified significant improvements in quality of life scores from baseline (p=NR and p<0.05).[14,155] The REST trial[17] reported a gain in quality of life after UAE with five year measures of SF-36 scores being comparable to normative data. The EMMY trial[93] also found those in the UAE group had improved general health-related quality of life at 6 months and later when compared with baseline values (p<0.05). Using the Body Image Scale, the EMMY trial[96] reported that body image also improved significantly from baseline (p<0.05) in the UAE group at 6 (−1.34), 18 (−1.24) and 24 (−1.06) months with lower scores representing favorable body image and negative numbers indicating improvement.

Table 18. Change in quality of life (SF-36) with uterine artery embolization by study arm[a]

Author (Year)	N	Domains	Followup(s) Months	Baseline, Mean ± SD	Followup(s), mean ± SD or mean change
Wang X et al. (2015)[155] UAE 200 µm PVA particles	65	Physical function Physical role Bodily pain General health	6	55.4 ± 5.3 49.0 ± 6.4 56.9 ± 5.1 57.1 ± 6.0	83.5 ± 6.4 84.8 ± 7.0 84.3 ± 6.0 85.9 ± 5.1 p=NR

Author (Year)	N	Domains	Followup(s) Months	Baseline, Mean ± SD	Followup(s), mean ± SD or mean change
Wang X et al. (2015)[155] UAE 500 µm PVA particles	65	Physical function Physical role Bodily pain General health	6	55.4 ± 4.0 48.8 ± 6.2 57.0 ± 5.2 57.3 ± 6.2	74.9 ± 5.1 78.5 ± 6.0 76.0 ± 5.3 71.6 ± 6.3 p=NR
Jun F et al. (2012)[14]	62	Physical function Social function Mental health Emotional role Vitality	6	57.7 ± 17.0 44.6 ± 7.0 43.3 ± 22.1 50.0 ± 24.9 54.0 ± 11.5	68.4 ± 6.1 63.0 ± 10.2 71.9 ± 6.2 69.6 ± 6.7 66.2 ± 6.0 p=NR
Moss J et al. (2011)[17,82,104]	94	Physical function Social function Mental health Emotional role Vitality Physical role Bodily pain General health	60	82 ± 19 63 ± 27 63 ± 18 60 ± 43 41 ± 22 51 ± 41 52 ± 22 61 ± 19	90 ± 18 86 ± 23 76 ± 17 82 ± 35 63 ± 22 84 ± 32 79 ± 22 78 ± 19 p=NR
van der Kooij S et al. (2010)[19]	78 81 70	Mental Component Summary	12 24 60	NR NR NR	6.3 (p<0.05) 5.8 (p<0.05) 6.3 (p<0.05)
van der Kooij S et al. (2010)[19]	78 81 70	Physical Component Summary	12 24 60	NR NR NR	7.3 (p<0.05) 9.4 (p<0.05) 8.5 (p<0.05)

N = number; NR = not reported; PVA = polyvinyl alcohol; SD = standard deviation; SF-36 = Medical Outcomes Study 36-Item Short Form General Health Survey; UAE = uterine artery embolization

[a] Single study may contribute more than one entry if more than one arm received the intervention. Multiple values for N indicate the number of patients at baseline and followup(s)

Quality of Life: EQ-5D

The REST trial did not report the change in EQ-5D or symptom status score from baseline at 12 months or at 5 years, though the absolute scores showed improvement.[17,104] Significant improvements (p<0.05) from baseline in EQ-5D scores were observed at 6 months and afterwards in the EMMY trial.[93]

Satisfaction

Out of the seven studies comparing UAE with surgeries, satisfaction rates were reported in all but one study (FUME trial[16]). Satisfaction with outcome was measured by asking women if they would undergo the same treatment again,[22] if they obtained symptom relief,[21,113] if they were satisfied with the treatment,[19,20] and if they would recommend treatment to a friend.[14,19,104] One trial also reported satisfaction without providing details of the criteria.[14] Satisfaction rates (Table 19) ranged from 78 to 89 percent at 6 months[21,22] to 82 to 88 percent at 1 year[14,104] to about 90 percent at 2 years.[19,20] Satisfaction rates remained high (84% to 90%) at 5-year followup.[17,19]

Table 19. Patient satisfaction with uterine artery embolization

Author (Year)	N	Outcome	Followup(s) Months	Percent
Pinto I et al. (2003)[22]	36	Would choose treatment again	6	78.0
Mara M et al. (2008)[21]	58	Symptoms relieved	6	88.5
Edwards R et al. (2007)[104]	95	Would recommend to a friend	12	88.0
Jun F et al. (2012)[14]	62	Would recommend to a friend	12	82.0
	62	Satisfactory rating	12	84.0
van der Kooij S et al. (2010)[19]	81 81 81	Satisfaction with outcome	12 24 60	84.0 91.4 84.0
	81	Would recommend to a friend	60	77.2
Ruuskanen A et al. (2010)[20]	26	Would choose treatment again	24	89.0
Moss J et al. (2011)[17]	93	Would recommend to a friend	60	90.0

N = number

Recurrence and Subsequent Treatment

Two studies[21,71] reported fibroid recurrence. In one trial, women were followed for a mean period of 26 months after UAE.[21] By 2 years, there were six women (10.3%) with regrowth or recurrence of fibroids.[21] The REST trial reported fibroid recurrence in five out of 68 women (7%) 5 years after UAE treatment.[71]

Subsequent treatment was reported in 11 trials with length of followup ranging from 6 to 60 months (Table 20). Hysterectomy was the most frequent intervention (8.9%) followed by repeat embolization (4.2%), myomectomy (3.6%), medication or IUD (1.1%) and endometrial ablation (0.1%).

Table 20. Subsequent fibroid treatment following uterine artery embolization by study arm[a]

Author (Year)	Baseline N	Followup Months	Followup N	HYS	MYO	UAE	ABL	MED/ IUD	No Tx	Percent receiving subsequent treatment
Mara M et al. (2008)[21]	58	24	58	0	19	0	0	0	39	32.8
Manyonda I et al. (2012)[16]	82	12-24	63	6	2	1	0	0	54	14.3
Moss J et al. (2011)[17]	106	60	96	18	0	8	0	0	69	28.1
Jun F et al. (2012)[14]	63	6-12	62	0	1	5	0	0	56	9.7
van der Kooij S et al. (2010)[19]	88	60	75	23	2	0	1	7	37	37.5
Pinto I et al. (2003)[22]	38	6	37	2	0	0	0	0	35	5.4

Author (Year)	Baseline N	Followup Months	Followup N	HYS	MYO	UAE	ABL	MED/ IUD	No Tx	Percent receiving subsequent treatment
Ruuskanen A et al. (2010)[20]	27	24	26	3	1	0	0	1	21	19.2
Shlansky-Goldberg R et al. (2014)[13]	60	12	56	1	0	0	0	0	55	1.8
Yu S et al. (2011)[15]	60	24	56	9	1	0	0	0	46	17.9
Bilhim T et al. (2011)[18]	160	6	153	2	0	14	0	0	137	11.5
Spies J et al. (2005)[23]	36	12	36	0	0	2	0	0	34	5.6
Hald K et al. (2007)[83,105]	29	6	29	1	0	0	0	1	27	6.9

HYS = hysterectomy; MED/IUD = medication or intrauterine device; MYO = myomectomy; N = number; No Tx = no treatment; UAE = uterine artery embolization

[a] Single study may contribute more than one entry if more than one arm received the intervention.

Effects of UAE on Ovarian Reserve and Pregnancy Outcomes

Ovarian reserve and pregnancy outcomes were not uniformly evaluated following UAE.[83,105,127] (Table 21) Ovarian failure, measured by follicle stimulating hormone (FSH) >40 IU/L and anti-Mullerian hormone (AMH), was reported in two trials.[82,97] In the EMMY trial 88 women were assigned to UAE. Their average age at baseline was 45. In this group FSH increased significantly by 12.1 IU/L compared with baseline (p=0.001) by 24 months after treatment with UAE. Ovarian failure (FSH >40 IU/L) was reported in 12 percent and 18 percent at 12 and 24 months, respectively.[97] Levels of AMH were significantly lower, indicating ovarian aging at each followup up to 24 months after UAE (p<0.05).[97] These changes in FSH and AMH were comparable to those randomized to hysterectomy (p=0.37). The only predictor of becoming menopausal in each group was being older than 45 at randomization. A similar proportion of 73 women (11%) were observed to have menopausal levels of FSH at 12 months after UAE in the REST study. This was also comparable to levels in the surgical arm of their trial (p=0.47). Participants in REST also had an average age in their mid-forties at the time of randomization.[82]

The trial by Mara and colleagues included 58 women randomized to UAE. The average age of participants in their study was more than a decade younger than the other trials.[21] In this younger study population the risk of elevated FSH >10 IU/L after intervention was higher among those with UAE (13.8%) than myomectomy (3.2%; p<0.05), though no participants became frankly menopausal. This study, though under-powered, was the only study that prespecified pregnancy and live birth as outcomes of interest. By two years, there were 13 pregnancies (50%) and five live births (19.2%) reported out of 26 women wanting to conceive. The REST trial[104] did not prespecify pregnancy outcomes, but did report seven pregnancies after UAE at 12 months which included four miscarriages, two livebirths, and one intrauterine fetal death at 33

weeks with no known cause. The EMMY trial[99] reported one unplanned pregnancy after UAE at 24 months in a 39-year-old multipara, who delivered a healthy child after secondary cesarean section for fetal distress.

Table 21. Pregnancy and fertility status following uterine artery embolization

Author (Year)	N (Imaging)	Followup, months	Number (%) or µg/L mean change
FSH >40 IU/L			
Hehenkamp W et al. (2007)[97]	79	1.4	10/79 (13.0)
	78	6	7/78 (9.0)
	74	12	9/74 (12.0)
	80 (US)	24	14/80 (18.0)
Rashid S et al. (2010)[82]	62 (US)	12	7/62 (11.0)
Mara M et al. (2008)[21]	58 (US)	6	8/58 (13.8)
Anti-Mullerian hormone			
Hehenkamp W et al. (2007)[97]	79	1.4	−0.62[a]
	78	6	−0.23[a]
	74	12	−0.31[a]
	80 (US)	24	−0.42[a]
Pregnancy			
Edwards R et al. (2007)[104]	95 (MRI)	12	7/95 (7.4)
Volkers N et al. (2007)[99]	81 (US)	24	1/81 (1.2)
Mara M et al. (2008)[21]	26 (US/MRI)	24	13/26 (50.0)

FSH = follicle stimulating hormone; IU/L = international units per liter; µg/L=micrograms per liter; MRI = magnetic resonance imaging; US = ultrasound

[a] Compared to expected AMH decrease due to ageing from baseline values.

Harms in Studies of UAE

Transfusion

Three studies of UAE compared with myomectomy or hysterectomy reported incidence of transfusion.[21,22,114] None of the 186 patients required transfusion after UAE.

Other Major Complications

The proportion of major complications, including unplanned hysterectomy, rehospitalization, ovarian failure, and pulmonary embolism during and following UAE ranged from 1.2 to 6.9 percent within a month of the procedure, up to 3 percent by 1 year,[16] and about 5 percent at 2 years.[91] The rates of major complications were highest in two studies that reported long-term followup (21% at 5 years in the REST trial[17] and 16.8% at 32 months in a second study[104].

Complication rates were generally low in the studies comparing embolic agents[15,18,62,92,117] (Appendix G), however the duration of followup among these studies was 9 months or less.

Summary of Uterine Artery Embolization or Occlusion

There was high strength of evidence that UAE is effective for reducing fibroid volume. The strength of evidence supporting improvements in bleeding and quality of life is moderate for UAE. Five-year followup data were available from two large good quality trials in which well over half the women who received an embolization did not need a subsequent intervention (including hysterectomy). The effect of UAE on reproductive outcomes is not well studied and evidence is insufficient to guide care or determine safety.

Because of small numbers and heterogeneity of methods, there is insufficient evidence to make any conclusions about uterine artery occlusion.

High Intensity Focused Ultrasound for Fibroid Ablation

The prior review[12] included findings from a prospective case series that was conducted to support an application for FDA approval of the MRgFUS.[168,169] Since then, we identified six studies reported in seven publications,[53,58,60,68,69,81,156] assessing HIFU as treatment for uterine fibroids. Interventions included MRgFUS in one study,[156] HIFU in two studies with three publications,[68,69,81] HIFU plus contrast enhanced ultrasound in two studies,[53,60] and HIFU plus ethanol injection into the fibroid in one study.[58] These trials were published between 2010 and 2016. Four studies were conducted in China and one each in Italy and the United States. Study size ranged from 20 to 100 women and included a total of 316 participants. The MRgFUS pilot study was fair quality and the other studies were poor quality.

Effects of HIFU for Fibroid Ablation on Fibroid Characteristics

Four studies reported fibroid volume following HIFU (Table 22).[53,58,60,156] The magnitude of fibroid volume reduction was greater at 12 months[53] after HIFU than at 1 month post-treatment.[58]

Table 22. Change in uterine fibroid volume following HIFU by study arm[a]

Author (Year)	Intervention	N	Followup, months	Baseline; Followup, cm^3 mean ± SD	Change, cm^3
Jacoby V et al. (2016)[156]	HIFU plus MRguidance	13	3	217 ± 139 176 ± NR	↓41 -18% p=NR
Jiang N et al. (2014)[60]	HIFU	40	0	NR 82.6 ± 102.0	NR
Jiang N et al. (2014)[60]	HIFU plus CEUS	40	0	NR 58.6 ± 69.3	NR
Orsi F et al. (2015)[53]	HIFU	17	12	189.6 ± 190.0 100.0 ± 144.0	↓89.9 −47.2% p=NR
Orsi F et al. (2015)[53]	HIFU plus CEUS	20	12	419.2 ± 409.0 249.3 ± 257.0	↓169.9 −40.5% p=NR
Yang Z et al. (2014)[58]	HIFU	20	1	156.2 ± 130.1 108.3 ± 926.1	↓47.9 p=NR
Yang Z et al. (2014)[58]	HIFU plus USg intramural ethanol injection	20	1	157.7 ± 198.5 112.8 ± 145.2	↓44.9 p=NR

CEUS = contrast enhanced ultrasound; cm3 = cubic centimeters; HIFU = high intensity focused ultrasound; NR = not reported; USg = ultrasound-guided

[a] Single study may contribute more than one entry if more than one arm received the intervention.

Effects of HIFU for Fibroid Ablation on Bleeding and Fibroid-Related Pain

There was no change in hemoglobin levels after twelve weeks in one small study.[156] Patient-reported bleeding symptoms were not reported in these trials.

Other Treatment Effects of HIFU for Fibroid Ablation

One month after HIFU, the mean change in UFS-QOL score was increased by 16 or more points among 37 patients (baseline not reported); however, four patients experienced persistent symptoms and underwent a second HIFU procedure.[53] A study that compared myomectomy to HIFU reported treatment effects on sexual function at 6 months postprocedure among 100 women. The total sexual function score using the brief index of sexual function for women (BISF-W) improved from 24.6 ± 6.6 at baseline to 26.7 ± 5.2 at 6 months in the HIFU group (n=48; $p<0.05$).[68]

Harms Reported in Studies of HIFU for Fibroid Ablation

No major harms were observed postprocedure in the 316 patients who received HIFU for fibroid treatment.[53,58,60,68,81,156] One study reported on transfusion; none of the 48 women who received HIFU required a transfusion (Appendix G).[68]

HIFU for Fibroid Ablation Summary

HIFU reduced fibroid and uterine size, but strength of evidence is low because of short followup and poor quality of overall study design. Studies of HIFU for fibroid ablation reported intra- and postprocedural outcomes, specifically technical success and safety of the technique.. Publications did not assess symptoms or long-term outcomes, including pregnancy. Limited data suggests that QOL and sexual function do not worsen post-procedure. Evidence related to patient reported outcomes is insufficient.

Radiofrequency Fibroid Ablation

We included two studies (4 publications) that assessed outcomes of radiofrequency fibroid ablation. These studies were conducted in China and Germany and included 75 patients. Both were assessed as poor quality. The Chinese study published in 2010 randomized women to radiofrequency ablation (n=50) or HIFU (n=50).[81] The smaller German study compared a different radiofrequency ablation device (n=25) with myomectomy (n=25).[57,154,159] One and two year followup data included quality of life, bleeding outcomes, reinterventions, and pregnancy outcomes.

Effects of Radiofrequency Fibroid Ablation on Fibroid Characteristics

The effect of the procedure on fibroid volume was only reported as technical success during the procedure. In the German study, authors reported that radiofrequency ablation successfully excised 71 of 72 fibroids (98.6 percent) in 25 patients.[57] The Chinese study reported ablation success of 86 percent (by volume) and 90 percent (by diameter) following radiofrequency ablation among 50 women.[81]

Effects of Radiofrequency Fibroid Ablation on Bleeding and Pain

At one year post-ablation, 94.4 percent of women (n=21) reported improved or no change in menstrual blood loss as measured by the Menstrual Impact Questionnaire.[159] The German study assessed pain and quality of life outcomes at 2 years. Uterine pain did not improve: 3 of 25 women (12%) reported uterine pain at baseline and 5/21 (24%) reported pain at 2 years after ablation.[154] The authors did not take into account recurrent fibroids. Mean health-related quality of life scores improved from 77.1 at baseline to 89.4 at 2 years (p=0.08).

Effects of Radiofrequency Fibroid Ablation on Pregnancy Outcomes

Three pregnancies, culminating in three live births were noted fin the German study after two years of followup for 21 women.[154]

Harms Reported in Studies of Radiofrequency Fibroid Ablation

With the exception of one case of rehospitalization for unexplained vertigo after treatment,[57] authors reported no complications following radiofrequency ablation treatment.[81]

Radiofrequency Fibroid Ablation Summary

We identified two small studies, both poor quality, that evaluated radiofrequency ablation techniques for fibroid symptoms. Two-year followup noted improvements in symptoms and quality of life. This study plans for a total of five years of followup to obtain long-term pregnancy and satisfaction outcomes.[57,156,159]

Surgical Intervention: Overview

Surgical Interventions: Results

We identified 37 studies[14,16,20,22,56,57,63,68,72,76,77,80,85,86,89,90,95,100,104,107,110,112-114,120,121,125,126,130-132,134,135,137,141,148,160] evaluating a surgical intervention to treat women with uterine fibroids. Studies were conducted in seven countries (Brazil, China, France, Germany, Italy, Korea, and Taiwan) and randomized 3,172 women with uterine fibroids to endometrial ablation, hysterectomy, or myomectomy. We assessed study quality as good in ten studies,[56,76,86,89,90,95,114,120,121] fair in ten studies,[16,22,100,104,113,130-132,134,135,141] and poor in 17 studies.[14,20,57,63,68,72,77,80,85,107,110,112,125,126,137,148,160]

Endometrial Ablation

We identified one study of endometrial ablation.[132] This fair quality study reported amenorrhea, bleeding, hemoglobin, patient satisfaction and the incidence of harms in patients treated by roller-ball (n=54) vs. thermal balloon endometrial ablation (n=42).

Effects of Endometrial Ablation on Bleeding

Menorrhagia, reported by pictorial blood loss chart, decreased significantly (p<0.0001) in both groups from baseline to 12 month after procedure. This patient-reported outcome was confirmed by a clinically significant increase in mean hemoglobin in both groups (p<0.001).[132] Table 23 reports changes in hemoglobin.

Table 23. Change in hemoglobin with endometrial ablation by method

Author (Year)	Intervention	N	Followup, months	Baseline; Followup, g/dL mean ± SD	Change, g/dL mean ± SD
Soysal ME et al. (2001)[132]	Rollerball	54	12	9.8 ± 1.2 12.9 ± 0.9	↑3.0 ± 1.6 p<0.0001
Soysal ME et al. (2001)[132]	Thermal balloon	42	12	10.0 ± 1.5 12.8 ± 0.9	↑2.7 ± 1.9 p<0.0001

g/dL = grams per deciliter; N = number; SD = standard deviation

Other Treatment Effects of Endometrial Ablation

The rate of reintervention was similar following rollerball (8.3%) and thermal balloon ablation (8.9%). Rates of dissatisfaction were high in both the rollerball (33%) and thermal balloon (39%) groups.[132]

Harms Reported in Studies of Endometrial Ablation

The endometrial ablation procedure using rollerball necessitates general anesthesia whereas the thermal balloon ablation procedure can be conducted under local anesthesia. The number of intraoperative complications was correspondingly higher in the group who underwent the more invasive procedure (five complications including one case of cervical injury). There were no complications reported during procedures in the thermal ablation group (Appendix G). Overall rates of patient satisfaction were equally poor as noted above.[132]

Endometrial Ablation Summary

Evidence is insufficient to assess the effectiveness of endometrial abalation to improve fibroid symptoms. Limited data suggest that bleeding outcomes remained improved one year following ablation.

Myomectomy

We included 20 studies (reported in 24 publications) that assessed myomectomy for treatment of uterine fibroids.[16,57,63,68,72,76,77,80,85,86,90,95,100,107,110,113,130,134,141,160] Of these, 15 studies reported final health outcomes following myomectomy for fibroids. Five studies reported harms only.[72,76,86,90,95] We considered four RCTs to be good quality, six to be fair quality and ten to be poor quality. Myomectomy techniques include laparoscopic, laparotomy, minilaparotomy, laparoscopically-assisted minilaparotomy, and hysteroscopic approaches.

Effects of Myomectomy on Fibroid Characteristics

Because fibroids are removed at the time of myomectomy, reduction in fibroid and uterine volume are not often reported as an outcome. Fibroid recurrence was reported in seven studies with duration of followup ranging from 6 to 40 months.[77,85,110,113,130,134,141] No recurrences were reported in two studies that evaluated 114 women by ultrasonography 6 months following myomectomy.[85,110] In five studies, recurrence rates ranged from 2.5 to 24.7 percent (56 recurrences reported in 456 women). Recurrence rates did not differ by type of incision in four studies that compared different surgical approaches.[110,113,130,134,141]

Effects of Myomectomy on Bleeding

One trial reported absence of heavy menstrual bleeding at 12 months after the procedure for 12 of 15 (87%) women who had reported it as a problem at baseline.[159] Another noted persistent abnormal menstruation in three (1.9%) women who had myomectomy plus uterine artery occlusion at 2-year followup.[77] No other studies reported changes in symptomatic fibroid-related bleeding, such as heaviness of menses or total days of bleeding. Lack of this outcome means evidence is insufficient for determining if myomectomy improves an extremely common concern among women who seek intervention for fibroids.

Other Treatment Effects of Myomectomy

Return to Usual Activity

Recovery time ranged from 15 days up an average of 30 days as reported in three studies.[110,113,141] Type of incision was a major determinant in recovery time in two studies with more women reporting feeling fully recovered by day 15 following laparoscopy compared with minilaparotomy[110] or abdominal myomectomy.[141] Recovery time from myomectomy averaged 30 days in another small study.[113]

Quality of Life and Symptom Status

Improvement in quality of life or symptom status was reported in five studies (7 publications).[16,21,57,77,80,154,159] Quality of life significantly improved in three studies that assessed it. The FUME trial comparing myomectomy to UAE reported improved quality of life for both groups after one year as measured by the UFS-QOL.[16] A large Chinese study reported improvements in all four domains (physical, psychological, environment, and social relationship) after two years following laparoscopic uterine artery occlusion plus myomectomy using the abbreviated World Health Organization Quality of Life (WHOQOL-BREF) measure. A small study of 25 women documented significant improvements in health related quality of life scores after two years as measured by UFS-QOL (p=0.04) and EQ-5D (p=NR).[154]

Measures of symptom status were reported in two studies. Symptom relief from six symptoms including heavy menstrual bleeding, dysmenorrhea, dyspareunia, pelvic pain, dysuria, and pressure improved for 88 percent (51/58) of women after six months assessed by a questionnaire Symptom improvement including constipation, urinary frequency and menorrhagia improved for 85 percent of women postoperatively in a study evaluating loop ligation for women with larger fibroids.[80] Patient satisfaction with scarring measured using a visual analog scale was comparable in a single study that compared single-port laparoscopically- assisted transumbilical ultraminilaparotomic with single-port laparoscopic myomectomy. [160]

Effects of Myomectomy on Pregnancy Outcomes

Fertility and Pregnancy

Reproductive outcomes were reported in five studies.[21,100,107,134,154] One study described no significant difference in pregnancy outcomes following laparoscopic myomectomy (54%) compared with myomectomy by laparotomy (56%).[134] An RCT (n=136) compared myomectomy approaches (laparoscopic vs. minilaparotomic) and assessed 12-month reproductive outcomes for a total of 556 and 669 cycles, respectively.[100] There was no significant difference in the cumulative pregnancy rate, or the cumulative live-birth rate. However, the time to first pregnancy (5 months

vs. 6 months) and live birth (14 months vs.15 months) was lower after laparoscopic than minilaparotomic myomectomy($p<0.01$). A post-hoc subgroup analysis stratified fibroid patients according to indication: symptoms vs. unexplained infertility. In patients without infertility, the cumulative pregnancy rate, pregnancy rate per cycle (11.1% vs. 5.4%) and live-birth rate per cycle (9.9% vs. 4.8%; $p<0.05$) were significantly higher following laparoscopic than minilaparotomy myomectomy. In patients without infertility, the times to first pregnancy and live birth were significantly lower after laparoscopic than minilaparotomic approach. In patients with unexplained infertility, no difference in any reproductive outcomes assessed was observed between the two myomectomy approaches.[100]

One RCT enrolled 181 women with fibroids and infertility (trying to conceive for at least 1 year without success) then subdivided the women according to the location of the fibroid (submucous, intramural, subserosal) and randomized them to myomectomy or no surgery.[107] For women with subserosal or intramural fibroids, there was no significant difference in the pregnancy rate, comparing myomectomy with no treatment. For women with submucous fibroids, the group who underwent myomectomy had a greater pregnancy rate (40.4%) than those who did not undergo surgery (21.4 percent).[104] A subset of women from a RCT comparing myomectomy to UAE among women with reproductive plans noted that among women who attempted to conceive following myomectomy, 31 of 40 were pregnant at 13 months after fibroid removal and the delivery rate was 47.5 percent (19/40).[21] In a small study comparing ablation (n=26) to myomectomy (n=25), there were six pregnancies culminating in four live births, one induced abortion, and one ongoing pregnancy among twenty-two women after 2 years of followup after myomectomy.[154]

Harms Reported in Studies of Myomectomy

Transfusion

Following treatment for fibroids with myomectomy, transfusion rates were most often zero (1,040 participants in 10 studies).[63,72,76,80,85,95,100,101,110,130,134] Six studies[68,76,80,113,134,160] reported 25 transfusions among 502 participants treated by myomectomy (Appendix G). Seven studies did not report transfusion following myomectomy.[16,57,77,86,90,107,141] One study reported no significant difference in transfusion outcomes following laparoscopic myomectomy compared with laparotomic myomectomy.[134] One study (n=166) reported no significant difference in transfusion outcomes following laparoscopic myomectomy plus uterine artery occlusion compared with laparoscopic myomectomy alone.[72] One study (n=384) reported fewer transfusions following gasless laparoscopic myomectomy compared with conventional laparoscopic myomectomy.[76] Postoperative transfusion risk was found to be comparable in one study comparing a single-port laparoscopically-assisted transumbilical minilaparotomy approach (n=3, 6.5%) with single-port laparoscopic myomectomy (n=4, 8.7%).[160]

Other Surgical Complications

One study (n=80) comparing isobaric laparoscopically-assisted myomectomy with myomectomy via minilaparotomy reported no organ perforations in either group, but was underpowered to assert comparability.[86] Another study (n=148) reported one small bowel injury and one conversion to laparotomy due to hemostasis difficulties in the laparoscopic myomectomy group while no complications were noted in the minilaparotomy group.[110]

Readmission

One study (n=80) comparing isobaric laparoscopically-assisted myomectomy with myomectomy via minilaparotomy reported no readmissions or reoperations, but was underpowered to assert comparability.[86] Another study (n=148) reported that one woman had acute peritonitis and underwent abdominal surgery 10 days after laparoscopic myomectomy, with no complications following minilaparotomic myomectomy.[110] The Mara trial[21] (n=121) reported just one readmission (1.6%) within 30 days after myomectomy.

Reintervention and Recurrence

One study (n=136) reported technical failure (conversion to laparotomy) was more common after myomectomy by minilaparotomy (9%) compared with laparoscopic myomectomy (0%) (p=NR).[100] The reintervention rate was 3.2 % due to fibroid recurrence in another study including 121 women. [21] One woman required hysterectomy 7 months after myomectomy in a second study including 163 women.[16]

Total Complications

In one study (n=136) that reported total complications, these were higher among mini-laparotomy (16%) compared to those who had laparoscopic myomectomy (3%).[100] The FUME trial[16] (n=163) reported six major complications (8%), all occurring during the hospital stay after myomectomy while another trial (n=121) reported "unexpected intrauterine penetration" (not defined) after myomectomy in three cases (5%).[21]

Myomectomy Summary

There is low strength of evidence that women had improved quality of life following myomectomy. Evidence is insufficient to determine if myomectomy improves bleeding. This procedure is an option for women desiring future fertility, but evidence is insufficient to define the potential benefit. There is some risk of fibroid recurrence (reported ranges from 0 to 25%) that does not vary by type of surgical technique.

Hysterectomy

We identified 14 studies reported in 23 publications [19,20,22,56,70,77,89,91,93,96,97,99,109,111,112,114,120,121,125,126,131,135,137] assessing hysterectomy in women with uterine fibroids. Seven reported harms only (i.e., did not report final health outcomes for effectiveness).[56,89,120,125,126,131,135] One study[137] did not report results for the women who were randomized to immediate hysterectomy; the results from the comparator arm (women treated with a GnRH) is reported in the medication section above and in the comparative effectiveness section below.

Studies addressed the following interventions: intrafascial supracervical hysterectomy,[77] laparoscopic assisted vaginal hysterectomy,[56,89,120,126,131,135] total laparoscopic hysterectomy,[56,125], vaginal hysterectomy,[56,89,112,120,121,131,135] and total abdominal hysterectomy.[22,112,120,121,125] Three studies used more than one hysterectomy approach (i.e., type and route not standardized) or did not describe the type of hysterectomy.[20,114,137] Assessment duration (where clearly reported) ranged from 15 days to 24 months. We assessed five studies as good quality,[56,89,114,120,121] three as fair quality,[22,131,135] and six as poor quality for effectiveness outcomes.[20,77,112,125,126,137]

Effects of Hysterectomy on Bleeding

Two studies reported increases in hemoglobin levels at 24 months after surgery.[20,114] The mean increase reported in the EMMY trial was statistically significant (2.03 g/dL; 95% CI, 1.44 to 2.61, $p<0.0001$).

Effects of Hysterectomy on Pain

Two studies reported pain or pressure outcomes. At 24 months after hysterectomy, 28 women (93%) reported total or substantial improvements in pressure symptoms. Lower abdominal pain decreased from 16 participants (53%) at baseline to three (10%) after 2 years.[20] A majority (78%) of the women who had lower abdominal pain at baseline reported improvement at 24 months after hysterectomy.[99] Of those without pain at baseline (n=14), one woman reported worsening of symptoms after hysterectomy.[99]

Other Treatment Effects of Hysterectomy

Return to Usual Activity

Mean time to return to work or usual activity ranged from 22 to 41 days as reported in four studies.[20,22,120,125] Women who received a vaginal or laparoscopic vaginal hysterectomy had a significantly faster recovery (mean 22 to 30 days) compared with total abdominal hysterectomy (mean 36 to 41 days) as reported in two studies[120,125] Mean recovery time for abdominal hysterectomy averaged 37 days in one study[22] and 35 days in another study that used a variety of surgical procedures.[20] We did not assess the strength of evidence for return to usual activities

Quality of Life and Symptom Status

Improvements in quality of life or symptom status were reported in four trials. Two studies reported short terms results (1-month after surgery) [112,121] and two studies reported results after 24 months.[77,93] Short-term results compared vaginal to abdominal hysterectomy in 179 women. Quality of life assessed by the SF-36 was better after vaginal hysterectomy than abdominal hysterectomy.[112] Patient satisfaction with treatment assessed using an unvalidated questionnaire was higher for women after vaginal than abdominal hysterectomy.[121] After two years, quality of life was significantly improved after hysterectomy in the EMMY trial[93] assessed by HRQOL and SF-36. A Chinese study reported improved quality of life two years after hysterectomy as measured by the WHOQOL-BREF questionnaire.[77]

Harms Reported in Studies of Hysterectomy

Transfusion

The proportion of women requiring transfusion following hysterectomy ranged from zero to 20 percent in 890 women from 11 studies (Appendix G, Table G-9). Six studies reported no significant difference in transfusion outcomes following different hysterectomy approaches for fibroids: laparoscopic-assisted vaginal versus total abdominal,[135] laparoscopic-assisted vaginal versus vaginal [56,131] laparoscopic-assisted vaginal versus total laparoscopic,[56]vaginal versus total abdominal, [112] vaginal versus total laparoscopic, [56] and total laparoscopic versus total abdominal,[125] Authors reported 5 percent (3/61) of patients randomized to laparoscopic hysterectomy with bipolar coagulation of uterine vessels or laparoscopic hysterectomy alone required transfusion.[126]

Thromboembolism

Two thromboembolic events (one pulmonary embolism and one deep vein thrombosis) were reported following hysterectomy in 227 patients from four studies that reported thromboembolism after hysterectomy (Appendix G, Table G-7).[22,114,121]

Perforation of Organs

Two studies (n=179) reported no organ perforation following different hysterectomy interventions for fibroids.[112,121] One RCT (n=122) reported that one woman randomized to total laparoscopic hysterectomy was converted to total abdominal hysterectomy because of intraoperative bowel injury.[125]

Hysterectomy Summary

There is low strength of evidence that women had improved quality of life following hysterectomy, regardless of surgical approach. Overall, patient satisfaction and recovery time following hysterectomy was better for women who received a vaginal hysterectomy compared with total abdominal hysterectomy, but the strength of this evidence was not graded. Harms, including the need for blood transfusion and organ perforation, were similar for all types of hysterectomy.

Hysterectomy or Myomectomy

We found three studies reported in six publications (one good quality[104] and two poor quality[14,148]) that randomized women to an arm that allowed either myomectomy or hysterectomy.

Quality of life was the primary outcome for two studies comparing UAE to surgery (myomectomy or hysterectomy). [14,104] In the REST trial, scores on the SF-36 and the EQ-5D for the surgery groups were significantly improved after 12 months.[17,71,82,104] In the trial by Jun and colleagues, there was limited improvement for the surgery group after 6 months as assessed by the SF-36 questionnaire. Scores were improved for the mental health and vitality measures only, while physical health, social function and emotional role were almost unchanged.[14]

One study compared a GnRH agonist to myomectomy or hysterectomy.[148] Symptom improvement and fertility outcomes were reported.[148] Three of five women who underwent myomectomy for infertility had term pregnancies.

Surgical Intervention Summary

The strength of evidence was low for improvement in quality of life after myomectomy and hysterectomy. We found insufficient evidence that myomectomy improves bleeding .Evidence is insufficient to assess the effectiveness of endometrial abalation in improving fibroid symptoms. With notable exceptions,[16,82,97] the majority of these studies did not follow patients beyond the postoperative period. Therefore, many studies did not report important patient outcomes such as change in fibroid-related pain or bleeding. Many of the studies with surgical or procedural interventions reported intermediate outcomes such as technical success, hospital length of stay, or estimates of blood loss related to the invasive procedure (e.g., postoperative hemoglobin, intra- or postoperative transfusion rate). While these are important measures, they do not provide evidence about patient-centered outcomes of surgery for fibroids such as relief from symptoms, improvement in quality of life, and sexual function.

Comparative Effectiveness Studies

Content of Literature for Comparing Effectiveness of Interventions

Direct comparisons of alternative treatment strategies are crucial to support informed decisions by women and their care providers. Direct comparative effectiveness studies provide unbiased comparisons by randomly assigning similar groups of women to different interventions and assessing the same outcomes with the same yardstick. When different approaches within the same category of intervention were compared (e.g., uterine artery occlusion vs. UAE, or myomectomy via laparoscopy vs. minilaparotomy) those findings are reviewed in the previous sections for each category.

In this section, we review comparisons across categories of interventions. In total we found 17 studies which compared the effectiveness of different categories of interventions.[14,16,20,22,57,68,73,77,81,84,102,104,113,114,127,137,165] Available comparisons are summarized in Table 24.

Table 24. Randomized trial comparisons across categories of interventions

Method	Medical	High Intensity Focused Ultrasound Ablation	UAE or Occlusion	Radiofrequency Ablation	Myomectomy	Hysterectomy	Count
	4[73,84,102,165]	0	0	0	0	1[137]	
			0	1[81]	1[68]	0	
			1[127a]	0	2[16,113]	5[14,20,22,104,114]	
					1[57]	0	
						1[77]	

UAE = uterine artery embolization

[a] Reviewed with surgical comparisons as vascular occlusion was done via laparoscope.

Comparisons of Medical Management

We identified four studies designed to compare outcomes across different categories of drugs.[73,84,102,152] One good quality study compared ulipristal acetate to leuprolide.[73] Two compared a GnRH agonist to cabergoline, which is a dopamine receptor agonist.[84,102] The fourth compared the levonorgestrel IUD to daily oral progesterone.[152] A single study randomized women interested in hysterectomy to immediate hysterectomy or goserelin to determine if medical management allowed some women to avoid surgery.[137] Overall, these studies were small and inadequately powered to provide definitive evidence; they are briefly described below.

Comparison of GnRH Agonist to Ulipristal Acetate

A single good quality, multisite European trial compared two doses of daily oral ulipristal to monthly injection of 3.75 mg leuprolide.[73] They recruited 307 women whose bleeding was severe enough that they were considering surgery. The three groups had similar outcomes for change in size of the three largest fibroids and improvements in pain and quality of life measures. The overall reduction in uterine size was superior for leuprolide. Across three arms, 5 mg and 10 mg of ulipristal achieved results at least as good, or better, than leuprolide for control of bleeding. In 90 percent, 98 percent, and 89 percent, respectively bleeding improved to normal as assessed by the standardized and validated pictorial blood loss assessment chart. The average time to absence of bleeding in women with complete cessation was shorter for ulipristal than leuprolide (5-7 days vs. 21 days) ($p<0.001$). Hot flashes were substantially more common among those receiving leuprolide (40% vs. 10%-11% in ulipristal arms). At 13 weeks the proportion of adverse events and individuals discontinuing medication were equivalent, though women in the leuprolide group had evidence of greater bone resorption as measured by biomarkers. Endometrial samples were benign in both groups. Forty-nine percent of these participants who had initially sought evaluation for surgery had not had surgery by the end of 6 months of followup. In a subgroup of these women, growth of fibroids at one month had resumed in some women who received leuprolide while at 6 months fibroid size remained reduced in the majority of women who received ulipristal. In summary, evidence was insufficient to choose between ulipristal and leuprolide, based on a single study with small numbers.

Comparison of GnRH Agonist to Cabergoline

The GnRH agonist used in these two small, poor quality studies (Diphereline) is not available in the United States, however similar drugs are. [84,102] Cabergoline is available in the United States for off-label use. In both trials, GnRH was given for one month and cabergoline for 6 weeks of treatment. Fibroid volume decreased in both groups and was not statistically different. [84,102 84,102 84,102 84,102 83,10179,97] Those on GnRH agonists were more likely to stop bleeding and to have hot flashes. In both arms bleeding days decreased compared with baseline, with the fewest days in the GnRH agonist arm.[84,102] Pain was similarly reduced in both groups.[84,102] Side effects of GnRH matched those reviewed above; cabergoline was associated with headaches and nausea in the first week of use.[84,102] Carbergoline side effects caused one woman to discontinue treatment, compared with none in the GnRH group.[84,102]

In summary, evidence was insufficient to choose between the GnRH agonist and cabergoline but them.

Comparison of Oral Versus IUD Delivered Progesterone

One poor quality Turkish study randomly assigned 30 women in each arm to daily norethindrone acetate or levonorgestrel IUD (LNG-IUD) among premenopausal women with fibroids who had declined surgery.[152]Visual blood loss scores improved by 6 months in both groups, with significantly greater improvement in the LNG-IUD group ($p=0.028$). Improvement in hemoglobin likewise occurred in both groups with a significantly greater improvement among those with an LNG-IUD ($p<0.01$). Women with the LNG-IUD were more satisfied and more likely to continue treatment than the oral treatment group.

This trial suggests that both norithindrone acetate and the LNG-IUD might improve bleeding even among women whose fibroid symptoms were considered appropriate for surgical intervention. However, evidence to choose between them is insufficient.

Comparison of Goserelin With Immediate Hysterectomy

Seventy-two premenopausal women older than 45, with at least one fibroid larger than 10 cm in diameter, heavy menses for three months or longer, and who were eligible for hysterectomy were randomized to immediate surgery (n=13) or treatment with a GnRH agonist (n=59) (goserelin 3.6 mg depo injection each month for three months) [137] Participants were followed for 3 years and allowed up to two more rounds of treatment if their bone mineral density was not at risk. Those on medication could opt for hysterectomy at any time. Twenty three of the 59 women assigned to medication, 39 percent (95% CI, 26 to 62), had continued to hysterectomy by the end of the third year.

In summary, some women may be able to use GnRH agonist therapy to delay hysterectomy. The quality of this study was judged to be poor in part because of lack of researcher and participant masking to assigned intervention; if participants were inclined to want surgery this bias would tend to increase the proportion who opted for hysterectomy rather than forestall that choice. The evidence is intriguing but insufficient to encourage selection of medication if hysterectomy is planned.

Comparisons of Procedures

Two studies compared HIFU to alternate interventions: one to radiofrequency ablation[81] and another to myomectomy.[68] The MRI guided HIFU system that is approved in the United States was not used in any direct comparison studies. Other direct comparisons of procedures included two comparisons of UAE to myomectomy,[16,113] three comparisons of UAE to hysterectomy,[20,22,114] and two comparisons of UAE to surgery (myomectomy or hysterectomy).[14,104]

Comparisons of HIFU for Fibroid Ablation to Radiofrequency Ablation

One RCT (n=100) of premenopausal women compared HIFU to radiofrequency ablation. However, the study reported only technical success (58% for HIFU vs 90% with radiofrequency ablation) Followup of fibroids and symptom resolution were not studied so evidence is insufficient to guide choice among these options.[81]

Comparisons of HIFU for Fibroid Ablation to Myomectomy

One RCT randomized women to HIFU vs. myomectomy. Fifty-five women were randomized to each arm; only results for women who completed followup (n=48 HIFU and n=52 myomectomy) are reported. Sexual function was comparable in both groups after 6 months of followup. Women having HIFU had shorter hospitalizations, earlier ambulation, and faster recovery; they had no blood loss and no surgery-related symptoms.[68,69] Fibroid outcomes and symptom resolution were not studied, therefore, evidence is insufficient to help women choose between options.

Comparisons of UAE to Myomectomy

Two European RCTs reported in three publications[16,21,113] compared UAE to myomectomy. The studies included 284 women ages 31 to 50 years; 96 percent of participants had symptoms, some had only fertility concerns. In total there were 121 embolizations and 122 myomectomies with followup. Technical success was similar.[21] as were improvements in quality of life (measured by UFS-QOL) one year after treatment, [16] and symptom relief (88% at an average of 17 months after intervention.)[113]

Length of stay is significantly shorter for UAE (averaging 2 days) compared with myomectomy (4 to 6 days).Blood loss was associated only with myomectomy.[16,21] Time away from work was at least 10 days shorter for those who had UAE compared with myomectomy.[21]

Around 2 years of followup, women in the UAE group had experienced more subsequent interventions (re-embolizations and myomectomies) compared with the myomectomy group (32.8% vs. 3.2%; p<0.0001).[21] However, subsequent intervention in the UAE group could have been driven by a protocol to recommend myomectomy if there was not reduction in fibroid size by 6 months or if or if a fibroid greater than 5 cm in size persisted. Risk of fibroid recurrence, satisfaction and quality of life are similar across groups. Thus, the likely cause of additional interventions among those with UAE was linked to the clinical protocol in this trial.

Reproductive outcomes were reported for 66 women (26 after UAE and 40 after myomectomy) in one study.[21,113] After 2 years pregnancy was significantly more common after myomectomy (78% vs. 50%; p<0.05) while miscarriage risk was higher after UAE (64% vs. 23%; p<0.05). Nineteen percent of women who had UAE had live births compared with 48 percent after myomectomy (p<0.05).[21] All participants in this study received care in a fertility clinic, for other underlying causes of infertility and treatment options included in vitro fertilization. As a result findings may not represent the general population of women with fibroids who plan to conceive.

In summary, two small studies of fair quality suggest UAE achieved similar results to myomectomy with a shorter recovery time. Because of low power to detect differences in outcomes, the evidence is insufficient to determine if outcomes are better after myomectomy compared to UAE. Women who have UAE may be more likely to have future interventions though this may have been driven by clinical protocol in these trials. Evidence is insufficient to guide choice between these options.

Comparisons of UAE to Hysterectomy

Three RCTs comparing UAE with hysterectomy are published in 12 reports. Study participants were all from Europe. The EMMY trial[19,70,91,93,96,97,99,109,111,114] is a multicenter trial (28 hospitals) conducted in the Netherlands. A Spanish trial by Pinto and colleagues[22] and a trial from Finland by Ruuskanen and colleagues[20] were single-center trials. Combined, these studies included 291 women aged 33 to 57 years with symptomatic uterine fibroids, who were candidates for hysterectomy. The EMMY trial excluded women with submucosal leiomyoma while the Spanish trial excluded women with leiomyomas larger than 10 cm in diameter. The third trial [62]did not exclude women based on the size or location of fibroids. Across studies, 153 women were allocated to UAE and 138 to hysterectomy. Followup duration of these three trials varied from 6 months[22] to 2 years[20,22] and 5 years.[19]

Early Procedure Outcomes and Recovery

Blood loss from the procedure was negligible for UAE and higher for hysterectomy.[114] In the surgical group of the Finnish trial,[20] 19 percent of the vaginal or laparoscopic hysterectomies were converted to abdominal hysterectomy due to technical difficulties; and the EMMY trial reported four conversions of laparoscopic or vaginal hysterectomy to laparotomy (5.3%)[114] Length of hospital stay was shorter (p<0.001) for UAE (1.3 to 1.7 days) compared with hysterectomy (3.5 to 5.9 days).[20,22,114] Re-admission rates were the same (5%) in both arms of the Spanish study[22] while the EMMY trial reported significantly higher near term re-admission rates after UAE (11% vs. 0%, p<0.003) compared with hysterectomy.[109,114] Despite this, time to return

to usual activities was significantly (p<0.001) shorter in the UAE group (fewer than 20 days) compared with hysterectomy group (more than 30 days).[20,22,114]

Fibroid Characteristics

By definition, women who have hysterectomy have 100% reduction in fibroids. For the UAE groups, effects on fibroid characteristics are included in Table 16.

Bleeding

By definition, women who have hysterectomy stop bleeding. Improvement in bleeding in the UAE arms is included in Table 17. Increase in hemoglobin levels from baseline at two years was significantly higher for the hysterectomy group compared with the UAE group (+2.03 vs. +1.37 g/dL; p=0.037) in EMMY[99] but not in the Finnish trial (p=0.16),[20] which may reflect inadequate power to detect modest differences.

Symptoms

Overall relief of symptoms was good across groups (82% UAE vs. 93% hysterectomy; p=0.173) in the Finnish study at 2 years.[20] For both groups, there was a significant decrease in pain from baseline at all time points (p≤0.03) and by 24 months women reported similar improvement of pain (84.9% after UAE vs. 78% after hysterectomy; p=0.30).[99] Greater improvement in pressure symptoms was reported after UAE compared with hysterectomy (95% vs. 69%; p=0.03).[20] More urinary bladder symptoms were reported after hysterectomy than after UAE (30% vs. 7%; p=0.03).

Quality of Life

In the EMMY trial, overall health related quality of life improved in both trial arms and was comparable across groups by completion of 5 years of followup.[19] One secondary outcome (change in bowel movements) was worse in the hysterectomy group than UAE at 5 years from baseline (p=0.01) while the UAE group had improvement from 6 month onwards.[19] At 6 months, body image scores improved significantly more in UAE group than in hysterectomy group (p=0.02), but there was no group difference in body image or sexual function scores at 24 months or later.[19]

Subsequent Treatment

Three studies assessed subsequent treatment at 6 months to 5 years. Subsequent treatment was higher in the UAE group than in the hysterectomy group at each time point in followup.[16,20,114] At 6 months, 1-year, 2-year, and 5-year followup, the EMMY trial reported significantly higher rates of any subsequent gynecologic intervention (9.8%, 17.3%, 28.3%, and 34.6%) after UAE versus 1.3 percent, 5.3 percent, 8.0 percent, and 10.7 percent after hysterectomy.[19] The risk of additional intervention was reported at 2-year followup in another study (19.2% with UAE and 10.3% after hysterectomy; p=0.24).[20] Some early reinterventions are repeat UAE, myomectomy, or hysterectomy among the small percentage of women (1.0% to 4.9%) for whom effective occlusion of the uterine vessels could not be achieved at the time of the initial procedure.[16,114] These data are included in the meta-analysis of subsequent intervention section.

Compared to women with UAE, women who received hysterectomy reported higher satisfaction rates after 1 (p=0.001) and 2 years (p=0.02) but satisfaction levels for both groups were comparable by 5 years (p=0.13) (Table 25). Forty six percent of women after UAE and 56

percent of women after hysterectomy were very satisfied with the outcome by 5 years (overall satisfaction, 84% vs. 88%; p=0.37).

Table 25. Satisfaction in studies of uterine artery embolization versus hysterectomy

Measure Author (Year)	Time Point, Month	UAE, Percent	Hysterectomy, Percent	Significance
Satisfied[a]				
Hehenkamp WJ et al. (2008)[19,93,114]	12	84.0	86.7	p=0.001[b]
	24	91.4	88.0	p=0.02[b]
	60	85.3	88.6	p=0.13[b]
Would undergo same treatment				
Pinto I et al. (2003)[22]	6	77.7	88.2	NR
Ruuskanen A et al. (2010)[20]	24	88.9	96.7	p=0.34

NR = not reported; NS = not significant; UAE = uterine artery embolization

[a] Satisfied from the EMMY trial includes very satisfied, satisfied, and moderately satisfied.
[b] P-values reported for comparison across seven possible levels of satisfaction that include very satisfied and satisfied.

Reproductive Status

Ovarian reserve, pregnancy, and sexual function related outcomes were reported only in the EMMY trial.[97] Reduction in ovarian reserve was based on FSH and AMH hormone levels. Levels of FSH, suggesting diminished reserves, increased from baseline (p=0.001) in both groups at 24 months followup but there was no group difference (p=0.32). The number of women with FSH >40 IU/L, confirming menopause, at 24 months was 14/80 (18%) in the UAE group compared with 17 women (21%) in the hysterectomy group, with no differences over continued followup (p=0.37). The change scores of AMH levels from baseline were significantly different between the groups only at 6 weeks of treatment (p=0.005) and the AMH levels remained decreased only in the UAE group during the followup.

Harms

Harms are reviewed for each category of intervention within the sections for UAE and specific surgeries above and in Appendix G.

Summary

Compared to hysterectomy, UAE provides similar relief of pressure and pain symptoms, similar improvements in quality of life, and fewer side effects. Though subsequent intervention is more common after UAE than hysterectomy, the majority (66%) of women randomly assigned to have UAE avoided hysterectomy for the duration of followup, which included up to 5 years of surveillance in the largest study. However, at present evidence is insufficient to shape clinical decisions.

Comparisons of UAE to Patient Choice of Myomectomy or Hysterectomy

A larger trial of good quality conducted in the United Kingdom[104] and a poor quality study conducted in China[14] made this comparison. Combined, these studies randomly assigned 169 women to UAE and 115 women to conventional surgeries for uterine fibroids.[14,104] Both found UAE to have shorter hospital stay and recovery time. UAE was associated with fewer

complications at the time of the procedure but a greater proportion of women had a subsequent intervention in followup. Similar to the studies detailed above, the study that included 1-year followup reported that among women assigned to UAE, 12.6 percent had subsequent interventions for inadequate control of symptoms. In the UK trial, quality of life (measured by the SF-36) at 1 month the UAE group had significant improvements in multiple areas of function, however by one year improved similarly in both groups.

In summary, these studies contribute to a growing body of evidence that UAE has a shorter recovery and is as effective as surgery in major domains of patient outcomes. The primary caveat is that this comes with risk of subsequent intervention, which is also addressed in our meta-analysis.

Comparisons of Surgeries

The majority of surgical studies that made comparisons did so within a category of intervention, for instance comparing myomectomy conducted by laparoscopy to myomectomy through a laparotomy incision. These are reviewed within categories of interventions above and when clinically and statistically significant advantages have been demonstrated they are noted. Comparisons across types of surgical interventions were meager, and the three related studies are noted below.

Comparison of Laparoscopic Bipolar Coagulation With and Without Uterine Nerve Ablation

In this small (n=85), poor quality study of women with fibroids and menstrual pain, 41 women were randomly assigned to also have laparoscopic uterine nerve ablation at the time of laparoscopic occlusion (bipolar coagulation) of the uterine vessels.[127] Both groups had equal reduction in size of fibroids and in reduction of bulk symptoms. Women in the nerve ablation group had less postoperative pain at 1 month as measured by a non-standardized five-point scale ($p<0.05$) and by 6 months painful menses were improved in 92.1 percent of the nerve ablation group compared with 73.8 percent of the occlusion only group ($p<0.05$).[127] The results are insufficient to inform a decision to include uterine nerve ablation at the time of coagulation of the uterine vessels.

Comparisons of Radiofrequency Ablation With Laparoscopic Myomectomy

A small study, reported in three publications, compared laparoscopic use of radiofrequency (n=26) to laparoscopic myomectomy (n=25).[57,154,159] Ultrasound was performed during the procedures to definitively identify fibroids and document immediate intervention outcomes. Intermediate outcomes (technical success, blood loss and length of stay) were better in the radiofrequency group compared with the myomectomy group [57]At 1 and 2 years, both groups experienced improvements in health related quality of life and symptom severity as assessed by UFS-QOL and EQ-5D scores. The majority of women were moderately or very satisfied with their treatment at 12 months (86% in both groups).[159] Three pregnancies, culminating in three live births were noted for the radiofrequency ablation group and six pregnancies (four live births, one induced abortion, and one ongoing) were reported for the myomectomy group.[154]

Radiofrequency appears to offer some advantages to myomectomy, but there is insufficient evidence to determine clinical decisions.

Comparisons of Myomectomy Plus Uterine Artery Occlusion with Hysterectomy

A single moderate size study of poor quality conducted in China compared laparoscopic uterine artery occlusion (n=158) plus myomectomy to supracervical hysterectomy (n=174).[77] Supracervical hysterectomy is rarely performed in the United States. This RCT assessed quality of life using the WHOQOL-BREF. At two months after surgery, physical and social domains were superior in the myomectomy plus occlusion compared with the hysterectomy groups; no other areas were meaningfully different. By two years, myomectomy plus occlusion was superior to hysterectomy in all domains except environment ($p<0.01$) and both study groups had meaningful improvements compared with their baseline. Women treated with myomectomy plus uterine artery occlusion had a 2.5 percent fibroid recurrence rate.

In summary this single study provides insufficient strength of evidence that myomectomy plus uterine artery occlusion differs from supracervical hysterectomy for improving quality of life in physical, psychological, and relationship domains.

Comparison of Transfusion Requirements

Transfusion was reported in 40 arms across 23 studies. Transfusions by intervention category are summarized in Table 26.

Table 26. Transfusion by intervention category

Intervention Category (Number of Arms)	Women Transfused	Total N	Percent
Hysterectomy (18)	36	785	4.6
Hysterectomy or Myomectomy (1)	4	20	20.0
Myomectomy (18)	18	1,286	1.4
Uterine artery embolization (3)	0	158	0
All (40)	58	2,297	2.5

Analysis of Subsequent Treatment Following Initial Treatment for Uterine Fibroids

We estimated the probabilities of subsequently receiving additional treatment for fibroids after randomization to a given initial treatment of medication, UAE, or myomectomy for uterine fibroids from data reported in in 46 studies (Table 27).[13-16,20,22,23,54,57,64,66,79,80,84,85,87,92,98,100,102,104,105,107,110,113,114,118,122,123,127-129,134,136,140,148,150,151]

Subsequent treatments were grouped into these categories: 1) no intervention; 2) LNG-IUD; 3) UAE; 4) HIFU for fibroid ablation; 5) myomectomy, and 6) hysterectomy (Appendix H). Rates of subsequent intervention ranged from zero up to 44 percent. For women in their 30s, the model predicted that the probability of subsequent intervention for fibroids over 2 years varied from 6 to 7 percent after medical treatment or myomectomy to 44 percent after UAE. For women in their 40s and 50s, modelled 2-year reintervention rates were 9 to 19 percent following medical treatment or UAE, and 0 percent after myomectomy. Overall, fewer than half of women had another intervention within 24 months. Rates of subsequent intervention were lowest for initial medical management and higher following myomectomy or UAE. UAE was most often followed by myomectomy among those in their 30s and by hysterectomy among those in their 50s. Younger women who initially had myomectomy were most likely to have repeat myomectomies over the 2 years of followup. After medical treatment, few (6-11 percent) women in any age

group had subsequent treatment within 2 years. Appendix G includes data for subsequent treatment at up to 6 and 12 months of followup.

Table 27. Estimated probability of subsequent treatment by age at up to 24 months of followup

Initial Intervention	Next Intervention Age	None	LNG IUD	UAE	HIFU for Fibroid Ablation	Myomectomy	Hysterectomy
Medical	**30**	0.94 (0.89 to 0.97)	0.00 (0.00 to 0.00)	0.00 (0.00 to 0.00)	0.00 (0.00 to 0.00)	0.00 (0.00 to 0.00)	0.06 (0.03 to 0.11)
	40	0.91 (0.89 to 0.94)	0.00 (0.00 to 0.00)	0.00 (0.00 to 0.00)	0.00 (0.00 to 0.00)	0.00 (0.00 to 0.00)	0.09 (0.06 to 0.11)
	50	0.89 (0.85 to 0.92)	0.00 (0.00 to 0.00)	0.00 (0.00 to 0.00)	0.00 (0.00 to 0.00)	0.00 (0.00 to 0.00)	0.12 (0.08 to 0.15)
UAE	**30**	0.56 (0.43 to 0.69)	0.00 (0.00 to 0.00)	0.05 (0.01 to 0.11)	0.00 (0.00 to 0.00)	0.37 (0.23 to 0.51)	0.01 (0.00 to 0.04)
	40	0.88 (0.84 to 0.92)	0.00 (0.00 to 0.00)	0.02 (0.01 to 0.03)	0.00 (0.00 to 0.00)	0.03 (0.01 to 0.06)	0.06 (0.04 to 0.10)
	50	0.81 (0.70 to 0.90)	0.00 (0.00 to 0.02)	0.00 (0.00 to 0.01)	0.00 (0.00 to 0.00)	0.00 (0.00 to 0.01)	0.18 (0.09 to 0.29)
Myomectomy	**30**	0.93 (0.77 to 1.00)	0.00 (0.00 to 0.00)	0.00 (0.00 to 0.00)	0.00 (0.00 to 0.00)	0.07 (0.01 to 0.22)	0.00 (0.00 to 0.01)
	40	1.00 (0.99 to 1.00)	0.00 (0.00 to 0.00)	0.00 (0.00, 0.00)	0.00 (0.00 to 0.00)	0.00 (0.00 to 0.01)	0.00 (0.00 to 0.01)
	50	1.00 (0.89 to 1.00)	0.00 (0.00 to 0.00)	0.00 (0.00 to 0.00)	0.00 (0.00 to 0.00)	0.00 (0.00 to 0.010)	0.00 (0.00 to 0.06)

Notes: Table reports estimated probability (95% credible interval)
HIFU = high intensity focused ultrasound; LNG IUD = levonorgestrel intrauterine device; UAE = uterine artery embolization

Key Question 2. Influence of Patient/Fibroid Characteristics on Effectiveness

Key Points

- Among 97 RCTs of interventions, none were explicitly designed to address whether intervention effectiveness varied by patient or fibroid characteristics.
- Six studies provided some information about influence of characteristics on outcomes within or across arms.

Description of Studies

For this KQ we systematically reviewed all included trials (n=97) for each category of intervention. We sought: (1) indication that the study aimed to determine the influence of patient or fibroid characteristics on effectiveness and/or (2) described statistical analyses that allowed determination of whether patient of fibroid characteristics modified outcomes.

At its core, this question is about effect modification, also called interaction, which can be used to inform clinical decisions. For instance if women with five or more fibroids are found to have less improvement of their hematocrit 6 months after an intervention than those with fewer than five initial fibroids, and the p-value for that comparison is significant, we would say there is modification of the effectiveness of the intervention by fibroid number, such that women with fewer fibroids may experience superior improvement in hematocrit. No studies were explicitly powered to investigate effect modification.

We identified only six trials that contributed related analyses: two trials of medications (in three publications),[115,119,123] two studies that compared UAE to surgery, each with multiple publications (REST[71,82,104] and EMMY[19,109,114]), and one surgical trial.[107] One additional study addressed whether baseline characteristics influenced likelihood of success across procedure arms.[81] We assessed two studies as good quality,[19,71,82,104,109,114] two as fair quality,[115,119,123] and two as poor quality.[81,107]

Detailed Synthesis of Effect Modifiers

Medical Intervention

In a dose comparisons trial of oral mifepristone (5 mg vs. 10 mg), the authors reported no difference in uterine fibroid volume size when analyses were adjusted for baseline volume, dose, and treatment duration (6 or 12 months). There was no significant difference in uterine volume reduction between the two dose groups (p=0.94). However in pooled analyses, for every 10 cm^3 larger increment in baseline fibroid volume, fibroid volume reduction increased, on average, by 3.8 cm^3 after adjusting for dose and time (95% CI, 2.7 to 4.9; p<0.001).[115]

Within a raloxifene arm (60 mg for six cycles) authors found the drug demonstrated selective action on leiomyoma by menopausal status, such that postmenopausal women were more likely to achieve decreased uterine and fibroid size. Thirteen of 31 postmenopausal women had decreased size of fibroids[128] compared with one of 29 premenopausal women.[123]

Procedures

Uterine Artery Embolization

In one followup publication from the REST trial comparing UAE to surgery (hysterectomy or myomectomy), the authors found that 5-year reintervention rate after UAE did not differ (p=0.123) by the degree of infarction achieved during the initial procedure, as measured by MRI.[71] Study authors reported no effect of age (p=0.77), uterine volume (p=0.50) or fibroid diameter (p=0.57) on the degree of infarction as measured by MRI at 6 months. Similarly, age (p=0.13), uterine volume (p=0.81) and fibroid diameter (p=0.81) did not modify the need for reintervention.[71] The presence of a single fibroid (OR=6.21; 95% CI, 1.65 to 23.41) and small uterine volume (less than 500 cm^3) (OR=10.8; 95% CI, 1.25 to 93.36) were associated with higher risk of procedural failure.

The finding of no significant group difference in the rate of ovarian failure as measured by FSH >40 IU/L at 1 year after treatment (UAE vs. any surgery) was not modified by age less than 45 years or age of 45 years and older.[82] The risk for major complications (OR=5.68; 95% CI, 2.05 to 15.75) and high pain scores (higher than score of 5) (OR=1.97; 95% CI, 1.08 to 3.58) increased with each extra vial of polyvinyl alcohol used, though there was no significant association (p=NS) between high pain scores and uterine size, fibroid size, or total number of fibroids at 6 weeks after the procedure.[109]

A multivariate analysis indicated that compared with baseline, after 24 months of treatment, higher number of fibroids was associated with lower risk of poor sexual function (OR=0.69; 95% CI, 0.51 to 0.94); while the presence of a comorbid condition was associated with an increased risk of a worse sexual function (OR=3.2; 95% CI, 1.38 to 7.41).[96]

HIFU for Fibroid Ablation

A study comparing radiofrequency fibroid ablation to HIFU for fibroid ablation examined intermediate outcomes across groups by fibroid characteristic (fibroid blood supply and size).[81] The rate of complete ablation was significantly different between groups with different grades of blood supply. The radiofrequency ablation technical success rate was 89.3 % versus 54.2 % among individuals with Grade II blood supply (direct vessels to fibroid readily visualized). No difference was seen within groups with no clear blood supply or widespread "halo" like blood supply; however the size of this trial was too small for meaningful assessment of true effect modification (total n =100). Completeness of ablation was similar among the subgroups of patients with fibroid diameter between 2 cm and 4 cm, whereas the technical success for radiofrequency ablation was superior to HIFU in patients with fibroid diameters between 4 and 6 cm and between 6 and 8 cm ($p<0.05$).[81]

Surgical Interventions

An RCT with 181 women with fibroids who had been trying to conceive for at least 1 year without success, subdivided the women according to the location of the fibroid (i.e., submucous, intramural, subserosal) and randomized to myomectomy (laparoscopic myomectomy or hysteroscopic myomectomy) or no surgery.[107] For women with subserosal or intramural fibroids, there was no significant difference in the pregnancy rate, comparing myomectomy with no treatment. For women with submucous fibroids, the group who underwent myomectomy had a greater pregnancy rate (40.4%) than those who did not undergo surgery (21.4%) ($p<0.05$).[107]

Summary of Effect Modification

Overall, there is insufficient evidence for women to choose one intervention over another based on individual characteristics or the characteristics of their fibroids. Too few studies have been adequately powered to determine within arms if one subgroup or another has superior outcomes within a treatment. Such information is required as a first step towards using individual characteristics to inform treatment choice.

Key Question 3. Risk of Leiomyosarcoma When Mass Thought To Be a Fibroid

Key Points

- The overall risk of discovering a leiomyosarcoma during surgery for presumed fibroids is 0.02 percent (range: 0% to 0.09%) in prospective studies and 0.08 percent (range: 0.05% to 0.13%) in retrospective studies. In other words, using data from 160 studies, an unexpected leiomyosarcoma will be identified in fewer than one and up to 13 of every 10,000 surgeries performed for symptomatic fibroids.

Overview

The risk of fragmenting and disseminating a leiomyosarcoma into the pelvic cavity is at the heart of the FDA and professional organizations concerns about the safety of power morcellation. The defining component of this risk is determining how likely it is that a surgeon who is operating for a fibroid encounters a leiomyosarcoma. To address KQ3 we pursued evidence in the literature to

estimate the prevalence of uterine leiomyosarcoma among women having surgery for uterine fibroids.

Description of Studies

We sought literature from studies of myomectomy or hysterectomy for presumed benign disease that included histopathologic analysis of all excised fibroid specimens. In the course of our work, Elizabeth Pritts and her colleagues published such an estimate using a similar approach, with a stated aim to estimate the prevalence of occult leiomyosarcoma at time of treatment for presumed benign tumors (fibroids).[10] We confirmed our search method included their articles and then updated their search using similar eligibility criteria to identify papers published since the end of their inclusion period in 2014. In addition to the 133 unique studies included in the prior analysis, we identified 27 additional studies, including twenty-four retrospective cohorts,[170, 172-194] two prospective cohorts,[195,196] and one RCT.[197] The RCT was included with the prospective studies in the analysis.

Detailed Synthesis

The 2015 Pritts analysis extracted data from 133 publications including 30,193 women.[10] The 27 new studies included an additional 106,002 women bringing the total to 160 studies and 136,195 women. Among prospective studies 56.7% focused on myomectomy findings; 35.8% hysterectomy, and 6.0% both types of surgery. Among retrospective studies 31.9% focused on myomectomy; 48.9% hysterectomy, and 19.2% both. Over 40,000 (29%) of the included women are from prospective studies. In prospective studies, subjects had an age range of 20 to 83 with a mean age of 38.5±6.0 years, while retrospective studies included women from age 18 to 96 with a mean age 43.4±5.6.

Following methods described in Pritts and colleagues[18] we fit a Bayesian binomial random effects models to update the estimate of prevalence of leiomyosarcoma and achieved good model fit. The point estimates and credible intervals for prevalence are summarized below for the original Pritts study and for our five new models. (Table 28)

We identified some errors in counts from the data extraction in the Pritts analysis. [10] We ran analyses with the original (model 1) and corrected data (model 2). We added data from 27 new studies (model 3, most inclusive, largest data set). Then, we excluded prospective studies that included hysteroscopic fibroid resection because of concerns that hysteroscopy might yield incomplete tissue for pathology (model 4). Because we had noticed some discrepancies, we reviewed all publications and reclassified them based on our confidence that complete histopathologic evaluation was performed for all subjects. We attempted to contact authors to confirm when necessary. For model 5, we restricted our analysis to those publications for which we had high confidence of complete histopathologic evaluation for every subject, as the most refined estimate (model 5).

We present estimates for prospective and retrospective studies separately since statistical models suggest meaningful heterogeneity is introduced by study design. Regardless of model assumptions, all estimates from retrospective data produced higher estimates (5.1 to 8.5 cases per 10,000 surgeries) than prospective studies (0.5 to 2.9 cases per 10,000 surgeries). An aggregate estimate combining both retrospective and prospective studies is 8.3 per 10,000 surgeries (95% CI: 1.17, 9.39) but this model is difficult to interpret because assessment of statistical heterogeneity suggests the estimates are distinctively different, thus a combined estimate is not appropriate. We have greater confidence in the ability of prospective studies using standardized

protocols to evaluate histology to detect incident cases than retrospective studies that rely on clinical pathology reports and retrospective determination of inclusion. Although we planned to estimate the effect of age on leiomyosarcoma risk, the lack of granular data (especially for non-cases) prevented us from doing so.

In her report, Pritts repeated the FDA analysis using a Bayesian binomial model. [10,24] To keep comparisons on the same scale, we plot these two published estimates on the same Bayesian binomial scale as our conservative model 3 (Figure 5.) While the point estimates differ, confidence intervals overlap.

Table 28. Leiomyosarcoma prevalence estimates

Model	Data Source Included in Analysis	Prevalence Estimate per 10,000 Surgeries (95% Credible Interval)	
Original		**Prospective**	**Retrospective**
	Pritts analysis[18]	1.2 (0 to 7.5)	5.7 (1.7 to 11.3)
Updated models:			
1.	Replication of Pritts analysis with raw data	2.9 (0 to 10.6)	5.1 (1.3 to 9.6)
2.	Pritts analysis using corrected data[a]	2.1 (0 to 9.3)	5.1 (0.9 to 9.4)
3.	Studies in Pritts analysis (corrected data) plus new studies[b]	2.1 (0 to 9.4)	8.5 (4.7 to 12.7)
4.	Studies in Pritts analysis (corrected data) plus new studies, excluding hysteroscopy	0 (0 to 0)[c]	7.2 (3.1 to 11.5)
5.	Studies in Pritts analysis (corrected data) plus new studies; restricted to studies with high confidence of histopathologic evaluation for all subjects	0.5 (0 to 2.9)	7.4 (3.4 to 12.2)

[a] We identified some errors in counts from the data extraction in the Pritts analysis.[10] We ran analyses with and without these corrections as indicated.
[b] Studies meeting inclusion criteria and published since the publication of the Pritts analysis.
[c] Estimate and credible interval below 1 in 10,000.

Figure 5. Risk of leiomyosarcoma at surgery for presumed fibroids

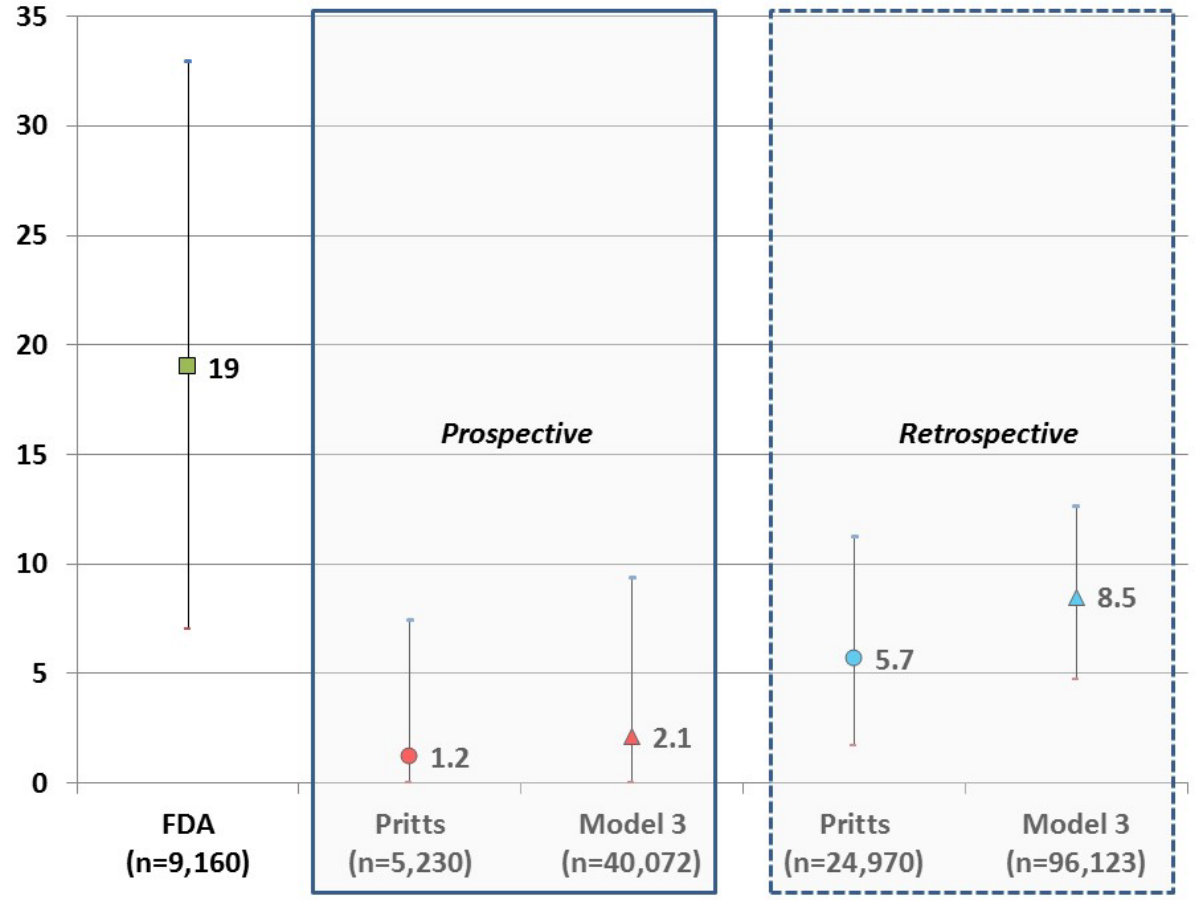

Notes: Point estimates (cases per 10,000 surgeries) and 95% credible interval for published estimates[10] and current model. Grouped by prospective (solid box) vs. retrospective (dashed box) study design. N= number of women included in each analysis. FDA indicates estimates from earlier Food and Drug Administration summary document.[24,40]

Summary

The literature investigating the prevalence of leiomyosarcoma in presumed fibroids has grown rapidly and has added more data but not greater precision to estimates of this rare event. From 160 prospective and retrospective studies, the estimate of leiomyosarcoma ranges from 0 to 13 cases out of 10,000 surgeries. Our estimate based on 68 prospective studies biased in favor of detection (model 3), estimates that two (range: fewer than one and up to 9) women in every 10,000 who have surgery for fibroids may be found to have a leiomyosarcoma.

Key Question 4. Influence of Morcellation and Patient/Fibroid Characteristics on Leiomyosarcoma Survival

Key Points

- Uterine leiomyosarcoma has high mortality regardless of surgical approach.
- For women with uterine leiomyosarcoma, survival time appears shorter for those where power morcellation was used compared to those where sharp morcellation with a scalpel was

used or to those who had intact removal of the uterus (no morcellation), however, confidence intervals are wide and overlap.

- We found insufficient data on the influence of patient or fibroid characteristics on leiomyosarcoma survival.

Description of Studies

Twenty-eight studies (29 publications) provided data about disease progression and vital status for women who had a leiomyosarcoma identified at the time of an initial surgery and for whom the method of removal of the surgical specimens was known and survival time data could be extracted.[170-172,177,184-192,194,198-212] The research was conducted in 14 different countries, including nine from the United States. The largest studies were from Norway and the United States. The majority identified baseline surgical data and outcomes after the events had occurred or relied on prospective registries and were able to provide followup for participants present at baseline. These studies included 715 women with leiomyosarcoma and the time of their initial surgeries ranges from the 1980s through 2015. This overlaps well with the period of growth in minimally invasive surgery for fibroids and with the use of power morcellation.

We reviewed studies for information about whether individual characteristics of the women or presumed fibroid status helped to identify those most at risk of harm. Similar to KQ2, we sought evidence that investigated effect modification by factors such as age, menopausal status, and imaging characteristics which can be known before surgery and have potential to inform decisions about surgical approach. Twenty-four studies (384 women) contributed data to models to compare survival time based on use of power morcellation, scalpel morcellation, or no morcellation. For studies that did not explicitly provide individual survival data[186,194,199,207] we were able to manually extract data from published survival curves using an online digitizing tool.[213] Another four studies (reported in five publications) provided information about survival, but we could not confidently extract data to include in the analysis because we either could not determine event times with confidence[170,171,198,204] or because the data in the tables and text did not align with those shown in the survival curves.[208]

Detailed Synthesis

Our purpose for this aim was to determine if leiomyosarcoma dissemination was influenced by method of morcellation and to compare this with no use of morcellation while also assessing characteristics of patients and fibroids that might be associated with risk of dissemination.

There is no clinical way to detect dissemination of leiomyosarcoma at the time of surgery. If the tumor is disrupted, both visible and microscopic particles may be spilled. However, even without visible tumor disruption, microscopic or hematogenous dissemination may occur. As a result, stage of disease, progression or recurrence of disease, and survival become surrogates for recognizing dissemination. Thus we hypothesize that stage and survival would be worse for those in whom leiomyosarcomas were removed by power morcellation compared with scalpel morcellation and that both of these would be inferior to no breach of the integrity of the tumor by removing the tumor intact.

To estimate survival for each surgical intervention, we fit parametric survival models using a Bayesian hierarchical approach, using the data extracted from publications that made it available. To account for heterogeneity among studies, we included a study-level random effect in the hierarchical baseline survival parameter. A simple exponential survival function was found to be a poor fit to the data, therefore we fit a Weibull survival function that resulted in an adequate fit.

Figure 6 captures cumulative hazard estimated by these models, with the shaded areas indicating the 95% Bayesian credible intervals (BCI) for each intervention group: no morcellation, scalpel morcellation and power morcellation.

Figure 6. Estimated survival after surgical intervention for leiomyosarcoma by morcellation approach

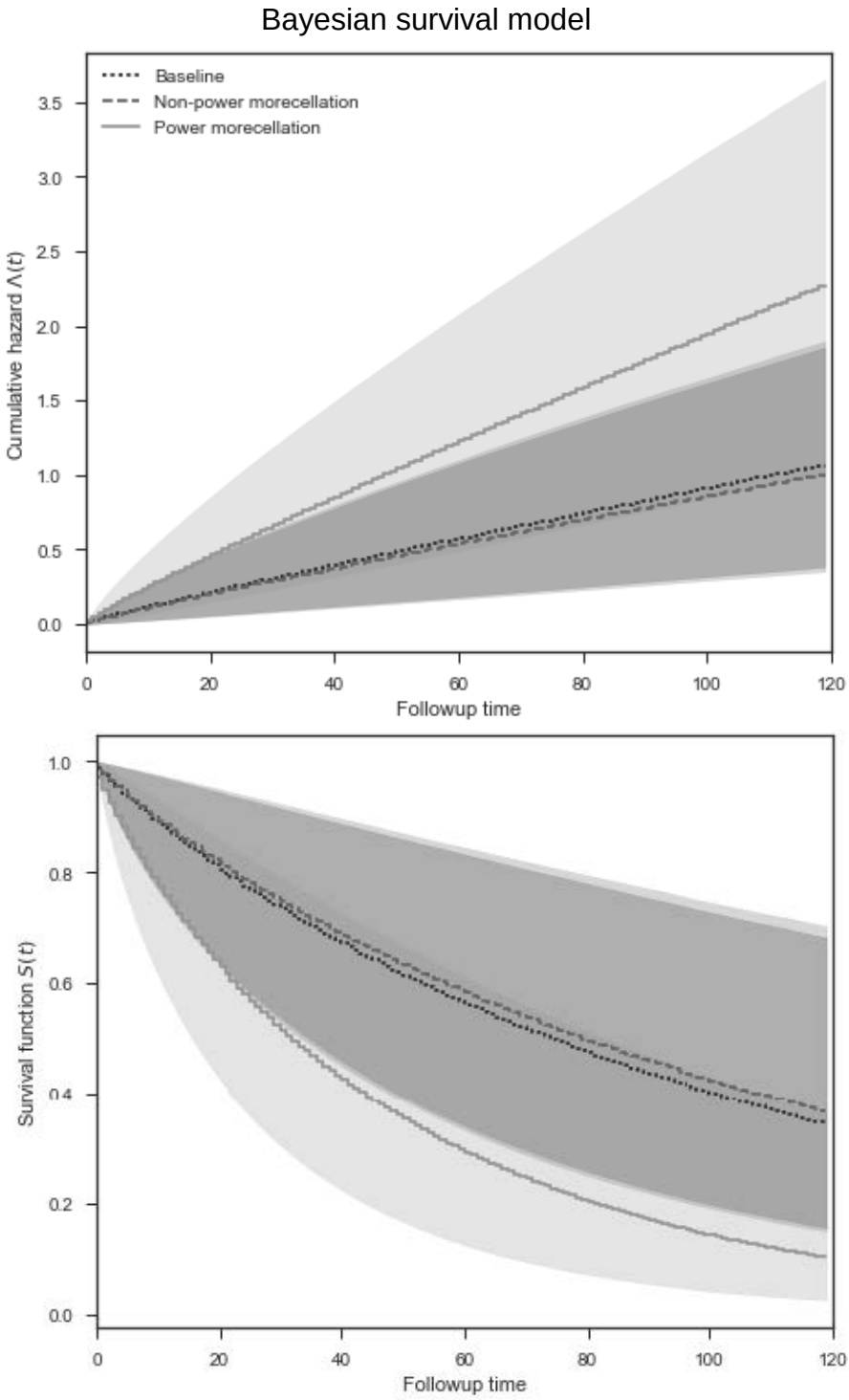

Notes: Survival curves plot x-axis as follow up time in months with hazard ratio indicated by y-axis. Dotted line indicates baseline comparison which is no use of morcellation. The darkest grey shading shows the 95% credible interval. Non-power morcellation is indicated with dashed line and medium grey shading for credible interval. Power morcellation is solid line with pale grey credible interval shaded.

By 5 years of followup (60 months), a typical interval considered in cancer outcomes, 30% (95% BCI, 13% to 61%) of women for whom power morcellation was used were alive. This is compared to 59% (95% BCI, 33% to 84%) of women for whom scalpel morcellation was used and 60% (95% BCI, 24% to 98%) with no use of morcellation. While the point estimate of power morcellation survival was much lower than for either non-morcellated or scalpel morcellation patients, the uncertainty in these estimates was very large, particularly at longer followup times. However this literature is evolving rapidly and more than half of the cases and papers that contribute to our estimates have appeared in the literature in 2015 or 2016.

Five papers, as described below, did not contribute to our estimates. Two small studies, one with 18 cases of leiomyosarcoma,[198] the other with 56 cases spread over 21 years,[208] suggested increase in disease recurrence and worse survival after morcellation. In contrast, a final paper that did not report individual level data that could be extracted identified 53 patients with leiomyosarcoma and found rates of pelvic recurrence did not differ by use of morcellation at three or six months of followup with comparable disease-free survival rates in both groups.[204] Three studies did not present data in a way to allow inclusion in our aggregate survival estimates. They include the findings of a recent review and lifetable analysis by Pritts and colleagues[214] and an analysis of data from Norway.[170,171] These studies do not find a statistically meaningful disadvantage to morcellation when aggregate data are used to calculate survival.

Individually, few authors had sufficient number of cases to address differences in risk of dissemination or survival by other characteristics of the women found to have leiomyosarcoma at the time of surgery for presumed fibroids. If we consider only those studies with more than 10 cases with scalpel or power morcellation, only five publications with total size of 15 to 56 participants have potential to contribute information.[199,204,207,208,215] Two do not provide adjusted multivariable models or stratification by characteristics other than operative approach.[215,216] None report assessment of effect modification by any trait other than surgical approach to removal of the uterus or fibroids.

Characteristics reported not to confound the association between risk of dissemination and outcome in multivariable time-to-event models included: age,[207,208] menopausal status,[207,208] adjuvant treatment including radiotherapy,[207,208] and BMI.[208] In the publications authored by Perri and Park, only surgical approach (grouped as total abdominal hysterectomy or other approaches with any morcellation or breech of the tumor capsule) compared to removal intact significantly influenced outcomes.[207,208] Lin and colleagues adjusted for age, tumor size, and mitotic count, but including these covariates in the model did not meaningfully change estimates.[199] Thus, this literature lacks information to identify those most likely to have a more aggressive course of disease beyond pathology features of tumor differentiation and stage. This is not unexpected since leiomyosarcoma is rare and power is limited. It is helpful, however, that larger studies do not find other characteristics act as confounders. This implies that our aggregate estimate and those of others are not likely to be seriously confounded by commonly measured clinical factors.

In summary, this literature provides data to indicate that method of morcellation is a potential determinant of outcomes, with power morcellation being associated with decreased 5 year survival. However, confidence intervals overlap, and even those who have leiomyosarcoma with removal of the uterus intact have substantial mortality risk.

Discussion

Key Findings

Strength of Evidence

We assessed the strength of evidence for medical, procedural, and surgical intervention effects on fibroid volume, uterine bleeding, and quality of life. The summaries below are organized by category of intervention and reflect findings for all arms of the included trials that examined the intervention. We report strength of evidence for those studies that report on these outcomes. Not all outcomes are considered by all publications. Tables 29-36 outline strength of evidence findings.

Expectant Management

Table 29. Strength of evidence for expectant management

Studies, Total N	Risk of Bias	Study Limitations	Directness	Consistency	Precision	Reporting Bias	Strength of Evidence
Fibroid Volume							
11 studies, 331 participants	Low: 2 Moderate: 3 High: 6	High	Direct	Inconsistent	Precise	Not detected	Insufficient
Bleeding							
13 studies, 400 participants	Low: 2 Moderate: 6 High: 5	High	Direct	Inconsistent	Precise	Not detected	Insufficient

Medications

Table 30. Strength of evidence for GnRH treatment

Studies, Total N	Risk of Bias	Study Limitations	Directness	Consistency	Precision	Reporting Bias	Strength of Evidence
Fibroid Volume							
12 studies, 534 participants	Low: 2 Moderate: 1 High: 9	High	Direct	Consistent	Precise	Not detected	Moderate for reduction in fibroid volume
Bleeding							
14 studies, 666 participants	Low: 1 Moderate: 3 High: 10	High	Direct	Consistent	Precise	Not detected	Moderate for improved bleeding, including cessation of menses
Quality of Life							
3 studies, 285 participants	Low: 1 Moderate: 1 High: 1	Medium	Direct	Consistent	Precise	Not detected	Low for improved fibroid-related quality of

Studies, Total N	Risk of Bias	Study Limitations	Directness	Consistency	Precision	Reporting Bias	Strength of Evidence
							life

GnRH = gonadotropin-releasing hormone

Table 31. Strength of evidence for progesterone antagonist and selective receptor modulators

Studies, Total N	Risk of Bias	Study Limitations	Directness	Consistency	Precision	Reporting Bias	Strength of Evidence
Fibroid Volume							
Mifepristone (7 studies, 690 participants)	Moderate: 5 High: 2	Medium	Direct	Consistent	Precise	Not detected	Moderate for reduction in fibroid volume
Ulipristal (6 studies, 1,095 participants)	Low: 2 Moderate: 2 High: 2	Medium	Direct	Consistent	Precise	Not detected	Moderate for reduction in fibroid volume
Bleeding							
Mifepristone (7 studies, 690 participants)	Moderate: 5 High: 2	Medium	Direct	Consistent	Precise	Not detected	Moderate for improved bleeding
Ulipristal (6 studies, 1,095 participants)	Low: 2 Moderate: 2 High: 2	Medium	Direct	Consistent	Precise	Not detected	Moderate for improved bleeding
LNG-IUD (1 study, 30 participants)	High: 1	High	Direct	Unknown	Imprecise	Not detected	Insufficient
Quality of Life							
Mifepristone (4 studies, 374 participants)	Moderate: 2 High: 2	High	Direct	Consistent	Precise	Not detected	Moderate for improved fibroid-related quality of life
Ulipristal (6 studies, 1,095 participants)	Low: 2 Moderate: 2 High: 2	Medium	Direct	Consistent	Precise	Not detected	Moderate for improved fibroid-related quality of life

LNG-IUD = levonorgestrel intrauterine device

Table 32. Strength of evidence for estrogen receptor agents

Studies, Total N	Risk of Bias	Study Limitations	Directness	Consistency	Precision	Reporting Bias	Strength of Evidence
Fibroid Volume							
3 studies, 107 participants	Moderate: 2 High: 1	Medium	Direct	Inconsistent	Imprecise	Not detected	Low for lack of effect on fibroid size

Studies, Total N	Risk of Bias	Study Limitations	Directness	Consistency	Precision	Reporting Bias	Strength of Evidence
							with raloxifene, insufficient for tamoxifen or HRT
Bleeding							
4 studies, 117 participants	Moderate: 2 High: 2	Medium	Indirect	Consistent	Imprecise	Not detected	Low for lack of effect on bleeding with raloxifene, insufficient for tamoxifen or HRT

Procedures

Table 33. Strength of evidence for uterine artery embolization or occlusion

Studies, Total N	Risk of Bias	Study Limitations	Directness	Consistency	Precision	Reporting Bias	Strength of Evidence
UAE							
Fibroid Volume							
12 studies, 838 participants	Low: 4 Moderate: 4 High: 4	Low	Direct	Consistent	Precise	Not detected	High for reduction in fibroid volume
Bleeding							
9 studies, 438 participants	Low: 1 Moderate: 4 High: 4	Medium	Direct	Consistent	Precise	Not detected	Moderate for improved bleeding
Quality of Life							
8 studies, 623 participants	Low: 2 Moderate: 4 High: 2	Medium	Direct	Consistent	Precise	Not detected	Moderate for improved fibroid-related quality of life
Fibroid Size and Bleeding							
2 studies, 82 participants	Medium: 1 High: 1	High	Direct	Consistent	Imprecise	Not detected	Insufficient
Uterine Artery Occlusion by Any Other Method							
Bleeding, Fibroid Size							
3 studies, 225	Medium: 1	Medium	Direct	Inconsistent	Imprecise	Not	Insufficient

Studies, Total N	Risk of Bias	Study Limitations	Directness	Consistency	Precision	Reporting Bias	Strength of Evidence
participants	High: 2					detected	due to heterogeneity of intervention methods

Table 34. Strength of evidence for HIFU for fibroid ablation

Studies, Total N	Risk of Bias	Study Limitations	Directness	Consistency	Precision	Reporting Bias	Strength of Evidence
Fibroid Volume							
HIFU (3 studies, 153 participants)	High: 3	High	Direct	Consistent	Imprecise	Not detected	Low for reduction in fibroid volume

HIFU = high intensity focused ultrasound

Surgery

Table 35. Strength of evidence for surgery

Studies, Total N	Risk of Bias	Study Limitations	Directness	Consistency	Precision	Reporting Bias	Strength of Evidence
Bleeding							
Endometrial ablation (1 study, 96 participants	Moderate: 1	Medium	Direct	Unknown	Imprecise	Not detected	Insufficient
Myomectomy (2 studies, 183 randomized)	High: 2	High	Direct	Inconsistent	Imprecise	Not detected	Insufficient
Quality of Life							
Myomectomy (3 studies, 264 participants)	Moderate: 1 High: 2	High	Direct	Consistent	Precise	Not detected	Low for improved fibroid-related quality of life
Hysterectomy (2 studies, 204 participants)	High: 2	High	Direct	Consistent	Precise	Not detected	Low for improved fibroid-related quality of life

Direct Comparisons of Interventions

Table 36. Strength of evidence for direct comparisons of interventions

Studies, Total N	Risk of Bias	Study Limitations	Directness	Consistency	Precision	Reporting Bias	Strength of Evidence
Ulipristal vs. GnRH							
Bleeding, Fibroid Size							

Studies, Total N	Risk of Bias	Study Limitations	Directness	Consistency	Precision	Reporting Bias	Strength of Evidence
1 study, 307 participants	Low: 1	Low	Direct	Unknown	Precise	Not detected	Insufficient
UAE vs. Myomectomy							
Quality of Life							
1 study, 163 participants	Medium: 1	Medium	Direct	Unknown	Imprecise	Not detected	Insufficient
UAE vs. Hysterectomy							
Quality of Life							
1 study, 177 participants	Low: 1	Low	Direct	Unknown	Imprecise	Not detected	Insufficient

GnRH = gonadotropin-releasing hormone agonist; UAE = uterine artery embolization

Findings in Relation to What Is Known

Existing Systematic Reviews

We searched for systematic reviews published between 2002 and 2015. We evaluated each for relevance to our Key Questions using the review patients/participants, interventions, comparators, outcomes, timing, and setting (PICOTS). We identified 24 systematic reviews of interventions to treat uterine fibroids (Appendix I).[12,163,217-238] The reviews addressed the following categories of interventions: medical (12 reviews), uterine artery embolization (UAE) (5 reviews), procedural (2 reviews), uterine sparing (1 review), surgical (3 reviews), and multiple interventions (1 review). The reviews overall were characterized by small numbers of included studies and limited data on long-term outcomes including future fertility. Harms were addressed in only a few reviews.

Existing Reviews of Medical Interventions

The medical interventions evaluated in the 12 medical systematic reviews included gonadotropin-releasing hormone (GnRH) analogues in four reviews,[163,217,224,233] , progesterone-containing intrauterine devices (IUDs) in 4 reviews, [222,228,235,236], and single reviews of progesterone antagonists including mifepristone,[237] selective estrogen receptor modulators (SERMs),[231] aromatase inhibitors[226] and tranexamic acid.[219]

GnRH analogues were evaluated in four reviews.[163,217,224,233] A Cochrane review of GnRH with add-back therapy assessed quality of life in 14 randomized clinical trials (RCTs).[217] Add-back therapies included medroxyprogesterone, tibolone, raloxifene, estriol, ipriflavone, and conjugated estrogens. Tibolone was associated with an improved quality of life and add-back therapies of tibolone, estriol, and ipriflavone helped preserve bone mass, but the quality of evidence for these findings was considered low.

Three reviews examined use of GnRH analogues as pre-medication prior to surgical procedures. Lethaby and colleagues summarized 20 RCTs that demonstrated preoperative GnRH agonist treatment reduced uterine volume and fibroid size and improved surgical bleeding outcomes.[163] Chen and colleagues analyzed data from three RCTs that compared GnRH versus no treatment or placebo prior to laparoscopic myomectomy.[233] GnRH significantly reduced intraoperative blood loss but did not shorten the operation time. Kamath and colleagues only found two studies that compared GnRH with placebo or no treatment in women with submucosal

fibroids prior to hysteroscopic resection.[224] The primary outcome of symptom relief was inconclusive.

Progestogen-releasing IUDs were evaluated in four systematic reviews.[222,228,235,236] A small Cochrane report of progestogens included only a single small study that compared levonorgestrel (LNG) IUD to oral contraceptives and found significant reduction in blood loss for IUD users.[228] LNG-IUD was associated with reduced menstrual blood loss reported in three other reviews that included few to no RCTs.[222,235,236] Women with fibroids may have higher device expulsion rates.[235]

A Cochrane review of SERMs used to treat leiomyoma only included three small RCTs.[231] All of the studies evaluated raloxifene but the evidence for the effectiveness in reducing fibroid size and improving clinical outcomes was inconclusive. An older systematic review of mifepristone included six pre-post studies.[237] Mifepristone was associated with a reduction in fibroid size and improvement in symptoms but there were no comparative studies in this review.

Another Cochrane review of aromatase inhibitors found only a single RCT comparing letrozole to GnRH agonist.[226] There were no statistically significant differences in fibroid volume after 12 weeks of treatment. A single review of tranexamic acid for management of menorrhagia due to fibroids noted that it may reduce perioperative blood loss during myomectomy.[219]

Our review documents effectiveness of GnRH agonists for reducing fibroid volume and improving bleeding outcomes and improved symptom status when combined with add-back therapy and provides comparative trial evidence for the effectiveness of mifepristone in fibroid size reduction and resolving bleeding problems.

Existing Reviews of Procedural Interventions

Two reviews evaluated MRI-guided focused ultrasound (MRgFUS) treatment of uterine fibroids.[223,227] The reviews did not include any RCTs; conclusions were from analysis of retrospective studies and case series. Outcomes assessed included symptom severity from UFS-QOL, subsequent pregnancy, and harms. MRgFUS treated women had an improved quality of life as assessed 6 months following treatment, future fertility was preserved, and the procedure was well tolerated with only one serious adverse event of deep vein thrombosis reported.

In contrast, the studies of high frequency ultrasound (HIFU) and MRgFUS included in our review (all RCTs) did not report pregnancy or other patient- centered outcomes, but focused on technical success.

Existing Reviews of UAE

Uterine artery embolization (UAE) was evaluated in five systematic reviews.[218,225,229,230,232] Four of these reviews reported on comparative studies of UAE versus surgical treatments for uterine fibroids.[218,229,230,232] More favorable short-term outcomes, including reduced blood loss[232] and a quicker return to usual activities,[232] were noted for UAE compared with surgery. The risk of major complications was reduced with UAE,[229,230] but the procedure is associated with higher rates for reintervention reported in three systematic reviews.[229,230,232] There were no differences in patient satisfaction after 2 and 5 years[218] and long-term quality of life was comparable.[218,232] Data for live birth outcomes following UAE were limited.[218] One review that examined comparative studies of UAE using different embolic agents did not find any evidence of superiority of any particular agent.[225]

Our findings on patient satisfaction and quality of life outcomes following embolization in comparison with surgical treatments were comparable to what has been previously reported.

Existing Reviews of Uterine-Sparing Interventions

A single systematic review of five RCTs in premenopausal women who wanted to preserve their uterus reported comparisons between UAE with myomectomy and laparoscopic uterine artery occlusion.[221] Patient satisfaction was better for UAE and myomectomy compared with laparoscopic uterine artery occlusion. Limited evidence was available for fertility and pregnancy outcomes. Our review also had limited evidence for reproductive outcomes following uterine-sparing procedures.

Existing Reviews of Surgical Interventions

Three systematic reviews evaluated surgical treatments for uterine fibroids.[220,234,238] A large review of 34 RCTs compared vaginal, abdominal, and/or laparoscopic-assisted hysterectomies in women with benign disease, although only six of these trials specifically addressed surgical treatment for uterine fibroids. Vaginal hysterectomy was associated with a quicker return to usual activities and fewer infections compared with abdominal hysterectomy.[238] A review of nine RCTs comparing laparoscopic or hysteroscopic versus open myomectomy found improved short-term outcomes (less postoperative pain and shorter hospitalization) for laparoscopic procedures.[220] Another small review of four RCTs noted a significantly shorter operation time for hysteroscopic myomectomy compared with laparoscopic. Data was not available for long-term outcomes in these reviews. Our review also reports higher patient satisfaction and shorter recovery time for vaginal hysterectomy compared with abdominal hysterectomy.

Existing Reviews of Multiple Interventions

One review, an update of 2001 review of multiple therapies, addressed medical and surgical approaches or procedures to treat uterine fibroids.[12] Preoperative medical management reduced fibroid volume but did not provide sufficient evidence of improvement in operative outcomes. In studies of GnRH agonists, treatment reduced fibroid size, and add-back therapy did not affect the extent of reduction. Studies typically reported improved hemoglobin and mixed effects on symptoms including menorrhagia and pelvic pain. Harms associated with GnRH treatment included increases in low density lipoprotein levels with leuprolide and bone mineral density loss with leuprolide and leuprolide plus tibolone, and GnRH plus raloxifene. Mifepristone reduced menstrual blood loss and uterine volume and was associated with endometrial hyperplasia in 8 percent of participants receiving higher doses. Raloxifene decreased fibroid size in postmenopausal women and increased it in premenopausal. Studies of UAE reported high levels of symptom improvement and satisfaction with treatment and reductions in uterine volume of 27 to 47 percent over time. The incidence of UAE complications, including procedure-associated pain, hospitalization, unplanned increases in care, and minor complications requiring no treatment, ranged from 0.6 percent to 92 percent (for pain) across studies.

Quality of life, bulk symptoms, and bleeding improved with HIFU, and harms of treatment included pain and nerve palsy. Data on the effects of myomectomy on long-term outcomes were limited, and complications, including hematoma, infection, ileus, organ injury, conversion to hysterectomy, transfusion, and fever, typically increased with the number of fibroids removed. Hysterectomy studies primarily reported complications including a rate of severe operative and postoperative complications of less than 5% in one case series. Other complications included

readmission or conversion to laparotomy (for laparoscopic approaches), febrile morbidity, transfusion, ileus, and postoperative pain. The review notes that no well-conducted trials in U.S. populations directly compared treatment options or followed women to determine whether the intervention met their treatment objectives.

Existing Estimations of Occult Leiomyosarcoma Prevalence

In 2014, the FDA estimated the risk of occult leiomyosarcoma to be 1 in 498 women undergoing surgery for presumed fibroids.[24,40] This corresponds to 20 cases per 10,000 (95% binomial exact confidence interval 11-38). They identified 18 publications, and only included data from nine, one of which is only an abstract. They identified a total of 9,160 women, of which only 505(6%) were identified in prospective studies. Most of the studies included only hysterectomy patients.

In contrast, we identified 160 studies that included 136,195 women, of whom 29% were from prospective studies. Our estimates and that of Pritts[10] find that the prevalence of leiomyosarcoma are lower in data from more contemporary prospective cohorts of women having surgery compared to retrospectively collected data. This may be explained by challenges in applying uniform definitions and quality controls in retrospectively collected data even when pathology specimen banks are used to index a full population of surgical patients. Prospectively collected data also includes more women who are having myomectomies who are on average somewhat younger than those having hysterectomies. It is known that the incidence of sarcoma has been shown to increase with age through the sixth decade of life. [26,187]

Applicability

Overall, our findings are widely applicable to the general population of women seeking treatment for uterine fibroids. For KQs 1 and 2 we set inclusion criteria for this review to women of any age with uterine fibroids with patient outcome data beyond intermediate outcomes only. We excluded studies in pregnant women, and restricted our synthesis to include only treatments currently available in the United States. Over 40 percent of the studies were conducted in European countries and another 27 percent were conducted in the United States or Canada. This could have implications because the available options and attitudes and expectations about outcomes of fibroid care may differ by country and by healthcare setting. The interventions themselves were selected to be comparable so that the results reported in this review are expected to apply to women with fibroids in the United States.

Evaluation of expectant management was not an explicit aim of any trial. Sixteen studies with placebo arms or no treatment arms that included 514 women served as a surrogate. This population is not an ideal substitute as participants in the trials presumably hoped to receive active treatment and may report their status differently than women willing to be randomized to watchful waiting. This could restrict applicability but since the majority of studies included a plausible level of participant masking, they would be unlikely to know if they were on an active agent.

Medical management of fibroids was assessed in over 2,800 predominately premenopausal women from 43 studies (15 industry-sponsored and 11 conducted in the United States). Procedures, including UAE HIFU, and radiofrequency fibroid ablation were evaluated in 28 studies including almost 2,000 women, although data was lacking for some interventions (radiofrequency ablation was evaluated in only two small studies, IUDs in one). Surgical studies

evaluated hysterectomy, myomectomy, and endometrial ablation in over 3,000 women. Although none of these studies were conducted in the United States, the surgical techniques described are comparable and the comparators are procedures widely available to women in the United States.

Data in these studies were inadequate to assess applicability based on patient characteristics, such as age, race/ethnicity, pregnancy intention, or menopausal status, or fibroid characteristics, such as size, position, and number, that could influence effectiveness outcomes.

While there are limitations in the literature as discussed below, the information that is available from these trials is relevant to contemporary practice. For key questions 1 and 2, this review is generally applicable to women in the United States seeking one of the many treatment choices currently available for fibroids.

For key questions 3 and 4 (leiomyosarcoma risk), data can only be systematically obtained from publically available research. Those represented in the literature may differ from the universe of women having surgery for fibroids in the US. The group of interest to surgeons trying to determine appropriate use of morcellation is premenopausal women. Nearly all women having myomectomies are premenopausal. This is the group with potential future pregnancy desires and indications such as anemia, menorrhagia, and bulk symptoms who make up the majority of women seeking care for fibroids. The literature about risk and outcomes of leiomyosarcoma does not separate cases well by type or surgery or menopausal status. Prospective studies which include a greater representation of myomectomy patients may be more applicable for discussing risk among younger women.

Implications for Clinical and Policy Decisionmaking

Available evidence in this literature is predominantly restricted to understanding outcomes of specific interventions and not comparisons among them. Therefore, this review reports evidence that an intervention delivers certain desired outcomes but not how those outcomes vary across types of intervention. While it is helpful to know that confidence in particular medications, procedures, or surgeries is not misplaced, it is not sufficient to fully inform choice among the options or to drive decisions about coverage by health plans.

Some implications for clinical care and other decisionmaking can be highlighted. Women with fibroids and symptoms typically have time to make decisions and the process need not feel emergent or rushed. This presumes that a patient's medical condition is not acutely emergent which is an exceptionally small minority of those seeking care. More typically symptoms are persistent and troubling but not life threatening. In these instances, RCT data from placebo groups show that fibroids do not grow substantially over a period of time that averaged 7 months, neither did bleeding pattern substantially worsen.

Several medications show benefit for reducing the size of fibroids, improving bleeding, and reducing symptoms. These include GnRH agonists and ulipristal. Mifepristone provided stabilizing effects on the size of fibroids (no growth) with similar improvement in symptoms. In a single study, among women randomized to have an immediate hysterectomy or to defer hysterectomy and be treated with a GnRH agonist, 61 percent did not have surgery over three years of followup, suggesting a meaningful proportion of symptomatic women who wish to pursue medical intervention may avoid surgical intervention.[137] Harms of medical therapies vary and include menopausal symptoms, unfavorable lipid profile, cognitive decline, bone loss, endometrial hyperplasia, and liver toxicity. Some are reversible, however, it is not clear if other effects persist after treatment ends. These medical management options are likely underutilized in clinical practice and care guidelines might more directly address instances that merit

consideration. Certainly all women with fibroids should at minimum be aware that medications for management of fibroids exist. We also note that these interventions are not compatible with and in some cases prevent pregnancy, while in others contraception is required.

Procedures also deliver the expected results. Uterine artery embolization reduces the size of fibroids, reduces bleeding, improves pressure and bulk symptoms, and improves quality of life. High intensity focused ultrasound and radiofrequency ablation each have fewer trials but they provide evidence of effectiveness for reducing fibroid size, but uncertain effects on bleeding, symptoms, and quality of life and durability of improvements. This poses challenges for determining if procedures should be covered or if healthcare systems should invest in professional expertise and equipment to perform new procedures. Other interventions are more rarely used or not included in the literature but are important. These are discussed in future research needs.

Surgeries are most studied. Hysterectomy remains the definitive treatment. Less invasive hysterectomy options (vaginal or laparoscopic compared with an abdominal approaches) have superior patient satisfaction and shorter recovery. Overall harms did not differ in ways that would warrant consideration of harms driving a clinical choice. Myomectomy follows the same pattern, less invasive approaches had less impact on women's lives and harms were equivalent. Women are at times advised to have myomectomy to improve reproductive outcomes and this review, as well as a related recent Cochrane review of randomized trials of myomectomy,[239] suggests this is not the case. It is notable that evidence suggests only intervention for submucous fibroids (those in the uterine cavity), as opposed to other more common locations, improve subsequent pregnancy outcomes.

Few direct comparisons across categories of intervention are available to inform care. Two small studies of fair quality compared UAE to hysterectomy or myomectomy[16,21] as did three larger studies, including the 28-site EMMY trial.[20,22,114] As a group these studies provide a good case for why more trials making direct comparisons are needed. The studies find UAE provided similar symptom relief, quality of life, and risk of fibroid recurrence (the latter compared with myomectomy). UAE had shorter recovery and lower transfusion risk than both myomectomy and hysterectomy. In the high quality study with longest followup at 5 years, fewer than one third of women assigned to UAE required additional intervention, emphasizing that over two-thirds avoided surgery.[114] Our modelling data supports the low risk of subsequent intervention for most women after UAE. However, the major complication rate was three percent at one year and up to 21 percent at five years after UAE, and the impact of UAE on fertility remains unclear.

Likely no topic in gynecologic surgery, other than abortion ethics, has stirred as much public controversy as recent concerns about use of power morcellators in the care of women with fibroids. The concern pivots on an essential question about risk that we have updated from the last estimate in the published literature. The bedrock question on which all other considerations rest is: What is the expected risk of planning a surgery for uterine fibroids and unintentionally encountering a leiomyosarcoma? While women and their physicians alike would like this number to be zero, it is not, but it is a small risk. The point estimate of prevalence from 68 prospective studies is 0.02 percent (95% credible interval, 0.00 to 0.09) Using both prospective and retrospective studies, we estimate fewer than one to 13 women in 10,000 who have surgery for a fibroid may have a leiomyosarcoma.

Leiomyosarcomas have poor outcomes.[240] In our meta-analysis of 24 studies that provide data about use of morcellation in three categories: none, scalpel, or power; we find that power morcellation may be a determinant of dissemination and death from leiomyosarcoma. Some

recent estimates in the literature find otherwise,[170] and it is important to note that primary means of dissemination of this cancer is believed to be hematogenous,. More than half of women with leiomyosarcomas present with distant metastasis before recurrent cancer in the pelvis, and most progress to higher stage disease regardless of order of spread.[44,45] Unfortunately, the literature does not speak to characteristics of the individual or characteristics revealed by imaging of her fibroids that can discriminate those at high risk from those with lower risk. While we know risk increases with age through the sixth decade of life, age is neither sensitive nor specific given such a rare condition.

Taken together these findings suggest that the current ban on power morcellation requires continued investigation with expanded data. Some have cautiously argued such a ban in all age groups could result in an increase in harms to women.[42,241] Is it prudent with a known leiomyosarcoma to avoid breaching the mass and to aim for intact removal? Of course. Might containment systems in which morcellation occurs within a closed bag-like system help? Potentially. Is it wise to perhaps advise older women that they are at increased risk of leiomyosarcoma and if childbearing is completed may wish to consider intact removal by hysterectomy? Perhaps, but the magnitude of risk averted is unknown. In each of these instances we have outstripped the evidence and guidance reverts to expert opinion. In discussion of future research we consider what data may better inform clinical and policy guidance.

Taken in total, women and care providers now have more and higher quality evidence of effectiveness than a decade ago, and the literature addresses multiple types of intervention in each of the categories of medication, procedural, and surgical management. Individual women should have access to this information to inform their decisions and factual estimates of outcomes should be used to guide the consenting process. Nonetheless, we need to continue to pursue questions about care trajectories, comparisons across categories of intervention and longer-term followup to best guide care and policy.

Limitations of the Systematic Review Process

Methodologic choices constrain the findings of this report. We chose to focus on publications in the English-language literature, to restrict to randomized clinical trials (for KQ 1 and KQ2 comparative effectiveness), and to review only those studies that included at least one intervention that is available in the United States. Similar reviews have documented in the past that language restrictions have a negligible effect on estimates of effectiveness.[242-244] This is especially true for the topic of fibroids because the fibroid research community is small. Our Technical Expert Panel and investigators are familiar with prior and ongoing work and helped assure relevant studies have not been overlooked. Restricting to trials allowed us to focus sharply on proof of effectiveness. Because all individuals whose outcomes were assessed in these studies were randomly assigned to the intervention received, provider and patient biases in intervention choice are reduced and risk of confounding, that is difficult to fully assess or adjust for in cohort studies, is minimized. Reduced risk of bias in assignment in trials allows aggregation and summary of the findings by study arm, as we have done in summaries and tables in this report. This approach provides a clearer picture of the expected outcomes and gaps in knowledge about specific interventions. Considering each possible combination of intervention arms and reporting per combinations of interventions fractionates this literature into very small groupings in which concordant and discordant findings about outcomes are more easily obscured.

Restricting our review to randomized controlled trials may have limited our ability to detect the full range of harms associated with medications or therapies for fibroids. Studies were

generally not designed or powered to evaluate harms, and many had a short duration of follow up.

Our analysis of subsequent intervention after a first intervention could be biased by the types of studies that reported this data; however, in general they were higher quality trials with longer followup. Nonetheless, subsequent care, even in longer followup, often represented a small number of women and our analysis can only broadly address probability of a next intervention by type.

For meta-estimates related to leiomyosarcoma prevalence and morcellation risk, available evidence, based on pathology specimens for estimating presence of leiomyosarcoma in a mass believed to be a fibroid, is accruing and will likely continue to do so through and past the production of this report. Our estimates and those of Pritts and colleagues[10]find that the estimates are lower in data from more contemporary prospective cohorts of women having surgery. This suggests some inaccuracies in retrospectively collected data even when pathology specimen banks are used to index a full population of surgical patients. On the other hand, it is important to note that prospectively collected data often includes younger patients and a larger proportion undergoing myomectomies. This risk of inaccuracy is especially true in understanding and estimating the potential that morcellation method influences survival when a woman is found to have a leiomyosarcoma that was believed to be a fibroid. All sources of information, including women with fibroids removed intact at hysterectomy must be included in order to accurately capture risk of this rare outcome. Focusing only on disease progression rate and risk of death among those with use of power morcellation fundamentally misrepresents the true comparisons. We have taken this approach for this review; however, such comparisons will only be complete and more robust for informing care when the literature contains more longitudinal data with common metrics.

Focusing on interventions available in the United States, and excluding those that cannot be obtained here could neglect a promising intervention but does restrict the report to data that is of immediate value to women and their care providers who must make decisions among available options. We have included interventions that are not widely available in the United States such as high frequency ultrasound ablation and operative thermal ablation, so in the strictest sense of applicability, some women live in locations, or have access to a limited group of providers or face limitations of insurance coverage that may restrict the availability of some options.

Limitations of the Evidence Base

While the literature about the effectiveness of uterine fibroids treatment has grown from 35 randomized clinical trials available in 2007 to 97 unique trials included in this report, significant gaps in knowledge persist. Across all studies, the 97 included RCTs with 36 unique interventions, enrolled a total of 9,179 women. Individual studies were often small and powered to address only a single continuous outcome such as hematocrit or score on a quality of life scale.

Our analytic framework was created to reflect the outcomes that matter to women when making decisions. The available literature has substantial gaps in collecting this information as indicated by the number of studies that addressed each of our eight primary outcomes:

- Fibroid characteristics (e.g., change in size, number, volume): 63
- Symptoms status (e.g., bleeding, pain, bulk symptoms): 57
- Sexual function: 12
- Quality of life and satisfaction with outcomes: 38
- Desired fertility status: 1

- Pregnancy outcomes: 8
- Fibroid recurrence: 8
- Subsequent treatment for fibroids: 48

Little continuity exists in approaches to measuring outcomes and use of unvalidated measures is common. Most postprocedural studies focused on perioperative outcomes, although a small minority recorded long-term outcomes, with one study reporting on 5-year outcomes. The literature is further restricted in its ability to answer questions of immediate relevance to the management of uterine fibroids because only a small number of studies compared different types of fibroid management. Although several studies compared different types of hysterectomy, myomectomy, or medical management, only 17 studies compared treatment from substantively different categories of intervention.

Even when data is combined across studies for a particular intervention, risk of serious rare harms cannot be fully assessed. This is not a comparable shortcoming for all the categories of intervention because the larger literature on surgical and medical interventions captures many of the "general risks," for instance the risk of postoperative hemorrhage after hysterectomy or adverse drug reactions to a specific drug formulation. Relative lack of harms data is more concerning for fibroid-specific interventions such as UAE, methods to ablate fibroids, and myomectomy because there is no broader literature to turn to outside this review that originates within clinical trials though cohort and surveillance data can provide insight.

In many instances ability to synthesize evidence across studies is absent, weak because of biased collection methods (e.g., assessors not blind to intervention), difficult to aggregate across studies because different metrics are used, or the studies did not have adequate power or followup time to assess a key outcome that would ideally be measured.

Paucity of "similar" articles (populations, settings, patient characteristics, and outcomes measured) also precludes efforts to pool data about characteristics of the study populations as they contribute to predicting outcomes and no studies were appropriately powered to understand whether specific groups of patients, such as those closer to menopause or with a specific symptom pattern, have outcomes that are modified by those characteristics.

Overall quality of the literature is improving over time but remains limited. Among 97 trials, 18 were good quality, 27 were fair quality, and 52 were poor quality. Secular trends for improvement in trial methods do not explain poor quality. Some studies of good quality are older, and some studies of poor quality are very recent. Lastly, a disappointing lack of direct comparisons means this review is hindered in providing summaries with data to help a woman or her care provider make an evidence-driven selection among choices in the context of the patients' priorities.

Limitations about leiomyosarcoma data: Because cases are rare and detailed age data for non-cases is lacking, only rough models of risk by age can be produced. [25]We need more prospective studies that include nuanced data such as patient and fibroid characteristics, patient age, menopausal status and surgical approach, hormonal exposures and genetic factors so that we can give more accurate estimates to patients.

Research Recommendations

Key components of study design, analysis, and reporting remain the leading weaknesses of the literature for each topic addressed in this review. Overall, the literature identified is limited by the following gaps and problems. Future research should aim to remediate these concerns:

Ability To Assess Internal and External Validity. Key characteristics of populations studied (e.g., race/ethnicity, reproductive history) and detailed operational definitions of inclusion and exclusion criteria are not reported consistently. Furthermore, the dominance of European literature means that we cannot assume that processes of care and outcomes will be similar to those in the United States. Moreover, practice and outcomes have been shown in other areas of research (such as cardiac care) to have substantial variability within the United States and even within individual states and facilities. We see no reason to believe that such variation is not also at work in the care of fibroids; more and better information from U.S. studies is required to advance our understanding about this important women's health issue.

Study Populations of Adequate Size for Assessing Key Outcomes and Modifiers. The small size of most of the included trials, which averaged fewer than 100 participants, stymies ability to understand modifiers of outcomes that could be extremely relevant to clinical decisionmaking. Though most trials reported power calculations, calculations were often linked to intermediate outcomes such as blood loss at surgery, length of hospital stay, or bleeding pattern at conclusion of 3 months of medical therapy. Even with power calculations, the sizes of the samples precluded having adequate numbers of participants for the types of answers that are needed to inform women and their care providers about the critical questions raised for this report. Future research would be better able to provide such answers if funding agencies supported studies of adequate size to answer questions about priorities for patient centered outcomes, minimal important differences on standard measures, resolution of symptoms, satisfaction with outcomes, recurrence or growth of fibroids, and further care needs at time horizons of a year and longer.

Standard Nomenclature and Validated Measures. To advance knowledge, investigators need to adopt common classifications across the whole spectrum of operational definitions required for research. Several deficiencies handicap our ability to compare interventions and populations or aggregate data to estimate effect size and outcome probabilities. Three shortcomings are especially problematic: (1) failure to define operationally details such as fibroid type or position in the uterus; (2) reliance on clinical measures such as estimated blood loss from operative reports or febrile morbidity from nursing notes as endpoints; and (3) use of ad hoc measures of outcome that lack validity and reliability data (e.g., intuitively derived approaches to collecting data about success in controlling bleeding or altering bleeding patterns).

Analysis Methods Matched to the Outcomes of Interest. Followup data that investigate topics such as time to return to work, maintenance of symptom control, recurrence of fibroids, subsequent surgery, and fertility and pregnancy outcomes should be addressed with analysis methods that explicitly incorporate time-to-event analyses. Few studies used life table or hazard model approaches to reporting outcomes. Likewise determinants of outcomes may be examined by use of tools such as classification and regression tree analysis to partition extant dates in ways that better reveal the contribution of fibroid and patient characteristics to outcomes.

Direct Comparisons of Treatment Options. Randomized trials with common endpoints that reflect the treatment goals of women with fibroids must become a priority. Promising efficacy studies should be rapidly followed by larger effectiveness and comparison studies. Although changing entrenched treatment patterns is often difficult, especially for surgical

procedures that have been clinically available in varied forms for decades, trials must be done that compare surgery to medication and to procedures. When possible, such as for women without or with mild symptoms, trials should include a delayed treatment arm or expectant management group in order to better understand the natural history of fibroids and to examine the degree to which symptoms may wax and wane.

Content Priorities. With the goal of achieving care tailored to the individual woman's fibroid status and characteristics, we need sophisticated information about a considerable array of issues. These include the burden of disease for both her and, possibly, her family; along with societal costs from loss of ability to function well in the usual family or occupational roles. Transitions associated with appearance of uterine fibroids, growth patterns, and influences on growth (e.g., concurrent medical conditions like diabetes, use of medications like hormonal contraception, influence of lactation and duration) are also high-priority topics, as are predictors of symptom development and resolution. Variation in care-seeking behaviors, differences in severity at presentation, and health and quality-of-life outcomes with and without treatment are yet other matters that investigators should attempt to address. Indeed this literature cannot currently address from trials whether disparities between white and black women in the age at appearance of fibroids and in the number and size of fibroids also foreshadows different treatment outcomes and durability of results.

In current practice, women without symptoms may forego intervention because of the general belief that care should be aimed at improving symptoms or addressing a specific clinical concern such as difficulty conceiving or recurrent pregnancy loss. A patient's preferences, age and menopausal status also play into these decisions. Although foregoing intervention can be wise in the absence of data that the intervention will prevent future difficulties, no data indicates whether harms from expectant management are any less than use of other therapeutics. Likewise data is lacking on whether therapeutics, short of surgery, might forestall or prevent future changes in fibroids or appearance of symptoms which would be a desirable reason to intervene early. The concept of preventive strategies is appealing. However, as long as the etiology of fibroids remains unclear, preliminary trials are not assessing lifestyle interventions, and the prospect for dietary management, exercise, hormonal management, or other prevention trials is slim.

The clinical research agenda will likely depend on new translational research and large-scale epidemiology studies that are yet to be done. Much remains to be learned that will require large-scale prospective observational studies of sufficient size and rigor to support time-to-event analysis of outcomes, such as that being conducted in the COMPARE Uterine Fibroids 10,000 woman cohort study supported by AHRQ and PCORI. These studies may afford greater power to examine effect modification and to determine trajectories of care over a reproductive lifespan for women with fibroids. Additionally, such studies will be better able to estimate both common and rare harms.

While we did not review these topics, many of the trials raise the question of what underpins the presence of symptoms and what modifies risk of growth. We must also continue to invest in basic and translational research to understand the pathogenesis and pathophysiology of uterine fibroids. Such research is required to best guide selection of pathways for exploration of genetic determinants of the timing and severity of disease, gene-environment interactions that may influence onset and symptoms, proteomic and treatment targeting research, as well as to discover potential prevention strategies. Research effort must be focused on documenting first the course and consequences of uterine fibroids using optimal imaging strategies, then the modifiers of that

course, so that we can offer women an accurate account of the likely outcome of expectant management based on their individual status.

Conclusions

A range of interventions are effective for reducing fibroid size and improving symptoms. Some medications and procedures also improve quality of life. In accord with the prior AHRQ systematic evidence review on management of uterine fibroids, we find a lack of high-quality evidence in several areas. Specifically notable is the lack of well-conducted trials in U.S. populations. Fewer than a quarter of the trials were conducted in the United States. Direct comparisons among different treatment options remain sparse. No studies have explicitly evaluated expectant management, which is a crucial missing piece of the evidence about the natural history of disease that would provide information about whether symptoms relapse and remit even after a woman presents seeking resolution of symptoms. The literature must include longer followup to determine whether women's objectives for treatment were met by the intervention received. Few women have only one concern driving their desire for intervention, yet remarkably many trials are directed at evaluating a single outcome. Likewise concerns about harms, such as drug side effects, serious surgical complications, and risk of undetected leiomyosarcoma, need to exploit larger and more nuanced data to be able to better determine what individual and fibroid characteristics best predict adverse events to better inform personalized care.

The range of options for medical management is expanding. However, no new agent has appeared that overcomes limitations of existing options (such as reducing hormonal side effects or allowing shorter duration of treatment). Appearance of new fibroids and growth of existing fibroids is poorly studied among the management options that leave the uterus in situ. Data to help women with fibroids who desire a pregnancy make treatment decisions are problematic because they originate primarily in populations dominated by participants with known fertility impairments or adverse pregnancy outcomes and often the proportion of women who wished to conceive is not known.

Across management options, we must note that lack of evidence is not equivalent to evidence of no benefit or of harm. Some of these interventions are effective in some patients but ability to estimate based on patient characteristics who would benefit most, or risk most, is lacking. Uncontrolled studies are not a substitute since they are notably biased for overestimating the degree of benefit subsequently reported in randomized trials. Indeed, not uncommonly, trials negate the findings of what in this case is largely retrospective and case series research. The current state of the literature does not permit definitive conclusions about comparative benefit, harm, or relative costs to achieve similar results across the range of available options and lacks strength of evidence for interventions such as use of continuous birth control pill regimens, progesterone containing IUDs, and endometrial ablation that are often used in routine clinical practice.

Finally, the uncertainty in estimates of leiomyosarcoma prevalence and evolving data about methods for tissue extraction will require explorations of ethical and shared decision making topics to offer coherent care recommendations and to support patients' and surgeons' autonomy. Given how common and concerning fibroids can be to women and their care providers, a redoubled emphasis on promoting high-quality fibroid research in the United States is imperative. Women need better information to guide their choices.

References

1. Baird DD, Dunson DB, Hill MC, Cousins D, Schectman JM. High cumulative incidence of uterine leiomyoma in black and white women: ultrasound evidence. American journal of obstetrics and gynecology. 2003;188(1):100-107. PMID: 12548202.

2. Wise LA, Palmer JR, Stewart EA, Rosenberg L. Age-specific incidence rates for self-reported uterine leiomyomata in the Black Women's Health Study. Obstetrics and gynecology. 2005;105(3):563-568. PMID: 15738025. doi:10.1097/01.AOG.0000154161.03418.e3.

3. Laughlin SK, Baird DD, Savitz DA, Herring AH, Hartmann KE. Prevalence of uterine leiomyomas in the first trimester of pregnancy: an ultrasound-screening study. Obstetrics and gynecology. 2009;113(3):630-635. PMID: 19300327. doi:10.1097/AOG.0b013e318197bbaf.

5. Myers ER, Barber MD, Gustilo-Ashby T, Couchman G, Matchar DB, McCrory DC. Management of uterine leiomyomata: what do we really know? Obstetrics and gynecology. 2002;100(1):8-17. PMID: 12100798.

6. Wegienka G, Baird DD, Hertz-Picciotto I, et al. Self-reported heavy bleeding associated with uterine leiomyomata. Obstetrics and gynecology. 2003;101(3):431-437. PMID: 12636944.

7. Templeman C, Marshall SF, Clarke CA, et al. Risk factors for surgically removed fibroids in a large cohort of teachers. Fertility and sterility. 2009;92(4):1436-1446. PMID: 19019355. doi:10.1016/j.fertnstert.2008.08.074.

8. Cardozo ER, Clark AD, Banks NK, Henne MB, Stegmann BJ, Segars JH. The estimated annual cost of uterine leiomyomata in the United States. American journal of obstetrics and gynecology. 2012;206(3):211.e211-219. PMID: 22244472. doi:10.1016/j.ajog.2011.12.002.

9. Hartmann KE, Birnbaum H, Ben-Hamadi R, et al. Annual costs associated with diagnosis of uterine leiomyomata. Obstetrics and gynecology. 2006;108(4):930-937. PMID: 17012456. doi:10.1097/01.aog.0000234651.41000.58.

10. Pritts EA, Vanness DJ, Berek JS, et al. The prevalence of occult leiomyosarcoma at surgery for presumed uterine fibroids: a meta-analysis. Gynecological surgery. 2015;12(3):165-177. PMID: 26283890. doi:10.1007/s10397-015-0894-4.

12. Viswanathan M, Hartmann K, McKoy N, et al. Management of uterine fibroids: an update of the evidence. Evidence report/technology assessment. 2007(154):1-122. PMID: 18288885.

13. Shlansky-Goldberg RD, Rosen MA, Mondschein JI, Stavropoulos SW, Trerotola SO, Diaz-Cartelle J. Comparison of polyvinyl alcohol microspheres and tris-acryl gelatin microspheres for uterine fibroid embolization: results of a single-center randomized study. Journal of vascular and interventional radiology : JVIR. 2014;25(6):823-832. PMID: 24788209. doi:10.1016/j.jvir.2014.03.009.

14. Jun F, Yamin L, Xinli X, et al. Uterine artery embolization versus surgery for symptomatic uterine fibroids: a randomized controlled trial and a meta-analysis of the literature. Archives of gynecology and obstetrics. 2012;285(5):1407-1413. PMID: 22048783. doi:10.1007/s00404-011-2065-9.

15. Yu SC, Lok I, Ho SS, Tong MM, Hui JW. Comparison of clinical outcomes of tris-acryl microspheres versus polyvinyl alcohol microspheres for uterine artery embolization for leiomyomas: results of a randomized trial. Journal of vascular and interventional radiology : JVIR. 2011;22(9):1229-1235. PMID: 21802314. doi:10.1016/j.jvir.2011.05.011.

16. Manyonda IT, Bratby M, Horst JS, Banu N, Gorti M, Belli AM. Uterine artery embolization versus myomectomy: impact on quality of life--results of the FUME (Fibroids of the Uterus: Myomectomy versus Embolization) Trial. Cardiovascular and interventional radiology. 2012;35(3):530-536. PMID: 21773858. doi:10.1007/s00270-011-0228-5.

17. Moss JG, Cooper KG, Khaund A, et al. Randomised comparison of uterine artery embolisation (UAE) with surgical treatment in patients with symptomatic uterine fibroids (REST trial): 5-year results. BJOG : an international journal of obstetrics and gynaecology. 2011;118(8):936-944. PMID: 21481151. doi:10.1111/j.1471-0528.2011.02952.x.

18. Bilhim T, Pisco JM, Duarte M, Oliveira AG. Polyvinyl alcohol particle size for uterine artery embolization: a prospective randomized study of initial use of 350-500 mum particles versus initial use of 500-700 mum particles. Journal of vascular and interventional radiology : JVIR. 2011;22(1):21-27. PMID: 21106390. doi:10.1016/j.jvir.2010.09.018.

19. van der Kooij SM, Hehenkamp WJ, Volkers NA, Birnie E, Ankum WM, Reekers JA. Uterine artery embolization versus hysterectomy in the treatment of symptomatic uterine fibroids: 5-year outcome from the randomized EMMY trial. American journal of obstetrics and gynecology. 2010;203(2):105.e101-113. PMID: 20579960. doi:10.1016/j.ajog.2010.01.049.

20. Ruuskanen A, Hippelainen M, Sipola P, Manninen H. Uterine artery embolisation versus hysterectomy for leiomyomas: primary and 2-year follow-up results of a randomised prospective clinical trial. European radiology. 2010;20(10):2524-2532. PMID: 20526776. doi:10.1007/s00330-010-1829-0.

21. Mara M, Maskova J, Fucikova Z, Kuzel D, Belsan T, Sosna O. Midterm clinical and first reproductive results of a randomized controlled trial comparing uterine fibroid embolization and myomectomy. Cardiovascular and interventional radiology. 2008;31(1):73-85. PMID: 17943348. doi:10.1007/s00270-007-9195-2.

22. Pinto I, Chimeno P, Romo A, et al. Uterine fibroids: uterine artery embolization versus abdominal hysterectomy for treatment--a prospective, randomized, and controlled clinical trial. Radiology. 2003;226(2):425-431. PMID: 12563136. doi:10.1148/radiol.2262011716.

23. Spies JB, Allison S, Flick P, et al. Spherical polyvinyl alcohol versus tris-acryl gelatin microspheres for uterine artery embolization for leiomyomas: results of a limited randomized comparative study. Journal of vascular and interventional radiology : JVIR. 2005;16(11):1431-1437. PMID: 16319148. doi:10.1097/01.rvi.0000179793.69590.1a.

24. Food and Drug Administration. Quantitative Assessment of the Prevalence of Unsuspected Uterine Sarcoma in Women Undergoing Treatment of Uterine Fibroids: Summary and Key Findings. 2014.

25. Brohl AS, Li L, Andikyan V, et al. Age-Stratified Risk of Unexpected Uterine Sarcoma Following Surgery for Presumed Benign Leiomyoma. The oncologist. 2015. PMID: 25765878. doi:10.1634/theoncologist.2014-0361.

26. Koivisto-Korander R, Martinsen JI, Weiderpass E, Leminen A, Pukkala E. Incidence of uterine leiomyosarcoma and endometrial stromal sarcoma in Nordic countries: results from NORDCAN and NOCCA databases. Maturitas. 2012;72(1):56-60. PMID: 22377186. doi:10.1016/j.maturitas.2012.01.021.

27. Stewart EA. Uterine fibroids. Lancet. 2001;357(9252):293-298. PMID: 11214143. doi:10.1016/s0140-6736(00)03622-9.

28. Huyck KL, Panhuysen CI, Cuenco KT, et al. The impact of race as a risk factor for symptom severity and age at diagnosis of uterine leiomyomata among affected sisters. American journal of obstetrics and gynecology. 2008;198(2):168 e161-169. PMID: 18226615. doi:10.1016/j.ajog.2007.05.038.

29. Segars JH, Parrott EC, Nagel JD, et al. Proceedings from the Third National Institutes of Health International Congress on Advances in Uterine Leiomyoma Research: comprehensive review, conference summary and future recommendations. Human reproduction update. 2014;20(3):309-333. PMID: 24401287. doi:10.1093/humupd/dmt058.

30. Wechter ME, Stewart EA, Myers ER, Kho RM, Wu JM. Leiomyoma-related hospitalization and surgery: prevalence and predicted growth based on population trends. American journal of obstetrics and gynecology. 2011;205(5):492 e491-495. PMID: 22035951. doi:10.1016/j.ajog.2011.07.008.

31. Whiteman MK, Hillis SD, Jamieson DJ, et al. Inpatient hysterectomy surveillance in the United States, 2000-2004. American journal of obstetrics and gynecology. 2008;198(1):34 e31-37. PMID: 17981254. doi:10.1016/j.ajog.2007.05.039.

32. Gliklich R, Leavy M, Velentgas P, et al. Identification of Future Research Needs in the Comparative Management of Uterine Fibroid Disease. Rockville, MD2011. AHRQ Publication No. 11-EHC023-EF.

33. Zimmermann A, Bernuit D, Gerlinger C, Schaefers M, Geppert K. Prevalence, symptoms and management of uterine fibroids: an international internet-based survey of 21,746 women. BMC women's health. 2012;12:6. PMID: 22448610. doi:10.1186/1472-6874-12-6.

34. Administration UFaD. Mifeprex (mifepristone) Information. http://www.fda.gov/Drugs/DrugSafety/ucm111323.htm.

35. Blithe DL, Nieman LK, Blye RP, Stratton P, Passaro M. Development of the selective progesterone receptor modulator CDB-2914 for clinical indications. Steroids. 2003;68(10-13):1013-1017. PMID: 14667994.

36. Levens ED, Potlog-Nahari C, Armstrong AY, et al. CDB-2914 for uterine leiomyomata treatment: a randomized controlled trial. Obstetrics and gynecology. 2008;111(5):1129-1136. PMID: 18448745. doi:10.1097/AOG.0b013e3181705d0e.

37. Passaro MD, Piquion J, Mullen N, et al. Luteal phase dose-response relationships of the antiprogestin CDB-2914 in normally cycling women. Human reproduction (Oxford, England). 2003;18(9):1820-1827. PMID: 12923133.

38. Cunningham E, Barreda L, Ngo M, Terasaki K, Munro MG. Uterine artery embolization versus occlusion for uterine leiomyomas: a pilot randomized clinical trial. Journal of minimally invasive gynecology. 2008;15(3):301-307. PMID: 18439501. doi:10.1016/j.jmig.2008.01.011.

39. Vilos GA, Allaire C, Laberge PY, et al. The management of uterine leiomyomas. Journal of obstetrics and gynaecology Canada : JOGC = Journal d'obstetrique et gynecologie du Canada : JOGC. 2015;37(2):157-181. PMID: 25767949.

40. Center for Devices and Radiological Health. Laparoscopic Uterine Power Morcellation in Hysterectomy and Myomectomy: FDA Safety Communication, Updated. [WebContent]. 2014; http://www.fda.gov/MedicalDevices/Safety/AlertsandNotices/ucm424443.htm.

41. Barron KI, Richard T, Robinson PS, Lamvu G. Association of the U.S. Food and Drug Administration Morcellation Warning With Rates of Minimally Invasive Hysterectomy and Myomectomy. Obstetrics and gynecology. 2015;126(6):1174-1180. PMID: 26595561. doi:10.1097/aog.0000000000001111.

42. Harris JA, Swenson CW, Uppal S, et al. Practice patterns and postoperative complications before and after US Food and Drug Administration safety communication on power morcellation. American journal of obstetrics and gynecology. 2016;214(1):98.e91-98.e13. PMID: 26314519. doi:10.1016/j.ajog.2015.08.047.

43. American Cancer Society. Uterine Sarcoma: Key Statistics. 2016; http://www.cancer.org/cancer/uterinesarcoma/detailedguide/uterine-sarcoma-key-statistics. Accessed July 2016.

44. Major FJ, Blessing JA, Silverberg SG, et al. Prognostic factors in early-stage uterine sarcoma. A Gynecologic Oncology Group study. Cancer. 1993;71(4 Suppl):1702-1709. PMID: 8381710.

45. Rose PG, Piver MS, Tsukada Y, Lau T. Patterns of metastasis in uterine sarcoma. An autopsy study. Cancer. 1989;63(5):935-938. PMID: 2914299.

46. Spies JB, Coyne K, Guaou Guaou N, Boyle D, Skyrnarz-Murphy K, Gonzalves SM. The UFS-QOL, a new disease-specific symptom and health-related quality of life questionnaire for leiomyomata. Obstetrics and gynecology. 2002;99(2):290-300. PMID: 11814511.

47. Coyne KS, Margolis MK, Murphy J, Spies J. Validation of the UFS-QOL-hysterectomy questionnaire: modifying an existing measure for comparative effectiveness research. Value in health : the journal of the International Society for Pharmacoeconomics and Outcomes Research. 2012;15(5):674-679. PMID: 22867776. doi:10.1016/j.jval.2012.03.1387.

48. Ware JE, Jr., Sherbourne CD. The MOS 36-item short-form health survey (SF-36). I. Conceptual framework and item selection. Medical care. 1992;30(6):473-483. PMID: 1593914.

49. Brooks R. EuroQol: the current state of play. Health Policy. 1996;37(1):53-72. PMID: 10158943.

50. methods guide. Methods Guide for Effectiveness and Comparative Effectiveness Reviews. Rockville (MD)2008.

51. Viswanathan M, Ansari MT, Berkman ND, et al. Assessing the Risk of Bias of Individual Studies in Systematic Reviews of Health Care Interventions. Methods Guide for Effectiveness and Comparative Effectiveness Reviews. Rockville (MD)2008.

52. Berkman ND, Lohr KN, Ansari M, et al. Grading the Strength of a Body of Evidence When Assessing Health Care Interventions for the Effective Health Care Program of the Agency for Healthcare Research and Quality: An Update. Methods Guide for Effectiveness and Comparative Effectiveness Reviews. Rockville (MD)2008.

53. Orsi F, Monfardini L, Bonomo G, Krokidis M, Della Vigna P, Disalvatore D. Ultrasound guided high intensity focused ultrasound (USgHIFU) ablation for uterine fibroids: Do we need the microbubbles? International journal of hyperthermia : the official journal of European Society for Hyperthermic Oncology, North American Hyperthermia Group. 2015:1-7. PMID: 25758436. doi:10.3109/02656736.2015.1004134.

54. Donnez J, Hudecek R, Donnez O, et al. Efficacy and safety of repeated use of ulipristal acetate in uterine fibroids. Fertility and sterility. 2015;103(2):519-527.e513. PMID: 25542821. doi:10.1016/j.fertnstert.2014.10.038.

55. Luyckx M, Squifflet JL, Jadoul P, Votino R, Dolmans MM, Donnez J. First series of 18 pregnancies after ulipristal acetate treatment for uterine fibroids. Fertility and sterility. 2014;102(5):1404-1409. PMID: 25241376. doi:10.1016/j.fertnstert.2014.07.1253.

56. Sesti F, Cosi V, Calonzi F, et al. Randomized comparison of total laparoscopic, laparoscopically assisted vaginal and vaginal hysterectomies for myomatous uteri. Archives of gynecology and obstetrics. 2014;290(3):485-491. PMID: 24710800. doi:10.1007/s00404-014-3228-2.

57. Brucker SY, Hahn M, Kraemer D, Taran FA, Isaacson KB, Kramer B. Laparoscopic radiofrequency volumetric thermal ablation of fibroids versus laparoscopic myomectomy. International journal of gynaecology and obstetrics: the official organ of the International Federation of Gynaecology and Obstetrics. 2014;125(3):261-265. PMID: 24698202. doi:10.1016/j.ijgo.2013.11.012.

58. Yang Z, Zhang Y, Zhang R, et al. A case-control study of high-intensity focused ultrasound combined with sonographically guided intratumoral ethanol injection in the treatment of uterine fibroids. Journal of ultrasound in medicine : official journal of the American Institute of Ultrasound in Medicine. 2014;33(4):657-665. PMID: 24658945. doi:10.7863/ultra.33.4.657.

59. Donnez J, Vazquez F, Tomaszewski J, et al. Long-term treatment of uterine fibroids with ulipristal acetate. Fertility and sterility. 2014;101(6):1565-1573.e1561-1518. PMID: 24630081. doi:10.1016/j.fertnstert.2014.02.008.

60. Jiang N, Xie B, Zhang X, et al. Enhancing ablation effects of a microbubble-enhancing contrast agent ("SonoVue") in the treatment of uterine fibroids with high-intensity focused ultrasound: a randomized controlled trial. Cardiovascular and interventional radiology. 2014;37(5):1321-1328. PMID: 24549267. doi:10.1007/s00270-013-0803-z.

61. Barlow DH, Lumsden MA, Fauser BC, Terrill P, Bestel E. Individualized vaginal bleeding experience of women with uterine fibroids in the PEARL I randomized controlled trial comparing the effects of ulipristal acetate or placebo. Human reproduction (Oxford, England). 2014;29(3):480-489. PMID: 24457604. doi:10.1093/humrep/det467.

62. Song YG, Jang H, Park KD, Kim MD, Kim CW. Non spherical polyvinyl alcohol versus gelatin sponge particles for uterine artery embolization for symptomatic fibroids. Minimally invasive therapy & allied technologies : MITAT : official journal of the Society for Minimally Invasive Therapy. 2013;22(6):364-371. PMID: 23992381. doi:10.3109/13645706.2013.826674.

63. Ardovino M, Ardovino I, Castaldi MA, Trabucco E, Colacurci N, Cobellis L. Minilaparoscopic myomectomy: a mini-invasive technical variant. Journal of laparoendoscopic & advanced surgical techniques Part A. 2013;23(10):871-875. PMID: 23992206. doi:10.1089/lap.2013.0037.

64. Carbonell JL, Acosta R, Perez Y, Garces R, Sanchez C, Tomasi G. Treatment of Uterine Myoma with 2.5 or 5 mg Mifepristone Daily during 3 Months with 9 Months Posttreatment Followup: Randomized Clinical Trial. ISRN obstetrics and gynecology. 2013;2013:649030. PMID: 23984082. doi:10.1155/2013/649030.

65. Esteve JL, Acosta R, Perez Y, et al. Mifepristone versus placebo to treat uterine myoma: a double-blind, randomized clinical trial. International journal of women's health. 2013;5:361-369. PMID: 23843709. doi:10.2147/ijwh.s42770.

66. Carbonell JL, Acosta R, Perez Y, et al. Safety and effectiveness of different dosage of mifepristone for the treatment of uterine fibroids: a double-blind randomized clinical trial. International journal of women's health. 2013;5:115-124. PMID: 23658500. doi:10.2147/ijwh.s33125.

67. Eder S, Baker J, Gersten J, Mabey RG, Adomako TL. Efficacy and safety of oral tranexamic acid in women with heavy menstrual bleeding and fibroids. Women's health (London, England). 2013;9(4):397-403. PMID: 23656203. doi:10.2217/whe.13.28.

68. Wang X, Qin J, Wang L, Chen J, Chen W, Tang L. Effect of high-intensity focused ultrasound on sexual function in the treatment of uterine fibroids: comparison to conventional myomectomy. Archives of gynecology and obstetrics. 2013;288(4):851-858. PMID: 23564052. doi:10.1007/s00404-013-2775-2.

69. Wang X, Qin J, Chen J, Wang L, Chen W, Tang L. The effect of high-intensity focused ultrasound treatment on immune function in patients with uterine fibroids. International journal of hyperthermia : the official journal of European Society for Hyperthermic Oncology, North American Hyperthermia Group. 2013;29(3):225-233. PMID: 23537008. doi:10.3109/02656736.2013.775672.

70. van der Kooij SM, Hehenkamp WJ, Birnie E, et al. The effect of treatment preference and treatment allocation on patients' health-related quality of life in the randomized EMMY trial. European journal of obstetrics, gynecology, and reproductive biology. 2013;169(1):69-74. PMID: 23474384. doi:10.1016/j.ejogrb.2013.01.019.

71. Ananthakrishnan G, Murray L, Ritchie M, et al. Randomized comparison of uterine artery embolization (UAE) with surgical treatment in patients with symptomatic uterine fibroids (REST trial): subanalysis of 5-year MRI findings. Cardiovascular and interventional radiology. 2013;36(3):676-681. PMID: 23070101. doi:10.1007/s00270-012-0485-y.

72. Vercellino G, Erdemoglu E, Joe A, et al. Laparoscopic temporary clipping of uterine artery during laparoscopic myomectomy. Archives of gynecology and obstetrics. 2012;286(5):1181-1186. PMID: 22714065. doi:10.1007/s00404-012-2419-y.

73. Donnez J, Tomaszewski J, Vazquez F, et al. Ulipristal acetate versus leuprolide acetate for uterine fibroids. The New England journal of medicine. 2012;366(5):421-432. PMID: 22296076. doi:10.1056/NEJMoa1103180.

74. Donnez J, Tatarchuk TF, Bouchard P, et al. Ulipristal acetate versus placebo for fibroid treatment before surgery. The New England journal of medicine. 2012;366(5):409-420. PMID: 22296075. doi:10.1056/NEJMoa1103182.

75. Esteve JL, Acosta R, Perez Y, Campos R, Hernandez AV, Texido CS. Treatment of uterine myoma with 5 or 10mg mifepristone daily during 6 months, post-treatment evolution over 12 months: double-blind randomised clinical trial. European journal of obstetrics, gynecology, and reproductive biology. 2012;161(2):202-208. PMID: 22269473. doi:10.1016/j.ejogrb.2011.12.018.

76. Wang JJ, Yang F, Gao T, Li L, Xia H, Li HF. Gasless laparoscopy versus conventional laparoscopy in uterine myomectomy: a single-centre randomized trial. The Journal of international medical research. 2011;39(1):172-178. PMID: 21672319.

77. Liu M, Cheng Z, Zhu Y, Dai H, Hu L, Xu L. Prospective comparison of laparoscopic uterine artery occlusion plus myomectomy with classic intrafascial supracervical hysterectomy for symptomatic fibroid treatment: differences in post-operative quality-of-life measures. European journal of obstetrics, gynecology, and reproductive biology. 2011;155(1):79-84. PMID: 21216518. doi:10.1016/j.ejogrb.2010.10.022.

78. Worthington-Kirsch RL, Siskin GP, Hegener P, Chesnick R. Comparison of the efficacy of the embolic agents acrylamido polyvinyl alcohol microspheres and tris-acryl gelatin microspheres for uterine artery embolization for leiomyomas: a prospective randomized controlled trial. Cardiovascular and interventional radiology. 2011;34(3):493-501. PMID: 21127866. doi:10.1007/s00270-010-0049-y.

79. Nieman LK, Blocker W, Nansel T, et al. Efficacy and tolerability of CDB-2914 treatment for symptomatic uterine fibroids: a randomized, double-blind, placebo-controlled, phase IIb study. Fertility and sterility. 2011;95(2):767-772.e761-762. PMID: 21055739. doi:10.1016/j.fertnstert.2010.09.059.

80. Zhao F, Jiao Y, Guo Z, Hou R, Wang M. Evaluation of loop ligation of larger myoma pseudocapsule combined with vasopressin on laparoscopic myomectomy. Fertility and sterility. 2011;95(2):762-766. PMID: 20883988. doi:10.1016/j.fertnstert.2010.08.059.

81. Meng X, He G, Zhang J, et al. A comparative study of fibroid ablation rates using radio frequency or high-intensity focused ultrasound. Cardiovascular and interventional radiology. 2010;33(4):794-799. PMID: 20544227. doi:10.1007/s00270-010-9909-8.

82. Rashid S, Khaund A, Murray LS, et al. The effects of uterine artery embolisation and surgical treatment on ovarian function in women with uterine fibroids. BJOG : an international journal of obstetrics and gynaecology. 2010;117(8):985-989. PMID: 20465558. doi:10.1111/j.1471-0528.2010.02579.x.

83. Hald K, Noreng HJ, Istre O, Klow NE. Uterine artery embolization versus laparoscopic occlusion of uterine arteries for leiomyomas: long-term results of a randomized comparative trial. Journal of vascular and interventional radiology : JVIR. 2009;20(10):1303-1310; quiz 1311. PMID: 19713130. doi:10.1016/j.jvir.2009.07.022.

84. Sayyah-Melli M, Tehrani-Gadim S, Dastranj-Tabrizi A, et al. Comparison of the effect of gonadotropin-releasing hormone agonist and dopamine receptor agonist on uterine myoma growth. Histologic, sonographic, and intra-operative changes. Saudi medical journal. 2009;30(8):1024-1033. PMID: 19668882.

85. Cicinelli E, Tinelli R, Colafiglio G, Saliani N. Laparoscopy vs minilaparotomy in women with symptomatic uterine myomas: a prospective randomized study. Journal of minimally invasive gynecology. 2009;16(4):422-426. PMID: 19573818. doi:10.1016/j.jmig.2009.03.011.

86. Tan J, Sun Y, Zhong B, Dai H, Wang D. A randomized, controlled study comparing minilaparotomy versus isobaric gasless laparoscopic assisted minilaparotomy myomectomy for removal of large uterine myomas: short-term outcomes. European journal of obstetrics, gynecology, and reproductive biology. 2009;145(1):104-108. PMID: 19427094. doi:10.1016/j.ejogrb.2009.04.015.

87. Parsanezhad ME, Azmoon M, Alborzi S, et al. A randomized, controlled clinical trial comparing the effects of aromatase inhibitor (letrozole) and gonadotropin-releasing hormone agonist (triptorelin) on uterine leiomyoma volume and hormonal status. Fertility and sterility. 2010;93(1):192-198. PMID: 19135657. doi:10.1016/j.fertnstert.2008.09.064.

88. Carbonell Esteve JL, Acosta R, Heredia B, Perez Y, Castaneda MC, Hernandez AV. Mifepristone for the treatment of uterine leiomyomas: a randomized controlled trial. Obstetrics and gynecology. 2008;112(5):1029-1036. PMID: 18978102. doi:10.1097/AOG.0b013e31818aa930.

89. Sesti F, Ruggeri V, Pietropolli A, Piccione E. Laparoscopically assisted vaginal hysterectomy versus vaginal hysterectomy for enlarged uterus. JSLS : Journal of the Society of Laparoendoscopic Surgeons / Society of Laparoendoscopic Surgeons. 2008;12(3):246-251. PMID: 18765046.

90. Tan J, Sun Y, Dai H, Zhong B, Wang D. A randomized trial of laparoscopic versus laparoscopic-assisted minilaparotomy myomectomy for removal of large uterine myoma: short-term outcomes. Journal of minimally invasive gynecology. 2008;15(4):402-409. PMID: 18602045. doi:10.1016/j.jmig.2008.03.010.

91. Volkers NA, Hehenkamp WJ, Smit P, Ankum WM, Reekers JA, Birnie E. Economic evaluation of uterine artery embolization versus hysterectomy in the treatment of symptomatic uterine fibroids: results from the randomized EMMY trial. Journal of vascular and interventional radiology : JVIR. 2008;19(7):1007-1016; quiz 1017. PMID: 18589314. doi:10.1016/j.jvir.2008.03.001.

92. Siskin GP, Beck A, Schuster M, Mandato K, Englander M, Herr A. Leiomyoma infarction after uterine artery embolization: a prospective randomized study comparing tris-acryl gelatin microspheres versus polyvinyl alcohol microspheres. Journal of vascular and interventional radiology : JVIR. 2008;19(1):58-65. PMID: 18192468. doi:10.1016/j.jvir.2007.08.034.

93. Hehenkamp WJ, Volkers NA, Birnie E, Reekers JA, Ankum WM. Symptomatic uterine fibroids: treatment with uterine artery embolization or hysterectomy--results from the randomized clinical Embolisation versus Hysterectomy (EMMY) Trial. Radiology. 2008;246(3):823-832. PMID: 18187401. doi:10.1148/radiol.2463070260.

94. Palomba S, Orio F, Jr., Falbo A, Oppedisano R, Tolino A, Zullo F. Tibolone reverses the cognitive effects caused by leuprolide acetate administration, improving mood and quality of life in patients with symptomatic uterine leiomyomas. Fertility and sterility. 2008;90(1):165-173. PMID: 18001721. doi:10.1016/j.fertnstert.2007.05.061.

95. Sesti F, Capobianco F, Capozzolo T, Pietropolli A, Piccione E. Isobaric gasless laparoscopy versus minilaparotomy in uterine myomectomy: a randomized trial. Surgical endoscopy. 2008;22(4):917-923. PMID: 17705083. doi:10.1007/s00464-007-9516-1.

96. Hehenkamp WJ, Volkers NA, Bartholomeus W, et al. Sexuality and body image after uterine artery embolization and hysterectomy in the treatment of uterine fibroids: a randomized comparison. Cardiovascular and interventional radiology. 2007;30(5):866-875. PMID: 17671809. doi:10.1007/s00270-007-9121-7.

97. Hehenkamp WJ, Volkers NA, Broekmans FJ, et al. Loss of ovarian reserve after uterine artery embolization: a randomized comparison with hysterectomy. Human reproduction (Oxford, England). 2007;22(7):1996-2005. PMID: 17582145. doi:10.1093/humrep/dem105.

98. Morris EP, Rymer J, Robinson J, Fogelman I. Efficacy of tibolone as "add-back therapy" in conjunction with a gonadotropin-releasing hormone analogue in the treatment of uterine fibroids. Fertility and sterility. 2008;89(2):421-428. PMID: 17572410. doi:10.1016/j.fertnstert.2007.02.064.

99. Volkers NA, Hehenkamp WJ, Birnie E, Ankum WM, Reekers JA. Uterine artery embolization versus hysterectomy in the treatment of symptomatic uterine fibroids: 2 years' outcome from the randomized EMMY trial. American journal of obstetrics and gynecology. 2007;196(6):519.e511-511. PMID: 17547877. doi:10.1016/j.ajog.2007.02.029.

100. Palomba S, Zupi E, Falbo A, et al. A multicenter randomized, controlled study comparing laparoscopic versus minilaparotomic myomectomy: reproductive outcomes. Fertility and sterility. 2007;88(4):933-941. PMID: 17434505. doi:10.1016/j.fertnstert.2006.12.047.

101. Palomba S, Zupi E, Russo T, et al. A multicenter randomized, controlled study comparing laparoscopic versus minilaparotomic myomectomy: short-term outcomes. Fertility and sterility. 2007;88(4):942-951. PMID: 17349643. doi:10.1016/j.fertnstert.2006.12.048.

102. Melli MS, Farzadi L, Madarek EO. Comparison of the effect of gonadotropin-releasing hormone analog (Diphereline) and Cabergoline (Dostinex) treatment on uterine myoma regression. Saudi medical journal. 2007;28(3):445-450. PMID: 17334477.

103. Chwalisz K, Larsen L, Mattia-Goldberg C, Edmonds A, Elger W, Winkel CA. A randomized, controlled trial of asoprisnil, a novel selective progesterone receptor modulator, in women with uterine leiomyomata. Fertility and sterility. 2007;87(6):1399-1412. PMID: 17307170. doi:10.1016/j.fertnstert.2006.11.094.

104. Edwards RD, Moss JG, Lumsden MA, et al. Uterine-artery embolization versus surgery for symptomatic uterine fibroids. The New England journal of medicine. 2007;356(4):360-370. PMID: 17251532. doi:10.1056/NEJMoa062003.

105. Hald K, Klow NE, Qvigstad E, Istre O. Laparoscopic occlusion compared with embolization of uterine vessels: a randomized controlled trial. Obstetrics and gynecology. 2007;109(1):20-27. PMID: 17197583. doi:10.1097/01.aog.0000249602.39339.31.

106. Fiscella K, Eisinger SH, Meldrum S, Feng C, Fisher SG, Guzick DS. Effect of mifepristone for symptomatic leiomyomata on quality of life and uterine size: a randomized controlled trial. Obstetrics and gynecology. 2006;108(6):1381-1387. PMID: 17138770. doi:10.1097/01.AOG.0000243776.23391.7b.

107. Casini ML, Rossi F, Agostini R, Unfer V. Effects of the position of fibroids on fertility. Gynecological endocrinology : the official journal of the International Society of Gynecological Endocrinology. 2006;22(2):106-109. PMID: 16603437. doi:10.1080/09513590600604673.

108. Vilos GA, Vilos AG, Abu-Rafea B, Pron G, Kozak R, Garvin G. Administration of goserelin acetate after uterine artery embolization does not change the reduction rate and volume of uterine myomas. Fertility and sterility. 2006;85(5):1478-1483. PMID: 16579996. doi:10.1016/j.fertnstert.2005.10.039.

109. Volkers NA, Hehenkamp WJ, Birnie E, et al. Uterine artery embolization in the treatment of symptomatic uterine fibroid tumors (EMMY trial): periprocedural results and complications. Journal of vascular and interventional radiology : JVIR. 2006;17(3):471-480. PMID: 16567671. doi:10.1097/01.rvi.0000203419.61693.84.

110. Alessandri F, Lijoi D, Mistrangelo E, Ferrero S, Ragni N. Randomized study of laparoscopic versus minilaparotomic myomectomy for uterine myomas. Journal of minimally invasive gynecology. 2006;13(2):92-97. PMID: 16527709. doi:10.1016/j.jmig.2005.11.008.

111. Hehenkamp WJ, Volkers NA, Birnie E, Reekers JA, Ankum WM. Pain and return to daily activities after uterine artery embolization and hysterectomy in the treatment of symptomatic uterine fibroids: results from the randomized EMMY trial. Cardiovascular and interventional radiology. 2006;29(2):179-187. PMID: 16447002. doi:10.1007/s00270-005-0195-9.

112. Silva-Filho AL, Werneck RA, de Magalhaes RS, Belo AV, Triginelli SA. Abdominal vs vaginal hysterectomy: a comparative study of the postoperative quality of life and satisfaction. Archives of gynecology and obstetrics. 2006;274(1):21-24. PMID: 16408185. doi:10.1007/s00404-005-0118-7.

113. Mara M, Fucikova Z, Maskova J, Kuzel D, Haakova L. Uterine fibroid embolization versus myomectomy in women wishing to preserve fertility: preliminary results of a randomized controlled trial. European journal of obstetrics, gynecology, and reproductive biology. 2006;126(2):226-233. PMID: 16293363. doi:10.1016/j.ejogrb.2005.10.008.

114. Hehenkamp WJ, Volkers NA, Donderwinkel PF, et al. Uterine artery embolization versus hysterectomy in the treatment of symptomatic uterine fibroids (EMMY trial): peri- and postprocedural results from a randomized controlled trial. American journal of obstetrics and gynecology. 2005;193(5):1618-1629. PMID: 16260201. doi:10.1016/j.ajog.2005.05.017.

115. Eisinger SH, Bonfiglio T, Fiscella K, Meldrum S, Guzick DS. Twelve-month safety and efficacy of low-dose mifepristone for uterine myomas. Journal of minimally invasive gynecology. 2005;12(3):227-233. PMID: 15922980. doi:10.1016/j.jmig.2005.01.022.

116. Palomba S, Orio F, Jr., Russo T, Falbo A, Amati A, Zullo F. Gonadotropin-releasing hormone agonist with or without raloxifene: effects on cognition, mood, and quality of life. Fertility and sterility. 2004;82(2):480-482. PMID: 15302308. doi:10.1016/j.fertnstert.2003.11.061.

117. Spies JB, Allison S, Flick P, et al. Polyvinyl alcohol particles and tris-acryl gelatin microspheres for uterine artery embolization for leiomyomas: results of a randomized comparative study. Journal of vascular and interventional radiology : JVIR. 2004;15(8):793-800. PMID: 15297582. doi:10.1097/01.rvi.0000136982.42548.5d.

118. Jirecek S, Lee A, Pavo I, Crans G, Eppel W, Wenzl R. Raloxifene prevents the growth of uterine leiomyomas in premenopausal women. Fertility and sterility. 2004;81(1):132-136. PMID: 14711556.

119. Eisinger SH, Meldrum S, Fiscella K, le Roux HD, Guzick DS. Low-dose mifepristone for uterine leiomyomata. Obstetrics and gynecology. 2003;101(2):243-250. PMID: 12576246.

120. Hwang JL, Seow KM, Tsai YL, Huang LW, Hsieh BC, Lee C. Comparative study of vaginal, laparoscopically assisted vaginal and abdominal hysterectomies for uterine myoma larger than 6 cm in diameter or uterus weighing at least 450 g: a prospective randomized study. Acta obstetricia et gynecologica Scandinavica. 2002;81(12):1132-1138. PMID: 12519109.

121. Benassi L, Rossi T, Kaihura CT, et al. Abdominal or vaginal hysterectomy for enlarged uteri: a randomized clinical trial. American journal of obstetrics and gynecology. 2002;187(6):1561-1565. PMID: 12501064.

122. Palomba S, Russo T, Orio F, Jr., et al. Effectiveness of combined GnRH analogue plus raloxifene administration in the treatment of uterine leiomyomas: a prospective, randomized, single-blind, placebo-controlled clinical trial. Human reproduction (Oxford, England). 2002;17(12):3213-3219. PMID: 12456626.

123. Palomba S, Orio F, Jr., Morelli M, et al. Raloxifene administration in premenopausal women with uterine leiomyomas: a pilot study. The Journal of clinical endocrinology and metabolism. 2002;87(8):3603-3608. PMID: 12161482. doi:10.1210/jcem.87.8.8747.

124. Simsek T, Karakus C, Trak B. Impact of different hormone replacement therapy regimens on the size of myoma uteri in postmenopausal period: tibolone versus transdermal hormonal replacement system. Maturitas. 2002;42(3):243-246. PMID: 12161049.

125. Seracchioli R, Venturoli S, Vianello F, et al. Total laparoscopic hysterectomy compared with abdominal hysterectomy in the presence of a large uterus. The Journal of the American Association of Gynecologic Laparoscopists. 2002;9(3):333-338. PMID: 12101331.

126. Yen YK, Liu WM, Yuan CC, Ng HT. Comparison of two procedures for laparoscopic-assisted vaginal hysterectomy of large myomatous uteri. The Journal of the American Association of Gynecologic Laparoscopists. 2002;9(1):63-69. PMID: 11821608.

127. Yen YK, Liu WM, Yuan CC, Ng HT. Addition of laparoscopic uterine nerve ablation to laparoscopic bipolar coagulation of uterine vessels for women with uterine myomas and dysmenorrhea. The Journal of the American Association of Gynecologic Laparoscopists. 2001;8(4):573-578. PMID: 11677339.

128. Palomba S, Sammartino A, Di Carlo C, Affinito P, Zullo F, Nappi C. Effects of raloxifene treatment on uterine leiomyomas in postmenopausal women. Fertility and sterility. 2001;76(1):38-43. PMID: 11438317.

129. Sadan O, Ginath S, Sofer D, et al. The role of tamoxifen in the treatment of symptomatic uterine leiomyomata -- a pilot study. European journal of obstetrics, gynecology, and reproductive biology. 2001;96(2):183-186. PMID: 11384804.

130. Rossetti A, Sizzi O, Soranna L, Cucinelli F, Mancuso S, Lanzone A. Long-term results of laparoscopic myomectomy: recurrence rate in comparison with abdominal myomectomy. Human reproduction (Oxford, England). 2001;16(4):770-774. PMID: 11278231.

131. Soriano D, Goldstein A, Lecuru F, Darai E. Recovery from vaginal hysterectomy compared with laparoscopy-assisted vaginal hysterectomy: a prospective, randomized, multicenter study. Acta obstetricia et gynecologica Scandinavica. 2001;80(4):337-341. PMID: 11264609.

132. Soysal ME, Soysal SK, Vicdan K. Thermal balloon ablation in myoma-induced menorrhagia under local anesthesia. Gynecologic and obstetric investigation. 2001;51(2):128-133. PMID: 11223708. doi:52908.

133. Takeuchi H, Kobori H, Kikuchi I, Sato Y, Mitsuhashi N. A prospective randomized study comparing endocrinological and clinical effects of two types of GnRH agonists in cases of uterine leiomyomas or endometriosis. The journal of obstetrics and gynaecology research. 2000;26(5):325-331. PMID: 11147718.

134. Seracchioli R, Rossi S, Govoni F, et al. Fertility and obstetric outcome after laparoscopic myomectomy of large myomata: a randomized comparison with abdominal myomectomy. Human reproduction (Oxford, England). 2000;15(12):2663-2668. PMID: 11098042.

135. Ferrari MM, Berlanda N, Mezzopane R, Ragusa G, Cavallo M, Pardi G. Identifying the indications for laparoscopically assisted vaginal hysterectomy: a prospective, randomised comparison with abdominal hysterectomy in patients with symptomatic uterine fibroids. BJOG : an international journal of obstetrics and gynaecology. 2000;107(5):620-625. PMID: 10826576.

136. Fedele L, Bianchi S, Raffaelli R, Zanconato G. A randomized study of the effects of tibolone and transdermal estrogen replacement therapy in postmenopausal women with uterine myomas. European journal of obstetrics, gynecology, and reproductive biology. 2000;88(1):91-94. PMID: 10659924.

137. Parazzini F, Bortolotti A, Chiantera V, et al. Goserelin acetate to avoid hysterectomy in pre-menopausal women with fibroids requiring surgery. European journal of obstetrics, gynecology, and reproductive biology. 1999;87(1):31-33. PMID: 10579613.

138. Palomba S, Affinito P, Tommaselli GA, Nappi C. A clinical trial of the effects of tibolone administered with gonadotropin-releasing hormone analogues for the treatment of uterine leiomyomata. Fertility and sterility. 1998;70(1):111-118. PMID: 9660431.

139. Gregoriou O, Vitoratos N, Papadias C, Konidaris S, Costomenos D, Chryssikopoulos A. Effect of tibolone on postmenopausal women with myomas. Maturitas. 1997;27(2):187-191. PMID: 9255754.

140. Broekmans FJ, Hompes PG, Heitbrink MA, et al. Two-step gonadotropin-releasing hormone agonist treatment of uterine leiomyomas: standard-dose therapy followed by reduced-dose therapy. American journal of obstetrics and gynecology. 1996;175(5):1208-1216. PMID: 8942490.

141. Mais V, Ajossa S, Guerriero S, Mascia M, Solla E, Melis GB. Laparoscopic versus abdominal myomectomy: a prospective, randomized trial to evaluate benefits in early outcome. American journal of obstetrics and gynecology. 1996;174(2):654-658. PMID: 8623802.

142. Scialli AR, Jestila KJ. Sustained benefits of leuprolide acetate with or without subsequent medroxyprogesterone acetate in the nonsurgical management of leiomyomata uteri. Fertility and sterility. 1995;64(2):313-320. PMID: 7615109.

143. Friedman AJ, Daly M, Juneau-Norcross M, Gleason R, Rein MS, LeBoff M. Long-term medical therapy for leiomyomata uteri: a prospective, randomized study of leuprolide acetate depot plus either oestrogen-progestin or progestin 'add-back' for 2 years. Human reproduction (Oxford, England). 1994;9(9):1618-1625. PMID: 7836510.

144. Friedman AJ, Daly M, Juneau-Norcross M, et al. A prospective, randomized trial of gonadotropin-releasing hormone agonist plus estrogen-progestin or progestin "add-back" regimens for women with leiomyomata uteri. The Journal of clinical endocrinology and metabolism. 1993;76(6):1439-1445. PMID: 8501148. doi:10.1210/jcem.76.6.8501148.

145. Carr BR, Marshburn PB, Weatherall PT, et al. An evaluation of the effect of gonadotropin-releasing hormone analogs and medroxyprogesterone acetate on uterine leiomyomata volume by magnetic resonance imaging: a prospective, randomized, double blind, placebo-controlled, crossover trial. The Journal of clinical endocrinology and metabolism. 1993;76(5):1217-1223. PMID: 8496313. doi:10.1210/jcem.76.5.8496313.

146. Watanabe Y, Nakamura G, Matsuguchi H, Nozaki M, Sano M, Nakano H. Efficacy of a low-dose leuprolide acetate depot in the treatment of uterine leiomyomata in Japanese women. Fertility and sterility. 1992;58(1):66-71. PMID: 1624025.

147. Friedman AJ, Hoffman DI, Comite F, Browneller RW, Miller JD. Treatment of leiomyomata uteri with leuprolide acetate depot: a double-blind, placebo-controlled, multicenter study. The Leuprolide Study Group. Obstetrics and gynecology. 1991;77(5):720-725. PMID: 1901638.

148. Fedele L, Bianchi S, Baglioni A, Arcaini L, Marchini M, Bocciolone L. Intranasal buserelin versus surgery in the treatment of uterine leiomyomata: long-term follow-up. European journal of obstetrics, gynecology, and reproductive biology. 1991;38(1):53-57. PMID: 1899079.

149. Costantini S, Anserini P, Valenzano M, Remorgida V, Venturini PL, De Cecco L. Luteinizing hormone-releasing hormone analog therapy of uterine fibroid: analysis of results obtained with buserelin administered intranasally and goserelin administered subcutaneously as a monthly depot. European journal of obstetrics, gynecology, and reproductive biology. 1990;37(1):63-69. PMID: 2142921.

150. Friedman AJ, Harrison-Atlas D, Barbieri RL, Benacerraf B, Gleason R, Schiff I. A randomized, placebo-controlled, double-blind study evaluating the efficacy of leuprolide acetate depot in the treatment of uterine leiomyomata. Fertility and sterility. 1989;51(2):251-256. PMID: 2492232.

151. Friedman AJ, Barbieri RL, Doubilet PM, Fine C, Schiff I. A randomized, double-blind trial of a gonadotropin releasing-hormone agonist (leuprolide) with or without medroxyprogesterone acetate in the treatment of leiomyomata uteri. Fertility and sterility. 1988;49(3):404-409. PMID: 2963759.

152. Tosun AK, Tosun I, Suer N. Comparison of levonorgestrel-releasing intrauterine device with oral progestins in heavy menstrual bleeding (HMB) cases with uterine leiomyoma (LNG-IUD and oral progestin usage in myoma uteri). Pakistan journal of medical sciences. 2014;30(4):834-839. PMID: 25097527.

153. Nik Hazlina NH, I MP, Nor Aliza AG, J SMS. Clinical study to compare the efficacy and adverse effects of Nona Roguy herbal formulation and gonadotrophin releasing hormone agonist (GnRH) in the treatment of uterine fibroids. International Medical Journal. 2005;12(4):295-302. PMID: 2006015151.

154. Kramer B, Hahn M, Taran FA, Kraemer D, Isaacson KB, Brucker SY. Interim analysis of a randomized controlled trial comparing laparoscopic radiofrequency volumetric thermal ablation of uterine fibroids with laparoscopic myomectomy. International journal of gynaecology and obstetrics: the official organ of the International Federation of Gynaecology and Obstetrics. 2016;133(2):206-211. PMID: 26892690. doi:10.1016/j.ijgo.2015.10.008.

155. Wang X, Zhang Z, Pan J, Zhang W. Effects of embolic agents with different particle sizes on interventional treatment of uterine fibroids. Pakistan journal of medical sciences. 2015;31(6):1490-1495. PMID: 26870122. doi:10.12669/pjms.316.7955.

156. Jacoby VL, Kohi MP, Poder L, et al. PROMISe trial: a pilot, randomized, placebo-controlled trial of magnetic resonance guided focused ultrasound for uterine fibroids. Fertility and sterility. 2016;105(3):773-780. PMID: 26658133. doi:10.1016/j.fertnstert.2015.11.014.

157. Donnez J, Donnez O, Matule D, et al. Long-term medical management of uterine fibroids with ulipristal acetate. Fertility and sterility. 2016;105(1):165-173.e164. PMID: 26477496. doi:10.1016/j.fertnstert.2015.09.032.

158. Macnaught G, Ananthakrishnan G, Hinksman L, et al. Can (1)H MR Spectroscopy be Used to Assess the Success of Uterine Artery Embolisation? Cardiovascular and interventional radiology. 2016;39(3):376-384. PMID: 26183465. doi:10.1007/s00270-015-1179-z.

159. Hahn M, Brucker S, Kraemer D, et al. Radiofrequency Volumetric Thermal Ablation of Fibroids and Laparoscopic Myomectomy: Long-Term Follow-up From a Randomized Trial. Geburtshilfe und Frauenheilkunde. 2015;75(5):442-449. PMID: 26097247. doi:10.1055/s-0035-1545931.

160. Yuk JS, Ji HY, Kim KH, Lee JH. Single-port laparoscopically assisted-transumbilical ultraminilaparotomic myomectomy (SPLA-TUM) versus single port laparoscopic myomectomy: a randomized controlled trial. European journal of obstetrics, gynecology, and reproductive biology. 2015;188:83-87. PMID: 25796058. doi:10.1016/j.ejogrb.2015.03.004.

161. Bronshtein M, Blumenfeld Z. The value of TVS after cervical suture. Ultrasound in obstetrics & gynecology : the official journal of the International Society of Ultrasound in Obstetrics and Gynecology. 2016. PMID: 27255211. doi:10.1002/uog.15984.

162. Okin CR, Guido RS, Meyn LA, Ramanathan S. Vasopressin during abdominal hysterectomy: a randomized controlled trial. Obstetrics and gynecology. 2001;97(6):867-872. PMID: 11384687.

163. Lethaby A, Vollenhoven B, Sowter M. Efficacy of pre-operative gonadotrophin hormone releasing analogues for women with uterine fibroids undergoing hysterectomy or myomectomy: a systematic review. BJOG : an international journal of obstetrics and gynaecology. 2002;109(10):1097-1108. PMID: 12387461.

164. Rivlin ME, Patel RB, Hess LW, Hess DB, Meeks GR. Leuprolide acetate depot for the treatment of uterine leiomyomas. Changes in bone density, uterine volume and uterine vascular resistive index. The Journal of reproductive medicine. 1994;39(9):663-666. PMID: 7807474.

165. Sangwan VG, Sangwan M, Mahendroo R, Garg MK, Munde H, Lakra P. Uterine Leiomyoma Presenting as Huge Retroperitoneal Mass: A Rare Case Report. Journal of gynecologic surgery. 2015;31(4):241-243. PMID: 2015225586. doi:http://dx.doi.org/10.1089/gyn.2014.0135.

166. Katzka DA, Smyrk TC, Chial HJ, Topazian MD. Esophageal leiomyomatosis presenting as achalasia diagnosed by high-resolution manometry and endoscopic core biopsy. Gastrointestinal endoscopy. 2012;76(1):216-217. PMID: 22305508. doi:10.1016/j.gie.2011.07.076.

167. Higham JM, O'Brien PM, Shaw RW. Assessment of menstrual blood loss using a pictorial chart. British journal of obstetrics and gynaecology. 1990;97(8):734-739. PMID: 2400752.

168. Stewart EA, Rabinovici J, Tempany CM, et al. Clinical outcomes of focused ultrasound surgery for the treatment of uterine fibroids. Fertility and sterility. 2006;85(1):22-29. PMID: 16412721. doi:10.1016/j.fertnstert.2005.04.072.

169. Hindley J, Gedroyc WM, Regan L, et al. MRI guidance of focused ultrasound therapy of uterine fibroids: early results. AJR American journal of roentgenology. 2004;183(6):1713-1719. PMID: 15547216. doi:10.2214/ajr.183.6.01831713.

170. Lieng M, Berner E, Busund B. Risk of morcellation of uterine leiomyosarcomas in laparoscopic supracervical hysterectomy and laparoscopic myomectomy, a retrospective trial including 4791 women. Journal of minimally invasive gynecology. 2015;22(3):410-414. PMID: 25460521. doi:10.1016/j.jmig.2014.10.022.

171. Skorstad M, Kent A, Lieng M. Uterine leiomyosarcoma - incidence, treatment, and the impact of morcellation. A nationwide cohort study. Acta obstetricia et gynecologica Scandinavica. 2016;95(9):984-990. PMID: 27223683. doi:10.1111/aogs.12930.

172. Bojahr B, De Wilde RL, Tchartchian G. Malignancy rate of 10,731 uteri morcellated during laparoscopic supracervical hysterectomy (LASH). Archives of gynecology and obstetrics. 2015;292(3):665-672. PMID: 25820974. doi:10.1007/s00404-015-3696-z.

173. Balgobin S, Maldonado PA, Chin K, Schaffer JI, Hamid CA. Safety Of Manual Morcellation Following Vaginal Or Laparoscopic-Assisted Vaginal Hysterectomy. Journal of minimally invasive gynecology. 2016. PMID: 26802908. doi:10.1016/j.jmig.2016.01.014.

174. Rodriguez AM, Asoglu MR, Sak ME, Tan A, Borahay MA, Kilic GS. Incidence of occult leiomyosarcoma in presumed morcellation cases: a database study. European journal of obstetrics, gynecology, and reproductive biology. 2015;197:31-35. PMID: 26699101. doi:10.1016/j.ejogrb.2015.11.009.

175. Zhao WC, Bi FF, Li D, Yang Q. Incidence and clinical characteristics of unexpected uterine sarcoma after hysterectomy and myomectomy for uterine fibroids: a retrospective study of 10,248 cases. OncoTargets and therapy. 2015;8:2943-2948. PMID: 26508879. doi:10.2147/ott.s92978.

176. Picerno TM, Wasson MN, Gonzalez Rios AR, et al. Morcellation and the Incidence of Occult Uterine Malignancy: A Dual-Institution Review. International journal of gynecological cancer : official journal of the International Gynecological Cancer Society. 2016;26(1):149-155. PMID: 26332395. doi:10.1097/igc.0000000000000558.

177. Zhang J, Zhang J, Dai Y, Zhu L, Lang J, Leng J. Clinical characteristics and management experience of unexpected uterine sarcoma after myomectomy. International journal of gynaecology and obstetrics: the official organ of the International Federation of Gynaecology and Obstetrics. 2015;130(2):195-199. PMID: 26117552. doi:10.1016/j.ijgo.2015.01.009.

178. Clark Donat L, Clark M, Tower AM, et al. Transvaginal morcellation. JSLS : Journal of the Society of Laparoendoscopic Surgeons / Society of Laparoendoscopic Surgeons. 2015;19(2). PMID: 26005318. doi:10.4293/jsls.2014.00255.

179. Huang PS, Sheu BC, Huang SC, Chang WC. Intraligamental Myomectomy Strategy Using Laparoscopy. Journal of minimally invasive gynecology. 2016;23(6):954-961. PMID: 27327965. doi:10.1016/j.jmig.2016.06.007.

180. Kinay T, Basarir ZO, Tuncer SF, et al. Is a history of cesarean section a risk factor for abnormal uterine bleeding in patients with uterine leiomyoma? Saudi medical journal. 2016;37(8):871-876. PMID: 27464864. doi:10.15537/smj.2016.8.14711.

181. Smits RM, De Kruif JH, Van Heteren CF. Complication rate of uterine morcellation in laparoscopic supracervical hysterectomy: a retrospective cohort study. European journal of obstetrics, gynecology, and reproductive biology. 2016;199:179-182. PMID: 26943477. doi:10.1016/j.ejogrb.2016.02.022.

182. Geethamala K, Murthy VS, Vani BR, Rao S. Uterine Leiomyomas: An ENIGMA. Journal of mid-life health. 2016;7(1):22-27. PMID: 27134477. doi:10.4103/0976-7800.179170.

183. Gao Z, Li L, Meng Y. A Retrospective Analysis of the Impact of Myomectomy on Survival in Uterine Sarcoma. PloS one. 2016;11(2):e0148050. PMID: 26828206. doi:10.1371/journal.pone.0148050.

184. Raine-Bennett T, Tucker LY, Zaritsky E, et al. Occult Uterine Sarcoma and Leiomyosarcoma: Incidence of and Survival Associated With Morcellation. Obstetrics and gynecology. 2016;127(1):29-39. PMID: 26646120. doi:10.1097/aog.0000000000001187.

185. Cormio G, Loizzi V, Ceci O, Leone L, Selvaggi L, Bettocchi S. Unsuspected diagnosis of uterine leiomyosarcoma after laparoscopic myomectomy. Journal of obstetrics and gynaecology : the journal of the Institute of Obstetrics and Gynaecology. 2015;35(2):211-212. PMID: 25057886. doi:10.3109/01443615.2014.937332.

186. Nemec W, Inwald EC, Buchholz S, Klinkhammer Schalke M, Gerken M, Ortmann O. Effects of morcellation on long-term outcomes in patients with uterine leiomyosarcoma. Archives of gynecology and obstetrics. 2016;294(4):825-831. PMID: 27105972. doi:10.1007/s00404-016-4086-x.

187. Brohl AS, Li L, Andikyan V, et al. Age-stratified risk of unexpected uterine sarcoma following surgery for presumed benign leiomyoma. The oncologist. 2015;20(4):433-439. PMID: 25765878. doi:10.1634/theoncologist.2014-0361.

188. Zhang J, Li T, Zhang J, Zhu L, Lang J, Leng J. Clinical Characteristics and Prognosis of Unexpected Uterine Sarcoma After Hysterectomy for Presumed Myoma With and Without Transvaginal Scalpel Morcellation. International journal of gynecological cancer : official journal of the International Gynecological Cancer Society. 2016. PMID: 26807642. doi:10.1097/igc.0000000000000638.

189. Cusido M, Fargas F, Baulies S, et al. Impact of Surgery on the Evolution of Uterine Sarcomas. Journal of minimally invasive gynecology. 2015;22(6):1068-1074. PMID: 26070730. doi:10.1016/j.jmig.2015.05.024.

190. Brown J, Taylor K, Ramirez PT, et al. Laparoscopic supracervical hysterectomy with morcellation: should it stay or should it go? Journal of minimally invasive gynecology. 2015;22(2):185-192. PMID: 25242233. doi:10.1016/j.jmig.2014.09.005.

191. Serur E, Zambrano N, Brown K, Clemetson E, Lakhi N. Extracorporeal Manual Morcellation of Very Large Uteri Within an Enclosed Endoscopic Bag: Our 5-Year Experience. Journal of minimally invasive gynecology. 2016;23(6):903-908. PMID: 27058770. doi:10.1016/j.jmig.2016.03.016.

192. Vercellini P, Cribiu FM, Bosari S, et al. Prevalence of unexpected leiomyosarcoma at myomectomy: a descriptive study. American journal of obstetrics and gynecology. 2016;214(2):292-294. PMID: 26450408. doi:10.1016/j.ajog.2015.09.092.

193. Rechberger T, Miotla P, Futyma K, et al. Power morcellation for women undergoing laparoscopic supracervical hysterectomy - safety of procedure and clinical experience from 426 cases. Ginekologia polska. 2016;87(8):546-551. PMID: 27629127. doi:10.5603/gp.2016.0042.

194. Raspagliesi F, Maltese G, Bogani G, et al. Morcellation worsens survival outcomes in patients with undiagnosed uterine leiomyosarcomas: A retrospective MITO group study. Gynecologic oncology. doi:10.1016/j.ygyno.2016.11.002.

195. Sandberg EM, van den Haak L, Bosse T, Jansen FW. Disseminated leiomyoma cells can be identified following conventional myomectomy. BJOG : an international journal of obstetrics and gynaecology. 2016. PMID: 27533508. doi:10.1111/1471-0528.14265.

196. Toubia T, Moulder JK, Schiff LD, Clarke-Pearson D, O'Connor SM, Siedhoff MT. Peritoneal Washings After Power Morcellation in Laparoscopic Myomectomy: A Pilot Study. Journal of minimally invasive gynecology. 2016;23(4):578-581. PMID: 26867701. doi:10.1016/j.jmig.2016.02.001.

197. Song T, Kim TJ, Lee SH, Kim TH, Kim WY. Laparoendoscopic single-site myomectomy compared with conventional laparoscopic myomectomy: a multicenter, randomized, controlled trial. Fertility and sterility. 2015;104(5):1325-1331. PMID: 26263079. doi:10.1016/j.fertnstert.2015.07.1137.

198. Lee JY, Kim HS, Nam EJ, Kim SW, Kim S, Kim YT. Outcomes of uterine sarcoma found incidentally after uterus-preserving surgery for presumed benign disease. BMC cancer. 2016;16(1):675. PMID: 27553655. doi:10.1186/s12885-016-2727-x.

199. Lin KH, Torng PL, Tsai KH, Shih HJ, Chen CL. Clinical outcome affected by tumor morcellation in unexpected early uterine leiomyosarcoma. Taiwanese journal of obstetrics & gynecology. 2015;54(2):172-177. PMID: 25951723. doi:10.1016/j.tjog.2015.03.001.

200. Tan A, Salfinger S, Tan J, Cohen P. Morcellation of occult uterine malignancies: an Australian single institution retrospective study. The Australian & New Zealand journal of obstetrics & gynaecology. 2015;55(5):503-506. PMID: 26314239. doi:10.1111/ajo.12401.

201. Kamikabeya TS, Etchebehere RM, Nomelini RS, Murta EF. Gynecological malignant neoplasias diagnosed after hysterectomy performed for leiomyoma in a university hospital. European journal of gynaecological oncology. 2010;31(6):651-653. PMID: 21319509.

202. Theben JU, Schellong AR, Altgassen C, Kelling K, Schneider S, Grosse-Drieling D. Unexpected malignancies after laparoscopic-assisted supracervical hysterectomies (LASH): an analysis of 1,584 LASH cases. Archives of gynecology and obstetrics. 2013;287(3):455-462. PMID: 23053310. doi:10.1007/s00404-012-2559-0.

203. Takamizawa S, Minakami H, Usui R, et al. Risk of complications and uterine malignancies in women undergoing hysterectomy for presumed benign leiomyomas. Gynecologic and obstetric investigation. 1999;48(3):193-196. PMID: 10545745. doi:10172.

204. Morice P, Rodriguez A, Rey A, et al. Prognostic value of initial surgical procedure for patients with uterine sarcoma: analysis of 123 patients. European journal of gynaecological oncology. 2003;24(3-4):237-240. PMID: 12807231.

205. Einstein MH, Barakat RR, Chi DS, et al. Management of uterine malignancy found incidentally after supracervical hysterectomy or uterine morcellation for presumed benign disease. International journal of gynecological cancer : official journal of the International Gynecological Cancer Society. 2008;18(5):1065-1070. PMID: 17986239. doi:10.1111/j.1525-1438.2007.01126.x.

206. Sinha R, Hegde A, Mahajan C, Dubey N, Sundaram M. Laparoscopic myomectomy: do size, number, and location of the myomas form limiting factors for laparoscopic myomectomy? Journal of minimally invasive gynecology. 2008;15(3):292-300. PMID: 18439500. doi:10.1016/j.jmig.2008.01.009.

207. Perri T, Korach J, Sadetzki S, Oberman B, Fridman E, Ben-Baruch G. Uterine leiomyosarcoma: does the primary surgical procedure matter? International journal of gynecological cancer : official journal of the International Gynecological Cancer Society. 2009;19(2):257-260. PMID: 19396005. doi:10.1111/IGC.0b013e31819a1f8f.

208. Park JY, Park SK, Kim DY, et al. The impact of tumor morcellation during surgery on the prognosis of patients with apparently early uterine leiomyosarcoma. Gynecologic oncology. 2011;122(2):255-259. PMID: 21565389. doi:10.1016/j.ygyno.2011.04.021.

209. Seidman MA, Oduyebo T, Muto MG, Crum CP, Nucci MR, Quade BJ. Peritoneal dissemination complicating morcellation of uterine mesenchymal neoplasms. PloS one. 2012;7(11):e50058. PMID: 23189178. doi:10.1371/journal.pone.0050058.

210. Oduyebo T, Rauh-Hain AJ, Meserve EE, et al. The value of re-exploration in patients with inadvertently morcellated uterine sarcoma. Gynecologic oncology. 2014;132(2):360-365. PMID: 24296345. doi:10.1016/j.ygyno.2013.11.024.

211. Tan-Kim J, Hartzell KA, Reinsch CS, et al. Uterine sarcomas and parasitic myomas after laparoscopic hysterectomy with power morcellation. American journal of obstetrics and gynecology. 2014. PMID: 25499259. doi:10.1016/j.ajog.2014.12.002.

212. Graebe K, Garcia-Soto A, Aziz M, et al. Incidental power morcellation of malignancy: A retrospective cohort study. Gynecologic oncology. 2015;136(2):274-277. PMID: 25740603. doi:10.1016/j.ygyno.2014.11.018.

213. Rohatgi A. WebPlotDigitizer v. 3.11. 2017.

214. Pritts EA, Parker WH, Brown J, Olive DL. Outcome of occult uterine leiomyosarcoma after surgery for presumed uterine fibroids: a systematic review. Journal of minimally invasive gynecology. 2015;22(1):26-33. PMID: 25193444. doi:10.1016/j.jmig.2014.08.781.

215. Tsivian A, Sidi AA. Port site metastases in urological laparoscopic surgery. The Journal of urology. 2003;169(4):1213-1218. PMID: 12629331. doi:10.1097/01.ju.0000035910.75480.4b.

216. Nannapaneni P, Naik R, de Barros Lopes A, Monaghan JM. Intra-abdominal bleed following LLETZ. Journal of obstetrics and gynaecology : the journal of the Institute of Obstetrics and Gynaecology. 2002;22(1):99-100. PMID: 12521750.

217. Moroni RM, Martins WP, Ferriani RA, et al. Add-back therapy with GnRH analogues for uterine fibroids. The Cochrane database of systematic reviews. 2015;3:Cd010854. PMID: 25793972. doi:10.1002/14651858.CD010854.pub2.

218. Gupta JK, Sinha A, Lumsden MA, Hickey M. Uterine artery embolization for symptomatic uterine fibroids. The Cochrane database of systematic reviews. 2014;12:Cd005073. PMID: 25541260. doi:10.1002/14651858.CD005073.pub4.

219. Peitsidis P, Koukoulomati A. Tranexamic acid for the management of uterine fibroid tumors: A systematic review of the current evidence. World journal of clinical cases. 2014;2(12):893-898. PMID: 25516866. doi:10.12998/wjcc.v2.i12.893.

220. Bhave Chittawar P, Franik S, Pouwer AW, Farquhar C. Minimally invasive surgical techniques versus open myomectomy for uterine fibroids. The Cochrane database of systematic reviews. 2014;10:Cd004638. PMID: 25331441. doi:10.1002/14651858.CD004638.pub3.

221. Panagiotopoulou N, Nethra S, Karavolos S, Ahmad G, Karabis A, Burls A. Uterine-sparing minimally invasive interventions in women with uterine fibroids: a systematic review and indirect treatment comparison meta-analysis. Acta obstetricia et gynecologica Scandinavica. 2014;93(9):858-867. PMID: 24909191. doi:10.1111/aogs.12441.

222. Jiang W, Shen Q, Chen M, et al. Levonorgestrel-releasing intrauterine system use in premenopausal women with symptomatic uterine leiomyoma: a systematic review. Steroids. 2014;86:69-78. PMID: 24832215. doi:10.1016/j.steroids.2014.05.002.

223. Clark NA, Mumford SL, Segars JH. Reproductive impact of MRI-guided focused ultrasound surgery for fibroids: a systematic review of the evidence. Current opinion in obstetrics & gynecology. 2014;26(3):151-161. PMID: 24751998. doi:10.1097/gco.0000000000000070.

224. Kamath MS, Kalampokas EE, Kalampokas TE. Use of GnRH analogues pre-operatively for hysteroscopic resection of submucous fibroids: a systematic review and meta-analysis. European journal of obstetrics, gynecology, and reproductive biology. 2014;177:11-18. PMID: 24702901. doi:10.1016/j.ejogrb.2014.03.009.

225. Das R, Champaneria R, Daniels JP, Belli AM. Comparison of embolic agents used in uterine artery embolisation: a systematic review and meta-analysis. Cardiovascular and interventional radiology. 2014;37(5):1179-1190. PMID: 24305981. doi:10.1007/s00270-013-0790-0.

226. Song H, Lu D, Navaratnam K, Shi G. Aromatase inhibitors for uterine fibroids. The Cochrane database of systematic reviews. 2013;10:Cd009505. PMID: 24151065. doi:10.1002/14651858.CD009505.pub2.

227. Gizzo S, Saccardi C, Patrelli TS, et al. Magnetic resonance-guided focused ultrasound myomectomy: safety, efficacy, subsequent fertility and quality-of-life improvements, a systematic review. Reproductive sciences (Thousand Oaks, Calif). 2014;21(4):465-476. PMID: 23868442. doi:10.1177/1933719113497289.

228. Sangkomkamhang US, Lumbiganon P, Laopaiboon M, Mol BW. Progestogens or progestogen-releasing intrauterine systems for uterine fibroids. The Cochrane database of systematic reviews. 2013;2:Cd008994. PMID: 23450594. doi:10.1002/14651858.CD008994.pub2.

229. Martin J, Bhanot K, Athreya S. Complications and reinterventions in uterine artery embolization for symptomatic uterine fibroids: a literature review and meta analysis. Cardiovascular and interventional radiology. 2013;36(2):395-402. PMID: 23152035. doi:10.1007/s00270-012-0505-y.

230. Toor SS, Jaberi A, Macdonald DB, McInnes MD, Schweitzer ME, Rasuli P. Complication rates and effectiveness of uterine artery embolization in the treatment of symptomatic leiomyomas: a systematic review and meta-analysis. AJR American journal of roentgenology. 2012;199(5):1153-1163. PMID: 23096193. doi:10.2214/ajr.11.8362.

231. Deng L, Wu T, Chen XY, Xie L, Yang J. Selective estrogen receptor modulators (SERMs) for uterine leiomyomas. The Cochrane database of systematic reviews. 2012;10:Cd005287. PMID: 23076912. doi:10.1002/14651858.CD005287.pub4.

232. van der Kooij SM, Bipat S, Hehenkamp WJ, Ankum WM, Reekers JA. Uterine artery embolization versus surgery in the treatment of symptomatic fibroids: a systematic review and metaanalysis. American journal of obstetrics and gynecology. 2011;205(4):317.e311-318. PMID: 21641570. doi:10.1016/j.ajog.2011.03.016.

233. Chen I, Motan T, Kiddoo D. Gonadotropin-releasing hormone agonist in laparoscopic myomectomy: systematic review and meta-analysis of randomized controlled trials. Journal of minimally invasive gynecology. 2011;18(3):303-309. PMID: 21545958. doi:10.1016/j.jmig.2011.02.010.

234. Yi YX, Zhang W, Guo WR, Zhou Q, Su Y. Meta-analysis: the comparison of clinical results between vaginal and laparoscopic myomectomy. Archives of gynecology and obstetrics. 2011;283(6):1275-1289. PMID: 21234758. doi:10.1007/s00404-011-1836-7.

235. Zapata LB, Whiteman MK, Tepper NK, Jamieson DJ, Marchbanks PA, Curtis KM. Intrauterine device use among women with uterine fibroids: a systematic review. Contraception. 2010;82(1):41-55. PMID: 20682142. doi:10.1016/j.contraception.2010.02.011.

236. Varma R, Sinha D, Gupta JK. Non-contraceptive uses of levonorgestrel-releasing hormone system (LNG-IUS)--a systematic enquiry and overview. European journal of obstetrics, gynecology, and reproductive biology. 2006;125(1):9-28. PMID: 16325993. doi:10.1016/j.ejogrb.2005.10.029.

237. Steinauer J, Pritts EA, Jackson R, Jacoby AF. Systematic review of mifepristone for the treatment of uterine leiomyomata. Obstetrics and gynecology. 2004;103(6):1331-1336. PMID: 15172874. doi:10.1097/01.AOG.0000127622.63269.8b.

238. Nieboer TE, Johnson N, Lethaby A, et al. Surgical approach to hysterectomy for benign gynaecological disease. The Cochrane database of systematic reviews. 2009(3):Cd003677. PMID: 19588344. doi:10.1002/14651858.CD003677.pub4.

239. Metwally M, Cheong YC, Horne AW. Surgical treatment of fibroids for subfertility. The Cochrane database of systematic reviews. 2012;11:Cd003857. PMID: 23152222. doi:10.1002/14651858.CD003857.pub3.

240. American Cancer Society. Uterine Sarcoma: Survival Rates for Uterine Sarcoma by Stage. 2016; http://www.cancer.org/cancer/uterinesarcoma/detailedguide/uterine-sarcoma-survival-rates. Accessed July 2016.

241. Parker WH, Kaunitz AM, Pritts EA, et al. U.S. Food and Drug Administration's Guidance Regarding Morcellation of Leiomyomas: Well-Intentioned, But Is It Harmful for Women? Obstetrics and gynecology. 2016;127(1):18-22. PMID: 26646134. doi:10.1097/aog.0000000000001157.

242. Morrison A, Polisena J, Husereau D, et al. The effect of English-language restriction on systematic review-based meta-analyses: a systematic review of empirical studies. Int J Technol Assess Health Care. 2012;28(2):138-144. PMID: 22559755. doi:10.1017/S0266462312000086.

243. Juni P, Holenstein F, Sterne J, Bartlett C, Egger M. Direction and impact of language bias in meta-analyses of controlled trials: empirical study. Int J Epidemiol. 2002;31(1):115-123. PMID: 11914306.

244. Moher D, Pham B, Klassen TP, et al. What contributions do languages other than English make on the results of meta-analyses? J Clin Epidemiol. 2000;53(9):964-972. PMID: 11004423.

Abbreviations

Abbreviation	Definition
AMSS	Aberdeen menorrhagia severity scale
BISF-W	Brief Index of Sexual Functioning for Women
BMI	body mass index
CEUS	contrast enhanced ultrasound
CI	confidence interval
cm	Centimeter
cm^3	cubic centimeters
E2	Estradiol
EQ-5D™	EuroQol Group standardized quality of life instrument, EQ-5D
FSH	follicle-stimulating hormone
g	Gram
g/dL	grams per deciliter
GnRH	gonadotropin-releasing hormone
GSP	gelatin sponge particle
HRQoL	health-related quality of life
HIFU	high intensity focused ultrasound
IQR	interquartile range
IM	Intramuscular
IU	international units
IUD	intrauterine device
IU/L	international units per liter
mg	Milligram
ml	Milliliter
MPA	Medroxyprogesterone Acetate
MR	magnetic resonance
MRgFUS	magnetic resonance guided focused ultrasound
MRI	magnetic resonance imaging
N	Number
NA	not applicable
NR	not reported
NS	not significant
NSAID	nonsteroidal anti-inflammatory drug
OR	odds ratio
PBAC	pictorial blood loss assessment chart
PVA	polyvinyl alcohol microspheres
RCT	randomized controlled trial
SAQ	Sexual Activity Questionnaire
SD	standard deviation
SEM	standard error of mean
UAE	uterine artery embolization
UFS-QOL	Uterine Fibroid Symptom and Health-Related Quality of Life Questionnaire
UK	United Kingdom
U.S.	United States
VAS	Visual Analog Scale

Abbreviation	Definition
vs.	Versus

Appendix A. Search Strategy

Key Question 1 and Key Question 2 Search Strategies

Table A-1. PubMed (3/24/15)

Search	Query	Records
1	((leiomyoma[mh]) OR (fibroma[mh] AND (uterine diseases[mh] OR uterus[mh])))	17656
2	(Uterine[tiab] AND (fibroma*[tiab] OR fibroid*[tiab] OR leiomyoma*[tiab] OR myoma*[tiab] OR fibromyoma*[tiab])) OR (submucous fibroid*[tiab] OR submucosal fibroid*[tiab] OR Intramural fibroids [tiab]) NOT medline[sb]	985
3	#1 OR #2	18621
4	("Mifepristone"[Mesh] OR "ulipristal"[Supplementary Concept] OR "Anti-Inflammatory Agents, Non-Steroidal"[Mesh] OR "Antifibrinolytic Agents"[Mesh] OR "Goserelin"[Mesh] OR "cetrorelix"[Supplementary Concept] OR "Selective Estrogen Receptor Modulators"[Mesh] OR "Levonorgestrel"[Mesh] OR "Nafarelin"[Mesh] OR "Triptorelin Pamoate"[Mesh] OR "Leuprolide"[Mesh])	90459
5	(Mifepristone[tiab] OR Ulipristal acetate[tiab] OR NSAID[tiab] OR antifibrinolytic[tiab] OR Goserelin[tiab] OR cetrorelix acetate[tiab] OR Selective estrogen receptor modulators[tiab] OR SERM[tiab] OR mirena[tiab] OR lng-ius[tiab] OR levonorgestrel-releasing intrauterine system[tiab] OR management[tiab] OR leuprolide[tiab] OR triptorelin[tiab] OR nafarelin[tiab]) NOT medline[sb]	92082
6	#4 OR #5	182541
7	therapy[sh:noexp] OR drug therapy[mh] OR drug therapy[sh] OR complementary therapies[mh] OR cam[sb] OR Treatment outcome[mh]	4576056
8	surgery[sh] OR surgical procedures, operative[mh] OR embolization, therapeutic[mh]	3058662
9	(Hysterectomy[tiab] OR myomectomy[tiab] OR hysteroscopy[tiab] OR emboliz*[tiab] OR ablation[tiab] OR magnetic resonance guided[tiab] OR focused ultrasound[tiab] OR artery occlusion[tiab] OR UAE[tiab] OR morcellat*[tiab] OR electrosurg*[tiab] OR cryoablation[tiab] OR myolysis[tiab]) NOT medline[sb]	16834
10	#8 OR #9	3075456
11	#6 OR #7 OR #10	6846698
12	#3 AND #11	10260

Notes: “Drug therapy”[mh] includes hormone therapy; “Surgical procedures, operative”[mh] includes ultrasound ablation, embolization, and hysterectomy; Search lines: #3=uterine fibroid concept; #6 drug treatment concept; #7=therapy or treatment general concept; #10=surgical and procedural interventions concept; #11=any intervention; #12=any intervention or treatment and fibroid

Table A-2. PubMed (4/26/16)

Search	Query	Records
1	((leiomyoma[mh]) OR (fibroma[mh] AND (uterine diseases[mh] OR uterus[mh])))	18618
2	(Uterine[tiab] AND (fibroma*[tiab] OR fibroid*[tiab] OR leiomyoma*[tiab] OR myoma*[tiab] OR fibromyoma*[tiab])) OR (submucous fibroid*[tiab] OR submucosal fibroid*[tiab] OR Intramural fibroids [tiab]) NOT medline[sb]	1206
3	#1 OR #2	19824
4	("Mifepristone"[Mesh] OR "ulipristal"[Supplementary Concept] OR "Anti-Inflammatory Agents, Non-Steroidal"[Mesh] OR "Antifibrinolytic Agents"[Mesh] OR "Goserelin"[Mesh] OR "cetrorelix"[Supplementary Concept] OR "Selective Estrogen Receptor Modulators"[Mesh] OR "Levonorgestrel"[Mesh] OR "Nafarelin"[Mesh] OR “Leuprolide"[Mesh])	95001
5	(Mifepristone[tiab] OR Ulipristal acetate[tiab] OR NSAID[tiab] OR antifibrinolytic[tiab] OR Goserelin[tiab] OR cetrorelix acetate[tiab] OR Selective estrogen receptor modulators[tiab] OR SERM[tiab] OR mirena[tiab] OR lng-ius[tiab] OR levonorgestrel-releasing intrauterine system[tiab] OR management[tiab] OR leuprolide[tiab] OR	109218

Search	Query	Records
	triptorelin[tiab] OR nafarelin[tiab]) NOT medline[sb]	
6	#4 OR #5	204219
7	therapy[sh:noexp] OR drug therapy[mh] OR drug therapy[sh] OR complementary therapies[mh] OR cam[sb] OR Treatment outcome[mh]	4840736
8	surgery[sh] OR surgical procedures, operative[mh] OR embolization, therapeutic[mh]	3228356
9	(Hysterectomy[tiab] OR myomectomy[tiab] OR hysteroscopy[tiab] OR emboliz*[tiab] OR ablation[tiab] OR magnetic resonance guided[tiab] OR focused ultrasound[tiab] OR artery occlusion[tiab] OR UAE[tiab] OR morcellat*[tiab] OR electrosurg*[tiab] OR cryoablation[tiab] OR myolysis[tiab]) NOT medline[sb]	19444
10	#7 OR #8 OR #9	7106684
11	#6 OR #10	7245249
12	#3 AND #11	10940
13	#12: Publication date from 2015/01/01	650

Notes: Imported 573 after 77 duplicates discarded by Endnote

Table A-3. Ovid® Embase (Excerpta Medica)

Date	Search strategy and limits	Retrieval
3/1/2015	*uterus myoma/dt, su [Drug Therapy, Surgery] (limited to English language; exclude medline journals; year="1985 -Current")	331*
4/26/2016	*uterus myoma/dt, su [Drug Therapy, Surgery] (limited to English language; exclude medline journals; year="2015 -Current")	56ǂ

Notes:*Retrieval: 331, imported 303 after duplicates were discarded; ǂ Retrieval: 56; imported 16 after 40 duplicates were discarded.

Key Question 3 Search Strategy

Table A-4. PubMed (2/2/2016)

Search	Query	Records
1	25016181 OR 24347933 OR 24012921 OR 23962573 OR 23189178 OR 23053310 OR 22905461 OR 22732808 OR 22626269 OR 22472335 OR 22142874 OR 22095838	12
2	Similar articles for PubMed (Select 12 documents) Filters: Publication date from 2014/03/01 to 2016/12/31	443

Notes: After duplicates removed, this literature strategy contributed 410 unique records.

Table A-5. PubMed (9/13/2016)

Search	Query	Results
#1	25016181 OR 24347933 OR 24012921 OR 23962573 OR 23189178 OR 23053310 OR 22905461 OR 22732808 OR 22626269 OR 22472335 OR 22142874 OR 22095838	12
#2	Similar articles for PubMed (Select 12 documents)	1844
#3	Filters: Publication date from 2014/03/01 to 2016/12/31	521

Notes: This literature search updated contributed 198 records, after 323 duplicates were removed.

Table A-6. Hand search

Search	Query	Results
#1	Records in Pritts Review	110
#2	Records identified in the UF CER literature library	14
#3	Records identified through other methods	9

Key Question 4 Search Strategy

Table A-7. PubMed (3/13/15)

Search	Query	Records
1	morcellation	445
2	morcellat* AND uterine	256
3	morcellat*	562
4	("Electrosurgery/adverse effects"[Mesh]) OR "Uterine Myomectomy/adverse effects"[MeSH] OR morcellat*	1251
5	("Electrosurgery/adverse effects"[Mesh] AND uterine) OR "Uterine Myomectomy/adverse effects"[MeSH] OR morcellat*	742

Notes: This literature search added 742 records.

Table A-8. PubMed (10/21/15)

Search	Query	Records
1	morcellation	520
2	morcellat* AND uterine	325
3	morcellat*	648
4	("Electrosurgery/adverse effects"[Mesh]) OR "Uterine Myomectomy/adverse effects"[MeSH] OR morcellat*	1374
5	("Electrosurgery/adverse effects"[Mesh] AND uterine) OR "Uterine Myomectomy/adverse effects"[MeSH] OR morcellat*	850

Notes: This literature search update added 102 records, after 748 duplicates were discarded.

Appendix B. Population, Intervention, Comparator, Outcomes, Timing, and Setting

Table B-1. Population, intervention, comparator, outcomes, timing, and setting

PICOTS	Criteria and Key Question(s)	
Population	Women who are being treated for uterine fibroids (KQs 1-4)	
Intervention(s)	Surgical (KQs 1-4) Procedural (KQs 1, 2) Medical / Pharmacologic (KQs 1, 2) Morcellation (KQs 1-4)	
Comparator	Inactive treatment including wait list control, expectant management, or placebo Active treatment	
Outcomes	<u>Intermediate outcomes (KQ 1)</u> Technical success Conversion to alternate operative procedure Estimated blood loss Wound healing status Length of stay Readmission/reoperation Return to usual activities <u>Final health outcomes (KQ 1)</u> Symptom status Desired fertility status Pregnancy outcomes Sexual function Fibroid characteristics Fibroid recurrence Subsequent treatment for fibroids Satisfaction with outcomes	<u>Adverse effects / Harms (KQs 1, 3)</u> Transfusion Unplanned hysterectomy Perforation of organs Cancer dissemination Misdirected embolization / non-target tissue embolization Ovarian failure Other serious adverse events
Timing	Any length of followup (KQs 1-4)	
Setting	Clinical setting in countries with health care systems similar to the U.S. (defined as inclusion as a Very High Human Development country on the United Nations Development Programme Human Development Index (KQs1-4) *Countries include: Albania, Algeria, Andorra, Antigua and Barbuda, Argentina, Armenia, Australia, Austria, Azerbaijan, Bahamas, Bahrain, Barbados, Belarus, Belgium, Belize, Bosnia and Herzegovina, Brazil, Brunei Darussalam, Bulgaria, Canada, Chile, China, Colombia, Costa Rica, Croatia, Cuba, Cyprus, Czech Republic, Denmark, Dominica, Dominican Republic, Ecuador, Estonia, Fiji, Finland, France, Georgia, Germany, Greece, Grenada, Hong Kong, China (SAR), Hungary, Iceland, Iran (Islamic Republic of), Ireland, Israel, Italy, Jamaica, Japan, Jordan, Kazakhstan, Korea (Republic of), Kuwait, Latvia, Lebanon, Libya, Liechtenstein, Lithuania, Luxembourg, Malaysia, Malta, Mauritius, Mexico, Montenegro, Netherlands, New Zealand, Norway, Oman, Palau, Panama, Peru, Poland, Portugal, Qatar, Romania, Russian Federation, Saint Kitts and Nevis, Saint Lucia, Saint Vincent and the Grenadines, Saudi Arabia, Serbia, Seychelles, Singapore, Slovakia, Slovenia, Spain, Sri Lanka, Suriname, Sweden, Switzerland, Thailand, The former Yugoslav Republic of Macedonia, Tonga, Trinidad and Tobago, Tunisia, Turkey, Ukraine, United Arab Emirates, United Kingdom, United States, Uruguay, Venezuela*	

Abbreviations: KQ=key question, PICOTS= Population, Intervention, Comparator, Outcomes, Timing, and Setting

Appendix C. Screening Forms

Key Question 1. Literature Screening Forms

Table C-1. Screening Form: Level 1

Question Text	Choice(s)	Code
1. Study evaluates a surgical or procedural or medical intervention(s) for women with uterine fibroids (If "NO," answer question 1a, submit this form, and move to next. If paper addresses morcellation harms, check Retain below before submitting.)	Yes	Yes
	No	X-1
	Cannot Determine	Unclear
1a. If no, the study evaluates (check all that apply)	Basic science	X-1a
	Genetics/etiology	X-1b
	Imaging/diagnosis	X-1c
	Pathophysiology/physiology	X-1d
	Pre-operative adjuncts to shrink fibroids or improve anemia	X-1e
	Risk factors	X-1f
	Case report	X-1g
	Other	X-1h
	Not uterine fibroid	X-1i
2. Paper reports original research (i.e., paper is not a review, editorial, commentary, letter to editor, etc.)	Yes	Yes
	No	X-2
	Cannot Determine	Unclear
3. Eligible study design: randomized controlled trial	Yes	Yes
	No	X-3
	Cannot Determine	Unclear
3a. If no, please select study design	Prospective or retrospective cohort study	X-3a
	Non-randomized trial	X-3b
	Case series	X-3c
	Case report	X-3d
	Case-control	X-3e
	Other	X-3f
Screener Comments:		
Retain for:	Background/Discussion	Bkg
	Review of references	Refs
	Harms/AE data	Harms
	Other	Oth

Table C-2. Screening Form: Level 2

Question Text	Choice(s)	Code
1. Paper reports original research (i.e., paper is not a review, editorial, commentary, letter to editor, etc.) NOTE: If the publication appears relevant to the topic, consider whether it should be retained for “review for references” (see check boxes below the form). These publications will be flagged for review, but not promoted for full text screening.	Yes	Yes
	No	X-2

Table C-2. Screening Form: Level 2, continued

Question Text	Choice(s)	Code
2. Study evaluates an intervention/treatment for uterine fibroids	Yes	Yes
	No	X-1
2a. If no, the study evaluates (check all that apply)	Basic science	X-1a
Reason	Genetics/etiology	X-1b
	Imaging/diagnosis	X-1c
	Pathophysiology/physiology	X-1d
	Pre-operative adjuncts to shrink fibroids or improve anemia	X-1e
	Risk factors	X-1f
	Case report	X-1g
	Other	X-1h
	Not uterine fibroid	X-1i
3. Eligible study design: randomized controlled trial	Yes	Yes
	No	X-3
3a. If no, please select study design	Prospective or retrospective cohort study	X-3a
	Non-randomized trial	X-3b
	Case series	X-3c
	Case report	X-3d
	Case-control	X-3e
	Other	X-3f
4. The study population is women with uterine fibroids or, for studies of mixed conditions, data is reported separately for women with uterine fibroids.	Yes	Yes
	No	X-5
5. Eligible setting: Any setting (clinic, hospital) in countries with health care systems similar to the U.S.	Yes	Yes
	No	X-4
6. Reports outcome(s) of interest	Yes	Yes
	No	X-6
Intermediate Outcomes	Technical success	IO01
	Conversion to alternate operative procedure	IO02
	Estimated blood loss	IO03
	Wound healing status	IO04
	Length of stay	IO05
	Readmission or reoperation	IO06
	Return to usual activities	IO07
Final Health Outcomes	Symptom status	FH01
	Desired fertility status	FH02
	Pregnancy outcome	FH03
	Sexual function	FH04
	Fibroid characteristic	FH05
	Fibroid recurrence	FH06
	Subsequent treatment for uterine fibroids	FH07
	Satisfaction with outcomes	FH08
Adverse effects / Harms	Transfusion	AE01
	Unplanned hysterectomy	AE02

Question Text	Choice(s)	Code
	Perforation of organs	AE03

Table C-2. Screening Form: Level 2, continued

Question Text	Choice(s)	Code
	Misdirected embolization	AE04
	Cancer dissemination	AE05
	Other	AE06
7. Addresses Key Question(s) If the aim of the study is to assess adhesion status, evaluate the preoperative or adjunctive medical treatment to minimize intraoperative blood loss or postoperative pain, or to report operative technique, time, or cost, check "no" and provide a brief explanation.	Yes	Yes
	No	X-7
Reason	Text	
Check one or more Key Question	(KQ1) What is the comparative effectiveness of treatments for uterine fibroids?	KQ1
	(KQ2) Does treatment effectiveness differ by patient or fibroid characteristics?	KQ2
	(KQ3) What is the risk of harm from morcellation of uterine fibroids at the time of myomectomy or hysterectomy?	KQ3
	(KQ4) Does risk of harm from morcellation differ by patient or fibroid characteristics?	KQ4
Check one or more intervention or treatment category	Hysterectomy	HYS
	Myomectomy	MYO
	Uterine artery embolization	UAE
	Ablative procedures (e.g., magnetic resonance-guided focused ultrasound [MRgFUS], cryoablation)	ABL
	Progestin-containing intrauterine devices	IUD
	Medication to resolve symptoms or reduce size of fibroids	MED
Type of comparator(s) in the study	Inactive control (e.g., expectant management, placebo)	IAC
	Other	OTH
	Alternate intervention/treatment	ALT
Comparator category	Hysterectomy	HYS
	Myomectomy	MYO
	Uterine artery embolization	UAE
	Ablative procedure (e.g., magnetic resonance-guided focused ultrasound [MRgFUS], cryoablation)	ABL
	Progestin-containing intrauterine devices	IUD
	Medication to resolve symptoms or reduce size of fibroids	MED
Retain	Background	Bkg
	Review of references	Refs
	Harms data	Harms
	Other	Oth

Question Text	Choice(s)	Code
Comments	Text	
Part of a family	Yes	Yes
	No	No

Table C-2. Screening Form: Level 2, continued

Question Text	Choice(s)	Code
	Unclear	Unclear
Related Ref ID(s):	Text	
Administrative	Unavailable	X-10
	Non-English	X-11
	Duplicate	X-12

Key Question 3. Literature Screening Forms

Table C-3. Screening Form: Level 1

Question Text	Choice(s)	Code
1. Reports original research (includes analysis of clinical or administrative data).	Yes	Yes
	No	X-1
	Unclear	UC
2. Population is women with uterine fibroids.	Yes	Yes
	No	X-2
3. Publication includes (or reports data from) 5 or more patients treated for uterine fibroids.	Yes	Yes
	No	X-4
	Unclear	UC
4. Publication reports the histopathological status of tumors from all women treated for uterine fibroids.	Yes	Yes
	No	X-3
	Unclear	UC
Number of women with uterine fibroids:	*text*	-
Number with confirmed leiomyosarcoma:	*text*	-
Leiomyosarcoma rate:	*text*	-
Retain for: Review of references	*checkbox*	REFS
Retain for: Team Review	*checkbox*	TEAM
Retain for: Other	*checkbox*	OTH

Table C-4. Screening Form: Level 2

Question Text	Choice(s)	Code
1. Reports original research (includes analysis of clinical or administrative data).	Yes	Yes
	No	X-1
2. Population is women with uterine fibroids.	Yes	Yes
	No	X-2

Question Text	Choice(s)	Code
3. Publication includes (or reports data from) 5 or more patients treated for uterine fibroids.	Yes	Yes
	No	X-4
4. Publication reports the histopathological status of tumors from all women treated for uterine fibroids.	Yes	Yes
	No	X-3

Table C-4. Screening Form: Level 2, continued

Question Text	Choice(s)	Code
Number of women with uterine fibroids:	*Text*	-
Number with confirmed leiomyosarcoma:	*Text*	-
Leiomyosarcoma rate:	*Text*	-
Retain for: Review of references	*Checkbox*	REFS
Retain for: Team Review	*Checkbox*	TEAM
Retain for: Other	*Checkbox*	OTH
Comments:	*Text*	-
Admin: Duplicate	*Checkbox*	X-11
Admin: Unavailable	*Checkbox*	X-12
Admin: Non-English	*Checkbox*	X-13
Admin: Published before 2014	*Checkbox*	X-14

Key Question 4. Literature Screening Forms

Table C-5. Screening Form: Level 1

Question Text	Choice(s)	Code
1. Reports original research (includes analysis of clinical or administrative data).	Yes	Yes
	No	X-1
	Unclear	Unclear
2. Population is women with uterine fibroids.	Yes	Yes
	No	X-2
3. Publication includes 5 or more patients (or data from patients) treated for uterine fibroids.	Yes	Yes
	No	X-3
	Unclear	Unclear
Number of patients included /number of clinical or administrative records analyzed:	*Text*	
4. The publication reports morcellator use.	Yes	Yes
	No	X-4
	Unclear	Unclear
5. The publication reports outcome(s) related to leiomyosarcoma subsequent to treatment for uterine fibroids. Check "yes" when the publication describes patients treated for uterine fibroids and follows those individuals forward in time. A publication that reports tumor pathology at time of treatment only (i.e., postoperative histopathologic information) should not be included unless it	Yes	Yes
	No	X-5
	Unclear	Unclear

Question Text	Choice(s)	Code
also reports subsequent outcomes such as residual disease, recurrence, survival, etc. Do not include papers that identify cases of leiomyosarcoma or uterine malignancy and look back to ascertain the time, type, and indication for initial treatment.		
Brief description of relevance of findings to KQ 4	*Text*	-
Brief description of reason for exclusion:	*Text*	-
Retain for: Background	*Checkbox*	BKG

Table C-5. Screening Form: Level 1, continued

Question Text	Choice(s)	Code
Retain for: Review of references	*Checkbox*	REFS
Retain for: Team Review	*Checkbox*	TEAM
Retain for: LMS prevalence	*Checkbox*	LMS
Retain for: Other	*Checkbox*	OTH

Table C-6. Screening Form: Level 2

Question Text	Choice(s)	Code
1. Paper reports original research (i.e., paper is not a review, editorial, commentary, letter to editor, etc.)	Yes	Yes
	No	X-1
2. Study reports use of morcellation or en bloc removal of the uterus or uterine fibroid.	Yes	Yes
	No	X-2
3. Eligible study design: case series, cohort, or trial Do not include studies that identify cases of leiomyosarcoma or uterine malignancy and look back at treatment/ exposure status	Yes	Yes
	No	X-3
3a. If no, please select study design / article type:		
Article type: Case report	*Checkbox*	X-3a
Article type: Literature review	*Checkbox*	X-3b
Article type: Surgical technique	*Checkbox*	X-3c
Article type: Retrospective cohort	*Checkbox*	X-3e
Article type: Other	*Checkbox*	X-3d
4. The paper includes 5 or more patients treated for uterine fibroids.	Yes	Yes
	No	X-4
5. The publication reports outcome(s) related to leiomyosarcoma subsequent to treatment for uterine fibroids. Check "yes" when the publication describes patients treated for uterine fibroids and follows those individuals forward in time. A publication that reports tumor pathology at time of treatment only (i.e., postoperative histopathologic information) should not be included unless it also reports subsequent outcomes such as residual disease, recurrence, survival, etc. Do not include papers that identify cases of leiomyosarcoma or uterine malignancy and look back to ascertain the time, type, and indication for initial treatment.	Yes	Yes
	No	X-5
Retain for: Background	*Checkbox*	BKG
Retain for: Review of references	*Checkbox*	REFS
Retain for: LMS prevalence (KQ3)	*Checkbox*	LMS

Question Text	Choice(s)	Code
Other	*Checkbox*	OTH
Comments	*Text*	
Related Ref ID(s):	*Text*	
Admin: Unavailable	*Checkbox*	X-10
Admin: Non-English	*Checkbox*	X-11
Admin: Duplicate	*Checkbox*	X-12

Appendix D. Reasons for Exclusion

Table D-1. Reasons for exclusion: Key Question 1 (n = 1,192*)

Exclusion Code	Exclusion Reason	Count
X-1	Does not include an intervention or treatment for uterine fibroids	555
	Basic science (X-1a)	
	Genetics/etiology (X-1b)	
	Imaging/diagnosis (X-1c)	
	Pathophysiology/physiology (X-1d)	
	Pre-operative adjuncts to shrink fibroids or improve anemia (X-1e)	
	Risk factors (X-1f)	
	Case report (X-1g)	
	Other (X-1h)	
	Not uterine fibroid (X-1i)	
X-2	Not original research	548
X-3	Not an eligible study design	493
	Prospective or retrospective cohort study (X-3a)	
	Non-randomized trial (X-3b)	
	Case series (X-3c)	
	Case report (X-3d)	
	Case-control (X-3e)	
	Other (X-3f)	
X-4	Not conducted in an eligible country	36
X-5	Population is not women with uterine fibroids or does not report data separately from mixed population	54
X-6	Does not report an outcome of interest	112
X-7	Does not address a Key Question	162
X-10	Unavailable	1
X-11	Non-English	107
X-12	Duplicate	6

*Total count exceeds number of records as records can be excluded for more than one reason

1. Abe J, Kimura J, Hirose T, et al. Endometriosis and various pelvic lesions associated with hyperprolactinemia. Asia Oceania J Obstet Gynaecol. 1985 Sep;11(3):393-7. PMID: 4084107. X-1, X-1h

2. Anteby SO, Yarkoni S, Ever Hadani P. The effect of a prostaglandin synthetase inhibitor, indomethacin, on excessive uterine bleeding. Clin Exp Obstet Gynecol. 1985;12(3-4):60-3. PMID: 4064305. X-3, X-3c

3. Darney PD. Sonographically guided extraction of a submucous myoma. Obstet Gynecol. 1985 Nov;66(5):731-2. PMID: 3903586. X-1, X-1g, X-3, X-3d

4. Driessen F. Myomectomy in treatment of uterine fibroids. Trop Doct. 1985 Apr;15(2):68. PMID: 4002330. X-2

5. Gilardenghi F. [Fibromas in pregnancy. Clinico-therapeutic considerations]. Minerva Ginecol. 1985 Oct;37(10):571-80. PMID: 3908982. X-2, X-11

6. Kanshin NN, Umarov AU, Maksimov Iu M. [A method of mechanical compression opening of hollow organs]. Khirurgiia (Mosk). 1985 Dec(12):105-7. PMID: 3910930. X-1, X-1h, X-1i, X-2

7. Kiriushchenkov AP. [Uterine myoma]. Feldsher Akush. 1985 Dec;50(12):5-11. PMID: 3853995. X-11

8. Krasnopol'skii VI. [Conservative myomectomy]. Akush Ginekol (Mosk). 1985 Mar(3):72-5. PMID: 3161378. X-11

9. Kuznetsova LV. [Computer-assisted prognosis of the reproductive function of patients following conservative myomectomy]. Akush Ginekol (Mosk). 1985 Mar(3):50-3. PMID: 3161369. X-11

10. Landekhovskii Iu D. [Principles of organization of dispensary observation of uterine myoma patients]. Akush Ginekol (Mosk). 1985 Nov(11):25-30. PMID: 2935027. X-1, X-2, X-11

11. Maheux R, Guilloteau C, Lemay A, et al. Luteinizing hormone-releasing hormone agonist and uterine leiomyoma: a pilot study. Am J Obstet Gynecol. 1985 Aug 15;152(8):1034-8. PMID: 3927734. X-3, X-3c, X-3f

12. McLaughlin DS. Metroplasty and myomectomy with the CO2 laser for maximizing the preservation of normal tissue and minimizing blood loss. J Reprod Med. 1985 Jan;30(1):1-9. PMID: 3919177. X-3, X-3a, X-3f

13. Piganova NL. [Uterine myoma and pregnancy]. Med Sestra. 1985 Sep;44(9):38-41. PMID: 3853069. X-7, X-11

14. Roopnarinesingh S, Suratsingh J, Roopnarinesingh A. The obstetric outcome of patients with previous myomectomy or hysterotomy. West Indian Med J. 1985 Mar;34(1):59-62. PMID: 4013245. X-1, X-1i, X-3, X-3c

15. Schlund GH. [Liability of the physician in a legal but failed abortion for social reasons]. Geburtshilfe Frauenheilkd. 1985 Sep;45(9):674-6. doi: 10.1055/s-2008-1036390. PMID: 4054551. X-1, X-1h, X-1i, X-2

16. Zhang YX. [A series of 440 vaginal hysterectomies performed for non-prolapsed uterus]. Zhonghua Fu Chan Ke Za Zhi. 1985 Sep;20(5):294-7, 319. PMID: 4085296. X-1, X-1i, X-3, X-3c

17. .Uterine fibroids: medical treatment or surgery? Lancet. 1986 Nov 22;2(8517):1197. PMID: 2877334. X-2

18. Andrys J, Stepan J. [Surgery of myomas during pregnancy and labor]. Cesk Gynekol. 1986 Jun;51(5):352-4. PMID: 3719754. X-7, X-11

19. Blandamura M, Oddi M, Cartocci R, et al. [A new antiestrogenic action inhibiting the conversion of testosterone to estrogens, discovered through the use of cyproterone acetate]. Minerva Ginecol. 1986 Sep;38(9):729-35. PMID: 2948139. X-1, X-11

20. Borovskaia VD. [Results of health resort treatment of women with chronic inflammation of the adnexae and uterine myoma]. Vopr Kurortol Fizioter Lech Fiz Kult. 1986 Jan-Feb(1):44-6. PMID: 3705493. X-1, X-1h, X-2, X-11

21. Boyd ME. Myomectomy. Can J Surg. 1986 May;29(3):161-3. PMID: 3518894. X-2

22. Buttram VC, Jr. Uterine leiomyomata--aetiology, symptomatology and management. Prog Clin Biol Res. 1986;225:275-96. PMID: 3538059. X-2

23. Chryssikopoulos A, Loghis C. Indications and results of total hysterectomy. Int Surg. 1986 Jul-Sep;71(3):188-94. PMID: 3771122. X-3, X-3f

24. Coddington CC, Collins RL, Shawker TH, et al. Long-acting gonadotropin hormone-releasing hormone analog used to treat uteri. Fertil Steril. 1986 May;45(5):624-9. PMID: 3084300. X-3, X-3c

25. Cornier E. [Ambulatory hysterofibroscopic treatment of persistent metrorrhagias using the Nd:YAG laser]. J Gynecol Obstet Biol Reprod (Paris). 1986;15(5):661-4. PMID: 3760478. X-1, X-2, X-3, X-3c

26. Coutinho EM, Boulanger GA, Goncalves MT. Regression of uterine leiomyomas after treatment with gestrinone, an antiestrogen, antiprogesterone. Am J Obstet Gynecol. 1986 Oct;155(4):761-7. PMID: 3532799. X-3, X-3f, X-7

27. Fakhr M, Abou-salem AM, El Sayed L, et al. Ovarian structure in cases of primary and secondary infertility. Med J Cairo Univ. 1986;54(3):423-8. PMID: 12295113. X-1, X-1d, X-1h, X-1i

28. Finikiotis G. Hysteroscopy in infertility. Clin Reprod Fertil. 1986 Aug;4(4):241-51. PMID: 3779580. X-2

29. Gonzalez Calzada GJ. [Isthmic-cervical myomatosis as a surgical problem]. Ginecol Obstet Mex. 1986 Jul;54:176-80. PMID: 3744092. X-11

30. Gorodeski IG, Geier A, Beery R, et al. Characterization of the nuclear progesterone receptor in human uterine leiomyoma. Eur J Obstet Gynecol Reprod Biol. 1986 Oct;23(1-2):91-9. PMID: 3023156. X-1, X-1a

31. Hagele D, Berg D. [Prevention of infection in hysterectomy by local preoperative antibiotics]. Geburtshilfe Frauenheilkd. 1986 Dec;46(12):906-7. doi: 10.1055/s-2008-1036343. PMID: 3817411. X-1, X-1h, X-1i

32. Hague WM, Abdulwahid NA, Jacobs HS, et al. Use of LHRH analogue to obtain reversible castration in a patient with benign metastasizing leiomyoma. Br J Obstet Gynaecol. 1986 May;93(5):455-60. PMID: 3085706. X-1, X-1g, X-3, X-3d

33. Healy DL, Lawson SR, Abbott M, et al. Toward removing uterine fibroids without surgery: subcutaneous infusion of a luteinizing hormone-releasing hormone agonist commencing in the luteal phase. J Clin Endocrinol Metab. 1986 Sep;63(3):619-25. doi: 10.1210/jcem-63-3-619. PMID: 3090092. X-1, X-1e, X-3, X-3c

34. Heidenreich W, Mlasowsky B. [Spontaneous splenic rupture as a cause of postoperative hemorrhage]. Geburtshilfe Frauenheilkd. 1986 Dec;46(12):910-1. doi: 10.1055/s-2008-1036345. PMID: 3817412. X-1, X-1i, X-3, X-3d

35. Hohl MK. [Function-preserving and function-restoring operations in gynecology]. Schweiz Rundsch Med Prax. 1986 Apr 22;75(17):472-8. PMID: 3520751. X-2, X-11

36. Hothorn W. [Invagination ileus as an acute disease picture--also in the adult]. Z Arztl Fortbild (Jena). 1986;80(19):815-8. PMID: 3811417. X-1, X-1h, X-1i, X-2

37. Ivanescu V. [Gynecological hemorrhage in elderly women]. Rev Fr Gynecol Obstet. 1986 Nov;81(11):639-42. PMID: 3797944. X-11

38. Jones M. The tumour. Cmaj. 1986 Oct 15;135(8):912. PMID: 3756722. X-2

39. Landekhovskii Iu D. [Hormonal therapy and uterine steroid receptors in myoma]. Akush Ginekol (Mosk). 1986 Feb(2):10-4. PMID: 2939738. X-1, X-1b, X-1d, X-11

40. Maheux R, Lemay A. Uterine leiomyoma: treatment with LHRH agonist. Prog Clin Biol Res. 1986;225:297-311. PMID: 3097669. X-2

41. Makarainen L, Ylikorkala O. Primary and myoma-associated menorrhagia: role of prostaglandins and effects of ibuprofen. Br J Obstet Gynaecol. 1986 Sep;93(9):974-8. PMID: 3533137. X-1, X-1h, X-3, X-3f, X-5, X-7

42. McLachlan RI, Healy DL, Burger HG. Clinical aspects of LHRH analogues in gynaecology: a review. Br J Obstet Gynaecol. 1986 May;93(5):431-54. PMID: 3085705. X-2

43. Mori T, Fujii S, Konishi I. [Pathogenesis and conservative therapy of uterine leiomyoma]. Nihon Sanka Fujinka Gakkai Zasshi. 1986 Jul;38(7):1144-9. PMID: 3091738. X-2, X-11

44. Okada M, Ohta T, Yasuoka S, et al. Surgical management of intracavitary cardiac tumors. A review of fifteen patients and current status in Japan. J Cardiovasc Surg (Torino). 1986 Nov-Dec;27(6):641-9. PMID: 3782267. X-1, X-1h, X-1i, X-3, X-3c

45. Rolland R, Franssen AM, Willemsen WN, et al. Uterine leiomyoma and LHRH agonist treatment. A preliminary report. Prog Clin Biol Res. 1986;225:313-20. PMID: 3097670. X-3, X-3f

46. Savchenko VF, Makatsariia AD, Mishchenko AL, et al. [Evaluation of the indicators of the hemostasis system during heparin use in the prevention of postoperative thrombotic complications in gynecologic patients]. Akush Ginekol (Mosk). 1986 Sep(9):34-6. PMID: 2947493. X-1, X-11

47. Shinagawa S, Ohishi T, Takano A. [An essay on elective hysterectomy and the treatment of uterine myoma]. Nihon Sanka Fujinka Gakkai Zasshi. 1986 Jul;38(7):1139-43. PMID: 3746033. X-2, X-11

48. Sidorova IS, Dzhavakhishvili GA. [Management of labor in patients with uterine myoma]. Akush Ginekol (Mosk). 1986 Feb(2):69-72. PMID: 2939761. X-1, X-1h, X-1i

49. Siegler AM. Therapeutic hysteroscopy. Acta Eur Fertil. 1986 Nov-Dec;17(6):467-71. PMID: 3630558. X-2

50. Sommer S, Engelmark C. [Polycythemia and uterine fibromyoma]. Ugeskr Laeger. 1986 Aug 11;148(33):2092-3. PMID: 3750545. X-11

51. Takahashi K. [Operation of functional maintenance in myoma uteri]. Nihon Sanka Fujinka Gakkai Zasshi. 1986 Jun;38(6):971-5. PMID: 3525705. X-11

52. van Leusden HA. Rapid reduction of uterine myomas after short-term treatment with microencapsulated D-Trp6-LHRH. Lancet. 1986 Nov 22;2(8517):1213. PMID: 2877341. X-2, X-3, X-3c

53. Weather L, Jr. Carbon dioxide laser myomectomy. J Natl Med Assoc. 1986 Oct;78(10):933-6. PMID: 3097332. X-3, X-3a, X-3c

54. Ylikorkala O, Pekonen F. Naproxen reduces idiopathic but not fibromyoma-induced menorrhagia. Obstet Gynecol. 1986 Jul;68(1):10-2. PMID: 3523328. X-1, X-1e, X-1h

55. Zurabiani ZR, Filatov VI, Kokhanskii IN. [Current methods of urologic examination of patients with uterine myoma]. Akush Ginekol (Mosk). 1986 Sep(9):8-11. PMID: 2947508. X-1, X-11

56. Andreyko JL, Marshall LA, Dumesic DA, et al. Therapeutic uses of gonadotropin-releasing hormone analogs. Obstet Gynecol Surv. 1987 Jan;42(1):1-21. PMID: 3543765. X-2

57. Blanda A, Catinella M. [Clinical considerations in an exceptional case of pregnancy with a voluminous fibromatous uterus]. Minerva Ginecol. 1987 Jul-Aug;39(7-8):519-23. PMID: 3670702. X-1, X-1g, X-3, X-3d

58. Chel'tsova NV. [Rehabilitative treatment of patients undergoing an operation for uterine myoma]. Med Sestra. 1987 Jun;46(6):59-61. PMID: 3669985. X-11

59. Cilley RE, Colletti LM, Dent TL, et al. Management of common gynecologic problems encountered during abdominal exploration. Am Surg. 1987 Nov;53(11):617-21. PMID: 3688657. X-2

60. Damewood MD, Rock JA. Reproductive uterine surgery. Obstet Gynecol Clin North Am. 1987 Dec;14(4):1049-68. PMID: 3328123. X-2

61. Doring GK, Larm S. [Conservative procedures in 64 pregnant patients with myoma: the course of pregnancy, labor, and the puerperium]. Geburtshilfe Frauenheilkd. 1987 Jan;47(1):26-9. doi: 10.1055/s-2008-1035767. PMID: 3552854. X-3, X-3c

62. Emembolu JO. Uterine fibromyomata: presentation and management in northern Nigeria. Int J Gynaecol Obstet. 1987 Oct;25(5):413-6. PMID: 2889637. X-3, X-3a, X-3c, X-4, X-5

63. Endzinas Zh A. [Giant uterine myoma in large unreduced postoperative ventral hernia]. Khirurgiia (Mosk). 1987 Apr(4):126-7. PMID: 3599718. X-1, X-1g, X-3, X-3d

64. Fedorchenko VM. [Simultaneous surgical treatment of varicose veins of the lower extremities and uterine fibromyoma]. Klin Khir. 1987(7):52-4. PMID: 3656966. X-1, X-1g, X-1h, X-1i, X-3, X-3d

65. Fraser HM, Baird DT. Clinical applications of LHRH analogues. Baillieres Clin Endocrinol Metab. 1987 Feb;1(1):43-70. PMID: 3109366. X-2

66. Fried FA, Hulka JF. Transuterine resection of fibroids: a new approach to the management of submucous fibroids in selected patients. J Urol. 1987 Nov;138(5):1256-7. PMID: 3669180. X-3, X-3c, X-3d

67. Friedman AJ, Barbieri RL, Benacerraf BR, et al. Treatment of leiomyomata with intranasal or subcutaneous leuprolide, a gonadotropin-releasing hormone agonist. Fertil Steril. 1987 Oct;48(4):560-4. PMID: 3115833. X-3, X-3f

68. Giamarellou H. Myonecrosis of the abdominal wall, complicating radical hysterectomy. Chemioterapia. 1987 Jun;6(2 Suppl):616-8. PMID: 2978389. X-1, X-3, X-3d

69. Goldrath MH. Vaginal removal of the pedunculated submucous myoma: the use of laminaria. Obstet Gynecol. 1987 Oct;70(4):670-2. PMID: 3627635. X-3, X-3c

70. Gwozdz AZ, Banaszczyk R. [Coexistence of pregnancy and uterine myomas and their effect on the puerperium after myomectomy during cesarean section]. Wiad Lek. 1987 Sep 1;40(17):1197-202. PMID: 3442015. X-11

71. Halila H, Suikkari AM, Seppala M. The effect of hysterectomy on serum CA 125 levels in patients with adenomyosis and uterine fibroids. Hum Reprod. 1987 Apr;2(3):265-6. PMID: 3474239. X-1, X-1h, X-3, X-3c, X-3e, X-3f, X-6, X-7

72. Hallez JP. [Transcervical intrauterine resection. A surgical technique that is safely controlled and non-traumatic]. J Gynecol Obstet Biol Reprod (Paris). 1987;16(6):781-5. PMID: 3452620. X-3, X-3c

73. Hallez JP, Netter A, Cartier R. Methodical intrauterine resection. Am J Obstet Gynecol. 1987 May;156(5):1080-4. PMID: 3578415. X-3, X-3c

74. Han ML, Wang YF, Tang MY, et al. Gossypol in the treatment of endometriosis and uterine myoma. Contrib Gynecol Obstet. 1987;16:268-70. PMID: 3121251. X-3, X-3c

75. Hardy JD. The ubiquitous fibroblast. Multiple oncogenic potentials with illustrative cases. Ann Surg. 1987 May;205(5):445-55. PMID: 3034175. X-1, X-1i, X-2, X-3, X-3d, X-5

76. Lemay A. Monthly implant of luteinizing hormone-releasing hormone agonist: a practical therapeutic approach for sex-steroid dependent gynecologic diseases. Fertil Steril. 1987 Jul;48(1):10-2. PMID: 2954859. X-2

77. Lin BL, Iwata Y, Miyamoto N, et al. Three-contrasts method: an ultrasound technique for monitoring transcervical operations. Am J Obstet Gynecol. 1987 Feb;156(2):469-72. PMID: 3548374. X-2, X-3, X-3a, X-3c, X-3f, X-7

78. Lumsden MA, West CP, Baird DT. Goserelin therapy before surgery for uterine fibroids. Lancet. 1987 Jan 3;1(8523):36-7. PMID: 2879106. X-1, X-1e, X-2, X-3, X-3a

79. Magurno G. [Complementary sacral colpopexy]. Minerva Ginecol. 1987 Jan-Feb;39(1-2):69-75. PMID: 3574750. X-1, X-1h, X-1i

80. Maheux R, Lemay A, Merat P. Use of intranasal luteinizing hormone-releasing hormone agonist in uterine leiomyomas. Fertil Steril. 1987 Feb;47(2):229-33. PMID: 3102282. X-3, X-3c, X-3f

81. Nardelli GB, Mega M, Bertasi M, et al. Estradiol and progesterone binding in uterine leiomyomata and pregnant myometrium. Clin Exp Obstet Gynecol. 1987;14(3-4):155-60. PMID: 3454723. X-1, X-1a, X-1d

82. Perl V, Marquez J, Schally AV, et al. Treatment of leiomyomata uteri with D-Trp6-luteinizing hormone-releasing hormone. Fertil Steril. 1987 Sep;48(3):383-9. PMID: 2957235. X-3, X-3c, X-3f

83. Reyniak JV, Corenthal L. Microsurgical laser technique for abdominal myomectomy. Microsurgery. 1987;8(2):92-8. PMID: 2957563. X-3, X-3c

84. Sasaki S. [Gynecological surgery: the importance of preoperative processes]. Josanpu Zasshi. 1987 Sep;41(9):730-7. PMID: 3682317. X-2, X-11

85. Shindo K, Oikawa N, Chida S, et al. [Pharmacokinetic and clinical studies on latamoxef in the field of obstetrics and gynecology]. Jpn J Antibiot. 1987 Jul;40(7):1243-52. PMID: 3682179. X-1, X-1h, X-1i, X-3, X-3c, X-3f

86. Tyszka JJ, Stypulkowski TA, Bieniawska M. [Leiomyoma diagnosed and treated as a ganglion]. Chir Narzadow Ruchu Ortop Pol. 1987;52(5):402-4. PMID: 3454312. X-1, X-1g, X-3, X-3d

87. Vikhliaeva EM. [Conservative treatment of patients with uterine myoma]. Akush Ginekol (Mosk). 1987 Nov(11):63-7. PMID: 3439575. X-11

88. Wang YF, Tang MY, Han ML, et al. [Ultrastructural changes in smooth muscle cells in leiomyoma and the myometrium of the human uterus after gossypol treatment]. Zhongguo Yi Xue Ke Xue Yuan Xue Bao. 1987 Aug;9(4):298-301. PMID: 2964936. X-1, X-1a, X-1d

89. Zhao HF. [Nailfold microcirculation in uterine myoma. Analysis of 61 cases]. Zhong Xi Yi Jie He Za Zhi. 1987 Feb;7(2):86-8, 69. PMID: 3621378. X-1, X-1h, X-3, X-3c

90. Andreyko JL, Blumenfeld Z, Marshall LA, et al. Use of an agonistic analog of gonadotropin-releasing hormone (nafarelin) to treat leiomyomas: assessment by magnetic resonance imaging. Am J Obstet Gynecol. 1988 Apr;158(4):903-10. PMID: 2966587. X-3, X-3a, X-3c

91. Baird DT, West CP. Medical management of fibroids. Br Med J (Clin Res Ed). 1988 Jun 18;296(6638):1684-5. PMID: 3135875. X-2

92. Bartfai G. Clinical applications of gonadotrophin-releasing hormone and its analogues. Hum Reprod. 1988 Jan;3(1):51-7. PMID: 3280595. X-2

93. Ben-Baruch G, Schiff E, Menashe Y, et al. Immediate and late outcome of vaginal myomectomy for prolapsed pedunculated submucous myoma. Obstet Gynecol. 1988 Dec;72(6):858-61. PMID: 3186093. X-2, X-3, X-3c

94. Bertrand de Nully M, Nielsen KD, Lykkesfeldt G. [Torsion of the non-pregnant uterus]. Ugeskr Laeger. 1988 Apr 18;150(16):983. PMID: 3376225. X-1, X-1h, X-1i

95. Chong RK, Thong PH, Tan SL, et al. Myomectomy: indications, results of surgery and relation to fertility. Singapore Med J. 1988 Feb;29(1):35-7. PMID: 3406762. X-3, X-3a, X-3f

96. Dadak C, Feiks A. [Organ-sparing surgery of leiomyomas of the uterus in young females]. Zentralbl Gynakol. 1988;110(2):102-6. PMID: 3364058. X-3, X-3c, X-3f

97. Ettinger B, Golditch IM, Friedman G. Gynecologic consequences of long-term, unopposed estrogen replacement therapy. Maturitas. 1988 Dec;10(4):271-82. PMID: 3226337. X-1, X-2, X-3, X-3f

98. Forti G. Clinical applications of GnRH analogs. J Endocrinol Invest. 1988 Nov;11(10):745-54. PMID: 3068292. X-2

99. Fujimaki M, Karaki Y, Sakamoto T, et al. [Leiomyoma of the esophagus]. Rinsho Kyobu Geka. 1988 Aug;8(4):345-51. PMID: 9301851. X-1, X-1g, X-1i, X-2, X-3

100. Garcia Muret MP, Pujol RM, Alomar A, et al. Familial leiomyomatosis cutis et uteri (Reed's syndrome). Arch Dermatol Res. 1988;280 Suppl:S29-32. PMID: 3408259. X-1, X-1f, X-1i, X-3, X-3f

101. Gavrilova AS, Kuznetsova VA, Tkachenko LV. [A combined treatment method for female infertility of mixed origin]. Akush Ginekol (Mosk). 1988 Aug(8):68-9. PMID: 3195714. X-1, X-1h, X-11

102. Gladun EV, Diug VM, Korchmaru VI, et al. [Characteristics of the hormonal ratios following the surgical treatment of patients with uterine myoma]. Akush Ginekol (Mosk). 1988 May(5):17-9. PMID: 3177768. X-11

103. Grillo M, Riedel HH, Lehmann-Willenbrock E, et al. Use of highly evacuated Redon drains after gynecologic laparotomies. Gynecol Obstet Invest. 1988;25(2):123-9. PMID: 3371760. X-1, X-1h

104. Grudzinska-Staniewska D, Blaszczyk M. [Treatment of multiple leiomyomata with nifedipine]. Przegl Dermatol. 1988 May-Jun;75(3):186-9. PMID: 3238013. X-11

105. Hallez JP, Perino A. Endoscopic intrauterine resection: principles and technique. Acta Eur Fertil. 1988 Jan-Feb;19(1):17-21. PMID: 3414327. X-1, X-1d, X-1h, X-2

106. Haouet S, Dellagi K, Kchir N, et al. [Lipoma of the uterus: apropos of a case of leiomyolipoma]. Tunis Med. 1988 Oct;66(10):701-3. PMID: 3222819. X-1, X-1g, X-3, X-3d

107. Hopp H, Hopp A, Knispel J. [Mortality and morbidity of thromboembolism in drug prevention--5-year analysis]. Zentralbl Gynakol. 1988;110(9):562-9. PMID: 3407358. X-1, X-1i

108. Horyn G. [Uterine fibroleiomyomas and mucosal polyps]. Soins Gynecol Obstet Pueric Pediatr. 1988 Oct(89):22-30. PMID: 3249994. X-11

109. Kessel B, Liu J, Mortola J, et al. Treatment of uterine fibroids with agonist analogs of gonadotropin-releasing hormone. Fertil Steril. 1988 Mar;49(3):538-41. PMID: 3277869. X-3, X-3a, X-3c

110. Killackey MA, Neuwirth RS. Evaluation and management of the pelvic mass: a review of 540 cases. Obstet Gynecol. 1988 Mar;71(3 Pt 1):319-22. PMID: 3347414. X-1, X-1h, X-3, X-3a, X-3c

111. Kiriushchenkov AP. [Postcastration syndrome]. Feldsher Akush. 1988 Aug;53(8):56-60. PMID: 3181478. X-1, X-1i

112. Kirsanova MI. [Characteristics of blood rheological and coagulation properties in patients with uterine myoma]. Akush Ginekol (Mosk). 1988 May(5):14-7. PMID: 3177767. X-11

113. Kondo K, Mizuno T, Niwa H, et al. [A case of benign metastasizing leiomyoma with pulmonary metastases]. Nihon Kyobu Geka Gakkai Zasshi. 1988 Sep;36(9):2131-5. PMID: 3204304. X-1, X-1g, X-3

114. Kuznetsova MN, Martysh NS, Saidova RA. [Diagnosis and echographic control of the treatment of uterine myoma in girls and young women]. Akush Ginekol (Mosk). 1988 Mar(3):27-30. PMID: 3041866. X-11

115. Lumsden MA, West CP, Bramley T, et al. The binding of epidermal growth factor to the human uterus and leiomyomata in women rendered hypo-oestrogenic by continuous administration of an LHRH agonist. Br J Obstet Gynaecol. 1988 Dec;95(12):1299-304. PMID: 2975953. X-1, X-1a, X-3, X-3b

116. Maheux R, Lemay A, Turcot-Lemay L. Dose-related inhibition of acute luteinizing hormone response during luteinizing hormone-releasing hormone agonist treatment for uterine leiomyoma. Am J Obstet Gynecol. 1988 Feb;158(2):361-4. PMID: 3124621. X-3, X-3b, X-3e, X-3f

117. Matta WH, Stabile I, Shaw RW, et al. Doppler assessment of uterine blood flow changes in patients with fibroids receiving the gonadotropin-releasing hormone agonist Buserelin. Fertil Steril. 1988 Jun;49(6):1083-5. PMID: 2967195. X-1, X-1a, X-3, X-3c

118. Megafu U. Surgical causes and management of female infertility in Nigeria. Int Surg. 1988 Jul-Sep;73(3):144-7. PMID: 3229919. X-1, X-1h, X-3, X-3c, X-4

119. Munk B, Rasmussen KL. [Acute urinary retention caused by incarcerated fibromyoma in the 8th week of pregnancy]. Ugeskr Laeger. 1988 Aug 8;150(32):1937-8. PMID: 3046087. X-1, X-1g, X-3, X-3d

120. Norris HJ, Hilliard GD, Irey NS. Hemorrhagic cellular leiomyomas ("apoplectic leiomyoma") of the uterus associated with pregnancy and oral contraceptives. Int J Gynecol Pathol. 1988;7(3):212-24. PMID: 3182168. X-1, X-1d, X-1f, X-3, X-3f

121. Ohara A, Ozawa M. [Physiopathology, diagnosis and treatment of uterine myoma]. Kurinikaru Sutadi. 1988 Jul;9(8):749-53. PMID: 3199851. X-1, X-1c, X-1h, X-2

122. Palatynski A, Mikaszewska-Pietraszun J, Zdziennicki A, et al. [Necrosis of a myoma in the 20th week of pregnancy]. Wiad Lek. 1988 May 15;41(10):674-7. PMID: 3239003. X-1, X-1g, X-3, X-3d

123. Palladi GA, Brezhneva NV. [Liver function indices during the treatment of patients with uterine myoma using synthetic progestins]. Akush Ginekol (Mosk). 1988 Mar(3):60-3. PMID: 3400831. X-1, X-1h, X-3, X-3f, X-11

124. Raju GC, Naraynsingh V, Woo J, et al. Adenomyosis uteri: a study of 416 cases. Aust N Z J Obstet Gynaecol. 1988 Feb;28(1):72-3. PMID: 3214387. X-1, X-3, X-3a

125. Ramsewak S, Perkins S, Roopnarinesingh S. Indications and risks of abdominal hysterectomy. West Indian Med J. 1988 Dec;37(4):215-7. PMID: 3232361. X-1, X-1h, X-3, X-3c, X-5

126. Semm K, Mettler L. Local infiltration of ornithine 8-vasopressin (POR 8) as a vasoconstrictive agent in surgical pelviscopy (applied to myoma enucleation, salpingotomy in cases of tubal pregnancy and peripheral salpingostomy). Endoscopy. 1988 Nov;20(6):298-304. doi: 10.1055/s-2007-1018201. PMID: 3229389. X-3, X-3c

127. Shaw RW. GnRH agonists-antagonists--clinical applications. Eur J Obstet Gynecol Reprod Biol. 1988 Jun;28(2):109-16. PMID: 2969835. X-2

128. Shmakov GS, Ivanov IP, Zheleznov BI, et al. [Is conservative myomectomy justified in cesarean section?]. Akush Ginekol (Mosk). 1988 Apr(4):41-7. PMID: 3421440. X-2, X-11

129. Starks GC. CO2 laser myomectomy in an infertile population. J Reprod Med. 1988 Feb;33(2):184-6. PMID: 3351816. X-3, X-3a, X-3f

130. van Leusden HA. Triptorelin to prevent hysterectomy in patients with leiomyomas. Lancet. 1988 Aug 27;2(8609):508. PMID: 2900426. X-2, X-3, X-3c

131. van Leusden HA, Dogterom AA. Rapid reduction of uterine leiomyomas with monthly injections of D-Trp6-GnRH. Gynecol Endocrinol. 1988 Mar;2(1):45-51. PMID: 2972173. X-3, X-3a, X-3c

132. Vdovina GF, Skipetrov VP. [Blood coagulation changes in gynecologic patients during surgery]. Akush Ginekol (Mosk). 1988 May(5):27-30. PMID: 3177770. X-1, X-1h, X-1i

133. Wang YF. [Observation on blood biochemical indices after gossypol treatment in gynecological cases]. Zhongguo Yi Xue Ke Xue Yuan Xue Bao. 1988 Jun;10(3):215-8. PMID: 2972411. X-1, X-1a, X-1d, X-1i, X-2

134. Weiner R, Haupt R, Klemm C. [Ileus caused by ileocecal invagination of a leiomyofibroma]. Zentralbl Chir. 1988;113(23):1540-3. PMID: 3239292. X-1, X-1g, X-1i, X-3, X-3d

135. West CP. LHRH analogues in the management of uterine fibroids, premenstrual syndrome and breast malignancies. Baillieres Clin Obstet Gynaecol. 1988 Sep;2(3):689-709. PMID: 3069270. X-2

136. Ye XQ. [Clinical and experimental study of gossypol in the treatment of dysfunctional menorrhagia, endometriosis and fibromyoma of the uterus]. Zhong Xi Yi Jie He Za Zhi. 1988 Apr;8(4):216-7, 197. PMID: 3191544. X-11

137. Zimmermann R. Dysfunctional uterine bleeding. Obstet Gynecol Clin North Am. 1988 Mar;15(1):107-10. PMID: 3173960. X-2

138. Baird DT, Bramley TA, Hawkins TA, et al. Effect of treatment with LHRH analogue Zoladex on binding of oestradiol, progesterone and epidermal growth factor to uterine fibromyomata. Horm Res. 1989;32 Suppl 1:154-6. PMID: 2533146. X-3, X-3b, X-3c

139. Bianchi S, Fedele L. The GnRH agonists in the treatment of uterine leiomyomas. Acta Eur Fertil. 1989 Jan-Feb;20(1):5-10. PMID: 2675524. X-2

140. Boudouris O, Ferrand S, Guillet JL, et al. [Paradoxical effects of tamoxifen on the woman's uterus. Apropos of 7 cases of myoma that appeared while under anti-estrogen treatment]. J Gynecol Obstet Biol Reprod (Paris). 1989;18(3):372-8. PMID: 2738326. X-3, X-3c, X-3d

141. Brooks PG, Loffer FD, Serden SP. Resectoscopic removal of symptomatic intrauterine lesions. J Reprod Med. 1989 Jul;34(7):435-7. PMID: 2769651. X-3,X-3c

142. Burgudzhieva T. [The laser therapy of wound complications with partial dehiscence following gynecologic operations. Clinical studies]. Akush Ginekol (Sofiia). 1989;28(6):55-60. PMID: 2633645. X-1, X-1i, X-3, X-3c

143. Coutinho EM, Goncalves MT. Long-term treatment of leiomyomas with gestrinone. Fertil Steril. 1989 Jun;51(6):939-46. PMID: 2656310. X-1h (drug not approved for use in US)

144. Cowan BD, Knobloch RP, Meeks GR, et al. Transcervical resection of submucous uterine fibroids: an alternative approach to management. J Miss State Med Assoc. 1989 Jan;30(1):1-3. PMID: 2926801. X-3, X-3c

145. Ellenbogen A, Shulman A, Libal Y, et al. Complication of triptorelin treatment for uterine myomas. Lancet. 1989 Jul 15;2(8655):167-8. PMID: 2567943. X-1, X-1g, X-3, X-3d

146. Friedman AJ. Clinical experience in the treatment of fibroids with leuprolide and other GnRH agonists. Obstet Gynecol Surv. 1989 May;44(5):311-3. PMID: 2498793. X-2

147. Friedman AJ, Rein MS, Harrison-Atlas D, et al. A randomized, placebo-controlled, double-blind study evaluating leuprolide acetate depot treatment before myomectomy. Fertil Steril. 1989 Nov;52(5):728-33. PMID: 2509250. X-6, X-7

148. Gatti D, Falsetti L, Viani A, et al. Uterine fibromyoma and sterility: role of myomectomy. Acta Eur Fertil. 1989 Jan-Feb;20(1):11-3. PMID: 2781982. X-3, X-3c

149. Gelmini G, Bacchi Modena A, Bresciani D, et al. Effects of ovariectomy on blood and plasma viscosity, fibrinogen and whole blood filterability. Maturitas. 1989 Sep;11(3):199-207. PMID: 2593863. X-1, X-1h, X-3, X-3f

150. Gitsch G, Berger E, Tatra G. [30 years of vaginal hysterectomy at the 2d University Gynecologic Clinic in Vienna, an analysis of over 6,000 operations]. Gynakol Rundsch. 1989;29 Suppl 2:45-7. PMID: 2613074. X-1, X-1f, X-1h, X-2, X-3, X-3c

151. Golan A, Bukovsky I, Schneider D, et al. D-Trp-6-luteinizing hormone-releasing hormone microcapsules in the treatment of uterine leiomyomas. Fertil Steril. 1989 Sep;52(3):406-11. PMID: 2528476. X-3, X-3c, X-3f

152. Green WJ, Fendley SM, Wintzell EC, et al. Cystic degeneration of a large uterine leiomyoma. Radiologic and surgical analyses. Invest Radiol. 1989 Aug;24(8):626-9. PMID: 2674052. X-1, X-1g, X-3, X-3d

153. Grundling H, Golob E, Schausberger L. [2,121 vaginal hysterectomies 1979-1988]. Gynakol Rundsch. 1989;29 Suppl 2:47-52. PMID: 2613078. X-1, X-1b, X-1f, X-1h, X-3, X-3c

154. Katz VL, Dotters DJ, Droegemeuller W. Complications of uterine leiomyomas in pregnancy. Obstet Gynecol. 1989 Apr;73(4):593-6. PMID: 2927854. X-1, X-1c, X-1h, X-2

155. Kiriushchenkov AP. [Conservative therapy of uterine myoma]. Feldsher Akush. 1989 Aug;54(8):59-61. PMID: 2583308. X-11

156. Landekhovskii Iu D, Strizhakov AN. [Conservative myomectomy in the complex treatment of patients with uterine myoma]. Akush Ginekol (Mosk). 1989 Oct(10):70-5. PMID: 2694848. X-11

157. Lumsden MA, West CP, Hawkins RA, et al. The binding of steroids to myometrium and leiomyomata (fibroids) in women treated with the gonadotrophin-releasing hormone agonist Zoladex (ICI 118630). J Endocrinol. 1989 May;121(2):389-96. PMID: 2526844. X-1, X-1a, X-1d, X-3, X-3a, X-3c

158. Magos AL, Baumann R, Turnbull AC. Managing gynaecological emergencies with laparoscopy. Bmj. 1989 Aug 5;299(6695):371-4. PMID: 2529009. X-1, X-1h, X-3, X-3c, X-3f

159. Maheux R. Treatment of uterine leiomyomata: past, present and future. Horm Res. 1989;32 Suppl 1:125-33. PMID: 2693323. X-2

160. Marugo M, Centonze M, Bernasconi D, et al. Estrogen and progesterone receptors in uterine leiomyomas. Acta Obstet Gynecol Scand. 1989;68(8):731-5. PMID: 2631544. X-1, X-1a

161. Marut EL. Etiology and pathophysiology of fibroid tumor disease: diagnosis and current medical and surgical treatment alternatives. Obstet Gynecol Surv. 1989 May;44(5):308-10. PMID: 2498792. X-2

162. Mettler L, Semm K. [Vaginal and abdominal hysterectomy at the Kiel University Gynecologic Clinic]. Arch Gynecol Obstet. 1989;245(1-4):379-82. PMID: 2802727. X-11

163. Monroe SE, Andreyko J. Treatment of uterine leiomyomas and hirsutism with nafarelin. J Reprod Med. 1989 Dec;34(12 Suppl):1029-33. PMID: 2533618. X-3, X-3c, X-3f

164. Nakagiri Y, Okuda H, Niida K, et al. [Pharmacokinetic and clinical studies on cefodizime in the field of obstetrics and gynecology]. Jpn J Antibiot. 1989 Oct;42(10):2128-34. PMID: 2607603. X-1, X-1i, X-3, X-3c

165. Rong GH. [Gynecologic surgery with simultaneous lipectomy of the abdominal wall]. Zhonghua Zheng Xing Shao Shang Wai Ke Za Zhi. 1989 Jun;5(2):115-6. PMID: 2529958. X-1, X-1g, X-3, X-3d, X-11

166. Schwarz R, Gerber B. [Experiences with vaginal hysterectomy]. Gynakol Rundsch. 1989;29 Suppl 2:43-5. PMID: 2613069. X-2, X-11

167. Shaw RW. Mechanism of LHRH analogue action in uterine fibroids. Horm Res. 1989;32 Suppl 1:150-3. PMID: 2533145. X-2

168. Smejkal V, Bauer J, Zavadil M. [Removal of a myoma using laser rays]. Cesk Gynekol. 1989 Jun;54(5):353-5. PMID: 2791003. X-11

169. Sudik R, Abbate Y, Andemariam S. [Problems in treatment of sterility in developing countries--experiences with sterility consultation in Gondar/Ethiopia]. Zentralbl Gynakol. 1989;111(23):1555-61. PMID: 2533771. X-1, X-1b, X-1c, X-1d, X-3, X-3c, X-3f, X-4

170. Uemura T, Kimura A, Shirasu K, et al. [Shrinkage of uterine leiomyomas after intranasal administration of a LHRH agonist]. Nihon Sanka Fujinka Gakkai Zasshi. 1989 Mar;41(3):365-8. PMID: 2499643. X-11

171. Uvarova EB. [Systemic approach to the diagnosis of combined benign hyperplastic uterine diseases in patients of reproductive age]. Akush Ginekol (Mosk). 1989 Oct(10):65-70. PMID: 2694847. X-1, X-1c, X-11

172. Uvarova EV. [Clinico-pathogenetic substantiation of medical tactics in combined benign hyperplastic processes in the uterus of patients of reproductive age]. Akush Ginekol (Mosk). 1989 Jul(7):19-24. PMID: 2802061. X-1, X-1b, X-1c, X-1d

173. West CP, Lumsden MA. Fibroids and menorrhagia. Baillieres Clin Obstet Gynaecol. 1989 Jun;3(2):357-74. PMID: 2692925. X-2

174. West CP, Lumsden MA, Baird DT. LHRH analogues and fibroids--potential for longer-term use. Horm Res. 1989;32 Suppl 1:146-9. PMID: 2693325. X-2

175. Abubakirova AM, Shmakov GS, Dizna SN, et al. [Choices in postoperative management of women after cesarean section and myomectomy]. Akush Ginekol (Mosk). 1990 Mar(3):44-8. PMID: 2115751. X-1, X-1h, X-3, X-3c, X-3f

176. Adamian LV, Kulakov VI, Kiselev SI, et al. [Experience with the use of the CO2 laser in reconstructive and plastic gynecologic surgery in patients with uterine myoma and endometriosis]. Akush Ginekol (Mosk). 1990 Feb(2):24-7. PMID: 2111100. X-1, X-1h, X-3, X-3c, X-11

177. Barbieri RL. Gonadotropin-releasing hormone agonists and estrogen-progestogen replacement therapy. Am J Obstet Gynecol. 1990 Feb;162(2):593-5. PMID: 2137979. X-2

178. Brun G. [Uterine fibroma. Diagnosis, development and prognosis, principles of treatment]. Rev Prat. 1990 May 1;40(13):1229-33. PMID: 2343258. X-1, X-1c, X-2, X-11

179. Campana L. [What is your roentgen diagnosis? Leiomyoma of the esophagus]. Schweiz Rundsch Med Prax. 1990 May 29;79(22):681-2. PMID: 2349427. X-1, X-1h, X-1i

180. Cass I, Heller DS, Goldstein M, et al. Pelvic mass as the initial symptom of ovarian leiomyoma. Mt Sinai J Med. 1990 Mar;57(2):122-4. PMID: 2195320. X-1, X-1g, X-1i, X-3, X-3d

181. Chikala ET, Chernetskii VB, Rozhnovianu GA. [Leiomyoma and leiomyosarcoma of the jejunum complicated by hemorrhage]. Klin Khir. 1990(2):55. PMID: 2342281. X-1, X-1g, X-1h, X-1i

182. Diemer HP, Kozlowski P. [Pregnancy and myomas--when operate?]. Gynakologe. 1990 Apr;23(2):71-4. PMID: 2194912. X-1, X-1i, X-2

183. Dorr A. [Proliferative metastasizing leiomyoma of the uterus]. Cesk Gynekol. 1990 May;55(4):278-80. PMID: 2372836. X-1, X-1h, X-11

184. Edelman MA, Keller RJ, Gendal ES, et al. Bleeding duodenal leiomyoma. Mt Sinai J Med. 1990 Jan;57(1):37-9. PMID: 2320021. X-1, X-1g, X-1i, X-3, X-3d, X-5

185. Erny R, Milliet E. [Treatment of uterine fibroma using LH-RH analogs and gestrinone. Limits and indications]. Rev Fr Gynecol Obstet. 1990 Feb;85(2):73-7. PMID: 2108483. X-2, X-11

186. Fedele L, Vercellini P, Bianchi S, et al. Treatment with GnRH agonists before myomectomy and the risk of short-term myoma recurrence. Br J Obstet Gynaecol. 1990 May;97(5):393-6. PMID: 2115379. X-1, X-1e, X-6, X-7

187. Fribourg S. Leuprolide depot before myomectomy. Fertil Steril. 1990 Apr;53(4):754. PMID: 2108064. X-2

188. Friedman AJ, Rein MS, Pandian MR, et al. Fasting serum growth hormone and insulin-like growth factor-I and -II concentrations in women with leiomyomata uteri treated with leuprolide acetate or placebo. Fertil Steril. 1990 Feb;53(2):250-3. PMID: 2105242. X-1, X-1e

189. Garay J, Garaj J, Durcansky D. [Giant subserous pendulous liquefied uterine myoma]. Cesk Gynekol. 1990 Sep;55(8):607-10. PMID: 2225124. X-1, X-1g, X-3, X-3d

190. Gleich P. Transcervical resection of uterine myomas with a resectoscope. Urol Clin North Am. 1990 Feb;17(1):59-62. PMID: 2305522. X-2, X-3, X-3c

191. Gonzalez Cajigal R, Rey Ibarra A, Banet Diaz R. [Leiomyoma of the esophagus. 2 cases removed through the hiatus]. Rev Esp Enferm Dig. 1990 Apr;77(4):309-10. PMID: 2390349. X-1, X-1g, X-1h

192. Hackenberg R, Gesenhues T, Deichert U, et al. [Preoperative reduction of uterine leiomyoma by the GnRH-analog goserelin (zoladex)]. Geburtshilfe Frauenheilkd. 1990 Feb;50(2):136-9. doi: 10.1055/s-2007-1026451. PMID: 2138580. X-1, X-1e, X-11

193. Jameson CF. Angiomyoma of the uterus in a patient with tuberous sclerosis. Histopathology. 1990 Feb;16(2):202-3. PMID: 2323745. X-1, X-1g, X-1i, X-3, X-3d

194. Kably Ambe A, Anaya Coeto H, Garza Rios P, et al. [Abdominal myomectomy and subsequent fertility]. Ginecol Obstet Mex. 1990 Sep;58:274-6. PMID: 2276654. X-1, X-1f, X-1h, X-3, X-3c

195. Kirsanova MI, Karapetian SG. [Correction of rheologic disorders of the blood in patients with uterine myoma in the postoperative period]. Akush Ginekol (Mosk). 1990 Feb(2):27-30. PMID: 2339758. X-1, X-1h, X-11

196. Kitagawa S, Ueyama T, Shimoda Y, et al. [Radiographic diagnosis of benign colonic tumors excluding adenoma]. Rinsho Hoshasen. 1990 Sep;35(10):1251-60. PMID: 2262994. X-1, X-1c, X-1h, X-1i

197. Kononenko NG, Korobko VB, Skoroda LV. [Leiomyoma of the small intestine simulating non-organ tumor of the lesser pelvis]. Klin Khir. 1990(2):46. PMID: 2342268. X-1, X-1g, X-1h, X-1i

198. Korotkevich AG, Menshikov VF. [Endoscopic removal of esophageal leiomyoma]. Khirurgiia (Mosk). 1990 Nov(11):146. PMID: 2292844. X-1, X-1h, X-1i, X-3, X-3d

199. Loong EP, Wong FW. Uterine leiomyosarcoma diagnosed during treatment with agonist of luteinizing hormone-releasing hormone for presumed uterine fibroid. Fertil Steril. 1990 Sep;54(3):530-1. PMID: 2118862. X-1, X-1g, X-3, X-3d

200. Maheux R. [Use of LH-RH agonists in uterine leiomyoma]. J Gynecol Obstet Biol Reprod (Paris). 1990;19(5):603-6. PMID: 2212519. X-11

201. Nichitailo ME, Skums AV. [Successful removal of giant malignant leiomyoma of the stomach in a patient with artificial pacemaker]. Vestn Khir Im I I Grek. 1990 Oct;145(10):44-5. PMID: 1964287. X-1, x-1g, X-1h, X-1i

202. Rein MS, Friedman AJ, Heffner LJ. Decreased prolactin secretion by explant cultures of fibroids from women treated with a gonadotropin-releasing hormone agonist. J Clin Endocrinol Metab. 1990 Jun;70(6):1554-8. doi: 10.1210/jcem-70-6-1554. PMID: 2112150. X-1, X-1a, X-1d, X-3, X-3f

203. Rein MS, Friedman AJ, Pandian MR, et al. The secretion of insulin-like growth factors I and II by explant cultures of fibroids and myometrium from women treated with a gonadotropin-releasing hormone agonist. Obstet Gynecol. 1990 Sep;76(3 Pt 1):388-94. PMID: 2116610. X-1, X-1a, X-1d, X-1e

204. Rein MS, Friedman AJ, Stuart JM, et al. Fibroid and myometrial steroid receptors in women treated with gonadotropin-releasing hormone agonist leuprolide acetate. Fertil Steril. 1990 Jun;53(6):1018-23. PMID: 2112489. X-1, X-1a, X-1d, X-3, X-3f

205. Sugai K, Sugai Y, Aoki H, et al. [Anesthesia for a patient with spinocerebellar degeneration who developed atrioventricular block]. Masui. 1990 Oct;39(10):1397-401. PMID: 2255048. X-1, X-1h, X-1i, X-3, X-3d

206. Tokumoto K, Tokushige M, Saeki K, et al. [A case of leiomyoblastoma of the duodenum]. Nihon Shokakibyo Gakkai Zasshi. 1990 Mar;87(3):852-6. PMID: 2201805. X-1, X-1g, X-1h, X-1i

207. Vasil'chenko NP, Firichenko VI. [Treatment of patients with uterine myoma and its effectiveness]. Akush Ginekol (Mosk). 1990 Feb(2):7-10. PMID: 2140246. X-11

208. Vasil'chenko NP, Turkin VN, Volkov VV. [Comparative evaluation of various methods of treatment of threatened abortion in patients with uterine myoma]. Akush Ginekol (Mosk). 1990 Jun(6):47-50. PMID: 2221266. X-1, X-1h, X-1i

209. Vaughn TR, Louton RB, Terranova WT. A large leiomyoma of the digit. Plast Reconstr Surg. 1990 Sep;86(3):605-6. PMID: 2385685. X-1, X-1g, X-1i, X-3, X-3d, X-5

210. Vikhliaeva EM, Adamian LV, Uvarova EV, et al. [Alternative solutions in the treatment of patients with combined benign endometrial and myometrial pathology]. Akush Ginekol (Mosk). 1990 Aug(8):45-8. PMID: 2260751. X-1, X-1h, X-3, X-3f, X-11

211. Vollenhoven BJ, Lawrence AS, Healy DL. Uterine fibroids: a clinical review. Br J Obstet Gynaecol. 1990 Apr;97(4):285-98. PMID: 2187522. X-2

212. Vollenhoven BJ, Shekleton P, McDonald J, et al. Clinical predictors for buserelin acetate treatment of uterine fibroids: a prospective study of 40 women. Fertil Steril. 1990 Dec;54(6):1032-8. PMID: 2123160. X-3, X-3a, X-3f

213. Zheleznov BI, Vasil'chenko NP, Firichenko VI, et al. [Interpretation of morphological changes in the tissues and organs of the reproductive system after radical surgical treatment of uterine leiomyoma]. Akush Ginekol (Mosk). 1990 Jul(7):66-9. PMID: 2240454. X-1, X-1d, X-3, X-3f

214. . [First National Enantone-Gyn Symposium. Advances in the therapy of endometriosis and uterine myomas. Heidelberg, 2 November 1991]. Gynakologe. 1991 Dec;24(6 Suppl):1-12. PMID: 1685723. X-2

215. . Recurrence of fibroids after myomectomy. Lancet. 1991 Aug 31;338(8766):548. PMID: 1678808. X-2

216. . Pretreatment with Zoladex improves surgery for uterine fibroids. Oncology (Williston Park). 1991 Jan;5(1):94. PMID: 1828691. X-2

217. Barau G. [New interventions. Future perspectives]. Soins Gynecol Obstet Pueric Pediatr. 1991 Jun-Jul(121-122):38-40. PMID: 1830172. X-2

218. Barkhatova TP. [Uterine myoma and pregnancy]. Feldsher Akush. 1991 Dec;56(12):44-8. PMID: 1790798. X-11

219. Bezrukov OF, Voitenko VK. [Giant leiomyoma of the stomach]. Klin Khir. 1991(5):74-5. PMID: 1875639. X-1, X-1g, X-1h, X-1i

220. Botvin MA, Sidorova IS, Guriev TD, et al. [The use of biocompatible connecting elements in conservative myomectomy]. Sov Med. 1991(7):84-6. PMID: 1948358. X-11

221. Fedorov EA, Lissov IL, Gubatenko IF, et al. [Non-cancerous tumors of the stomach and duodenum as a cause of acute hemorrhage]. Klin Khir. 1991(4):40-2. PMID: 1881078. X-1, X-1h, X-1i

222. Foulot H, Lecuru F. [Other indications: tubal sterilization, medically assisted procreation, salpingitis, fibromas]. Rev Prat. 1991 Dec 1;41(25):2567-9. PMID: 1839458. X-2

223. Grigor'ev SG, Afanasenko VP, Golubev OI, et al. [Benign tumors of the stomach and intestine]. Klin Khir. 1991(5):72-4. PMID: 1875638. X-1, X-1h, X-i

224. Holmgren E, Windahl T. [Laser surgery combined with antiestrogenic therapy--a suitable therapeutic method in intracavitary myoma]. Lakartidningen. 1991 May 22;88(21):1978. PMID: 2056814. X-2, X-11

225. McLucas B. Intrauterine applications of the resectoscope. Surg Gynecol Obstet. 1991 Jun;172(6):425-31. PMID: 2035130. X-2

226. Merser LJ, Jilbert HM, Chen P. [The use of a gonadotropin-releasing hormone agonist for treating gynecological diseases]. Akush Ginekol (Mosk). 1991 Feb(2):16-20. PMID: 1862845. X-11

227. Nakamura Y, Yoshimura Y, Yamada H, et al. Treatment of uterine leiomyomata with a luteinizing hormone-releasing hormone agonist: the possibility of nonsurgical management in selected perimenopausal women. Fertil Steril. 1991 May;55(5):900-5. PMID: 1902420. X-3, X-3a, X-3f

228. Nenning H, Kohler W, Mahnke PF. [Streptococcus-induced toxic shock]. Pathologe. 1991 Sep;12(5):275-8. PMID: 1946235. X-1, X-1h, X-11

229. Neuman M, Langer R, Golan A, et al. Gonadotropin-releasing hormone (GnRH) action on uterine leiomyomata is not mediated by uterine GnRH receptors. Fertil Steril. 1991 Aug;56(2):364-6. PMID: 1649060. X-1, X-1a, X-1d, X-3, X-3c

230. Nezhat C, Nezhat F, Silfen SL, et al. Laparoscopic myomectomy. Int J Fertil. 1991 Sep-Oct;36(5):275-80. PMID: 1683655. X-3, X-3c

231. Pashkova VS, Erokhin Iu A. [Effects of androgens and gestagens on uterine myoma]. Akush Ginekol (Mosk). 1991 Jan(1):46-9. PMID: 2042719. X-1, X-1a, X-1d, X-3, X-3f

232. Quiel V. [Pregnancy in uterine myoma and abortion request--abortion by hysterectomy]. Zentralbl Gynakol. 1991;113(5):259-62; discussion 61-2. PMID: 2058332. X-1, X-1h, X-3, X-3c

233. Rock JA. Gonadotropin-releasing hormone agonist analogs in the treatment of uterine leiomyomas. Journal of Gynecologic Surgery. 1991;7(3):147-53. PMID: 1993159533. X-2

234. Ruppitsch U, Petru E, Woltsche M, et al. [The value of preventive ovariectomy at the time of hysterectomy for prevention of ovarian cancer]. Gynakol Rundsch. 1991;31 Suppl 2:289-90. PMID: 1790955. X-1, X-1h, X-1i

235. Savey L. [Heavy and prolonged bleeding]. Soins Gynecol Obstet Pueric Pediatr. 1991 May(120):I-ii. PMID: 2047981. X-2, X-11

236. Semm K. [Hysterectomy via laparotomy or pelviscopy. A new CASH method without colpotomy]. Geburtshilfe Frauenheilkd. 1991 Dec;51(12):996-1003. doi: 10.1055/s-2008-1026252. PMID: 1838998. X-2

237. Stovall TG, Ling FW, Henry LC, et al. A randomized trial evaluating leuprolide acetate before hysterectomy as treatment for leiomyomas. Am J Obstet Gynecol. 1991 Jun;164(6 Pt 1):1420-3; discussion 3-5. PMID: 1904681. X-6, X-7

238. Vodianik ND. [Uterine myoma]. Feldsher Akush. 1991 Apr;56(4):18-21. PMID: 1874303. X-2, X-11

239. Wirth U, Rossmanith WG, Sasse V, et al. [Differential effects of GnRH analogs on androgen concentrations in females]. Gynakol Rundsch. 1991;31 Suppl 2:400-2. PMID: 1838737. X-11

240. . Prophylaxis of pelvic sidewall adhesions with Gore-Tex surgical membrane: a multicenter clinical investigation. The Surgical Membrane Study Group. Fertil Steril. 1992 Apr;57(4):921-3. PMID: 1555708. X-1, X-1h, X-3, X-3f

241. Acar B, Posaci C. Clinical application of a gonadotropin releasing hormone analog (buserelin) in the treatment of uterine leiomyomas. Int J Gynaecol Obstet. 1992 May;38(1):52-3. PMID: 1348994. X-2, X-3, X-3c

242. Andrei B, Nonnis-Marzano C. [Operative pelviscopy: notes on the technique]. Acta Biomed Ateneo Parmense. 1992;63(3-4):279-98. PMID: 1341107. X-1, X-1h, X-3, X-3c

243. Benagiano G, Morini A, Primiero FM. Fibroids: overview of current and future treatment options. Br J Obstet Gynaecol. 1992 Feb;99 Suppl 7:18-22. PMID: 1554684. X-2

244. Bergsjo P. Acta seventy years ago. Continuing the story of Volume I: operative versus radiological treatment of fibromyomas. Acta Obstet Gynecol Scand. 1992 Feb;71(2):95-7. PMID: 1316052. X-2

245. Blumenfeld Z. Treatment of uterine leiomyomata by LH-RH agonists. Recent Results Cancer Res. 1992;124:19-31. PMID: 1615216. X-2

246. Breckwoldt M, Zahradnik HP, Karck U. [Pharmacology and possibilities for use of gonadotropin releasing hormone analogs]. Gynakologe. 1992 Aug;25(4):241-6. PMID: 1398253. X-2, X-11

247. Brodzinski W, Wozikowski B, Dzwoniarkiewicz Z. [Levels of ferritin and iron in women with leiomyoma of the uterus treated surgically]. Ginekol Pol. 1992 Jun;63(6):296-9. PMID: 1305130. X-3, X-3a, X-3c

248. Brooks PG. Hysteroscopic surgery using the resectoscope: myomas, ablation, septae & synechiae. Does pre-operative medication help? Clin Obstet Gynecol. 1992 Jun;35(2):249-55. PMID: 1638817. X-2

249. Corson SL. Operative hysteroscopy for infertility. Clin Obstet Gynecol. 1992 Jun;35(2):229-41. PMID: 1638815. X-2

250. Donnez J, Nisolle M. Hysteroscopic surgery. Curr Opin Obstet Gynecol. 1992 Jun;4(3):439-46. PMID: 1623154. X-2

251. Donnez J, Nisolle M, Grandjean P, et al. The place of GnRH agonists in the treatment of endometriosis and fibroids by advanced endoscopic techniques. Br J Obstet Gynaecol. 1992 Feb;99 Suppl 7:31-3. PMID: 1532508. X-1, X-1e, X-3, X-3f

252. Hardiman MK. Routine hysterectomy for large asymptomatic uterine leiomyomata: a reappraisal. Obstet Gynecol. 1992 Sep;80(3 Pt 1):475; author reply -6. PMID: 1495711. X-2

253. Healy DL, Vollenhoven BJ. The role of GnRH agonists in the treatment of uterine fibroids. Br J Obstet Gynaecol. 1992 Feb;99 Suppl 7:23-6. PMID: 1554685. X-2

254. Houdelette P, De Jaureguiberry JP, Quinot JF, et al. [Severe uronephrological complication of an excluded uterine fibroma]. J Urol (Paris). 1992;98(1):53-5. PMID: 1527401. X-1, X-1g, X-3, X-3d

255. Langebrekke A, Skar OJ, Urnes A. Laparoscopic hysterectomy. Initial experience. Acta Obstet Gynecol Scand. 1992 Apr;71(3):226-9. PMID: 1317648. X-1, X-3, X-3c

256. Maheux R, Lemay A. Treatment of peri-menopausal women: potential long-term therapy with a depot GnRH agonist combined with hormonal replacement therapy. Br J Obstet Gynaecol. 1992 Feb;99 Suppl 7:13-7. PMID: 1532506. X-3, X-3b, X-3f

257. March CM. Uterine surgical approaches to reduce prematurity. Clin Perinatol. 1992 Jun;19(2):319-31. PMID: 1617878. X-1, X-2, X-3

258. Mettler L, Semm K. Pelviscopic uterine surgery. Surg Endosc. 1992 Jan-Feb;6(1):23-31. PMID: 1344575. X-1, X-1h, X-2, X-3, X-3c

259. Miller RM, Frank RA. Zoladex (goserelin) in the treatment of benign gynaecological disorders: an overview of safety and efficacy. Br J Obstet Gynaecol. 1992 Feb;99 Suppl 7:37-41. PMID: 1532509. X-2

260. Narayansingh GV, Ramsewak S, Kissoon W. Elective cesarean hysterectomy for uterine fibroids. Int J Gynaecol Obstet. 1992 Jun;38(2):125-6. PMID: 1356843. X-2, X-3, X-3c

261. Nisell H, Lindblom B. [Myoma: uterus can be saved with new therapeutic methods]. Lakartidningen. 1992 Jul 22;89(30-31):2514-6. PMID: 1507982. X-2, X-11

262. Raj R, Lake Y. Polycythemia associated with leiomyoma of the uterus. Br J Obstet Gynaecol. 1992 Nov;99(11):923-5. PMID: 1450146. X-1, X-1g, X-3, X-3d

263. Schreiber JH, Gad A. [Endoscopic surgery in a gynecologic outpatient clinic]. Geburtshilfe Frauenheilkd. 1992 Jan;52(1):42-6. doi: 10.1055/s-2007-1022948. PMID: 1532155. X-1, X-1h, X-3, X-3c

264. Serra GB, Panetta V, Colosimo M, et al. Efficacy of leuprorelin acetate depot in symptomatic fibromatous uteri: the Italian Multicentre Trial. Clin Ther. 1992;14 Suppl A:57-73. PMID: 1606594. X-3, X-3c, X-3f

265. Soderstrom RM. Routine hysterectomy for large asymptomatic uterine leiomyomata: a reappraisal. Obstet Gynecol. 1992 Sep;80(3 Pt 1):474-5; author reply 5-6. PMID: 1495710. X-2

266. Spadaro M, Tresoldi M, Dalla Pria S. [A case of myomectomy in the course of cesarean section]. Minerva Ginecol. 1992 Jun;44(6):343-4. PMID: 1635658. X-1, X-1g, X-3

267. Tantucci C, Paoletti F, Bruni B, et al. Acute respiratory effects of sublingual buprenorphine: comparison with intramuscular morphine. Int J Clin Pharmacol Ther Toxicol. 1992 Jun;30(6):202-7. PMID: 1612814. X-1, X-1h, X-6, X-7

268. Tescher M, Lemaire B, Michaud P. [Laparoscopic vascular exclusion of complicated uterine leiomyoma]. Presse Med. 1992 Mar 28;21(12):582-3. PMID: 1533926. X-11

269. West C. Management of uterine fibroids. Practitioner. 1992 Feb;236(1511):117-8, 21. PMID: 1598325. X-2

270. West CP, Lumsden MA, Baird DT. Goserelin (Zoladex) in the treatment of fibroids. Br J Obstet Gynaecol. 1992 Feb;99 Suppl 7:27-30. PMID: 1532507. X-2

271. Barbieri RL, Dilena M, Chumas J, et al. Leuprolide acetate depot decreases the number of nucleolar organizer regions in uterine leiomyomata. Fertil Steril. 1993 Sep;60(3):569-70. PMID: 8375543. X-1, X-1d, X-6, X-7

272. Bezard-Falgas X, Mares P. [Uterine fibroma. Diagnosis, development, treatment]. Rev Prat. 1993 Jan 15;43(2):251-7. PMID: 8502951. X-1, X-1c, X-2

273. Carlson KJ, Nichols DH, Schiff I. Indications for hysterectomy. N Engl J Med. 1993 Mar 25;328(12):856-60. doi: 10.1056/nejm199303253281207. PMID: 8357364. X-2

274. Carvajal JC, Galvez V, Messina E, et al. [Hysterectomy by videolaparoscopy. Use of the CASH technique]. Rev Chil Obstet Ginecol. 1993;58(3):190-5; discussion 5-6. PMID: 7991830. X-2, X-11

275. Friedman AJ. Use of gonadotropin-releasing hormone agonists before myomectomy. Clin Obstet Gynecol. 1993 Sep;36(3):650-9. PMID: 8403611. X-2

276. Gallagher ML, Roberts-Fox M. Respiratory and circulatory compromise associated with acute hydrothorax during operative hysteroscopy. Anesthesiology. 1993 Nov;79(5):1129-31. PMID: 8238990. X-1, X-1g, X-3, X-3d

277. Ginsburg ES, Benson CB, Garfield JM, et al. The effect of operative technique and uterine size on blood loss during myomectomy: a prospective randomized study. Fertil Steril. 1993 Dec;60(6):956-62. PMID: 8243699. X-1, X-1e, X-6, X-7

278. Golan A, Bukovsky I, Pansky M, et al. Pre-operative gonadotrophin-releasing hormone agonist treatment in surgery for uterine leiomyomata. Hum Reprod. 1993 Mar;8(3):450-2. PMID: 8473466. X-1, X-1e, X-7

279. Harding SG, Pesce A, McMillan L. Symptomatic ascites complicating GnRH analogue use for myoma shrinkage. Br J Obstet Gynaecol. 1993 Nov;100(11):1054-6. PMID: 8251456. X-1, X-1g, X-3, X-3d

280. Igarashi M. Value of myomectomy in the treatment of infertility. Fertil Steril. 1993 Jun;59(6):1331-2; author reply 2-3. PMID: 8495789. X-2

281. Lang N. [Uterine myoma: hormonal therapy--conventional hysterectomy]. Gynakol Geburtshilfliche Rundsch. 1993;33 Suppl 1:6-8. PMID: 8118360. X-2, X-11

282. Loverro G, Nicolardi V, Selvaggi L. Depot GnRH analog treatment of uterine fibroids. Int J Gynaecol Obstet. 1993 Nov;43(2):199-201. PMID: 7905441. X-1, X-1e, X-2, X-3, X-3c

283. Nagele F, Kurz C, Husslein P. [Abdominal hysterectomy without internal peritonealization. A prospective randomized multicenter study]. Gynakol Geburtshilfliche Rundsch. 1993;33 Suppl 1:271-3. PMID: 8118309. X-11

284. Nakamura Y, Yoshimura Y. Treatment of uterine leiomyomas in perimenopausal women with gonadotropin-releasing hormone agonists. Clin Obstet Gynecol. 1993 Sep;36(3):660-7. PMID: 8403612. X-2, X-3, X-3c

285. Paulson RJ. Value of myomectomy in the treatment of infertility. Fertil Steril. 1993 Jun;59(6):1332; author reply -3. PMID: 8495790. X-2

286. Rein MS, Barbieri RL, Welch W, et al. The concentrations of collagen-associated amino acids are higher in GnRH agonist-treated uterine myomas. Obstet Gynecol. 1993 Dec;82(6):901-5. PMID: 8233262. X-1, X-1a, X-1d

287. Smith SK. The regulation of fibroid growth: time for a re-think? Br J Obstet Gynaecol. 1993 Nov;100(11):977-9. PMID: 8251467. X-2

288. Stovall TG. Gonadotropin-releasing hormone agonists: utilization before hysterectomy. Clin Obstet Gynecol. 1993 Sep;36(3):642-9. PMID: 8403610. X-2

289. van Herendael BJ. [Laparoscopy-assisted vaginal hysterectomy]. Gynakologe. 1993 Dec;26(6):360-5. PMID: 8119621. X-11

290. Wierrani F, Huber M, Schramm W, et al. [Effect of salpingectomy in hysterectomy on female sex hormones]. Gynakol Geburtshilfliche Rundsch. 1993;33 Suppl 1:54-6. PMID: 8118358. X-1, X-1h, X-1i

291. Audebert AJ, Madenelat P, Querleu D, et al. Deferred versus immediate surgery for uterine fibroids: clinical trial results. Br J Obstet Gynaecol. 1994 May;101 Suppl 10:29-32. PMID: 8199102. X-1, X-1e

292. Avery JK. Physician-to-physician communication. J Tenn Med Assoc. 1994 Nov;87(11):482-3. PMID: 7983866. X-1, X-1g, X-3, X-3d

293. Benzarti H, Mokhtar I, Fazaa B, et al. [Leiomyoma, a painful cutaneous tumor]. Rev Med Liege. 1994 Nov 1;49(11):611-4. PMID: 7800999. X-1, X-1g, X-1i, X-2, X-3, X-3d

294. Botvin MA, Podedinskii NM, Zuev VM, et al. [Utilization of biocompatible polymers for conservative surgery of the uterus]. Med Tekh. 1994 May-Jun(3):40-1. PMID: 7934733. X-11

295. Chapron C, Dubuisson JB, Aubert V, et al. Total laparoscopic hysterectomy: preliminary results. Hum Reprod. 1994 Nov;9(11):2084-9. PMID: 7868679. X-3, X-3c, X-3f

296. Chapron C, Dubuisson JB, Chavet X, et al. [Uterine myoma: modalities and indications for coelioscopic treatment]. Arch Gynecol Obstet. 1994;255 Suppl 2:S335-44. PMID: 7847925. X-2, X-3, X-3c

297. Chung TK, Chan MY, Stock AI. Myomectomy in the treatment of postpartum haemorrhage. Br J Obstet Gynaecol. 1994 Jan;101(1):73-4. PMID: 8297876. X-1, X-1g, X-3, X-3d

298. Donnez J, Nisolle M, Clerckx F, et al. Advanced endoscopic techniques used in dysfunctional bleeding, fibroids and endometriosis, and the role of gonadotrophin-releasing hormone agonist treatment. Br J Obstet Gynaecol. 1994 May;101 Suppl 10:2-9. PMID: 8199099. X-2

299. Goldfarb HA. Comparison of Bipolar Electrocoagulation and Nd:YAG Laser Coagulation for Symptomatic Reduction of Uterine Myomas. J Am Assoc Gynecol Laparosc. 1994 Aug;1(4, Part 2):S13. PMID: 9073687. X-3, X-3c, X-3f

300. Ito M, Ito S, Kitagawa I, et al. [Total laparoscopic hysterectomy]. Nihon Sanka Fujinka Gakkai Zasshi. 1994 Apr;46(4):361-4. PMID: 8151181. X-11

301. Ivaniuta LI, Bondarchuk O, Khristich VN. [The effect of sex hormones on cardiovascular system function in patients with uterine myoma]. Lik Sprava. 1994 Jan(1):109-11. PMID: 8067002. X-1, X-1h, X-1i, X-11

302. Kayser P. [Indications for and limitations of vaginal hysterectomy]. Bull Soc Sci Med Grand Duche Luxemb. 1994;131(2):25-9. PMID: 7820906. X-11

303. Kishikawa H, Nakamae K, Funato Y, et al. [Leiomyoma, leiomyosarcoma]. Ryoikibetsu Shokogun Shirizu. 1994(4):162-4. PMID: 8007118. X-11

304. Lois D, Zikopoulos K, Paraskevaidis E. Surgical management of leiomyomata during pregnancy. Int J Gynaecol Obstet. 1994 Jan;44(1):71-2. PMID: 7907062. X-2, X-3, X-3a

305. Magos AL, Bournas N, Sinha R, et al. Vaginal myomectomy. Br J Obstet Gynaecol. 1994 Dec;101(12):1092-4. PMID: 7826970. X-3, X-3c, X-3d

306. Marcus SG, Krauss T, Freedberg RS, et al. Pulmonary embolectomy for intravenous uterine leiomyomatosis. Am Heart J. 1994 Jun;127(6):1642-5. PMID: 8198001. X-1, X-1g, X-2, X-3

307. Marino J, Kelly D, Brull SJ. Dilutional hyponatremia during endoscopic curettage: the "female TURP syndrome"? Anesth Analg. 1994 Jun;78(6):1180-1. PMID: 7880224. X-1, X-1g, X-3

308. Matsumoto K, Nouga K, Yokoyama I, et al. Intravenous leiomyomatosis of the uterus. Eur J Vasc Surg. 1994 May;8(3):377-8. PMID: 8013696. X-1, X-1g, X-3, X-3d

309. Pellicano M, Vigorito R, Magri G, et al. [The efficacy of the hysteroscopic treatment of menorrhagia associated with uterine fibromyomas]. Minerva Ginecol. 1994 Oct;46(10):545-9. PMID: 7838410. X-3, X-3c

310. Reinsch RC, Murphy AA, Morales AJ, et al. The effects of RU 486 and leuprolide acetate on uterine artery blood flow in the fibroid uterus: a prospective, randomized study. Am J Obstet Gynecol. 1994 Jun;170(6):1623-7; discussion 7-8. PMID: 8203418. X-1, X-1e, X-7

311. Reissmann T, Diedrich K, Comaru-Schally AM, et al. Introduction of LHRH-antagonists into the treatment of gynaecological disorders. Hum Reprod. 1994 May;9(5):769. PMID: 7929720. X-2

312. Rene AMJ, Morin C, Rodriguez J, et al. Supra-Cervical Laparoscopic Hysterectomy (SCLH) vs. Total Laparoscopic Hysterectomy (LH): A Comparative Post-Operative Study. J Am Assoc Gynecol Laparosc. 1994 Aug;1(4, Part 2):S30. PMID: 9073744. X-3, X-3f, X-5

313. Steiner RA, Haller U. [Formulating indications for treatment of benign tumors of the uterus]. Arch Gynecol Obstet. 1994;255 Suppl 2:S329-34. PMID: 7847924. X-11

314. Stovall TG, Summit RL, Jr., Washburn SA, et al. Gonadotropin-releasing hormone agonist use before hysterectomy. Am J Obstet Gynecol. 1994 Jun;170(6):1744-8; discussion 8-51. PMID: 8203435. X-1, X-1e

315. Trott MS, Gewirtz A, Lavertu P, et al. Sinonasal leiomyomas. Otolaryngol Head Neck Surg. 1994 Nov;111(5):660-4. PMID: 7970808. X-1, X-1g, X-1i, X-3, X-3d, X-5

316. Vercellini P, Crosignani PG. Goserelin (Zoladex) and the anaemic patient. Br J Obstet Gynaecol. 1994 May;101 Suppl 10:33-7. PMID: 8199103. X-2, X-3 X-3f

317. Yan H, Wang J. [The clinical study on hysteromyoma treated with acupuncture]. Zhen Ci Yan Jiu. 1994;19(2):14-6. PMID: 7750167. X-3, X-3f, X-11

318. . An expanded polytetrafluoroethylene barrier (Gore-Tex Surgical Membrane) reduces post-myomectomy adhesion formation. The Myomectomy Adhesion Multicenter Study Group. Fertil Steril. 1995 Mar;63(3):491-3. PMID: 7851575. X-6, X-7

319. Balasch J, Manau D, Mimo J, et al. Trial of routine gonadotropin releasing hormone agonist treatment before abdominal hysterectomy for leiomyoma. Acta Obstet Gynecol Scand. 1995 Aug;74(7):562-5. PMID: 7618457. X-1, X-1e, X-6, X-7

320. Concin H, Bosch H, Schwarzler P. [Hysteroscopy--applications and risks. Hysteroscopy versus fractionated curettage: therapeutic insufficiency of abrasion]. Gynakol Geburtshilfliche Rundsch. 1995;35(2):114-6. PMID: 7620377. X-11

321. De Lia JE, Michelin DP, Johnson SC, et al. Cherney versus midline vertical incision for myomectomy or hysterectomy of a significantly enlarged uterus. Am J Obstet Gynecol. 1995 Dec;173(6):1714-7; discussion 7-8. PMID: 8610750. X-3, X-3b

322. Eizenberg DH. Goserelin reduction of uterine fibroids prior to vaginal hysterectomy. Aust N Z J Obstet Gynaecol. 1995 Feb;35(1):109-10. PMID: 7771988. X-1, X-1g, X-3, X-3d

323. Fernandez-Montoli ME, Diez-Gibert O, Samaniego JM, et al. Total and unbound cytosolic estrogen and progesterone receptors in myometrium and fibroid after gonadotropin-releasing hormone agonist treatment. Fertil Steril. 1995 Mar;63(3):522-7. PMID: 7851581. X-1, X-1d, X-6, X-7

324. Gallinat A. [Ambulatory endoscopic surgery--ovary and leiomyoma]. Arch Gynecol Obstet. 1995;257(1-4):17-21. PMID: 8579394. X-11

325. Gorbanev EA. [A case of leiomyomatosis with a clinical picture of chylopericardium and chylothorax]. Ter Arkh. 1995;67(3):65-7. PMID: 7770810. X-1, X-1g, X-3

326. Gregora M, Forbes K, Hill B. Early severe haemorrhage complicating GnRH analogue treatment of submucous uterine fibroids. Aust N Z J Obstet Gynaecol. 1995 Feb;35(1):111-2. PMID: 7771989. X-1, X-1g, X-3, X-3d

327. Ishimaru T, Samejima T, Masuzaki H. GnRHa and steroid add-back therapy for uterine myoma. Int J Gynaecol Obstet. 1995 Feb;48(2):221. PMID: 7789601. X-2, X-3, X-3c

328. Kallimanis G, Garra BS, Tio TL, et al. The feasibility of three-dimensional endoscopic ultrasonography: a preliminary report. Gastrointest Endosc. 1995 Mar;41(3):235-9. PMID: 7789682. X-1, X-1h, X-1i, X-3, X-3f

329. Klimek M, Reron A, Homa T, et al. [Video-laparoscopic removal of uterine myoma]. Ginekol Pol. 1995 Jun;66(6):357-60. PMID: 8522243. X-11

330. Levy T, Ben-Rafael Z. [Estrogen-progesterone "add-back" for long-term GNRH analogue therapy]. Harefuah. 1995 Jun 15;128(12):789-92. PMID: 7557691. X-2, X-11

331. Mais V, Ajossa S, Piras B, et al. Prevention of de-novo adhesion formation after laparoscopic myomectomy: a randomized trial to evaluate the effectiveness of an oxidized regenerated cellulose absorbable barrier. Hum Reprod. 1995 Dec;10(12):3133-5. PMID: 8822429. X-1, X-1h, X-7

332. Makhovskii VZ, Dolganin PF, Mazikina LM. [One-stage surgical treatment of giant multichamber recurrent irreducible ventral hernia and chronic calculous cholecystitis associated with uterine fibromyoma]. Khirurgiia (Mosk). 1995(2):64. PMID: 7616716. X-1, X-1g, X-1i, X-3, X-3d

333. Mecke H, Wallas F, Brocker A, et al. [Pelviscopic myoma enucleation: technique, limits, complications]. Geburtshilfe Frauenheilkd. 1995 Jul;55(7):374-9. doi: 10.1055/s-2007-1022804. PMID: 7557202. X-3, X-3c, X-3f

334. Mettler L, Alvarez-Rodas E, Lehmann-Willenbrock E, et al. Intrafascial supracervical hysterectomy without colpotomy and transuterine mucosal resection by pelviscopy and laparotomy. Diagn Ther Endosc. 1995;1(4):201-7. doi: 10.1155/dte.1.201. PMID: 18493366. X-3, X-3a, X-3f

335. Nagele F, Kurz C, Staudach A, et al. Closure or nonclosure of the visceral peritoneum in abdominal hysterectomy. Journal of Gynecologic Surgery. 1995;11(3):133-9. PMID: 1995306252. X-1, X-1h, X-6

336. Parker WH. Myomectomy: laparoscopy or laparotomy? Clin Obstet Gynecol. 1995 Jun;38(2):392-400. PMID: 7554606. X-2

337. Ravina JH, Merland JJ, Ciraru-Vigneron N, et al. [Arterial embolization: a new treatment of menorrhagia in uterine fibroma]. Presse Med. 1995 Dec 2;24(37):1754. PMID: 8545421. X-2, X-11

338. Reron A. [Uterine myomectomy in the treatment of infertility]. Ginekol Pol. 1995 Feb;66(2):108-11. PMID: 8575674. X-2

339. Rutgers JL, Spong CY, Sinow R, et al. Leuprolide acetate treatment and myoma arterial size. Obstet Gynecol. 1995 Sep;86(3):386-8. doi: 10.1016/0029-7844(95)00191-s. PMID: 7651647. X-1, X-1e, X-3, X-3f

340. Seki K, Kobiki K, Komiyama S, et al. [Total laparoscopic hysterectomy with abdominal wall-lift method]. Nihon Sanka Fujinka Gakkai Zasshi. 1995 Dec;47(12):1397-400. PMID: 8568364. X-2, X-11

341. Spong CY, Sinow R, Renslo R, et al. Induced hypoestrogenism increases the arterial resistance index of leiomyomata without affecting uterine or carotid arteries. J Assist Reprod Genet. 1995 May;12(5):338-41. PMID: 8520200. X-6, X-7

342. Stovall TG, Muneyyirci-Delale O, Summitt RL, Jr., et al. GnRH agonist and iron versus placebo and iron in the anemic patient before surgery for leiomyomas: a randomized controlled trial. Leuprolide Acetate Study Group. Obstet Gynecol. 1995 Jul;86(1):65-71. PMID: 7784025. X-1, X-1e, X-6, X-7

343. Takebayashi T, Fujino Y, Umesaki N, et al. Danazol suspension injected into the uterine cervix of patients with adenomyosis and myoma. Preliminary study. Gynecol Obstet Invest. 1995;39(3):207-11. PMID: 7789919. X-3, X-3c, X-3f

344. Vorobev GI, Odariuk TS, Shelygin Iu A, et al. [Differential diagnosis of non-epithelial rectal neoplasms]. Khirurgiia (Mosk). 1995 Jan(1):45-50. PMID: 7745937. X-1, X-1i, X-3

345. Watanabe Y, Nakamura G. Effects of two different doses of leuprolide acetate depot on uterine cavity area in patients with uterine leiomyomata. Fertil Steril. 1995 Mar;63(3):487-90. PMID: 7851574. X-6, X-7

346. . ACOG criteria set. Gonadotropin-releasing hormone agonists for preoperative treatment of leiomyomata. American College of Obstetricians and Gynecologists Committee on Quality Assessment. Int J Gynaecol Obstet. 1996 Feb;52(2):213-4. PMID: 8855113. X-2

347. Andrei B. Myomectomy by pelvicoscopy. Int Surg. 1996 Jul-Sep;81(3):271-5. PMID: 9028988. X-2

348. Benagiano G, Kivinen ST, Fadini R, et al. Zoladex (goserelin acetate) and the anemic patient: results of a multicenter fibroid study. Fertil Steril. 1996 Aug;66(2):223-9. PMID: 8690106. X-1, X-1e, X-6, X-7

349. Chang KJ, Yoshinaka R, Nguyen P. Endoscopic ultrasound-assisted band ligation: a new technique for resection of submucosal tumors. Gastrointest Endosc. 1996 Dec;44(6):720-2. PMID: 8979064. X-1, X-1g, X-1i, X-3 X-3d, X-5

350. Dicker D, Dekel A, Orvieto R, et al. The controversy of laparoscopic myomectomy. Hum Reprod. 1996 May;11(5):935-7. PMID: 8815068. X-2

351. Donnez J, Mathieu PE, Bassil S, et al. Laparoscopic myomectomy today. Fibroids: management and treatment: the state of the art. Hum Reprod. 1996 Sep;11(9):1837-40. PMID: 8921049. X-2

352. Dubuisson JB, Chapron C. Laparoscopic myomectomy today. A good technique when correctly indicated. Hum Reprod. 1996 May;11(5):934-5. PMID: 8815067. X-2, X-3, X-3c

353. Dubuisson JB, Chapron C. [Uterine fibroma. Diagnosis, development, treatment]. Rev Prat. 1996 Jan 1;46(1):107-12. PMID: 8596883. X-2, X-11

354. Fletcher H, Frederick J, Hardie M, et al. A randomized comparison of vasopressin and tourniquet as hemostatic agents during myomectomy. Obstet Gynecol. 1996 Jun;87(6):1014-8. PMID: 8649682. X-1, X-1e, X-7

355. Friedmann W, Maier RF, Luttkus A, et al. Uterine rupture after laparoscopic myomectomy. Acta Obstet Gynecol Scand. 1996 Aug;75(7):683-4. PMID: 8822668. X-1, X-1g, X-3, X-3d

356. Gerris J, Degueldre M, Peters AA, et al. The place of Zoladex in deferred surgery for uterine fibroids. Zoladex Myoma Study Group. Horm Res. 1996;45(6):279-84. PMID: 8793522. X-1, X-1e, X-6, X-7

357. Golan A. GnRH analogues in the treatment of uterine fibroids. Hum Reprod. 1996 Nov;11 Suppl 3:33-41. PMID: 9147100. X-2

358. Hasson HM. The role of laparoscopy in myomectomy. Int J Fertil Menopausal Stud. 1996 May-Jun;41(3):276-9. PMID: 8799755. X-2

359. Hutchins FL, Jr. A randomized comparison of vasopressin and tourniquet as hemostatic agents during myomectomy. Obstet Gynecol. 1996 Oct;88(4 Pt 1):639-40. PMID: 8841235. X-2

360. Katabuchi H, Ohshige A, Matsumura S, et al. [Clinical and histopathologic features of the uterine lipoleiomyoma]. Nihon Sanka Fujinka Gakkai Zasshi. 1996 Dec;48(12):1169-72. PMID: 8960693. X-1, X-1d, X-11

361. Kunz G, Plath T, Leyendecker G. [Comparison of laparoscopically assisted vaginal hysterectomy with abdominal hysterectomy. Technique and results]. Geburtshilfe Frauenheilkd. 1996 Sep;56(9):453-7. doi: 10.1055/s-2007-1022286. PMID: 8991841. X-1, X-1h, X-1i, X-11

362. Lee JM, Baumgartner FJ, Shellans S, et al. Degeneration and sarcomatous transformation of a retroperitoneal leiomyoma. Eur J Surg. 1996 Apr;162(4):337-40. PMID: 8739423. X-1, X-1g, X-3

363. Lerner A, Levi T, Peleg D, et al. [Indications for hysterectomy--a time for re-evaluation]. Harefuah. 1996 Mar 15;130(6):400-3. PMID: 8707198. X-2, X-3

364. Maheux R. GnRH agonists: an alternative to surgery? Hum Reprod. 1996 Nov;11 Suppl 3:43-50. PMID: 9147101. X-3, X-3b

365. Nezhat F, Seidman DS, Nezhat C, et al. Laparoscopic myomectomy today. Why, when and for whom? Hum Reprod. 1996 May;11(5):933-4. PMID: 8671365. X-2

366. Nikolov A, Karag'ozov I. [The development of conservative treatment in uterine myoma]. Akush Ginekol (Sofiia). 1996;35(1-2):51-3. PMID: 8967544. X-11

367. Sato A, Takahashi O, Saito A, et al. [Limitation of uterine weight in total vaginal hysterectomy in patients with uterine myoma and adenomyosis]. Nihon Sanka Fujinka Gakkai Zasshi. 1996 Mar;48(3):240-2. PMID: 8721061. X-11

368. Sener AB, Seckin NC, Ozmen S, et al. The effects of hormone replacement therapy on uterine fibroids in postmenopausal women. Fertil Steril. 1996 Feb;65(2):354-7. PMID: 8566261. X-1, X-1f, X-1h

369. Shaw RW. Blood flow changes in the uterus induced by treatment with GnRH analogues. Hum Reprod. 1996 Nov;11 Suppl 3:27-32. PMID: 9147099. X-1, X-1e, X-2

370. Sutton CJ. Treatment of large uterine fibroids. Br J Obstet Gynaecol. 1996 Jun;103(6):494-6. PMID: 8645637. X-2

371. Uncu G, Benderli S, Esmer A. Pregnancy during gonadotrophin-releasing hormone agonist therapy. Aust N Z J Obstet Gynaecol. 1996 Nov;36(4):484-5. PMID: 9006841. X-1, X-1g, X-3, X-3d

372. Way JC. Retroareolar leiomyoma. Can J Surg. 1996 Aug;39(4):339. PMID: 8697329. X-1, X-1g, X-1i, X-3, X-3d, X-5

373. Yang Y, Zheng S, Li K. [Treatment of uterine leiomyoma by two different doses of mifepristone]. Zhonghua Fu Chan Ke Za Zhi. 1996 Oct;31(10):624-6. PMID: 9275461. X-3, X-3b

374. . [Radiologists may prevent hysterectomy in some patients]. Rofo. 1997 Nov;167(5):M39. PMID: 9440884. X-2, X-11

375. Arcangeli S, Pasquarette MM. Gravid uterine rupture after myolysis. Obstet Gynecol. 1997 May;89(5 Pt 2):857. PMID: 9166351. X-1, X-1g, X-3, X-3d

376. Basbug M, Tayyar M, Erdogan N. Fibroma of the vulva and uterine leiomyoma. Int J Gynaecol Obstet. 1997 Oct;59(1):55-6. PMID: 9359450. X-1, X-1g, X-3, X-3d

377. Brosens IA. Variable response of uterine leiomyomas after GnRH agonist therapy. Fertil Steril. 1997 Nov;68(5):948-9. PMID: 9389836. X-2

378. Caird LE, West CP, Lumsden MA, et al. Medroxyprogesterone acetate with Zoladex for long-term treatment of fibroids: effects on bone density and patient acceptability. Hum Reprod. 1997 Mar;12(3):436-40. PMID: 9130735. X-5

379. Chabanne F, Wallez JC, Lansac J. [Deciding on a cesarean after a laparoscopic myomectomy?]. Contracept Fertil Sex. 1997 Oct;25(10):753-6. PMID: 9424213. X-2, X-11

380. Chapman R. Treatment of large uterine fibroids. Br J Obstet Gynaecol. 1997 Jul;104(7):867. PMID: 9236659. X-2

381. Davis SR. "Add-back" estrogen reverses cognitive deficits induced by a gonadotropin-releasing hormone agonist in women with leiomyomata uteri. J Clin Endocrinol Metab. 1997 Feb;82(2):702-3. doi: 10.1210/jcem.82.2.3771-3. PMID: 9024281. X-2

382. Dubuisson JB, Chapron C, Fauconnier A. Laparoscopic myomectomy. Operative technique and results. Ann N Y Acad Sci. 1997 Sep 26;828:326-31. PMID: 9329853. X-3, X-3c

383. Fernandez H. [Infertility and small myoma: role of myomectomy]. Contracept Fertil Sex. 1997 May;25(5):348-9. PMID: 9273103. X-11

384. Fiore CE, Dieli M, Caschetto S, et al. Relative deficiency in circulating levels of insulin-like growth factor I (IGF-I) during long-term treatment with a GnRH agonist. Horm Metab Res. 1997 Sep;29(9):472-4. doi: 10.1055/s-2007-979081. PMID: 9370120. X-1, X-1a, X-3, X-3f

385. Gomez Arce JE, Garcia Herreros F, Estan A, et al. [Disseminated peritoneal leiomyomatosis]. Med Clin (Barc). 1997 Sep 13;109(8):318-9. PMID: 9379759. X-1, X-1h, X-1i, X-3, X-3f, X-11

386. Herman P, Gaspard U. [The value of trans-hysteroscopic electroresection in the treatment of benign organic uterine bleeding. Comparison with classical surgical techniques]. Rev Med Liege. 1997 Feb;52(2):89-92. PMID: 9173490. X-11

387. Hutchins FL, Jr. Preoperative use of GnRH agonist for leiomyomas. J Reprod Med. 1997 Apr;42(4):253. PMID: 9131502. X-2, X-7

388. Lo KW, Lau TK. The use of gonadotrophin-releasing hormone analogues in gynaecology. Chin Med J (Engl). 1997 Oct;110(10):746-9. PMID: 9642302. X-2

389. Lopes P. [In an infertile woman, does the presence of one or several myomas of less than three cm in diameter justify a myomectomy?]. Contracept Fertil Sex. 1997 May;25(5):350-1. PMID: 9273104. X-2, X-3

390. Magos A. Treatment of large uterine fibroids. Br J Obstet Gynaecol. 1997 Jul;104(7):867-8. PMID: 9236660. X-2

391. Metcalfe W, Boulton-Jones JM. Exacerbation of lupus nephritis in association with leuprorelin injection for uterine leiomyoma. Nephrol Dial Transplant. 1997 Aug;12(8):1699-700. PMID: 9269652. X-1, X-1g, X-3, X-3d

392. Nigojevic S, Kapural L, Scukanec-Spoljar M, et al. Leiomyomatosis peritonealis disseminata in a postmenopausal woman. Acta Obstet Gynecol Scand. 1997 Oct;76(9):893-4. PMID: 9351422. X-1, X-1g, X-1h, X-1i, X-3, X-3d, X-5

393. Rutgers J. Leuprolide-treated myomas. Am J Surg Pathol. 1997 Apr;21(4):500-1. PMID: 9131000. X-2

394. Skolnick AA. Interventional radiological treatments tested. Jama. 1997 May 14;277(18):1424-5. PMID: 9145701. X-2, X-3, X-3c

395. Steege JF. Indications for hysterectomy: have they changed? Clin Obstet Gynecol. 1997 Dec;40(4):878-85. PMID: 9429801. X-2

396. Szamatowicz J, Laudanski T, Bulkszas B, et al. Fibromyomas and uterine contractions. Acta Obstet Gynecol Scand. 1997 Nov;76(10):973-6. PMID: 9435739. X-1, X-1d, X-1h, X-3, X-3f

397. Thomas S. Embolisation of uterine fibroids. Nurs Stand. 1997 Jul 23;11(44):27. PMID: 9325996. X-2

398. Wijesinghe P. Leiomyomatosis peritonealis disseminata presenting as an acute abdomen. Ceylon Med J. 1997 Dec;42(4):196-7. PMID: 9476408. X-1, X-1g, X-3

399. Zullo E, Pellicano M, De Stefano R, et al. GnRH analogues and laparoscopic myomectomy. Italian Journal of Gynaecology and Obstetrics. 1997;9(2):63-7. PMID: 1997216061. X-1, X-1e

400. . Options for hysterectomy. Health News. 1998 Oct 25;4(13):1-2. PMID: 9803170. X-2

401. . Treating fibroids. Harv Womens Health Watch. 1998 Apr;5(8):2-3. PMID: 9577267. X-2

402. Adamian LV, Askol'skaia SI, Van'ko LV, et al. [Local vaginal immunity in patients with uterine myoma before and after hysterectomy]. Biull Eksp Biol Med. 1998 Oct;126(10):436-40. PMID: 9825145. X-1, X-11

403. Bartos PJ. [Laparoscopic hysterectomy of the enlarged uterus: an advanced vaginal technique--retrospective analytic study]. Ceska Gynekol. 1998 Feb;63(1):86-7. PMID: 9650395. X-3, X-3a

404. Beranek JT. Induction of apoptosis by laser: a new therapeutic modality. Lasers Surg Med. 1998;23(2):65. PMID: 9738539. X-2, X-3, X-3c

405. Bessenay F, Cravello L, Roger V, et al. [Vaginal myomectomy]. Contracept Fertil Sex. 1998 Jun;26(6):448-51. PMID: 9691523. X-1, X-1h, X-3, X-3c

406. Buckshee K, Verma A, Karak AK. Leiomyomatosis peritonealis disseminata. Int J Gynaecol Obstet. 1998 May;61(2):191-2. PMID: 9639228. X-1, X-1g, X-3, X-3d

407. Chapman R. The induction of apoptosis by laser: a new therapeutic modality. Lasers Surg Med. 1998;23(5):247. PMID: 9888318. X-2

408. Chapman R. Successful pregnancies following laser-induced interstitial thermotherapy (LITT) for treatment of large uterine leiomyomas by a minimally invasive method. Acta Obstet Gynecol Scand. 1998 Nov;77(10):1024-5. PMID: 9849850. X-1, X-1g, X-3, X-3d

409. Cittadini E. Laparoscopic myomectomy: the Italian experience. J Am Assoc Gynecol Laparosc. 1998 Feb;5(1):7-9. PMID: 9454869. X-2

410. Cramer SF. Effects of gonadotropin-releasing hormone agonists on uterine leiomyomas. Arch Pathol Lab Med. 1998 Dec;122(12):1045-6. PMID: 9870847. X-2

411. de Aloysio D, Altieri P, Penacchioni P, et al. Bleeding patterns in recent postmenopausal outpatients with uterine myomas: comparison between two regimens of HRT. Maturitas. 1998 Jun 17;29(3):261-4. PMID: 9699198. X-1, X-1i, X-3, X-3b

412. Demopoulos RI, Mesia AF. Effects of leuprolide acetate on treatment of leiomyomata--clues to mechanisms of action. Adv Anat Pathol. 1998 Mar;5(2):129-36. PMID: 9868519. X-2

413. Dicker D, Dekel A, Orvieto R, et al. [Laparoscopic myomectomy]. Harefuah. 1998 Oct;135(7-8):310-2. PMID: 9885681. X-11

414. Dubinsky T, Abu-Gazzeh Y, Stroehlein K. Role of transvaginal sonography and endometrial biopsy in the evaluation of dysfunctional uterine bleeding in premenopausal women. J Clin Ultrasound. 1998 Mar-Apr;26(3):180-1. PMID: 9502044. X-1, X-1c, X-3

415. Eldar-Geva T, Healy DL. Other medical management of uterine fibroids. Baillieres Clin Obstet Gynaecol. 1998 Jun;12(2):269-88. PMID: 10023422. X-2

416. Ellis PK, Kelly IM, Fogarty PP. The use of transcatheter embolisation to treat uterine fibroids. Ulster Med J. 1998 Nov;67(2):139-41. PMID: 9885556. X-1, X-1g, X-3, X-3d

417. Fidler HM, El-Jabbour JN, Bevan G. Endoscopic resection of large polypoid leiomyoma: case study. Endoscopy. 1998 Oct;30(8):740. doi: 10.1055/s-2007-1001401. PMID: 9865570. X-1, X-1g, X-3

418. Hastier P, Caroli-Bosc FX, Harris AG, et al. Solitary hepatic infantile myofibromatosis in a female adolescent. Dig Dis Sci. 1998 May;43(5):1124-8. PMID: 9590431. X-1, X-1g, X-1i, X-3

419. Huang FJ, Chang SY, Chang JC. Recurrent wound infection due to abdomino-vaginal fistula after abdominal hysterectomy. Br J Obstet Gynaecol. 1998 Jul;105(7):807-8. PMID: 9692426. X-1, X-1g, X-3, X-3d

420. Kok KY, Mathew VV, Yapp SK. Laparoscopic-assisted small bowel resection for a bleeding leiomyoma. Surg Endosc. 1998 Jul;12(7):995-6. PMID: 9632878. X-1, X-1g, X-1i, X-3

421. Lee DW, Chan AC, Lai CW, et al. Endoscopic management of postpolypectomy perforation. Endoscopy. 1998 Sep;30(7):S84. PMID: 9826160. X-1, X-1g, X-1i, X-3, X-3d

422. Maredia R, Snyder BJ, Harvey LA, et al. Benign metastasizing leiomyoma in the lung. Radiographics. 1998 May-Jun;18(3):779-82. doi: 10.1148/radiographics.18.3.9599398. PMID: 9599398. X-1, X-1g, X-1i

423. Nikolov A, Raicheva R, Mainkhard K. [Myomectomy performed after Zoladex preparation with subsequent repair of the uterine wall via a balloon catheter in the uterine cavity]. Akush Ginekol (Sofiia). 1998;37(1):55-7. PMID: 9770805. X-1, X-1g, X-3, X-3d

424. Pelosi MA, 3rd, Pelosi MA. Comparison of bimanual examination with ultrasound examination before hysterectomy for uterine leiomyoma. Obstet Gynecol. 1998 Nov;92(5):890. PMID: 9794689. X-1, X-1c, X-2

425. Pelosi MA, Pelosi MA, 3rd. Simultaneous laparoscopic surgical treatments. Surg Laparosc Endosc. 1998 Feb;8(1):81-2. PMID: 9488580. X-2

426. Peyman GA, Martinez CE, Hew A, et al. Endoresection of a ciliary body leiomyoma. Can J Ophthalmol. 1998 Feb;33(1):32-4. PMID: 9513771. X-1, X-1g, X-1i, X-3

427. Pickersgill A. GnRH agonists and add-back therapy: is there a perfect combination? Br J Obstet Gynaecol. 1998 May;105(5):475-85. PMID: 9637115. X-2

428. Piron A, Gielen JL, Kolh P, et al. [Laparoscopic discovery of disseminated peritoneal leiomyomatosis closely resembling metastatic peritoneal carcinomatosis]. Ann Chir. 1998;52(3):298-300. PMID: 9752460. X-1, X-1g, X-1i

429. Reidy JF, Bradley EA. Uterine artery embolization for fibroid disease. Cardiovasc Intervent Radiol. 1998 Sep-Oct;21(5):357-60. PMID: 9853139. X-2

430. Rempen A. [Obstetrical management in enucleated myoma]. Z Geburtshilfe Neonatol. 1998 Mar-Apr;202(2):91. PMID: 9654723. X-2, X-3, X-3d

431. Schafer WR, Zahradnik HP. Organochlorine compounds and xenoestrogens in human endometrium. Adv Exp Med Biol. 1998;444:5-8. PMID: 10026929. X-1, X-1a, X-2

432. Tan SJ, Lang JH. [Clinical uses of goserelin in gynecologic diseases and its safety]. Zhonghua Fu Chan Ke Za Zhi. 1998 Jan;33(1):58-60. PMID: 10682460. X-2

433. Underwood PB, Jr. Been there--done that: surgical challenges. Am J Obstet Gynecol. 1998 Aug;179(2):330-5. PMID: 9731834. X-2

434. Vercellini P, Crosignani PG, Mangioni C, et al. Treatment with a gonadotrophin releasing hormone agonist before hysterectomy for leiomyomas: results of a multicentre, randomised controlled trial. Br J Obstet Gynaecol. 1998 Nov;105(11):1148-54. PMID: 9853762. X-7

435. Zeng C, Gu M, Huang H. [A clinical control study on the treatment of uterine leiomyoma with gonadotrophin releasing hormone agonist or mifepristone]. Zhonghua Fu Chan Ke Za Zhi. 1998 Aug;33(8):490-2. PMID: 10806751. X-11

436. Zullo F, Pellicano M, De Stefano R, et al. A prospective randomized study to evaluate leuprolide acetate treatment before laparoscopic myomectomy: efficacy and ultrasonographic predictors. Am J Obstet Gynecol. 1998 Jan;178(1 Pt 1):108-12. PMID: 9465812. X-1, X-1e, X-7

437. Zullo F, Pellicano M, Di Carlo C, et al. Ultrasonographic prediction of the efficacy of GnRH agonist therapy before laparoscopic myomectomy. J Am Assoc Gynecol Laparosc. 1998 Nov;5(4):361-6. PMID: 9782139. X-1, X-1e, X-7

438. . Patient death raises issue of new technology in ORs. OR Manager. 1999 Jan;15(1):1, 8-9. PMID: 10345129. X-2

439. Abbara S, Spies JB, Scialli AR, et al. Transcervical expulsion of a fibroid as a result of uterine artery embolization for leiomyomata. J Vasc Interv Radiol. 1999 Apr;10(4):409-11. PMID: 10229467. X-1, X-1g, X-3, X-3d

440. Abulafia O, Sherer DM. Ultrasonographic diagnosis of postpartum aborting large intracavitary leiomyoma. J Ultrasound Med. 1999 Mar;18(3):243-5. PMID: 10082360. X-1, X-1c, X-1g, X-3, X-3d

441. Andrei B, Crovini G, Rosi A. Uterine myomas: pelviscopic treatment. Clin Exp Obstet Gynecol. 1999;26(1):44-6. PMID: 10490357. X-2, X-3, X-3c

442. Barbieri RL. Ambulatory management of uterine leiomyomata. Clin Obstet Gynecol. 1999 Jun;42(2):196-205. PMID: 10370841. X-2

443. Benzakine Y, Driguez P. [Diagnostic modalities: indications and place of diagnostic hysteroscopy]. J Gynecol Obstet Biol Reprod (Paris). 1999 Nov;28(7):724-8. PMID: 10624624. X-1, X-1c, X-2, X-3

444. Boubli L. [Drug treatment of uterine fibromas]. J Gynecol Obstet Biol Reprod (Paris). 1999 Nov;28(7):729-31. PMID: 10624625. X-2

445. Bouret JM. [Role of embolization in myomatous pathology]. J Gynecol Obstet Biol Reprod (Paris). 1999 Nov;28(7):753-60. PMID: 10624629. X-1, X-1d, X-2

446. Chappatte O. Current fibroid management. Practitioner. 1999 Jun;243(1599):474-6, 9, 81-3. PMID: 10476566. X-2

447. Chapron C, Fernandez B, Fauconnier A, et al. [Indications and modalities of conservative surgical treatment of interstitial and sub-serous myomas]. J Gynecol Obstet Biol Reprod (Paris). 1999 Nov;28(7):732-7. PMID: 10624626. X-1, X-1h, X-2

448. Cosson M, Vinatier D, Subtil D. [Indications and modalities of radical surgical treatment in sub-serous and interstitial myomas]. J Gynecol Obstet Biol Reprod (Paris). 1999 Nov;28(7):738-47. PMID: 10624627. X-2, X-11

449. Cravello L. [Indications and modalities of surgical treatment for sub-mucosal myomas]. J Gynecol Obstet Biol Reprod (Paris). 1999 Nov;28(7):748-52. PMID: 10624628. X-2

450. Davies A. Treatment with a gonadotrophin releasing hormone agonist before hysterectomy for leiomyomas: results of a multicentre, randomised controlled trial. Br J Obstet Gynaecol. 1999 Jul;106(7):751-2. PMID: 10428541. X-2

451. De Leo V, De Palma P, Ditto A, et al. Total abdominal hysterectomy: a randomized study comparing two techniques. Eur J Obstet Gynecol Reprod Biol. 1999 Aug;85(2):141-5. PMID: 10584626. X-1, X-1h

452. Dessolle L, Darai E. [Uterine fibromyoma. Diagnosis, evolution, treatment]. Rev Prat. 1999 Dec 1;49(19):2161-7. PMID: 10649654. X-1, X-1c, X-1h, X-2

453. Elenkov C, Tzvetkov M, Kumanov H. [Obstruction of the upper urinary tract following gynecological interventions for neoplastic diseases of female genitalia]. Khirurgiia (Sofiia). 1999;55(3):37-46. PMID: 11194669. X-1, X-1i

454. Felberbaum RE, Ludwig M, Diedrich K. [Medical treatment of uterine fibroids with the LHRH antagonist: Cetrorelix]. Contracept Fertil Sex. 1999 Oct;27(10):701-9. PMID: 10605180. X-6, X-7, X-11

455. Haas S, Spies JB. Toward optimal health: the experts respond to fibroids. Interview by Jodi Godfrey Meisler. J Womens Health Gend Based Med. 1999 Sep;8(7):879-83. PMID: 10534290. X-2

456. Hovsepian DM. Uterine fibroid embolization: another paradigm shift for interventional radiology? J Vasc Interv Radiol. 1999 Oct;10(9):1145-7. PMID: 10527189. X-2

457. Hutchins FL, Worthington-Kirsch R, Berkowitz RP. GnRH analogs and uterine artery embolization. J Am Assoc Gynecol Laparosc. 1999 Aug;6(3):367-8. PMID: 10610208. X-2, X-3, X-3a

458. Isaacson KB. Complications of hysteroscopy. Obstet Gynecol Clin North Am. 1999 Mar;26(1):39-51. PMID: 10083928. X-1, X-1g, X-2

459. Istre O. Fluid absorption and the long term outcome after transcervical resection of the endometrium. Acta Obstet Gynecol Scand. 1999 Nov;78(10):919. PMID: 10577627. X-1, X-1i, X-2

460. Ivaniuta LI, Kondratiuk VK, Danilenko OH, et al. [Diagnosis, surgical treatment and evaluation of adaptation possibilities of women with congenital abnormalities and fibromyoma of the uterus]. Klin Khir. 1999(7):43-4. PMID: 10483220. X-1, X-1d, X-1h, X-3, X-3f

461. Jamin C. [Contraception, hormone replacement therapy and myomas]. J Gynecol Obstet Biol Reprod (Paris). 1999 Nov;28(7):768-71. PMID: 10624631. X-2

462. Jermy KV, Stanton SL, Nager CW, et al. A leiomyomatous perineal hernia? Br J Obstet Gynaecol. 1999 May;106(5):507-8. PMID: 10430205. X-1, X-1g, X-1h, X-3, X-3d

463. Katsumori T, Nakajima K, Hanada Y. MR imaging of a uterine myoma after embolization. AJR Am J Roentgenol. 1999 Jan;172(1):248-9. doi: 10.2214/ajr.172.1.9888784. PMID: 9888784. X-1, X-1g, X-3, X-3d

464. Kelleher C, Braude P. Recent advances. Gynaecology. Bmj. 1999 Sep 11;319(7211):689-92. PMID: 10480828. X-2

465. Krizko M. [Possibilities of reducing blood loss during gynecologic operations with drugs]. Ceska Gynekol. 1999 Jun;64 Suppl 2:7-8. PMID: 10566247. X-1, X-1e, X-1i, X-2

466. Laforga JB, Aranda FI. Uterine leiomyomas with T-cell infiltration associated with GnRH agonist goserelin. Histopathology. 1999 May;34(5):471-2. PMID: 10231516. X-1, X-1g, X-2

467. Law P, Gedroyc WM, Regan L. Magnetic-resonance-guided percutaneous laser ablation of uterine fibroids. Lancet. 1999 Dec 11;354(9195):2049-50. PMID: 10636374. X-3, X-3c

468. Lindheim SR, Kavic S, Sauer MV. Intraoperative applications of saline infusion ultrasonography. J Assist Reprod Genet. 1999 Aug;16(7):390-4. PMID: 10459524. X-1, X-1h, X-2

469. Marfella A, Bilancio A, Polese C, et al. Urinary neopterin and kynurenine in patients submitted to surgical stress with different inhalational anesthetics (halothane or isoflurane). Int J Immunopharmacol. 1999 Jul;21(7):423-33. PMID: 10454016. X-1, X-1h, X-1i

470. McBride G. Benign but no longer forgotten--fibroids get their own conference. Lancet. 1999 Oct 23;354(9188):1450. doi: 10.1016/s0140-6736(05)77589-9. PMID: 10543681. X-2

471. McCluggage WG, Bharucha H. Cellular leiomyoma mimicking endometrial stromal neoplasm in association with GnRH agonist goserelin. Histopathology. 1999 Feb;34(2):184-6. PMID: 10064405. X-1, X-1g, X-3, X-3d

472. McLucas B, Goodwin SC, Adler L, et al. Fatal septicaemia after fibroid embolisation. Lancet. 1999 Nov 13;354(9191):1730. doi: 10.1016/s0140-6736(05)76717-9. PMID: 10568598. X-3, X-3c, X-3d

473. Mellor Pita S, Yebra Bango M, Gonzalez Hernando C, et al. [Von Recklinghausen's disease and abdominal mass]. Rev Clin Esp. 1999 Nov;199(11):759-60. PMID: 10638244. X-2, X-3, X-3d

474. Mesia AF, Popiolek D. Effects of gonadotropin-releasing hormone agonists on leiomyomas. Arch Pathol Lab Med. 1999 Apr;123(4):282-3. doi: 10.1043/1543-2165(1999)123<282b:EOGHAO>2.0.CO;2. PMID: 10320136. X-2

475. Minakuchi K, Kawamura N, Tsujimura A, et al. Remarkable and persistent shrinkage of uterine leiomyoma associated with interferon alfa treatment for hepatitis. Lancet. 1999 Jun 19;353(9170):2127-8. doi: 10.1016/s0140-6736(99)01648-7. PMID: 10382702. X-1, X-1g, X-3, X-3d

476. Miskry T, Magos A. Laparoscopic myomectomy. Semin Laparosc Surg. 1999 Jun;6(2):73-9. doi: 10.1053/slas00600073. PMID: 10459059. X-2

477. Nakayama H, Yano T, Sagara Y, et al. Estriol add-back therapy in the long-acting gonadotropin-releasing hormone agonist treatment of uterine leiomyomata. Gynecol Endocrinol. 1999 Dec;13(6):382-9. PMID: 10685331. X-6, X-7

478. Nikolov A, Karag'ozov I. [A comparative efficacy study of the preoperative use of GnRH agonists in women with uterine fibromyomas]. Akush Ginekol (Sofiia). 1999;38(4):38-42. PMID: 10726353. X-1, X-1e, X-6, X-7

479. Odnusi KO, Rutherford TJ, Olive DL, et al. Cryomyolysis in the management of uterine fibroids: technique and complications. Surg Technol Int. 1999;8:173-8. PMID: 12451527. X-1, X-1g, X-2

480. Orsini G, Pinto V, Di Biase S, et al. [The effects of menopausal replacement therapy in women with uterine myomas]. Minerva Ginecol. 1999 Nov;51(11):421-5. PMID: 10726441. X-1, X-1h, X-1i

481. Ortac F, Gungor M, Sonmezer M. Myomectomy during cesarean section. Int J Gynaecol Obstet. 1999 Dec;67(3):189-90. PMID: 10659906. X-3, X-3c, X-3d

482. Osborn K, Simmons S. Embolic occlusion for the treatment of uterine myomas. Aust N Z J Obstet Gynaecol. 1999 Nov;39(4):525. PMID: 10687787. X-2

483. Poncelet C, Benifla JL, Madelenat P. [Myoma and infertility]. J Gynecol Obstet Biol Reprod (Paris). 1999 Nov;28(7):761-7. PMID: 10624630. X-1, X-1f, X-11

484. Raders JL. Dispersive pad injuries associated with hysteroscopic surgery. J Am Assoc Gynecol Laparosc. 1999 Aug;6(3):363-7. PMID: 10610207. X-1, X-1g, X-3, X-5

485. Robson S, Wilson K, Munday D, et al. Pelvic sepsis complicating embolization of a uterine fibroid. Aust N Z J Obstet Gynaecol. 1999 Nov;39(4):516-7. PMID: 10687781. X-1, X-1g, X-3, X-3d

486. Schifano MJ, Hoshaw NJ, Boushka WM, et al. Uterine artery embolization in a hemorrhaging postoperative myomectomy patient. Obstet Gynecol Surv. 1999 Jan;54(1):1-3; discussion -4. PMID: 9891298. X-1, X-1g, X-3, X-3d

487. Scholz M. A new way to treat uterine fibroids. Rn. 1999 Nov;62(11):92. PMID: 10640138. X-2

488. Siskin GP, Eaton LA, Jr., Stainken BF, et al. Pathologic findings in a uterine leiomyoma after bilateral uterine artery embolization. J Vasc Interv Radiol. 1999 Jul-Aug;10(7):891-4. PMID: 10435706. X-1, X-1g, X-3

489. Smith SJ, Sewall LE, Handelsman A. A clinical failure of uterine fibroid embolization due to adenomyosis. J Vasc Interv Radiol. 1999 Oct;10(9):1171-4. PMID: 10527193. X-1, X-1g, X-3, X-3d

490. Spencer CP, Whitehead MI. Endometrial assessment re-visited. Br J Obstet Gynaecol. 1999 Jul;106(7):623-32. PMID: 10428515. X-2

491. Terras K, Koubaa A, Makhlouf T, et al. [Indications and results of abdominal hysterectomies (report of 250 cases)]. Tunis Med. 1999 Feb;77(2):87-94. PMID: 10333705. X-1, X-1h, X-3, X-3c

492. Thompson JC. Lessons from a life in surgery. I. Do you want the high figure or the low? Surgery. 1999 Mar;125(3):345-6. PMID: 10076621. X-2

493. Tomai E. Laparoscopic treatment of uterine myomas. Hawaii Med J. 1999 Jan;58(1):16-7. PMID: 10052269. X-2

494. Tulandi T, al-Took S. Endoscopic myomectomy. Laparoscopy and hysteroscopy. Obstet Gynecol Clin North Am. 1999 Mar;26(1):135-48, viii. PMID: 10083935. X-2

495. Vedantham S, Goodwin SC, McLucas B, et al. Uterine artery embolization for fibroids: considerations in patient selection and clinical follow-up. Medscape Womens Health. 1999 Oct;4(5):2. PMID: 10629068. X-2

496. Walker W, Worthington-Kirsch RL. Fatal septicaemia after fibroid embolisation. Lancet. 1999 Nov 13;354(9191):1730. doi: 10.1016/s0140-6736(05)76716-7. PMID: 10568597. X-2, X-3, X-3d

497. Weiss B. Death in the OR: trial by tabloid. Med Econ. 1999 Mar 22;76(6):212, 5-6. PMID: 10351087. X-2

498. Weng L. [Clinical application of mifepristone in obstetrics and gynecology]. Zhonghua Fu Chan Ke Za Zhi. 1999 May;34(5):261-4. PMID: 11326928. X-2

499. Worthington-Kirsch RL. Flow redistribution during uterine artery embolization for the management of symptomatic fibroids. J Vasc Interv Radiol. 1999 Feb;10(2 Pt 1):237-8. PMID: 10082113. X-2, X-3, X-3c

500. Worthington-Kirsch RL, Hutchins FL, Jr., Berkowitz RP. Regarding sloughing of fibroids after uterine artery embolization. J Vasc Interv Radiol. 1999 Sep;10(8):1135. PMID: 10496723. X-2, X-3, X-3c

501. . Procedure minimizes need for hysterectomies. Rep Med Guidel Outcomes Res. 2000 Aug 3;11(16):8-10. PMID: 11799996. X-2

502. . The future of women's health. Harv Womens Health Watch. 2000 Jan;7(5):4-6. PMID: 10594969. X-2

503. Benassi L, Lopopolo G, Pazzoni F, et al. Chemically assisted dissection of tissues: an interesting support in abdominal myomectomy. J Am Coll Surg. 2000 Jul;191(1):65-9. PMID: 10898185. X-3, X-3f, X-7

504. Cea-Calvo L, Lozano F, Pombo M, et al. Images in cardiovascular medicine. Uterine intravenous leiomyomatosis extending through the inferior vena cava into the right cardiac cavities. Circulation. 2000 Feb 8;101(5):581-3. PMID: 10662757. X-1, X-1g, X-1h, X-3, X-3d

505. Dessole S, Rubattu G, Capobianco G, et al. Utility of bipolar electrocautery scissors for abdominal hysterectomy. Am J Obstet Gynecol. 2000 Aug;183(2):396-9. doi: 10.1067/mob.2000.105911. PMID: 10942476. X-6, X-7

506. Dover RW, Torode HW, Briggs GM. Uterine artery embolisation for symptomatic fibroids. Med J Aust. 2000 Mar 6;172(5):233-6. PMID: 10776397. X-2

507. Dubuisson JB. Management of leiomyomata. Hum Reprod Update. 2000 Nov-Dec;6(6):587. PMID: 11129691. X-2

508. Gao Y, Chen D. [Clinical study on effect of Tripterygium wilfordii Hook. f. on uterin leiomyoma]. Zhonghua Fu Chan Ke Za Zhi. 2000 Jul;35(7):430-2. PMID: 11776193. X-3, X-3c, X-3f

509. Gedroyc WM. Interventional magnetic resonance imaging. BJU Int. 2000 Jul;86 Suppl 1:174-80. PMID: 10961287. X-2

510. Goodwin SC, Landow WJ, Matalon TA, et al. Opportunity and responsibility: SCVIR's role with uterine artery embolization. Society of Cardiovascular & Interventional Radiology. J Vasc Interv Radiol. 2000 Apr;11(4):409-10. PMID: 10787197. X-2

511. Kawamura K, Sekiguchi K, Shibata S, et al. Immunohistochemical analysis of adenomatoid tumor of the uterus utilizing of monoclonal antibody HBME-1. Acta Obstet Gynecol Scand. 2000 Sep;79(9):798-9. PMID: 10993108. X-1, X-1g, X-1i, X-3, X-3d

512. Lai AC, Goodwin SC, Bonilla SM, et al. Sexual dysfunction after uterine artery embolization. J Vasc Interv Radiol. 2000 Jun;11(6):755-8. PMID: 10877421. X-1, X-1g, X-3, X-3d

513. Ozcakir T, Tavmergen E, Goker EN, et al. CT scanning to diagnose incisional hernias after laparoscopy. J Am Assoc Gynecol Laparosc. 2000 Nov;7(4):595-7. PMID: 11189063. X-1, X-1c, X-2

514. Pelage J. [Uterine fibroid embolization: mature enough?]. J Radiol. 2000 May;81(5):483-4. PMID: 10804396. X-2

515. Pelage JP, Le Dref O, Jacob D, et al. Ovarian artery supply of uterine fibroid. J Vasc Interv Radiol. 2000 Apr;11(4):535. PMID: 10787217. X-1, X-1g, X-2

516. Pelage JP, Le Dref O, Jacob D, et al. [Uterine embolization]. J Radiol. 2000 Dec;81(12 Suppl):1873-4. PMID: 11173757. X-11

517. Petta CA, Aldrighi JM. [Which is the ideal myomectomy technique in infertility?]. Rev Assoc Med Bras. 2000 Oct-Dec;46(4):301-2. PMID: 11175555. X-2

518. Polatti F, Viazzo F, Colleoni R, et al. Uterine myoma in postmenopause: a comparison between two therapeutic schedules of HRT. Maturitas. 2000 Nov 30;37(1):27-32. PMID: 11099870. X-1, X-1h

519. Preutthipan S, Herabutya Y. Vaginal misoprostol for cervical priming before operative hysteroscopy: a randomized controlled trial. Obstet Gynecol. 2000 Dec;96(6):890-4. PMID: 11084173. X-5, X-6, X-7

520. Rajab KE, Aradi AN, Datta BN. Postmenopausal leimyomatosis peritonealis disseminata. Int J Gynaecol Obstet. 2000 Mar;68(3):271-2. PMID: 10699204. X-1, X-1g, X-3, X-3d

521. Robb-Nicholson C. By the way, doctor. I am 59 years old, in good health, and have been on HRT (estrogen and progesterone) for about 10 years. I have tried several different preparations, but despite this, have developed a uterine fibroid, experienced indigestion, gained 20 pounds, and had one abnormal mammogram (with, thankfully, a negative biopsy). Because there is heart disease in my family, my doctor wants me to stay on HRT for the rest of my life. Can you suggest any alternatives? Harv Womens Health Watch. 2000 Jan;7(5):8. PMID: 10594971. X-2

522. Shoupe D. Hysterectomy or an alternative? Hosp Pract (1995). 2000 Sep 15;35(9):55-62; quiz 92. PMID: 11004927. X-2

523. Siskin GP, Englander M, Stainken BF, et al. Embolic agents used for uterine fibroid embolization. AJR Am J Roentgenol. 2000 Sep;175(3):767-73. doi: 10.2214/ajr.175.3.1750767. PMID: 10954464. X-2

524. Stotz M, Lampart A, Kochli OR, et al. Intraabdominal bleeding masked by hemodilution after hysteroscopy. Anesthesiology. 2000 Aug;93(2):569-70. PMID: 10910510. X-1, X-1g, X-2

525. Tercanli S, Kochli OR, Hoesli I, et al. Differentiation and management of endometrium abnormalities and leiomyomas by hydrosonography. Contrib Gynecol Obstet. 2000;20:69-80. PMID: 11791287. X-1, X-1c

526. Verspyck E, Marpeau L, Lucas C. Leuprorelin depot 3.75 mg versus lynestrenol in the preoperative treatment of symptomatic uterine myomas: a multicentre randomised trial. Eur J Obstet Gynecol Reprod Biol. 2000 Mar;89(1):7-13. PMID: 10733017. X-1, X-1e, X-6, X-7

527. Wahab M, Thompson J, Al-Azzawi F. The effect of submucous fibroids on the dose-dependent modulation of uterine bleeding by trimegestone in postmenopausal women treated with hormone replacement therapy. Bjog. 2000 Mar;107(3):329-34. PMID: 10740328. X-1, X-1h

528. Willemsen WN, de Kruif JH, Velthausz MB, et al. [Fibroids and fertility]. Ned Tijdschr Geneeskd. 2000 Apr 22;144(17):789-91. PMID: 10800547. X-2

529. . Uterine artery embolization for leiomyomata. Clin Privil White Pap. 2001 Jul 19(63):1-7. PMID: 11715990. X-2

530. Ambekar A, Vogelzang RL. Aberrant uterine artery as a cause of uterine artery embolization treatment failure. Int J Gynaecol Obstet. 2001 Jul;74(1):59-60. PMID: 11430943. X-1, X-1g, X-3 X-3d

531. Armstrong C, Caird L. Fibroid embolisation: a technique not without significant complications. Bjog. 2001 Jan;108(1):132. PMID: 11212997. X-2, X-3, X-3c

532. Brannstrom M, Jones I, Lew W, et al. Ovarian lipoleiomyoma--a rare benign ovarian tumor with pre- and intra-operative features suggestive of malignancy. Acta Obstet Gynecol Scand. 2001 Sep;80(9):866-8. PMID: 11531640. X-1, X-1g, X-1h, X-1i, X-3, X-3d, X-5

533. Bravo JJ, Novoa D, Romero R, et al. [Hemolytic-uremic syndrome after myomectomy]. Nefrologia. 2001 Mar-Apr;21(2):217. PMID: 11464658. X-1, X-1g, X-3, X-3d

534. Bren L. Alternatives to hysterectomy. New technologies, more options. FDA Consum. 2001 Nov-Dec;35(6):23-8. PMID: 11785489. X-2

535. Burbank F. Pathologic features of uterine leiomyomas following uterine artery embolization. Int J Gynecol Pathol. 2001 Oct;20(4):407-9. PMID: 11603229. X-2

536. Chang A, Natarajan S. Polypoid endometriosis. Arch Pathol Lab Med. 2001 Sep;125(9):1257. doi: 10.1043/0003-9985(2001)125<1257:pe>2.0.co;2. PMID: 11520289. X-1, X-1g, X-1h, X-3, X-3d

537. Chavez NF, Stewart EA. Medical treatment of uterine fibroids. Clin Obstet Gynecol. 2001 Jun;44(2):372-84. PMID: 11347559. X-2

538. Christman GM, McCarthy JD. Gene therapy and uterine leiomyomas. Clin Obstet Gynecol. 2001 Jun;44(2):425-35. PMID: 11345003. X-1, X-1b, X-2

539. Cohen J. [Fibroma: surgical myomectomy or embolization or GnRH analogs? Intramural and sub-serous fibroma: start with medical treatment!]. Gynecol Obstet Fertil. 2001 Jan;29(1):64-6. PMID: 11217196. X-2

540. Cyr E. Uterine fibroid embolization. Radiol Technol. 2001 Sep-Oct;73(1):69-70. PMID: 11579772. X-2

541. Darai E, Soriano D, Kimata P, et al. Vaginal hysterectomy for enlarged uteri, with or without laparoscopic assistance: randomized study. Obstet Gynecol. 2001 May;97(5 Pt 1):712-6. PMID: 11339921. X-5, X-7

542. De Leo V, la Marca A, Morgante G, et al. Administration of somatostatin analogue reduces uterine and myoma volume in women with uterine leiomyomata. Fertil Steril. 2001 Mar;75(3):632-3. PMID: 11239556. X-3, X-3c

543. Demello AB. Uterine artery embolization. Aorn j. 2001 Apr;73(4):790-2, 4-8, 800-4 passim; quiz 9-14. PMID: 11303469. X-2, X-3, X-3d

544. Devireddy RV, Coad JE, Bischof JC. Microscopic and calorimetric assessment of freezing processes in uterine fibroid tumor tissue. Cryobiology. 2001 Jun;42(4):225-43. doi: 10.1006/cryo.2001.2327. PMID: 11748932. X-1, X-1a, X-1h, X-2

545. Dubuisson JB, Chapron C, Fauconnier A, et al. Laparoscopic myomectomy fertility results. Ann N Y Acad Sci. 2001 Sep;943:269-75. PMID: 11594546. X-1, X-3, X-3c, X-3f

546. Dubuisson JB, Chapron C, Fauconnier A, et al. [Fibroma: surgical myomectomy or embolization or GnRH analogs? Does myomectomy by laparoscopy have a justifiable place in the therapeutic strategy today?]. Gynecol Obstet Fertil. 2001 Jan;29(1):67-72. PMID: 11217198. X-2, X-11

547. Edens MS, Heath AM. Theriogenology question of the month. Histologic examination of tissue sections of the mass. J Am Vet Med Assoc. 2001 Dec 15;219(12):1683-5. PMID: 11767917. X-1, X-1h, X-1i, X-2

548. Farquhar C, Arroll B, Ekeroma A, et al. An evidence-based guideline for the management of uterine fibroids. Aust N Z J Obstet Gynaecol. 2001 May;41(2):125-40. PMID: 11453261. X-2

549. Goodwin SC, Bonilla SM, Sacks D, et al. Reporting standards for uterine artery embolization for the treatment of uterine leiomyomata. J Vasc Interv Radiol. 2001 Sep;12(9):1011-20. PMID: 11535763. X-2

550. Goodwin SC, Wong GC. Uterine artery embolization for uterine fibroids: a radiologist's perspective. Clin Obstet Gynecol. 2001 Jun;44(2):412-24. PMID: 11345002. X-2

551. Hodges LC, Hunter DS, Bergerson JS, et al. An in vivo/in vitro model to assess endocrine disrupting activity of xenoestrogens in uterine leiomyoma. Ann N Y Acad Sci. 2001 Dec;948:100-11. PMID: 11795388. X-1, X-1a, X-1h

552. Jasonni VM, D'Anna R, Mancuso A, et al. Randomized double-blind study evaluating the efficacy on uterine fibroids shrinkage and on intra-operative blood loss of different length of leuprolide acetate depot treatment before myomectomy. Acta Obstet Gynecol Scand. 2001 Oct;80(10):956-8. PMID: 11580742. X-1, X-1e, X-7

553. Justesen P, Lund N, Andersen PE, et al. [Endovascular treatment of uterine fibromas]. Ugeskr Laeger. 2001 Aug 13;163(33):4371-4. PMID: 11521572. X-2, X-3, X-3c

554. Lee WL, Liu RS, Yuan CC, et al. Relationship between gonadotropin-releasing hormone agonist and myoma cellular activity: preliminary findings on positron emission tomography. Fertil Steril. 2001 Mar;75(3):638-9. PMID: 11239559. X-1, X-1a, X-1e, X-1g, X-3, X-3c

555. Marcu S, Leron E, Mazor M. [Uterine artery embolisation for symptomatic leiomyomata uteri--a new treatment method]. Harefuah. 2001 Feb;140(2):153-7. PMID: 11242923. X-2, X-11

556. Matchar DB, Myers ER, Barber MW, et al. Management of uterine fibroids. Evid Rep Technol Assess (Summ). 2001 Jan(34):1-6. PMID: 11236283. X-2

557. McLucas B, Adler L. Uterine fibroid embolization compared with myomectomy. Int J Gynaecol Obstet. 2001 Sep;74(3):297-9. PMID: 11543757. X-3, X-3a

558. Milad MP, Sankpal RS. Laparoscopic approaches to uterine leiomyomas. Clin Obstet Gynecol. 2001 Jun;44(2):401-11. PMID: 11345001. X-2

559. Misra R, Grundsell H. The Ellik evacuator. A reinvention. Surg Endosc. 2001 Mar;15(3):329. doi: 10.1007/s004640080145. PMID: 11344445. X-2

560. Molnar BG. Combining myoma coagulation with endometrial ablation/resection reduces subsequent surgery rates. Jsls. 2001 Jan-Mar;5(1):97-8. PMID: 11304006. X-2, X-3, X-3c

561. Moorehead ME, Conard CJ. Uterine leiomyoma: a treatable condition. Ann N Y Acad Sci. 2001 Dec;948:121-9. PMID: 11795390. X-2

562. Munro MG. Abnormal uterine bleeding: surgical management--part III. J Am Assoc Gynecol Laparosc. 2001 Feb;8(1):18-44, test 5-7. PMID: 11274617. X-2

563. Okin CR, Guido RS, Meyn LA, et al. Vasopressin during abdominal hysterectomy: a randomized controlled trial. Obstet Gynecol. 2001 Jun;97(6):867-72. PMID: 11384687. X-5, X-7

564. Oktem O, Gokaslan H, Durmusoglu F. Spontaneous uterine rupture in pregnancy 8 years after laparoscopic myomectomy. J Am Assoc Gynecol Laparosc. 2001 Nov;8(4):618-21. PMID: 11677352. X-1, X-1g, X-3, X-3d

565. Palomba S, Pellicano M, Affinito P, et al. Effectiveness of short-term administration of tibolone plus gonadotropin-releasing hormone analogue on the surgical outcome of laparoscopic myomectomy. Fertil Steril. 2001 Feb;75(2):429-33. PMID: 11172852. X-6, X-7

566. Pelage JP, Walker WJ, Le Dref O, et al. Treatment of uterine fibroids. Lancet. 2001 May 12;357(9267):1530. doi: 10.1016/s0140-6736(00)04683-3. PMID: 11383541. X-2

567. Puzigaca Z, Prelevic G, Markovic A. [Treatment of leiomyomas with gonadoliberin agonists]. Srp Arh Celok Lek. 2001 May-Jun;129(5-6):143-6. PMID: 11797463. X-11

568. Rachev E. [Embolism of the uterine artery - is this the end for the operative treatment of leiomyomas?]. Akush Ginekol (Sofiia). 2001;40(4):28-32. PMID: 11803866. X-2

569. Ravina JH. [Fibroma: surgical myomectomy or embolization or GnRH analogs? Embolization of uterine fibroma: a new treatment]. Gynecol Obstet Fertil. 2001 Jan;29(1):66-7. PMID: 11217197. X-2

570. Rosenthal AN. Fibroid embolisation: a technique not without significant complications. Bjog. 2001 Mar;108(3):337. PMID: 11281481. X-1, X-2, X-3

571. Seidman DS, Nezhat CH, Nezhat F, et al. The role of laparoscopic-assisted myomectomy (LAM). Jsls. 2001 Oct-Dec;5(4):299-303. PMID: 11719974. X-2

572. Shlansky-Goldberg R, Cope C. A new twist on the Waltman loop for uterine fibroid embolization. J Vasc Interv Radiol. 2001 Aug;12(8):997-1000. PMID: 11487683. X-1, X-1h, X-2, X-3, X-3f

573. Somekawa Y, Chiguchi M, Ishibashi T, et al. Efficacy of ipriflavone in preventing adverse effects of leuprolide. J Clin Endocrinol Metab. 2001 Jul;86(7):3202-6. doi: 10.1210/jcem.86.7.7673. PMID: 11443189. X-1, X-6, X-7

574. Tulandi T, Sammour A, Valenti D, et al. Images in endoscopy: uterine artery embolization and utero-ovarian collateral. J Am Assoc Gynecol Laparosc. 2001 Nov;8(4):474. PMID: 11677322. X-1, X-1g, X-3, X-3d

575. Uchikova E, Malinova M, Dikov D. [Lipoleiomyoma of the uterus]. Akush Ginekol (Sofiia). 2001;41 Suppl 4:7-8. PMID: 11519322. X-1, X-1g, X-1h, X-1i

576. van de Ven J, Sprong M, Donker GH, et al. Levels of estrogen and progesterone receptors in the myometrium and leiomyoma tissue after suppression of estrogens with gonadotropin releasing hormone analogs. Gynecol Endocrinol. 2001 Dec;15 Suppl 6:61-8. PMID: 12227888. X-1, X-1d, X-1e, X-6, X-7

577. Vashisht A, Smith JR, Thorpe-Beeston G, et al. Pregnancy subsequent to uterine artery embolization. Fertil Steril. 2001 Jun;75(6):1246-8. PMID: 11388348. X-1, X-1g, X-2, X-3, X-3d

578. Wang PH, Lee WL, Yuan CC, et al. Major complications of operative and diagnostic laparoscopy for gynecologic disease. J Am Assoc Gynecol Laparosc. 2001 Feb;8(1):68-73. PMID: 11172117. X-1, X-3, X-3a, X-5

579. Worthington-Kirsch R, Fueredi G, Goodwin S, et al. Polyvinyl alcohol particle size for uterine artery embolization. Radiology. 2001 Feb;218(2):605-6. doi: 10.1148/radiology.218.2.r01fe02605. PMID: 11161189. X-2

580. Worthington-Kirsch RL, Hutchins FL, Jr. Retained myoma fragment after LASH procedure. Clin Radiol. 2001 Sep;56(9):777-8. doi: 10.1053/crad.1999.0288. PMID: 11585402. X-1, X-1g, X-3, X-3d

581. Yano T, Taketani Y. [GnRH antagonist]. Nihon Rinsho. 2001 Jan;59 Suppl 1:133-8. PMID: 11235152. X-11

582. . Uterine artery embolization for treatment of symptomatic uterine fibroids. TEC Bull (Online). 2002 Jul 8;19(2):37-9. PMID: 12166477. X-1, X-2

583. Bricault I, Ayoubi JM. Is 3-D ultrasound-based virtual hysteroscopy feasible? J Obstet Gynaecol. 2002 Jul;22(4):438-9. doi: 10.1080/01443610220141470. PMID: 12521475. X-1, X-1c, X-1g, X-3

584. Chez RA. Etiology and treatment of uterine fibroids. Altern Ther Health Med. 2002 Mar-Apr;8(2):32-3. PMID: 11890383. X-2

585. Cobellis L, Pecori E, Cobellis G. Hemostatic technique for myomectomy during cesarean section. Int J Gynaecol Obstet. 2002 Dec;79(3):261-2. PMID: 12445997. X-2, X-3, X-3c

586. De Iaco PA, Muzzupapa G, Golfieri R, et al. A uterine wall defect after uterine artery embolization for symptomatic myomas. Fertil Steril. 2002 Jan;77(1):176-8. PMID: 11779611. X-1, X-1g, X-3, X-3d

587. Englander MJ, Siskin GP, Dowling K, et al. Uterine fibroid embolization without the use of iodinated contrast material. J Vasc Interv Radiol. 2002 Apr;13(4):427-9. PMID: 11932377. X-1, X-1g, X-2

588. Farquhar C. Re: New Zealand evidence-based guidelines for management of uterine fibroids. Aust N Z J Obstet Gynaecol. 2002 Aug;42(3):316-7. PMID: 12230077. X-1, X-2, X-3

589. Gocmen A, Kara IH, Karaca M. The effects of add-back therapy with tibolone on myoma uteri. Clin Exp Obstet Gynecol. 2002;29(3):222-4. PMID: 12519049. X-1, X-1e, X-6, X-7

590. Inki P, Hurskainen R, Palo P, et al. Comparison of ovarian cyst formation in women using the levonorgestrel-releasing intrauterine system vs. hysterectomy. Ultrasound Obstet Gynecol. 2002 Oct;20(4):381-5. doi: 10.1046/j.1469-0705.2002.00805.x. PMID: 12383322. X-5, X-6, X-7

591. Itkin M, Shlansky-Goldberg R. Uterine fibroid embolization for the treatment of symptomatic leiomyomata. Applied Radiology. 2002 01 Oct;31(10):9-17. PMID: 2002393019. X-2, X-3, X-3f

592. Kadowaki M, Murakami T, Morita J, et al. Prediction of the effects of gonadotropin-releasing hormone agonist therapy in uterine leiomyoma by T1 contrast-enhanced magnetic resonance imaging sequences. Fertil Steril. 2002 May;77(5):1081-2. PMID: 12009376. X-3, X-3c, X-3f

593. Karuppaswamy J, Tapp A. Leiomyomatosis peritonealis disseminata-is a different approach needed? J Obstet Gynaecol. 2002 Jul;22(4):446-7. doi: 10.1080/01443610220141498. PMID: 12521481. X-1, X-1g, X-3

594. Kriplani A, Agarwal N, Parul D, et al. Prolapsed leiomyoma with severe haemorrhage after GnRH analogue therapy. J Obstet Gynaecol. 2002 Jul;22(4):449-51. doi: 10.1080/014436102320261221. PMID: 12521484. X-1, X-1g, X-3, X-3d

595. Kwawukume EY. Myomectomy during cesarean section. Int J Gynaecol Obstet. 2002 Feb;76(2):183-4. PMID: 11818118. X-2, X-3, X-3e

596. Lethaby A, Vollenhoven B. Fibroids (uterine myomatosis, leiomyomas). Clin Evid. 2002 Jun(7):1666-78. PMID: 12230780. X-2

597. McLucas B, Sostrin S. Uterine necrosis after uterine artery embolization for leiomyoma. Obstet Gynecol. 2002 Dec;100(6):1357-8. PMID: 12468189. X-1, X-1g, X-2

598. Nawroth F, Foth D. IVF outcome and intramural fibroids not compressing the uterine cavity. Hum Reprod. 2002 Sep;17(9):2485; discusson -6. PMID: 12202450. X-1, X-2

599. Nikolov A, Kolarov G. [Adjuvant therapy during the administration of GnRH agonists]. Akush Ginekol (Sofiia). 2002;41(2):36-40. PMID: 12066551. X-2, X-11

600. Ozumba B, Ezegwui H. Intrauterine adhesions in an African population. Int J Gynaecol Obstet. 2002 Apr;77(1):37-8. PMID: 11929656. X-1, X-1h, X-3, X-3f

601. Palomba S, Morelli M, Noia R, et al. Short-term administration of tibolone plus GnRH analog before laparoscopic myomectomy. J Am Assoc Gynecol Laparosc. 2002 May;9(2):170-4. PMID: 11960042. X-1, X-1e, X-6, X-7

602. Palomba S, Orio F, Jr., Morelli M, et al. Raloxifene administration in women treated with gonadotropin-releasing hormone agonist for uterine leiomyomas: effects on bone metabolism. J Clin Endocrinol Metab. 2002 Oct;87(10):4476-81. doi: 10.1210/jc.2002-020780. PMID: 12364422. X-6, X-7

603. Palomba S, Sena T, Morelli M, et al. Effect of different doses of progestin on uterine leiomyomas in postmenopausal women. Eur J Obstet Gynecol Reprod Biol. 2002 May 10;102(2):199-201. PMID: 11950491. X-1, X-1h

604. Pelage JP, Walker WJ, Dref OL. Uterine necrosis after uterine artery embolization for leiomyoma. Obstet Gynecol. 2002 Apr;99(4):676-7; author reply 7. PMID: 12039135. X-2

605. Pelage JP, Walker WJ, Le Dref O. Re: utility of nonselective abdominal aortography in demonstrating ovarian artery collaterals in patients undergoing uterine artery embolization for fibroids. J Vasc Interv Radiol. 2002 Jun;13(6):656. PMID: 12090245. X-1, X-2, X-3, X-3c

606. Petrovic Z. [Sonographically guided vascular sclerosation: new method of myoma treatment]. Glas Srp Akad Nauka Med. 2002(47):169-79. PMID: 16078450. X-3, X-3a, X-3f

607. Ryan JM, Gainey M, Glasson J, et al. Simplified pain-control protocol after uterine artery embolization. Radiology. 2002 Aug;224(2):610-1; discussion 1-3. doi: 10.1148/radiol.2242011954. PMID: 12147865. X-1, X-2

608. Sasadeusz KJ, Andrews RT. Uterine fibroid embolization. Semin Roentgenol. 2002 Oct;37(4):361-70. PMID: 12455133. X-2

609. Schlotzer-Schrehardt U, Junemann A, Naumann GO. Mitochondria-rich epithelioid leiomyoma of the ciliary body. Arch Ophthalmol. 2002 Jan;120(1):77-82. PMID: 11786062. X-1, X-1i

610. Tulandi T, Sammour A, Valenti D, et al. Ovarian reserve after uterine artery embolization for leiomyomata. Fertil Steril. 2002 Jul;78(1):197-8. PMID: 12095516. X-2, X-3, X-3c

611. van de Ven J, Donker TH, Blankenstein MA, et al. Differential effect of gonadotropin-releasing hormone analogue treatment on estrogen levels and sulfatase activity in uterine leiomyoma and myometrium. Fertil Steril. 2002 Jun;77(6):1227-32. PMID: 12057733. X-3, X-3f, X-6, X-7

612. Yang CH, Lee JN, Hsu SC, et al. Effect of hormone replacement therapy on uterine fibroids in postmenopausal women--a 3-year study. Maturitas. 2002 Sep 30;43(1):35-9. PMID: 12270580. X-1, X-3, X-3e

613. . Patient page. Uterine fibroid embolization. Radiol Technol. 2003 Nov-Dec;75(2):176. PMID: 14671837. X-2

614. . [Endometriosis and diferelin]. Akush Ginekol (Sofiia). 2003;42 Suppl 1:27-8. PMID: 12899124. X-1, X-1i, X-2

615. Andrews RT, Binkert CA. Digital subtraction fluoroscopy to enhance visualization during uterine fibroid embolization. Cardiovasc Intervent Radiol. 2003 May-Jun;26(3):296-7. doi: 10.1007/s00270-003-0004-2. PMID: 14562982. X-2

616. Cagnacci A, Pirillo D, Malmusi S, et al. Early outcome of myomectomy by laparotomy, minilaparotomy and laparoscopically assisted minilaparotomy. A randomized prospective study. Hum Reprod. 2003 Dec;18(12):2590-4. PMID: 14645175. X-6, X-7

617. Carr BR, Breslau NA, Peng N, et al. Effect of gonadotropin-releasing hormone agonist and medroxyprogesterone acetate on calcium metabolism: a prospective, randomized, double-blind, placebo-controlled, crossover trial. Fertil Steril. 2003 Nov;80(5):1216-23. PMID: 14607578. X-1, X-1h, X-5, X-6, X-7

618. Celik H, Ayar A, Kilic N. Effects of goserelin administration before myomectomy on plasma homocysteine levels in patients with symptomatic uterine leiomyomata. Fertil Steril. 2003 Oct;80(4):1060-1. PMID: 14556836. X-2, X-3, X-6, X-7

619. Celik H, Sapmaz E. Use of a single preoperative dose of misoprostol is efficacious for patients who undergo abdominal myomectomy. Fertil Steril. 2003 May;79(5):1207-10. PMID: 12738519. X-1, X-1e, X-7

620. Celik H, Sapmaz E, Serhatlioglu S, et al. Effect of intravaginal misoprostol use on uterine artery blood flow in patients with myoma uteri. Fertil Steril. 2003 Dec;80(6):1526-8. PMID: 14667899. X-2, X-6, X-7

621. Chen CL. [Current situation and development of transcatheter technique in obstetrics and gynecology]. Zhonghua Fu Chan Ke Za Zhi. 2003 Aug;38(8):506-9. PMID: 14627044. X-2

622. D'Angelo A, Amso NN, Wood A. Uterine leiomyosarcoma discovered after uterine artery embolisation. J Obstet Gynaecol. 2003 Nov;23(6):686-7. doi: 10.1080/01443610310001609597. PMID: 14617492. X-1, X-1g, X-3

623. Donnez J, Hervais Vivancos B, Kudela M, et al. A randomized, placebo-controlled, dose-ranging trial comparing fulvestrant with goserelin in premenopausal patients with uterine fibroids awaiting hysterectomy. Fertil Steril. 2003 Jun;79(6):1380-9. PMID: 12798886. X-6, X-7

624. Dousias V, Paraskevaidis E, Dalkalitsis N, et al. Recombinant human erythropoietin in mildly anemic women before total hysterectomy. Clin Exp Obstet Gynecol. 2003;30(4):235-8. PMID: 14664421. X-6, X-7

625. Ehigiegba AE, Ande AB, Ojobo SI. Caesarean myomectomy: new frontier in surgical practice. Afr J Reprod Health. 2003 Apr;7(1):125. PMID: 12816320. X-2

626. Goodwin SC, Bonilla SC, Sacks D, et al. Reporting standards for uterine artery embolization for the treatment of uterine leiomyomata. J Vasc Interv Radiol. 2003 Sep;14(9 Pt 2):S467-76. PMID: 14514862. X-2

627. Hart R. Unexplained infertility, endometriosis, and fibroids. Bmj. 2003 Sep 27;327(7417):721-4. doi: 10.1136/bmj.327.7417.721. PMID: 14512481. X-2

628. Hindley JT, Gedroyc WM, Regan L. Interstitial laser coagulation for uterine myomas. Am J Obstet Gynecol. 2003 Mar;188(3):859; author reply 60. PMID: 12634679. X-2

629. Huang SC, Tang MJ, Cheng YM, et al. Enhanced polyadenosine diphosphate-ribosylation in gonadotropin-releasing hormone agonist-treated uterine leiomyoma. J Clin Endocrinol Metab. 2003 Oct;88(10):5009-16. doi: 10.1210/jc.2003-030175. PMID: 14557488. X-1, X-1a, X-3, X-3f

630. Jeong YY, Kang HK, Park JG, et al. CT features of uterine torsion. Eur Radiol. 2003 Dec;13 Suppl 4:L249-50. PMID: 15018200. X-1, X-1g, X-2

631. Kobayashi TK, Moritani S, Katsumori T, et al. Cytologic features of vaginal discharge obtained after uterine artery embolization for uterine leiomyomata. Acta Cytol. 2003 Mar-Apr;47(2):309-11. PMID: 12685206. X-1, X-1d, X-h, X-3, X-3f

632. Krumov G, Milchev N, Paskaleva V, et al. [Perioperative prophylaxis with ciphin in gynecological practice]. Akush Ginekol (Sofiia). 2003;42 Suppl 1:10-2. PMID: 12858495. X-1, X-1h, X-1i

633. La Marca A, Musacchio MC, Morgante G, et al. Hemodynamic effect of danazol therapy in women with uterine leiomyomata. Fertil Steril. 2003 May;79(5):1240-2. PMID: 12738528. X-2, X-3, X-3c

634. Learman LA, Summitt RL, Jr., Varner RE, et al. A randomized comparison of total or supracervical hysterectomy: surgical complications and clinical outcomes. Obstet Gynecol. 2003 Sep;102(3):453-62. PMID: 12962924. X-5

635. Lethaby A, Vollenhoven B. Fibroids (uterine myomatosis, leiomyomas). Clin Evid. 2003 Jun(9):2028-43. PMID: 15366172. X-2

636. Maltau JM, Kumar S, Singh K, et al. [Percutaneous embolization of uterine arteries in uterine myoma]. Tidsskr Nor Laegeforen. 2003 Mar 6;123(5):614-6. PMID: 12683185. X-11

637. Manyonda IT, Sinthamoney E, Lotfallah H, et al. Uterine artery embolisation for symptomatic fibroids: clinical results in 400 women with imaging follow up. Bjog. 2003 Dec;110(12):1139. PMID: 14664893. X-2, X-3, X-3c

638. McLucas B, Adler L, Reidy J. Fibroid embolization--not without problems. Fertil Steril. 2003 Jul;80(1):233-4; author reply 4. PMID: 12849842. X-2

639. Mettler L, Audebert A, Lehmann-Willenbrock E, et al. New adhesion prevention concept in gynecological surgery. Jsls. 2003 Jul-Sep;7(3):207-9. PMID: 14558707. X-1, X-3, X-6, X-7

640. Mettler L, Audebert A, Lehmann-Willenbrock E, et al. Prospective clinical trial of SprayGel as a barrier to adhesion formation: an interim analysis. J Am Assoc Gynecol Laparosc. 2003 Aug;10(3):339-44. PMID: 14567808. X-6, X-7

641. Mulik V, Griffiths AN, Beattie RB. Desmoid tumours with familial adenomatous polyposis in pregnancy. J Obstet Gynaecol. 2003 May;23(3):307-8. PMID: 12850869. X-1, X-1h, X-1i, X-3, X-3d, X-5

642. Pelage JP. [Arterial embolisation, a welcome alternative to the surgical management of uterine fibromas]. Presse Med. 2003 Nov 22;32(37 Pt 1):1731-2. PMID: 14663386. X-2

643. Pellicano M, Bramante S, Cirillo D, et al. Effectiveness of autocrosslinked hyaluronic acid gel after laparoscopic myomectomy in infertile patients: a prospective, randomized, controlled study. Fertil Steril. 2003 Aug;80(2):441-4. PMID: 12909511. X-6, X-7

644. Peyton-Jones B, Fiadjoe P, Fox R. Massive uterine leiomyomas and successful pregnancy. J Obstet Gynaecol. 2003 Sep;23(5):569-70. doi: 10.1080/0144361031000156591. PMID: 12963528. X-1, X-1g, X-3, X-3d

645. Ribeiro SC, Ribeiro RM, Santos NC, et al. A randomized study of total abdominal, vaginal and laparoscopic hysterectomy. Int J Gynaecol Obstet. 2003 Oct;83(1):37-43. PMID: 14511870. X-5, X-7

646. Sapmaz E, Celik H, Altungul A. Bilateral ascending uterine artery ligation vs. tourniquet use for hemostasis in cesarean myomectomy. A comparison. J Reprod Med. 2003 Dec;48(12):950-4. PMID: 14738022. X-1h, X-5

647. Savelli L, Pilu G, Valeri B, et al. Transvaginal sonographic appearance of anaerobic endometritis. Ultrasound Obstet Gynecol. 2003 Jun;21(6):624-5. doi: 10.1002/uog.107. PMID: 12808686. X-1, X-1c, X-1g, X-1i, X-3, X-3d

648. Seki H, Takizawa Y, Sodemoto T. Epidural analgesia for painful myomas refractory to medical therapy during pregnancy. Int J Gynaecol Obstet. 2003 Dec;83(3):303-4. PMID: 14643043. X-1, X-1g, X-3, X-3d

649. Seracchioli R, Venturoli S, Colombo FM, et al. GnRH agonist treatment before total laparoscopic hysterectomy for large uteri. J Am Assoc Gynecol Laparosc. 2003 Aug;10(3):316-9. PMID: 14567804. X-1, X-1e, X-7

650. Spies JB. Recovery after uterine artery embolization: understanding and managing short-term outcomes. J Vasc Interv Radiol. 2003 Oct;14(10):1219-22. PMID: 14551266. X-2

651. Spies JB. Uterine artery embolization for fibroids: understanding the technical causes of failure. J Vasc Interv Radiol. 2003 Jan;14(1):11-4. PMID: 12525581. X-2

652. Stambolov B, Zheliazkov E. [Leiomyoma and pregnancy]. Akush Ginekol (Sofiia). 2003;42 Suppl 1:22-3. PMID: 12858500. X-2, X-3, X-3d

653. Sun Y, Tawfiqul B, Valderrama E, et al. Pulmonary crystal-storing histiocytosis and extranodal marginal zone B-cell lymphoma associated with a fibroleiomyomatous hamartoma. Ann Diagn Pathol. 2003 Feb;7(1):47-53. doi: 10.1053/adpa.2003.50008. PMID: 12616474. X-1, X-1g, X-1i, X-2, X-3

654. Tsai EM, Chen HS, Long CY, et al. Laparoscopically assisted vaginal hysterectomy versus total abdominal hysterectomy: a study of 100 cases on light-endorsed transvaginal section. Gynecol Obstet Invest. 2003;55(2):105-9. doi: 70182. PMID: 12771457. X-5, X-6

655. Vercellini P, Trespidi L, Zaina B, et al. Gonadotropin-releasing hormone agonist treatment before abdominal myomectomy: a controlled trial. Fertil Steril. 2003 Jun;79(6):1390-5. PMID: 12798887. X-7

656. Wang ZB. [Clinical application of high-intensity foused ultrasound in obstetrics and gynecology]. Zhonghua Fu Chan Ke Za Zhi. 2003 Aug;38(8):510-2. PMID: 14627045. X-2, X-11

657. Xia EL. [Development and clinical practice of gynecologic endoscopy]. Zhonghua Fu Chan Ke Za Zhi. 2003 Aug;38(8):502-5. PMID: 14627043. X-2

658. . Ultrasound treatment zaps fibroids. Health News. 2004 Aug;10(8):2. PMID: 15551451. X-2

659. . Myomas and reproductive function. Fertil Steril. 2004 Sep;82 Suppl 1:S111-6. doi: 10.1016/j.fertnstert.2004.05.061. PMID: 15363705. X-2

660. Andreu AL, Chiner E, Gomez Merino E, et al. [Pleural effusion as a manifestation of ovarian hyperstimulation syndrome, after treatment with triptoreline for uterus myomata]. An Med Interna. 2004 Jun;21(6):308-9. PMID: 15283650. X-1, X-1g, X-1i

661. Andrews RT, Spies JB, Sacks D, et al. Patient care and uterine artery embolization for leiomyomata. J Vasc Interv Radiol. 2004 Feb;15(2 Pt 1):115-20. PMID: 14963177. X-2

662. Baltzer J. [Myoma: many women have unnecessary surgery -- finally new methods come to Germany, too]. Kinderkrankenschwester. 2004 Oct;23(10):395. PMID: 15551814. X-2

663. Basile A, Lupattelli T. Embolization of uterine arteries with type IA utero-ovarian anastomoses. Radiology. 2004 Jun;231(3):923; author reply -4. doi: 10.1148/radiol.2313031914. PMID: 15163828. X-2

664. Bozzini N, Messina ML, Borsari R, et al. Comparative study of different dosages of goserelin in size reduction of myomatous uteri. J Am Assoc Gynecol Laparosc. 2004 Nov;11(4):462-3. PMID: 15701186. X-1, X-1e, X-6, X-7

665. Browne RF, McCann J, Johnston C, et al. Emergency selective arterial embolization for control of life-threatening hemorrhage from uterine fibroids. AJR Am J Roentgenol. 2004 Oct;183(4):1025-8. doi: 10.2214/ajr.183.4.1831025. PMID: 15385297. X-3, X-3c, X-3d

666. Chan LY. The use of vaginal misoprostol before myomectomy. Fertil Steril. 2004 Apr;81(4):1160; author reply -1. doi: 10.1016/j.fertnstert.2004.01.010. PMID: 15066492. X-2

667. Decenzo JA. Iatrogenic endometriosis caused by uterine morcellation during a supracervical hysterectomy. Obstet Gynecol. 2004 Mar;103(3):583; author reply -4. PMID: 15024758. X-2

668. Fernandez H. [Embolization of uterine fibromas: results of 454 cases. Gynecol Obstet Fertil 2003 ; 31: 597-605]. Gynecol Obstet Fertil. 2004 Jan;32(1):96-7; author reply 8-9. PMID: 14736608. X-3, X-3c

669. Fugh-Berman A, Balick MJ, Kronenberg F, et al. Treatment of fibroids: the use of beets (Beta vulgaris) and molasses (Saccharum officinarum) as an herbal therapy by Dominican healers in New York City. J Ethnopharmacol. 2004 Jun;92(2-3):337-9. doi: 10.1016/j.jep.2004.03.009. PMID: 15138021. X-2

670. Gabriel H, Pinto CM, Kumar M, et al. MRI detection of uterine necrosis after uterine artery embolization for fibroids. AJR Am J Roentgenol. 2004 Sep;183(3):733-6. doi: 10.2214/ajr.183.3.1830733. PMID: 15333363. X-1, X-1g, X-3, X-3d

671. Gilles JM, Jacques E, Diro M, et al. A real difference or creative summary measures? Fertil Steril. 2004 Apr;81(4):1159-60; author reply 60-1. doi: 10.1016/j.fertnstert.2004.01.009. PMID: 15066491. X-2

672. Gulati MS, Srinivasan A, Paul SB, et al. Uterine restoration following fibroid expulsion after uterine artery embolisation using gelfoam. J Postgrad Med. 2004 Jan-Mar;50(1):80. PMID: 15048010. X-1, X-1g, X-2

673. Hascalik S, Celik O, Sarac K, et al. Transient ovarian failure: a rare complication of uterine fibroid embolization. Acta Obstet Gynecol Scand. 2004 Jul;83(7):682-5. doi: 10.1111/j.0001-6349.2004.0226a.x. PMID: 15225195. X-1, X-1g, X-3

674. Hovsepian DM, Siskin GP, Bonn J, et al. Quality improvement guidelines for uterine artery embolization for symptomatic leiomyomata. J Vasc Interv Radiol. 2004 Jun;15(6):535-41. PMID: 15178712. X-2

675. Huang FY, Fang XL, Lin QH, et al. [Clinical analysis of laproscopic classic intrafascial Semm hysterectomy in 86 patients]. Zhong Nan Da Xue Xue Bao Yi Xue Ban. 2004 Jun;29(3):355-6. PMID: 16136982. X-3, X-3c

676. Iacobellis G, Iacobellis G. Combined treatment with tranexamic acid and oral contraceptive pill causes coronary ulcerated plaque and acute myocardial infarction. Cardiovasc Drugs Ther. 2004 May;18(3):239-40. doi: 10.1023/B:CARD.0000033646.21346.e4. PMID: 15229393. X-1, X-1g, X-3, X-3d

677. Jain P, Pradhan P, Cietak KA, et al. Acute abdomen following spontaneous variceal rupture overlying uterine leiomyoma. J Obstet Gynaecol. 2004 Aug;24(5):589. doi: 10.1080/01443610410001722833. PMID: 15369956. X-1, X-1g, X-3, X-3d

678. Johnson N, Fletcher H, Reid M. Depo medroxyprogesterone acetate (DMPA) therapy for uterine myomata prior to surgery. Int J Gynaecol Obstet. 2004 May;85(2):174-6. doi: 10.1016/j.ijgo.2003.09.010. PMID: 15099785. X-2, X-6, X-7

679. Karila-Cohen P, Petit T, Kotobi H, et al. [Pedunculated uterine leiomyoma]. J Radiol. 2004 Jun;85(6 Pt 1):741-5. PMID: 15243374. X-1, X-1g

680. Lethaby A, Vollenhoven B. Fibroids (uterine myomatosis, leiomyomas). Clin Evid. 2004 Dec(12):2563-85. PMID: 15865807. X-2

681. Lowenstein L, Solt I, Siegler E, et al. Focal cervical and vaginal necrosis following uterine artery embolisation. Eur J Obstet Gynecol Reprod Biol. 2004 Oct 15;116(2):250-1. doi: 10.1016/j.ejogrb.2004.02.024. PMID: 15358482. X-1, X-1g, X-3, X-3d

682. Maruthur NM, Hsiao EC, Lee J, et al. Cases from the Osler medical service at Johns Hopkins University. Am J Med. 2004 Apr 1;116(7):490-2. doi: 10.1016/j.amjmed.2004.01.006. PMID: 15047040. X-1, X-1g, X-3

683. McLucas B, Adler L. Re: Leiomyoma recurrence after uterine artery embolization. J Vasc Interv Radiol. 2004 Jul;15(7):773-4; author reply 4-5. PMID: 15231894. X-1, X-2, X-3

684. Meldrum DR. Open electronic debate--even your obituary fails to escape peer review! Fertil Steril. 2004 Jul;82(1):260; author reply doi: 10.1016/j.fertnstert.2004.04.015. PMID: 15237037. X-1, X-2, X-3

685. Mettler L, Audebert A, Lehmann-Willenbrock E, et al. A randomized, prospective, controlled, multicenter clinical trial of a sprayable, site-specific adhesion barrier system in patients undergoing myomectomy. Fertil Steril. 2004 Aug;82(2):398-404. doi: 10.1016/j.fertnstert.2003.12.046. PMID: 15302290. X-6, X-7

686. Morita M, Asakawa Y, Uchiide I, et al. Surgery results using different uterine wall incision directions in laparoscopic myomectomy of the intramural myoma. Reproductive Medicine and Biology. 2004;3(1):33-7. doi: http://dx.doi.org/10.1111/j.1447-0578.2004.00049.x. PMID: 2005259938. X-1, X-1h, X-6, X-7

687. Ng PH, Mahdy Z, Nik NI. Recurrent leiomyomatosis peritonealis disseminata. J Obstet Gynaecol. 2004 Feb;24(2):188-9. doi: 10.1080/01443610410001643380. PMID: 14766471. X-1, X-1g, X-1i

688. Nilas L, Knudsen UB. [Surgical treatment of uterine bleeding]. Ugeskr Laeger. 2004 Feb 16;166(8):708-9. PMID: 15042823. X-2

689. Ojili V, Bapuraj JR, Suri V. Uterine artery embolization for the treatment of symptomatic fibroids. Int J Gynaecol Obstet. 2004 Dec;87(3):249-51. doi: 10.1016/j.ijgo.2004.08.008. PMID: 15548400. X-3, X-3c, X-4

690. Olivennes F. [Embolization of uterine fibromas: results of 454 cases. Gynecol Obstet Fertil 2003; 31: 597-605]. Gynecol Obstet Fertil. 2004 Jan;32(1):98; author reply -9. PMID: 14736609. X-3, X-3c

691. Palomba S, Russo T, Orio F, Jr., et al. Lipid, glucose and homocysteine metabolism in women treated with a GnRH agonist with or without raloxifene. Hum Reprod. 2004 Feb;19(2):415-21. PMID: 14747190. X-6, X-7

692. Palomba S, Zullo F, Orio F, Jr., et al. Does raloxifene inhibit the growth of uterine fibroids? Fertil Steril. 2004 Jun;81(6):1719-20; author reply 20-1. doi: 10.1016/j.fertnstert.2004.03.009. PMID: 15193512. X-2

693. Parker WH, Pritts EA, Olive DL. Uterine fibroids--impact on IVF and outcome of IVF pregnancies. Fertil Steril. 2004 Sep;82(3):763; author reply -4. doi: 10.1016/j.fertnstert.2004.06.002. PMID: 15374732. X-2

694. Pelage JP. Polyvinyl alcohol particles versus tris-acryl gelatin microspheres for uterine artery embolization for leiomyomas. J Vasc Interv Radiol. 2004 Aug;15(8):789-91. doi: 10.1097/01.rvi.0000133855.80334.d4. PMID: 15297581. X-2

695. Pelage JP, Jacob D, Le Dref O, et al. Re: fatal sepsis after uterine artery embolization with microspheres. J Vasc Interv Radiol. 2004 Apr;15(4):405-6; author reply 6. PMID: 15064346. X-1, X-2, X-3

696. Pelage JP, Jacob D, Le Dref O, et al. Re: Leiomyoma recurrence after uterine artery embolization. J Vasc Interv Radiol. 2004 Jul;15(7):773; author reply 4-5. PMID: 15231895. X-1, X-2, X-3

697. Powell JL. Giant fibroids. J Am Coll Surg. 2004 Oct;199(4):670. doi: 10.1016/j.jamcollsurg.2004.06.008. PMID: 15454164. X-2

698. Ringold S. FDA approves ultrasound fibroid therapy. Jama. 2004 Dec 15;292(23):2826. doi: 10.1001/jama.292.23.2826. PMID: 15598901. X-2

699. Ryan JM. Misinterpretation of postembolization syndrome after conservative treatment of fibroids. J Vasc Interv Radiol. 2004 Jan;15(1 Pt 1):99-100; author reply PMID: 14709697. X-2, X-3, X-3c

700. Sandhu AK, Hassan WY. Uterine fibroid embolization: is there a role? Saudi Med J. 2004 May;25(5):669-70. PMID: 15138541. X-1, X-1g, X-3

701. Spies JB, Sacks D. Credentials for uterine artery embolization. J Vasc Interv Radiol. 2004 Feb;15(2 Pt 1):111-3. PMID: 14963175. X-2

702. Sutton CJ. Historical curiosities in the surgical management of myomas. J Am Assoc Gynecol Laparosc. 2004 Feb;11(1):4-7. PMID: 15104824. X-2

703. Zullo F, Palomba S, Corea D, et al. Bupivacaine plus epinephrine for laparoscopic myomectomy: a randomized placebo-controlled trial. Obstet Gynecol. 2004 Aug;104(2):243-9. doi: 10.1097/01.AOG.0000132801.41880.e8. PMID: 15291994. X-1, X-1e, X-6, X-7

704. . Magnetic resonance-guided focused ultrasound therapy for symptomatic uterine fibroids. Technol Eval Cent Assess Program Exec Summ. 2005 Oct;20(10):1-3. PMID: 16267949. X-2

705. . [Recommendations of good practice: drug therapy for fibroma of uterus (October 2004)]. Gynecol Obstet Fertil. 2005 Jul-Aug;33(7-8):547-52. PMID: 16106573. X-2

706. . Can you tell me about the new device the FDA has approved for treating uterine fibroids? Mayo Clin Womens Healthsource. 2005 Apr;9(4):8. PMID: 15891684. X-2

707. . Uterine artery embolization for fibroids. Med Lett Drugs Ther. 2005 Apr 11;47(1206):31-2. PMID: 15821634. X-2

708. . Noninvasive treatment for uterine fibroids. FDA Consum. 2005 Jan-Feb;39(1):4. PMID: 15803583. X-2

709. Agostini A, Blanc B. [Urinary fibromas. Embolization: state of the art. Gynecol Obstet Fertil 2004; 32: 1057-63]. Gynecol Obstet Fertil. 2005 May;33(5):363. doi: 10.1016/j.gyobfe.2005.04.014. PMID: 15914071. X-1, X-1i, X-2

710. Agostini A, Ronda I, Franchi F, et al. Oxytocin during myomectomy: a randomized study. Eur J Obstet Gynecol Reprod Biol. 2005 Feb 1;118(2):235-8. doi: 10.1016/j.ejogrb.2004.06.032. PMID: 15653210. X-1, X-1e, X-7

711. Attilakos G, Fox R. Regression of tamoxifen-stimulated massive uterine fibroid after conversion to anastrozole. J Obstet Gynaecol. 2005 Aug;25(6):609-10. doi: 10.1080/01443610500242465. PMID: 16234156. X-1, X-1g, X-3, X-3d

712. Baakdah H, Tulandi T. Uterine fibroid embolization. Clin Obstet Gynecol. 2005 Jun;48(2):361-8. PMID: 15805793. X-2

713. Bats AS, Madelenat P. [GnRH analogues and myomas: somewhat for]. Gynecol Obstet Fertil. 2005 Dec;33(12):1023-7. doi: 10.1016/j.gyobfe.2005.10.002. PMID: 16316773. X-2

714. Boos CJ, Calver AL, Moors A, et al. Uterine artery embolisation for massive uterine fibroids in the presence of submassive pulmonary emboli. Bjog. 2005 Oct;112(10):1440-2. doi: 10.1111/j.1471-0528.2005.00724.x. PMID: 16167954. X-3, X-3d

715. Caglar GS, Tasci Y, Kayikcioglu F. Management of prolapsed pedunculated myomas. Int J Gynaecol Obstet. 2005 May;89(2):146-7. doi: 10.1016/j.ijgo.2005.01.018. PMID: 15847881. X-2, X-3, X-3a

716. Cole P, Castaner J, Fernandez-Forner D. Asoprisnil: Endometriosis therapy treatment of uterine fibroids selective progesterone receptor modulator. Drugs of the Future. 2005 October;30(10):985-91. doi: http://dx.doi.org/10.1358/dof.2005.030.10.945144. PMID: 2006032453. X-2

717. Dandolu V, Lorico A. Outcome of uterine embolization and hysterectomy for leiomyomas. Am J Obstet Gynecol. 2005 Jul;193(1):304-5; author reply 5-6. doi: 10.1016/j.ajog.2005.01.082. PMID: 16021096. X-2

718. de la Linde CM, Lopez MI, Ortiz JM, et al. [Selective intubation through a rigid bronchoscope]. Rev Esp Anestesiol Reanim. 2005 Oct;52(8):509-11. PMID: 16281752. X-1, X-1i, X-2

719. Dubuisson JB. [The limits of laparoscopic myomectomy. Gynecol Obstet Fertil 2005;33:44-9]. Gynecol Obstet Fertil. 2005 Jul-Aug;33(7-8):553-4. doi: 10.1016/j.gyobfe.2005.06.005. PMID: 16005665. X-2

720. Elkington NM, Carlton M. Recurrent intravenous leiomyomatosis with extension up the inferior vena cava. Aust N Z J Obstet Gynaecol. 2005 Apr;45(2):167. doi: 10.1111/j.1479-828X.2005.00355.x. PMID: 15760324. X-1, X-1g, X-3, X-5

721. Elliot AP, Heazell AE, Judge JK, et al. An evaluation of the use of an intra-operative uterine tourniquet during multiple myomectomy: does this reduce blood loss and the need for blood transfusion? J Obstet Gynaecol. 2005 May;25(4):382-3. doi: 10.1080/01443610500119630. PMID: 16091326. X-3, X-3a

722. Falcone T, Gustilo-Ashby AM. Minimally invasive surgery for mass lesions. Clin Obstet Gynecol. 2005 Jun;48(2):353-60. PMID: 15805792. X-2

723. Fanfani F, Fagotti A, Bifulco G, et al. A prospective study of laparoscopy versus minilaparotomy in the treatment of uterine myomas. J Minim Invasive Gynecol. 2005 Nov-Dec;12(6):470-4. doi: 10.1016/j.jmig.2005.07.002. PMID: 16337572. X-3, X-3a

724. Fernandez H. [GnRH analogues and myomas: against but...]. Gynecol Obstet Fertil. 2005 Dec;33(12):1019-22. doi: 10.1016/j.gyobfe.2005.10.003. PMID: 16314135. X-2

725. Fernandez H. [Uterine fibroma. Embolization: state-of-the-art. Gynecol Obstet Fertil 2004; 32: 1057-63]. Gynecol Obstet Fertil. 2005 May;33(5):364-6. doi: 10.1016/j.gyobfe.2005.04.007. PMID: 15914070. X-2

726. Frishman GN, Jurema MW. Myomas and myomectomy. J Minim Invasive Gynecol. 2005 Sep-Oct;12(5):443-56; quiz 57-8. doi: 10.1016/j.jmig.2005.05.023. PMID: 16213434. X-2

727. Goldberg J. Pregnancy after uterine artery embolization for leiomyomata: the Ontario Multicenter Trial. Obstet Gynecol. 2005 Jul;106(1):195-6; author reply 6. doi: 10.1097/01.AOG.0000169598.61122.5a. PMID: 15994645. X-2

728. Goldberg J. Uterine fibroid embolization: a hidden alternative? Obstet Gynecol Surv. 2005 Apr;60(4):209-10. PMID: 15795610. X-2

729. Goldfarb HA. Re: Hysterectomy after endometrial ablation-resection. J Am Assoc Gynecol Laparosc. 2004 Nov;11(4):495-9. J Minim Invasive Gynecol. 2005 May-Jun;12(3):298. doi: 10.1016/j.jmig.2005.03.010. PMID: 15922991. X-1, X-2, X-3

730. Gutmann JN, Corson SL. GnRH agonist therapy before myomectomy or hysterectomy. J Minim Invasive Gynecol. 2005 Nov-Dec;12(6):529-37; quiz 8, 38-9. doi: 10.1016/j.jmig.2005.09.012. PMID: 16337584. X-2

731. Hernandez Rivera S. [Uterine fibromyoma and pregnancy. 1949]. Ginecol Obstet Mex. 2005 Feb;73(2):106-8. PMID: 21961346. X-2

732. Istre O. Uterine artery occlusion for the treatment of symptomatic fibroids: endoscopic, radiological and vaginal approach. Minim Invasive Ther Allied Technol. 2005;14(3):167-74. doi: 10.1080/13645700510033976. PMID: 16754159. X-2

733. Kulishova TV, Tabashnikova NA, Akker LV. [Efficacy of general magnetotherapy in conservative therapy of uterine myoma in women of reproductive age]. Vopr Kurortol Fizioter Lech Fiz Kult. 2005 Jan-Feb(1):26-8. PMID: 15759473. X-3, X-3f

734. Kuppermann M, Summitt RL, Jr., Varner RE, et al. Sexual functioning after total compared with supracervical hysterectomy: a randomized trial. Obstet Gynecol. 2005 Jun;105(6):1309-18. doi: 10.1097/01.AOG.0000160428.81371.be. PMID: 15932822. X-5

735. Lai TK, Huang HY, Chan RY, et al. Magnetic resonance venogram of intravenous leiomyomatosis. Hong Kong Med J. 2005 Dec;11(6):524-6. PMID: 16340033. X-1, X-1h, X-3, X-3d

736. Leonhardt H, Aziz A, Lonn L. Post-embolization syndrome and complete expulsion of a leiomyoma after uterine artery embolization. Acta Obstet Gynecol Scand. 2005 Mar;84(3):303-5. doi: 10.1111/j.0001-6349.2005.0358d.x. PMID: 15715544. X-3, X-3d

737. Leon-Villapalos J, Kaniorou-Larai M, Dziewulski P. Full thickness abdominal burn following magnetic resonance guided focused ultrasound therapy. Burns. 2005 Dec;31(8):1054-5. doi: 10.1016/j.burns.2005.04.019. PMID: 15970389. X-1, X-1g, X-3, X-3d

738. Lethaby A, Vollenhoven B. Fibroids (uterine myomatosis, leiomyomas). Clin Evid. 2005 Dec(14):2264-82. PMID: 16620489. X-2

739. Lethaby A, Vollenhoven B. Fibroids (uterine myomatosis, leiomyomas). Am Fam Physician. 2005 May 1;71(9):1753-6. PMID: 15887454. X-2

740. Lin JF. [Minimally invasive surgery and problems in gynecologic practice of China]. Zhonghua Yi Xue Za Zhi. 2005 Jan 19;85(3):149-51. PMID: 15854454. X-2

741. Litta P, Cosmi E, Nardelli GB. Laparoscopic myomectomy following GnRH therapy. Int J Gynaecol Obstet. 2005 Jan;88(1):63-4. doi: 10.1016/j.ijgo.2004.09.023. PMID: 15617712. X-1, X-1e, X-2, X-3, X-3e

742. Marret H, Lansac J, Fourquet F. Transvaginal hysterectomy: not always the rational approach for leiomyomas. Eur J Obstet Gynecol Reprod Biol. 2005 Jun 1;120(2):232-3. doi: 10.1016/j.ejogrb.2004.11.002. PMID: 15925061. X-2

743. Mizutani T, Sugihara A, Honma H, et al. Effect of steroid add-back therapy on the proliferative activity of uterine leiomyoma cells under gonadotropin-releasing hormone agonist therapy. Gynecol Endocrinol. 2005 Feb;20(2):80-3. doi: 10.1080/09513590400021029. PMID: 15823826. X-1, X-1a, X-1e

744. Moss JG. Uterine fibroid embolization: more evidence is required. Cardiovasc Intervent Radiol. 2005 Mar-Apr;28(2):150-2. doi: 10.1007/s00270-004-4243-7. PMID: 15883859. X-2

745. Olayemi O, Adekanle DA, Aimakhu CO, et al. Blood loss at fibroids surgery: myomectomy versus total abdominal hysterectomy. Trop Doct. 2005 Jul;35(3):171-2. doi: 10.1258/0049475054620932. PMID: 16105348. X-3, X-3a, X-4

746. Palomba S, Orio F, Jr., Russo T, et al. Antiproliferative and proapoptotic effects of raloxifene on uterine leiomyomas in postmenopausal women. Fertil Steril. 2005 Jul;84(1):154-61. doi: 10.1016/j.fertnstert.2004.12.058. PMID: 16009171. X-6, X-7

747. Pietura R, Jakiel G, Swatowski D, et al. Pregnancy 4 months after uterine artery embolization. Cardiovasc Intervent Radiol. 2005 Jan-Feb;28(1):117-9. doi: 10.1007/s00270-004-9026-7. PMID: 15772730. X-3, X-3d

748. Poncelet C. [GnRH analogues and myomas: which strategy?]. Gynecol Obstet Fertil. 2005 Dec;33(12):1018. doi: 10.1016/j.gyobfe.2005.10.014. PMID: 16316770. X-2

749. Price N, Gillmer MD, Stock A, et al. Pregnancy following uterine artery embolisation. J Obstet Gynaecol. 2005 Jan;25(1):28-31. doi: 10.1080/01674820400023416. PMID: 16147689. X-3, X-3c

750. Prollius A, du Plessis A, Nel M. Uterine artery embolization in HIV positive patients. Int J Gynaecol Obstet. 2005 Jan;88(1):67-8. doi: 10.1016/j.ijgo.2004.08.005. PMID: 15617714. X-1, X-2, X-3, X-3c

751. Ravina JH. [Uterine fibroids. Embolization: state-of-the-art. Gynecol Obstet Fertil 2004; 32: 1057-63]. Gynecol Obstet Fertil. 2005 May;33(5):363-4. doi: 10.1016/j.gyobfe.2005.04.004. PMID: 15921946. X-2

752. Ryu RK. Uterine artery embolization: current implications of embolic agent choice. J Vasc Interv Radiol. 2005 Nov;16(11):1419-22. doi: 10.1097/01.RVI.0000190494.11439.6f. PMID: 16319145. X-2

753. Safonov AV, Urmancheeva AF. [Ultrasound and hysteroscopic assessment as a component of diagnosis of genital tumors in women with menopausal bleeding]. Vopr Onkol. 2005;51(4):480-4. PMID: 16308984. X-1, X-1c

754. Sinha R, Hegde A, Warty N, et al. Laparoscopic myomectomy: enucleation of the myoma by morcellation while it is attached to the uterus. J Minim Invasive Gynecol. 2005 May-Jun;12(3):284-9. doi: 10.1016/j.jmig.2005.03.018. PMID: 15922988. X-4

755. Sprague RA, Hayes CS, Advincula AP. Integration of robot-assisted laparoscopy in the minimally invasive management of symptomatic uterine fibroids. Biomed Instrum Technol. 2005;Suppl:55-60. PMID: 16134543. X-2

756. Srivatsa A, Burdett J, Gill D. A 35-year-old woman with uterine fibroids and multiple embolic strokes. Neurology. 2005 Apr 26;64(8):1479-80. doi: 10.1212/01.wnl.0000158677.85322.e6. PMID: 15851754. X-1, X-1g, X-1h, X-3, X-3d

757. Takeuchi H, Kitade M, Kikuchi I, et al. Adhesion-prevention effects of fibrin sealants after laparoscopic myomectomy as determined by second-look laparoscopy: a prospective, randomized, controlled study. J Reprod Med. 2005 Aug;50(8):571-7. PMID: 16220761. X-1, X-1h, X-6, X-7

758. Taylor A, Blackmore S, Tsirkas P, et al. Color Doppler evaluation of changes in uterine perfusion induced by the use of an absorbable cervical tourniquet during open myomectomy. J Clin Ultrasound. 2005 Oct;33(8):390-3. doi: 10.1002/jcu.20144. PMID: 16240429. X-1, X-1h, X-6, X-7

759. Taylor A, Sharma M, Tsirkas P, et al. Reducing blood loss at open myomectomy using triple tourniquets: a randomised controlled trial. Bjog. 2005 Mar;112(3):340-5. doi: 10.1111/j.1471-0528.2004.00430.x. PMID: 15713151. X-6, X-7

760. Theodoridis TD, Zepiridis L, Grimbizis G, et al. Laparoscopic management of broad ligament leiomyoma. J Minim Invasive Gynecol. 2005 Nov-Dec;12(6):469. doi: 10.1016/j.jmig.2005.09.016. PMID: 16337571. X-1, X-1g, X-1h, X-1i, X-3, X-3d, X-5

761. Torigian DA, Siegelman ES, Terhune KP, et al. MRI of uterine necrosis after uterine artery embolization for treatment of uterine leiomyomata. AJR Am J Roentgenol. 2005 Feb;184(2):555-9. doi: 10.2214/ajr.184.2.01840555. PMID: 15671379. X-3, X-3d

762. Tsuji S, Takahashi K, Yomo H, et al. Effectiveness of antiadhesion barriers in preventing adhesion after myomectomy in patients with uterine leiomyoma. Eur J Obstet Gynecol Reprod Biol. 2005 Dec 1;123(2):244-8. doi: 10.1016/j.ejogrb.2005.04.012. PMID: 15950364. X-3, X-3a

763. Vallejo JM, Ballester C, Sorribas F. [Intravascular leiomyomatosis: the surgical challenge of tumors with cavoatrial extension]. Rev Esp Cardiol. 2005 Oct;58(10):1246-7. PMID: 16238996. X-1, X-1g, X-1h, X-1i

764. Vavilis D, Togaridou E, Agorastos T. Abdominal myomectomy and febrile morbidity. Int J Gynaecol Obstet. 2005 Jan;88(1):61-2. doi: 10.1016/j.ijgo.2004.09.021. PMID: 15617711. X-3, X-3a

765. Worthington-Kirsch RL. Uterine artery embolization for fibroid disease is not experimental. Cardiovasc Intervent Radiol. 2005 Mar-Apr;28(2):148-9. doi: 10.1007/s00270-004-0125-2. PMID: 15719184. X-2

766. Zhan S, Li Y, Wang G, et al. Effectiveness of intra-arterial anesthesia for uterine fibroid embolization using dilute lidocaine. Eur Radiol. 2005 Aug;15(8):1752-6. doi: 10.1007/s00330-005-2686-0. PMID: 15696287. X-6, X-7

767. Zhang GL, Wen WQ, Xing FQ. [Effect of enucleation of hysteromyoma by laparoscopic surgery on protein oxidation and lipid hyperoxidation]. Zhonghua Yi Xue Za Zhi. 2005 Jan 19;85(3):177-80. PMID: 15854463. X-1, X-1a, X-1d, X-1h, X-6, X-7

768. Zhou YF, Yang DZ, Hu LN, et al. [Clinical trial on the effectiveness and safety of triptorelin in treatment of uterine leiomyoma]. Zhonghua Fu Chan Ke Za Zhi. 2005 Jul;40(7):460-3. PMID: 16080872. X-11

769. Zorlu CG, Akar ME, Seker-Ari E, et al. Uterine artery embolization to control bleeding after myomectomy. Acta Obstet Gynecol Scand. 2005 Jun;84(6):606-7. doi: 10.1111/j.0001-6349.2005.0037d.x. PMID: 15901277. X-3, X-3d

770. . Myomas and reproductive function. Fertil Steril. 2006 Nov;86(5 Suppl 1):S194-9. doi: 10.1016/j.fertnstert.2006.08.026. PMID: 17055821. X-2

771. . Procedure shrinks fibroids in postmenopausal women, too. Harv Womens Health Watch. 2006 Jun;13(10):5. PMID: 16841383. X-2, X-3, X-3c, X-7

772. . Treating uterine fibroids. New therapies provide more choices. Mayo Clin Womens Healthsource. 2006 May;10(5):4-5. PMID: 16585924. X-1, X-1h, X-2, X-3, X-3f, X-5

773. Acien P. The importance of being precise about Mullerian malformations. Fertil Steril. 2006 Nov;86(5):1556; author reply -7. doi: 10.1016/j.fertnstert.2006.05.015. PMID: 16926008. X-1, X-1i, X-2, X-3, X-3f, X-4, X-5, X-6, X-7

774. Anderson L, Russell P, Halloway C, et al. Uterine plexiform leiomyomatosis with an intrinsic granulomatous response. Pathology. 2006 Apr;38(2):179-81. doi: 10.1080/00313020600562011. PMID: 16581663. X-1, X-1d, X-1g, X-2, X-3, X-3d

775. Ayabe T. [Clinical application of GnRH antagonist to uterine fibroid]. Nihon Rinsho. 2006 Apr;64 Suppl 4:116-21. PMID: 16689295. X-2

776. Bedaiwy MA, Paraiso MF. Reply to letter by Dionne. Int Urogynecol J Pelvic Floor Dysfunct. 2006 May;17(3):302. doi: 10.1007/s00192-004-1222-0. PMID: 16583122. X-2

777. Chang FW, Yu MH, Ku CH, et al. Effect of uterotonics on intra-operative blood loss during laparoscopy-assisted vaginal hysterectomy: a randomised controlled trial. Bjog. 2006 Jan;113(1):47-52. doi: 10.1111/j.1471-0528.2005.00804.x. PMID: 16398771. X-1, X-1h, X-6, X-7

778. Chigbu CO, Iloabachie GC. Intrauterine Foley urethral catheter for postmyomectomy uterine bleeding. Int J Gynaecol Obstet. 2006 Nov;95(2):175-6. doi: 10.1016/j.ijgo.2006.06.017. PMID: 16916516. X-1, X-1g, X-1h, X-1i, X-2, X-3, X-3d, X-4, X-7

779. Cohen J. [GnRH analogues and myomas: which strategy?]. Gynecol Obstet Fertil. 2006 May;34(5):462. doi: 10.1016/j.gyobfe.2006.03.006. PMID: 16630742. X-2

780. Cohen J. Save my uterus, take the fibroids. AWHONN Lifelines. 2006 Feb-Mar;10(1):11. doi: 10.1111/j.1552-6356.2006.00005.x. PMID: 16542325. X-2

781. De Falco M, Staibano S, D'Armiento FP, et al. Preoperative treatment of uterine leiomyomas: clinical findings and expression of transforming growth factor-beta3 and connective tissue growth factor. J Soc Gynecol Investig. 2006 May;13(4):297-303. doi: 10.1016/j.jsgi.2006.02.008. PMID: 16697947. X-1, X-1e, X-7

782. Drahonovsky J, Pan M, Baresova S, et al. [Clinical comparison of laparoscopy-assisted vaginal hysterectomy (LAVH) and total laparoscopy hysterectomy (TLH) in women with benign disease of uterus--a prospective randomized study]. Ceska Gynekol. 2006 Dec;71(6):431-7. PMID: 17236400. X-1, X-1h

783. Gavai M, Berkes E, Papp Z. Surgery for large uterine fibroids: size is rarely an issue. Fertil Steril. 2006 Dec;86(6):1806; author reply -7. doi: 10.1016/j.fertnstert.2006.08.078. PMID: 17055498. X-2, X-3, X-3c

784. Golzarian J, Lang E, Hovsepian D, et al. Higher rate of partial devascularization and clinical failure after uterine artery embolization for fibroids with spherical polyvinyl alcohol. Cardiovasc Intervent Radiol. 2006 Jan-Feb;29(1):1-3. doi: 10.1007/s00270-005-0243-5. PMID: 16391950. X-2

785. Grimbizis GF, Assimakopoulos E, Chatzigeorgiou KN, et al. Successful laparoscopic treatment of a primary peritoneal leiomyoma. Acta Obstet Gynecol Scand. 2006;85(11):1399-400. doi: 10.1080/00016340500534492. PMID: 17091425. X-1, X-1g, X-1i, X-3, X-3d

786. Herzog TJ, Coleman RL, Guerrieri JP, Jr., et al. A double-blind, randomized, placebo-controlled phase III study of the safety of alvimopan in patients who undergo simple total abdominal hysterectomy. Am J Obstet Gynecol. 2006 Aug;195(2):445-53. doi: 10.1016/j.ajog.2006.01.039. PMID: 16626607. X-1, X-1h, X-5, X-7

787. Hoeldtke NJ. Long-term outcome of uterine artery embolization of leiomyomata. Obstet Gynecol. 2006 Mar;107(3):741; author reply -2. doi: 10.1097/01.aog.0000203430.64845.31. PMID: 16507952. X-2

788. Holub Z, Jabor A, Kliment L, et al. Inflammatory responses after laparoscopic uterine myomectomy compared to open surgery in current clinical practice. Saudi Med J. 2006 Nov;27(11):1693-7. PMID: 17106543. X-3, X-3b, X-3f

789. Holzer A, Jirecek ST, Illievich UM, et al. Laparoscopic versus open myomectomy: a double-blind study to evaluate postoperative pain. Anesth Analg. 2006 May;102(5):1480-4. doi: 10.1213/01.ane.0000204321.85599.0d. PMID: 16632830. X-6, X-7

790. Inaba F, Furuno M, Fukasawa I, et al. The diagnosis of intravenous leiomyomatosis of an early stage is difficult. Indian J Med Sci. 2006 Oct;60(10):422-4. PMID: 17006029. X-1, X-1i, X-2, X-3, X-3d

791. Indman PD. Hysteroscopic treatment of submucous myomas. Clin Obstet Gynecol. 2006 Dec;49(4):811-20. doi: 10.1097/01.grf.0000211960.53498.29. PMID: 17082675. X-2

792. Katsumori T, Kasahara T. Uterine artery embolization versus hysterectomy in the treatment of symptomatic uterine fibroids (EMMY trial). Am J Obstet Gynecol. 2006 Oct;195(4):1190; author reply 1. doi: 10.1016/j.ajog.2005.12.068. PMID: 17000261. X-2

793. Kim HS, Patra A. Uterine artery embolization and future fertility. J Vasc Interv Radiol. 2006 Jun;17(6):1064-5. doi: 10.1097/01.RVI.0000223706.31418.b0. PMID: 16778245. X-1, X-1g, X-2

794. Kroencke TJ, Lohle PN. Re: primary failure of uterine artery embolization: use of magnetic resonance imaging to select patients for repeated embolization. J Vasc Interv Radiol. 2006 Jan;17(1):181-2; author reply 2. doi: 10.1097/01.rvi.0000197368.48934.5c. PMID: 16415150. X-1, X-2, X-3

795. Langton J, Timms MJ. Uterine myomectomy by Coblation. Bjog. 2006 Mar;113(3):347-9. doi: 10.1111/j.1471-0528.2005.00830.x. PMID: 16487210. X-2, X-3, X-3d

796. Mais V, Bracco GL, Litta P, et al. Reduction of postoperative adhesions with an auto-crosslinked hyaluronan gel in gynaecological laparoscopic surgery: a blinded, controlled, randomized, multicentre study. Hum Reprod. 2006 May;21(5):1248-54. doi: 10.1093/humrep/dei488. PMID: 16439505. X-1, X-1h, X-6, X-7

797. Marik JJ. Follow-up after uterine artery embolization versus myomectomy. Fertil Steril. 2006 Oct;86(4):1029; author reply doi: 10.1016/j.fertnstert.2006.06.002. PMID: 16926012. X-2

798. Maruyama T, Asada H, Ono M, et al. [Uterine leiomyoma]. Nihon Rinsho. 2006 Jun 28;Suppl 2:477-84. PMID: 16817446. X-2, X-11

799. Maslovsky I, Gemer O, Gefel D, et al. Polycythemia as a result of ectopic erythropoietin production in benign cystic leiomyoma of uterus. Acta Obstet Gynecol Scand. 2006;85(7):887-8. doi: 10.1080/00016340600608865. PMID: 16817092. X-1, X-1g, X-3, X-3d

800. Matsuo H, Maruo T. [GnRH analogues in the management of uterine leiomyoma]. Nihon Rinsho. 2006 Apr;64 Suppl 4:75-9. PMID: 16689288. X-2, X-11

801. Murakami T. [Estrogens and leiomyoma of the uterus]. Nihon Rinsho. 2006 Apr;64 Suppl 4:364-9. PMID: 16689335. X-2

802. Muthukrishnan R, Oyakhire GK, Ramachandran UK. Uterus didelphus. Saudi Med J. 2006 Nov;27(11):1766-7. PMID: 17106562. X-1, X-1g, X-1i, X-2, X-3

803. Palomba S, Zupi E, Zullo F. Fanfani F, et al. A prospective study of laparoscopy versus minilaparotomy in the treatment of uterine myomas. J Minim Invasive Gynecol. 2006 May-Jun;13(3):253; author reply -4. doi: 10.1016/j.jmig.2006.01.016. PMID: 16698538. X-1, X-1h, X-2, X-3, X-3f

804. Parker WH. Laparoscopic myomectomy and abdominal myomectomy. Clin Obstet Gynecol. 2006 Dec;49(4):789-97. doi: 10.1097/01.grf.0000211949.36465.ef. PMID: 17082673. X-2

805. Pelage JP. Uterine fibroid ablation: the beginning of the end of uterine fibroid embolization? Cardiovasc Intervent Radiol. 2006 Jul-Aug;29(4):499-501. doi: 10.1007/s00270-004-5163-2. PMID: 16502182. X-2

806. Pritts EA, Parker WH. Predictive value of myomectomy. Fertil Steril. 2006 Sep;86(3):769-70; author reply 70-1. doi: 10.1016/j.fertnstert.2006.07.1460. PMID: 16952518. X-2

807. Reekers JA, Ankum PM, Birnie E. Re: Dr. Spies' commentary on the EMMY study. J Vasc Interv Radiol. 2006 Sep;17(9):1548-9; author reply 9-50. doi: 10.1097/01.rvi.0000240421.31440.db. PMID: 16990480. X-1, X-2, X-3

808. Ruscalleda N, Eixarch E, Pages M, et al. Leiomyomatosis peritonealis disseminata (2006: 9b). Eur Radiol. 2006 Dec;16(12):2879-82. doi: 10.1007/s00330-006-0356-5. PMID: 17047963. X-1, X-1g, X-1i, X-2

809. Scheurig C, Gauruder-Burmester A, Kluner C, et al. Uterine artery embolization for symptomatic fibroids: short-term versus mid-term changes in disease-specific symptoms, quality of life and magnetic resonance imaging results. Hum Reprod. 2006 Dec;21(12):3270-7. doi: 10.1093/humrep/del275. PMID: 16877371. X-3, X-3c, X-7

810. Siddiqi AJ, Chrisman HB, Vogelzang RL, et al. MR imaging evidence of reversal of uterine ischemia after uterine artery embolization for leiomyomata. J Vasc Interv Radiol. 2006 Sep;17(9):1535-8. doi: 10.1097/01.rvi.0000235700.37074.f1. PMID: 16990475. X-3, X-3d

811. Siskin GP, Shlansky-Goldberg RD, Goodwin SC, et al. A prospective multicenter comparative study between myomectomy and uterine artery embolization with polyvinyl alcohol microspheres: long-term clinical outcomes in patients with symptomatic uterine fibroids. J Vasc Interv Radiol. 2006 Aug;17(8):1287-95. doi: 10.1097/01.rvi.0000231953.91787.af. PMID: 16923975. X-3, X-3a

812. Spies JB. The EMMY trial of uterine artery embolization for the treatment of symptomatic uterine fibroid tumors: randomized, yes, but a flawed trial nonetheless. J Vasc Interv Radiol. 2006 Mar;17(3):413-5. doi: 10.1097/01.rvi.0000203420.62462.0f. PMID: 16567666. X-2

813. Spies JB. Adding to our understanding of uterine fibroid embolization. AJR Am J Roentgenol. 2006 Mar;186(3):846-7. doi: 10.2214/ajr.05.2112. PMID: 16498119. X-2

814. Subramaniam B, Pawlowski J, Gross BA, et al. TEE-guided one-stage excision of intravenous leiomyomatosis with cardiac extension through an abdominal approach. J Cardiothorac Vasc Anesth. 2006 Feb;20(1):94-5. doi: 10.1053/j.jvca.2004.11.049. PMID: 16458225. X-1, X-1g, X-1i

815. Taylor A, Magos A. Reducing blood loss at open myomectomy using triple tourniquet: a randomised controlled trial. Bjog. 2006 May;113(5):618-9. doi: 10.1111/j.1471-0528.2006.00866.x. PMID: 16579807. X-2

816. Toon C, McGahan S, Henderson P, et al. Myxoid symplastic leiomyoma of the uterus. Pathology. 2006 Jun;38(3):275-7. doi: 10.1080/00313020600699276. PMID: 16753760. X-1, X-1g, X-3, X-3d

817. Vilos GA, Hollett-Caines J, Burbank F. Uterine artery occlusion: what is the evidence? Clin Obstet Gynecol. 2006 Dec;49(4):798-810. doi: 10.1097/01.grf.0000211950.74583.f5. PMID: 17082674. X-2

818. Wang CJ, Yuen LT, Lee CL, et al. A prospective comparison of morcellator and culdotomy for extracting of uterine myomas laparoscopically in nullipara. J Minim Invasive Gynecol. 2006 Sep-Oct;13(5):463-6. doi: 10.1016/j.jmig.2006.05.005. PMID: 16962533. X-3, X-3a

819. Zamurovic M, Stanojevic D, Srbinovic P, et al. [Myomectomy by vaginal route]. Acta Chir Iugosl. 2006;53(1):83-6. PMID: 16989153. X-3, X-3c, X-3f

820. Zupi E, Sbracia M, Marconi D, et al. Myolysis of uterine fibroids: is there a role? Clin Obstet Gynecol. 2006 Dec;49(4):821-33. doi: 10.1097/01.grf.0000211961.91616.78. PMID: 17082676. X-2

821. . ACOG Practice Bulletin. Clinical management guidelines for obstetrician-gynecologists. Number 81, May 2007. Obstet Gynecol. 2007 May;109(5):1233-48. doi: 10.1097/01.AOG.0000263898.22544.cd. PMID: 17470612. X-2

822. Andersen PE. [Interventional therapeutic embolization of tumors]. Ugeskr Laeger. 2007 Apr 23;169(17):1543. PMID: 17484819. X-2

823. Ashawesh K, Abdulqawi R, Redford D, et al. Postmenopausal hyperandrogenism of ovarian origin: diagnostic and therapeutic difficulties. Endocr J. 2007 Aug;54(4):647. PMID: 17878611. X-1, X-2, X-3, X-3d

824. Banu NS, Gaze DC, Bruce H, et al. Markers of muscle ischemia, necrosis, and inflammation following uterine artery embolization in the treatment of symptomatic uterine fibroids. Am J Obstet Gynecol. 2007 Mar;196(3):213.e1-5. doi: 10.1016/j.ajog.2006.10.888. PMID: 17346524. X-6, X-7

825. Basama FM, Ghani R. A rapidly growing uterine leiomyoma and postmyomectomy ureteric fistula. Arch Gynecol Obstet. 2007 Jan;275(1):57-8. doi: 10.1007/s00404-006-0177-4. PMID: 16847637. X-1, X-1g, X-3, X-3d

826. Baytur YB, Ozbilgin K, Cilaker S, et al. A comparative study of the effect of raloxifene and gosereline on uterine leiomyoma volume changes and estrogen receptor, progesterone receptor, bcl-2 and p53 expression immunohistochemically in premenopausal women. Eur J Obstet Gynecol Reprod Biol. 2007 Nov;135(1):94-103. doi: 10.1016/j.ejogrb.2006.07.042. PMID: 16973256. X-1, X-1e, X-6, X-7

827. Bell JG, Shaffer LE, Schrickel-Feller T. Randomized trial comparing 3 methods of postoperative analgesia in gynecology patients: patient-controlled intravenous, scheduled intravenous, and scheduled subcutaneous. Am J Obstet Gynecol. 2007 Nov;197(5):472.e1-7. doi: 10.1016/j.ajog.2007.03.039. PMID: 17980179. X-1, X-1h, X-5, X-6, X-7

828. Bhatla N, Singla S. Symptomatic uterine fibroids: is uterine artery embolization better than surgery? Natl Med J India. 2007 Mar-Apr;20(2):87-8. PMID: 17802988. X-2

829. Borghese B, Chapron C. Treatment of symptomatic uterine fibroids. N Engl J Med. 2007 May 24;356(21):2218-9; author reply 9. PMID: 17526093. X-2

830. Buek J. Management options for uterine fibroid tumors. Am Fam Physician. 2007 May 15;75(10):1452-3. PMID: 17555138. X-2

831. Chapman A, ter Haar G. Thermal ablation of uterine fibroids using MR-guided focused ultrasound-a truly non-invasive treatment modality. Eur Radiol. 2007 Oct;17(10):2505-11. doi: 10.1007/s00330-007-0644-8. PMID: 17473924. X-2

832. Chiang AJ, Wang YY. A string of myomata. J Minim Invasive Gynecol. 2007 Nov-Dec;14(6):679. doi: 10.1016/j.jmig.2007.02.002. PMID: 17980325. X-1, X-1g, X-2, X-3, X-3d

833. Dubuisson JB. [How I perform...the preventive occlusion of the uterine arteries before myomectomy or hysterectomy?]. Gynecol Obstet Fertil. 2007 Dec;35(12):1264-7. doi: 10.1016/j.gyobfe.2007.10.013. PMID: 18035578. X-2

834. Dueholm M. [Therapeutic methods for myoma in 2007]. Ugeskr Laeger. 2007 Apr 23;169(17):1544. PMID: 17484820. X-2

835. El-Shawarby SA, Hassan M, Gangooly S, et al. A novel application of the Lap Loop system in day case laparoscopic myomectomy prior to IVF. J Obstet Gynaecol. 2007 May;27(4):437-8. doi: 10.1080/01443610701359605. PMID: 17654211. X-3, X-3d

836. Engel JB, Audebert A, Frydman R, et al. Presurgical short term treatment of uterine fibroids with different doses of cetrorelix acetate: a double-blind, placebo-controlled multicenter study. Eur J Obstet Gynecol Reprod Biol. 2007 Oct;134(2):225-32. doi: 10.1016/j.ejogrb.2006.07.018. PMID: 16930803. X-1e, X-7

837. Funaki K, Fukunishi H, Funaki T, et al. Magnetic resonance-guided focused ultrasound surgery for uterine fibroids: relationship between the therapeutic effects and signal intensity of preexisting T2-weighted magnetic resonance images. Am J Obstet Gynecol. 2007 Feb;196(2):184.e1-6. doi: 10.1016/j.ajog.2006.08.030. PMID: 17306674. X-3, X-3a, X-3c, X-7

838. Gaetje R, Mavrova-Risteska L, Zangos S, et al. Clinical outcome after myomectomy versus uterine artery embolization for uterine fibroids. Geburtshilfe und Frauenheilkunde. 2007 July;67(7):748-52. doi: http://dx.doi.org/10.1055/s-2007-965396. PMID: 2007395704. X-3, X-3a

839. Gomel V. Isobaric laparoscopy. J Obstet Gynaecol Can. 2007 Jun;29(6):493-4. PMID: 17650562. X-1, X-1h, X-2

840. Gonsalves C, Franciosa SV, Shah S, et al. Patient presentation and management of labial ulceration following uterine artery embolization. Cardiovasc Intervent Radiol. 2007 Nov-Dec;30(6):1263-6. doi: 10.1007/s00270-007-9120-8. PMID: 17624571. X-3, X-3c, X-3d

841. Ho SY, Huang KG, Yeow KM, et al. Uterine fibroid with calcified rim formation mimicking a fetal head after uterine artery embolization. Taiwan J Obstet Gynecol. 2007 Mar;46(1):85-7. doi: 10.1016/s1028-4559(08)60117-5. PMID: 17389200. X-1, X-2, X-3, X-3d

842. Holub Z, Mara M, Eim J. Laparoscopic uterine artery occlusion versus uterine fibroid embolization. Int J Gynaecol Obstet. 2007 Jan;96(1):44-5. doi: 10.1016/j.ijgo.2006.09.016. PMID: 17188272. X-2, X-3, X-3a

843. Jao MS, Huang KG, Jung SM, et al. Postmenopausal uterine leiomyoma with hemorrhagic cystic degeneration mimicking ovarian malignancy. Taiwan J Obstet Gynecol. 2007 Dec;46(4):431-4. doi: 10.1016/s1028-4559(08)60018-2. PMID: 18182354. X-3, X-3d

844. Justesen P. [Embolization for treatment of symptomatic uterine fibroma]. Ugeskr Laeger. 2007 Apr 23;169(17):1548-50. PMID: 17484822. X-2

845. Kabli N, Arseneau J, Tulandi T. A diagnostic challenge. Am J Obstet Gynecol. 2007 Oct;197(4):435.e1-2. doi: 10.1016/j.ajog.2007.07.048. PMID: 17904993. X-1, X-3, X-3d, X-5

846. Lampmann LE, Lohle PN, Smeets A, et al. Pain management during uterine artery embolization for symptomatic uterine fibroids. Cardiovasc Intervent Radiol. 2007 Jul-Aug;30(4):809-11. doi: 10.1007/s00270-007-9069-7. PMID: 17533543. X-2

847. Leone FP, Bignardi T, Marciante C, et al. Sonohysterography in the preoperative grading of submucous myomas: considerations on three-dimensional methodology. Ultrasound Obstet Gynecol. 2007 Jun;29(6):717-8. doi: 10.1002/uog.4043. PMID: 17523152. X-1, X-1c, X-2

848. Lowenstein L, McClung C, Mueller E. Periurethral leiomyoma. Isr Med Assoc J. 2007 Jan;9(1):54. PMID: 17274362. X-1, X-3, X-3d

849. Mahajan NN. Comment on "Isobaric (gasless) laparoscopic uterine myomectomy--an overview" [Eur. J. Obstet. Gynecol. Reprod. Biol. 129 (2006) 9-14]. Eur J Obstet Gynecol Reprod Biol. 2007 May;132(1):133-4; author reply 4-5. doi: 10.1016/j.ejogrb.2006.12.019. PMID: 17291674. X-2

850. Mahajan NN, Gaikwad NL, Soni RN, et al. Extracorporeal ablation of uterine fibroids with high-intensity focused ultrasound. J Ultrasound Med. 2007 May;26(5):702; author reply PMID: 17460017. X-2

851. Marret H, Tranquart F, Herbreteau D, et al. [First treatment in France using high intensity focalised ultrasound for myomas ablation: fiction became reality!]. Gynecol Obstet Fertil. 2007 Sep;35(9):718-20. doi: 10.1016/j.gyobfe.2007.08.002. PMID: 17822935. X-2

852. Maruo T. Progesterone and progesterone receptor modulator in uterine leiomyoma growth. Gynecol Endocrinol. 2007 Apr;23(4):186-7. doi: 10.1080/09513590701350416. PMID: 17505936. X-2

853. McDaniel C. Uterine fibroid embolization: the less invasive alternative. Nursing. 2007 Jul;37(7):26-7. doi: 10.1097/01.NURSE.0000279411.31117.e1. PMID: 17603350. X-2, X-3, X-3d

854. Messina ML, Bozzini N, Baracat EC. Necrotic fibroid expulsion with intrauterine infection after uterine fibroid embolization. Int J Gynaecol Obstet. 2007 May;97(2):158-9. doi: 10.1016/j.ijgo.2007.02.008. PMID: 17376447. X-3, X-3d

855. Morita Y, Ito N, Ohashi H. Pregnancy following MR-guided focused ultrasound surgery for a uterine fibroid. Int J Gynaecol Obstet. 2007 Oct;99(1):56-7. doi: 10.1016/j.ijgo.2007.03.053. PMID: 17599842. X-3, X-3d

856. Muneyyirci-Delale O, Richard-Davis G, Morris T, et al. Goserelin acetate 10.8 mg plus iron versus iron monotherapy prior to surgery in premenopausal women with iron-deficiency anemia due to uterine leiomyomas: results from a Phase III, randomized, multicenter, double-blind, controlled trial. Clin Ther. 2007 Aug;29(8):1682-91. doi: 10.1016/j.clinthera.2007.08.024. PMID: 17919549. X-1, X-6, X-7

857. Narin MA, Caliskan E, Kayikcioglu F, et al. Blood loss and power Doppler ultrasound characteristics of uterine artery blood flow after 2 levels of bilateral internal iliac artery ligation before extensive myomectomies. J Reprod Med. 2007 Aug;52(8):696-702. PMID: 17879830. X-1, X-1e, X-6, X-7

858. Okonkwo JE, Udigwe GO. Myomectomy in pregnancy. J Obstet Gynaecol. 2007 Aug;27(6):628-30. doi: 10.1080/01443610701538372. PMID: 17896274. X-3, X-3d

859. Parashar A, Varma A, Bedi S. Treatment of symptomatic uterine fibroids. N Engl J Med. 2007 May 24;356(21):2218; author reply 9. doi: 10.1056/NEJMc070446. PMID: 17522408. X-2

860. Park SJ, Choi SJ, Han KH, et al. Leiomyoma of the vagina that caused cyclic urinary retention. Acta Obstet Gynecol Scand. 2007;86(1):102-4. doi: 10.1080/00016340500334828. PMID: 17230298. X-1, X-1g, X-3, X-3d

861. Parker WH. Sustained relief of leiomyoma symptoms by using focused ultrasound surgery. Obstet Gynecol. 2007 Nov;110(5):1173; author reply doi: 10.1097/01.AOG.0000289082.21561.1f. PMID: 17978140. X-2

862. Pelage JP. [Is uterine fibroid embolization an alternative to surgery?]. J Radiol. 2007 Jun;88(6):825-6. PMID: 17652976. X-2

863. Price N, Golding S, Slack RA, et al. Delayed presentation of vesicouterine fistula 12 months after uterine artery embolisation for uterine fibroids. J Obstet Gynaecol. 2007 Feb;27(2):205-7. doi: 10.1080/01443610601157273. PMID: 17454485. X-3, X-3d

864. Rathat G, Blanc PM, Guillon F, et al. [Intravascular leiomyomatosis: an original tumor]. Gynecol Obstet Fertil. 2007 Apr;35(4):323-6. doi: 10.1016/j.gyobfe.2006.12.018. PMID: 17336128. X-3, X-3d

865. Ricci P, Sola V, Pardo J, et al. Laparoscopic McCall culdoplasty. J Minim Invasive Gynecol. 2007 Jul-Aug;14(4):397-8. doi: 10.1016/j.jmig.2006.10.025. PMID: 17630155. X-1, X-1i, X-3, X-3c, X-3d

866. Salinas-Martin MV, Carranza-Carranza A, Mendoza-Garcia E. [Massive pseudo-lymphomatous lymphoid infiltrate and vasculitis in uterine leiomyoma treated with LH-RH analogues]. Med Clin (Barc). 2007 Jul 7;129(6):238. PMID: 17678609. X-1, X-1g, X-1i, X-2, X-3, X-3d

867. Senapati S, Advincula AP. Surgical techniques: robot-assisted laparoscopic myomectomy with the da Vinci surgical system. J Robot Surg. 2007;1(1):69-74. doi: 10.1007/s11701-007-0014-1. PMID: 25484940. X-2

868. Sheldon EC, Howe R, Selman T, et al. Uterine malignant mesenchymoma, arising in a leiomyoma, with pulmonary metastases. Histopathology. 2007 Feb;50(3):397-400. doi: 10.1111/j.1365-2559.2007.02589.x. PMID: 17257144. X-1, X-1g, X-3

869. Sherer DM, Cheung W, Gorelick C, et al. Sonographic and magnetic resonance imaging findings of an isolated vaginal leiomyoma. J Ultrasound Med. 2007 Oct;26(10):1453-6. PMID: 17901151. X-3, X-3d,

870. Silberzweig JE, Zidon M. Use of a 5-F tight curve catheter to facilitate uterine artery embolization. J Vasc Interv Radiol. 2007 Sep;18(9):1193-4. doi: 10.1016/j.jvir.2007.06.020. PMID: 17804785. X-2, X-3, X-3d

871. Singh SS, Bordman R, Leyland N. Pregnancy after uterine artery embolization for fibroids. Can Fam Physician. 2007 Feb;53(2):293-5. PMID: 17872647. X-2, X-3, X-3c

872. Spies JB. Sustained relief of leiomyoma symptoms by using focused ultrasound surgery. Obstet Gynecol. 2007 Dec;110(6):1427-8; author reply 8-9. doi: 10.1097/01.AOG.0000295979.81092.e5. PMID: 18055746. X-2

873. Tulandi T. Treatment of uterine fibroids--is surgery obsolete? N Engl J Med. 2007 Jan 25;356(4):411-3. doi: 10.1056/NEJMe068281. PMID: 17251539. X-2

874. Umezurike CC. Caesarean myomectomy in Aba, south-eastern Nigeria. Trop Doct. 2007 Apr;37(2):109-11. PMID: 17540098. X-3, X-3c, X-4

875. Usifo F, Macrae R, Sharma R, et al. Successful myomectomy in early second trimester of pregnancy. J Obstet Gynaecol. 2007 Feb;27(2):196-7. doi: 10.1080/01443610601137911. PMID: 17454479. X-3, X-3d

876. Wang CJ, Soong YK, Lee CL. Laparoscopic myomectomy for large intramural and submucous fibroids. Int J Gynaecol Obstet. 2007 Jun;97(3):206-7. doi: 10.1016/j.ijgo.2007.02.021. PMID: 17434517. X-3, X-3c, X-3f

877. Wang PH, Chao HT, Lee WL. Rationale of myomectomy for perimenopausal women. Maturitas. 2007 Dec 20;58(4):406-7. doi: 10.1016/j.maturitas.2007.10.001. PMID: 18022333. X-2

878. Watkinson A, Nicholson A. Uterine artery embolisation to treat symptomatic uterine fibroids. Bmj. 2007 Oct 6;335(7622):720-2. doi: 10.1136/bmj.39251.440069.AD. PMID: 17916857. X-2, X-3, X-3d

879. Williams AR, Critchley HO, Osei J, et al. The effects of the selective progesterone receptor modulator asoprisnil on the morphology of uterine tissues after 3 months treatment in patients with symptomatic uterine leiomyomata. Hum Reprod. 2007 Jun;22(6):1696-704. doi: 10.1093/humrep/dem026. PMID: 17339234. X-6, X-7

880. Agarwal K, Raghunandan C. Conservative management of placenta invading into leiomyoma. Indian J Med Sci. 2008 Jul;62(7):294-5. PMID: 18688116. X-1, X-1g, X-3, X-3d, X-4, X-5, X-6, X-7

881. Agdi M, Tulandi T. The benefits of intrauterine balloon: an intrauterine manipulator and balloon proved useful in myomectomy. Am J Obstet Gynecol. 2008 Nov;199(5):581.e1. doi: 10.1016/j.ajog.2008.07.042. PMID: 18984081. X-3, X-3d

882. Baik SH, Kim YT, Ko YT, et al. Simultaneous robotic total mesorectal excision and total abdominal hysterectomy for rectal cancer and uterine myoma. Int J Colorectal Dis. 2008 Feb;23(2):207-8. doi: 10.1007/s00384-007-0300-4. PMID: 17390143. X-2

883. Bara C, Pi L, Haverich A, et al. Echocardiography in leiomyomatosis of the uterus: how to guide your surgeon. Clin Res Cardiol. 2008 Feb;97(2):135-8. doi: 10.1007/s00392-007-0613-x. PMID: 18049830. X-2, X-3, X-3d

884. Bartnicki J, Poreba R. The position of laparoscopy in contemporary operative gynecology - Surgeries of myoma tumors. [Polish, English]. Ginekologia i Poloznictwo. 2008;8(2):58-68. PMID: 2010009670. X-2, X-3, X-3c

885. Bayya J, Minkoff H, Khulpateea N. Tamoxifen and growth of an extrauterine leiomyoma. Eur J Obstet Gynecol Reprod Biol. 2008 Nov;141(1):90-1. doi: 10.1016/j.ejogrb.2008.07.001. PMID: 18848745. X-1, X-1g, X-3, X-3d

886. Bhatia K, Doonan Y, Giannakou A, et al. A randomised controlled trial comparing GnRH antagonist cetrorelix with GnRH agonist leuprorelin for endometrial thinning prior to transcervical resection of endometrium. Bjog. 2008 Sep;115(10):1214-24. doi: 10.1111/j.1471-0528.2008.01837.x. PMID: 18715405. X-5

887. Caglar GS, Tasci Y, Kayikcioglu F, et al. Intravenous tranexamic acid use in myomectomy: a prospective randomized double-blind placebo controlled study. Eur J Obstet Gynecol Reprod Biol. 2008 Apr;137(2):227-31. doi: 10.1016/j.ejogrb.2007.04.003. PMID: 17499419. X-1, X-1e, X-7

888. Chen ZY, Jin HM, Shi HY. [Clinical efficacy of Gengxueting and its effect on estrogen receptor and progesterone receptor in patients with hysteromyoma]. Zhongguo Zhong Xi Yi Jie He Za Zhi. 2008 Mar;28(3):219-21. PMID: 18476420. X-1, X-1e

889. Ding DC, Hwang KS. Female acute urinary retention caused by anterior deflection of the cervix which was augmented by an uterine myoma. Taiwan J Obstet Gynecol. 2008 Sep;47(3):350-1. doi: 10.1016/s1028-4559(08)60141-2. PMID: 18936006. X-1, X-3, X-3d

890. Edozien LC. Costing magnetic resonance-guided focused ultrasound surgery, a new treatment for symptomatic fibroids. Bjog. 2008 Sep;115(10):1321. doi: 10.1111/j.1471-0528.2008.01835.x. PMID: 18715421. X-2

891. Fiscella K, Eisinger S. CDB-2914 for uterine leiomyomata treatment: a randomized controlled trial. Obstet Gynecol. 2008 Sep;112(3):707; author reply -8. doi: 10.1097/AOG.0b013e3181864943. PMID: 18757682. X-2, X-6, X-7

892. Haldar K, Izuwah-Njoku N, Warren M. Cervical leiomyosarcoma diagnosed after uterine artery embolization. Int J Gynaecol Obstet. 2008 May;101(2):197-8. doi: 10.1016/j.ijgo.2007.11.003. PMID: 18336821. X-3, X-3d

893. Jensen LL, Handberg G, Helbo-Hansen HS, et al. No morphine sparing effect of ketamine added to morphine for patient-controlled intravenous analgesia after uterine artery embolization. Acta Anaesthesiol Scand. 2008 Apr;52(4):479-86. doi: 10.1111/j.1399-6576.2008.01602.x. PMID: 18339153. X-6, X-7

894. Lee KH, Park TC, Park JS. Duplicated uterine arteries in laparoscopic hysterectomy. J Minim Invasive Gynecol. 2008 Jan-Feb;15(1):3. doi: 10.1016/j.jmig.2007.05.006. PMID: 18262135. X-1, X-1g, X-3, X-3d

895. Lim SS, Sockalingam JK, Tan PC. Goserelin versus leuprolide before hysterectomy for uterine fibroids. Int J Gynaecol Obstet. 2008 May;101(2):178-83. doi: 10.1016/j.ijgo.2007.10.020. PMID: 18164303. X-1, X-1e

896. Lin XN, Zhang SY, Fang SH, et al. [Assessment of different homeostatic methods used in laparoscopic intramural myomectomy]. Zhonghua Yi Xue Za Zhi. 2008 Apr 1;88(13):905-8. PMID: 18756957. X-7

897. Lowenstein L, Zimmer EZ, Deutsch M, et al. Preoperative analgesia with local lidocaine infiltration for abdominal hysterectomy pain management. Eur J Obstet Gynecol Reprod Biol. 2008 Feb;136(2):239-42. doi: 10.1016/j.ejogrb.2006.11.008. PMID: 17178187. X-1, X-1h, X-6, X-7

898. Manyonda IT, Gorti M. Costing magnetic resonance-guided focused ultrasound surgery, a new treatment for symptomatic fibroids. Bjog. 2008 Apr;115(5):551-3. doi: 10.1111/j.1471-0528.2007.01656.x. PMID: 18333935. X-2

899. Marque M, Avril MF, Bressac de Paillerets B, et al. [Familial cutaneous and uterine leiomyomatosis]. Ann Dermatol Venereol. 2008 Aug-Sep;135(8-9):612-6. doi: 10.1016/j.annder.2008.04.010. PMID: 18789302. X-2, X-3, X-3d

900. Matsuo K, Rosenshein NB, Im DD. The big seep. Am J Obstet Gynecol. 2008 Jan;198(1):145.e1-2. doi: 10.1016/j.ajog.2007.10.805. PMID: 18166332. X-3, X-3d

901. Mettler L, Hucke J, Bojahr B, et al. A safety and efficacy study of a resorbable hydrogel for reduction of post-operative adhesions following myomectomy. Hum Reprod. 2008 May;23(5):1093-100. doi: 10.1093/humrep/den080. PMID: 18346996. X-6, X-7

902. Pakiz M, But I. Uterine artery embolization for symptomatic uterine fibroids. Int J Gynaecol Obstet. 2008 Apr;101(1):81-2. doi: 10.1016/j.ijgo.2007.09.025. PMID: 18045603. X-2, X-3, X-3c

903. Pan HS, Ko ML, Huang LW, et al. Total laparoscopic hysterectomy (TLH) versus coagulation of uterine arteries (CUA) at their origin plus total laparoscopic hysterectomy (TLH) for the management of myoma and adenomyosis. Minim Invasive Ther Allied Technol. 2008;17(5):318-22. doi: 10.1080/13645700802274588. PMID: 18850461. X-5, X-7

904. Rasuli P, Hammond I, Al-Mutairi B, et al. Spherical versus conventional polyvinyl alcohol particles for uterine artery embolization. J Vasc Interv Radiol. 2008 Jan;19(1):42-6. doi: 10.1016/j.jvir.2007.08.016. PMID: 18192466. X-3, X-3a, X-3f

905. Simms-Stewart D, Frederick S, Fletcher H, et al. Postmenopausal uterine inversion treated by subtotal hysterectomy. J Obstet Gynaecol. 2008 Jan;28(1):116-7. doi: 10.1080/01443610701844366. PMID: 18259922. X-3, X-3d

906. Singh A, Bansal S. Comparative study of morbidity and mortality associated with nondescent vaginal hysterectomy and abdominal hysterectomy based on ultrasonographic determination of uterine volume. Int Surg. 2008 Mar-Apr;93(2):88-94. PMID: 18998287. X-4

907. Ter Haar G. Harnessing the interaction of ultrasound with tissue for therapeutic benefit: high-intensity focused ultrasound. Ultrasound Obstet Gynecol. 2008 Oct;32(5):601-4. doi: 10.1002/uog.6228. PMID: 18816466. X-2

908. van Dongen H, Emanuel MH, Wolterbeek R, et al. Hysteroscopic morcellator for removal of intrauterine polyps and myomas: a randomized controlled pilot study among residents in training. J Minim Invasive Gynecol. 2008 Jul-Aug;15(4):466-71. doi: 10.1016/j.jmig.2008.02.002. PMID: 18588849. X-5, X-6, X-7

909. Wilkens J, Chwalisz K, Han C, et al. Effects of the selective progesterone receptor modulator asoprisnil on uterine artery blood flow, ovarian activity, and clinical symptoms in patients with uterine leiomyomata scheduled for hysterectomy. J Clin Endocrinol Metab. 2008 Dec;93(12):4664-71. doi: 10.1210/jc.2008-1104. PMID: 18765509. X-1, X-1e, X-7

910. Zaher S, Gedroyc WM. Costing magnetic resonance guided focused ultrasound surgery. Bjog. 2008 Aug;115(9):1191-2. doi: 10.1111/j.1471-0528.2008.01798.x. PMID: 18715451. X-2

911. Alborzi S, Ghannadan E, Alborzi S, et al. A comparison of combined laparoscopic uterine artery ligation and myomectomy versus laparoscopic myomectomy in treatment of symptomatic myoma. Fertil Steril. 2009 Aug;92(2):742-7. doi: 10.1016/j.fertnstert.2008.06.011. PMID: 18692826. X-3, X-3a

912. Al-Shabibi N, Chapman L, Madari S, et al. Prospective randomised trial comparing gonadotrophin-releasing hormone analogues with triple tourniquets at open myomectomy. Bjog. 2009 Apr;116(5):681-7. doi: 10.1111/j.1471-0528.2008.02022.x. PMID: 19191779. X-1, X-1e, X-7

913. Ambat S, Mittal S, Srivastava DN, et al. Uterine artery embolization versus laparoscopic occlusion of uterine vessels for management of symptomatic uterine fibroids. Int J Gynaecol Obstet. 2009 May;105(2):162-5. doi: 10.1016/j.ijgo.2009.01.006. PMID: 19232612. X-4

914. Andrews RT, Spies JB, Sacks D, et al. Patient care and uterine artery embolization for leiomyomata. J Vasc Interv Radiol. 2009 Jul;20(7 Suppl):S307-11. doi: 10.1016/j.jvir.2009.04.002. PMID: 19560015. X-2

915. Bagaria M, Suneja A, Vaid NB, et al. Low-dose mifepristone in treatment of uterine leiomyoma: a randomised double-blind placebo-controlled clinical trial. Aust N Z J Obstet Gynaecol. 2009 Feb;49(1):77-83. doi: 10.1111/j.1479-828X.2008.00931.x. PMID: 19281585. X-4

916. Berg A, Sandvik L, Langebrekke A, et al. A randomized trial comparing monopolar electrodes using glycine 1.5% with two different types of bipolar electrodes (TCRis, Versapoint) using saline, in hysteroscopic surgery. Fertil Steril. 2009 Apr;91(4):1273-8. doi: 10.1016/j.fertnstert.2008.01.083. PMID: 18371962. X-1, X-1h, X-5, X-6, X-7

917. Bukar M, Audu BM, Mustapha Z, et al. Uterine leiomyosarcoma arising from a fibroid. J Obstet Gynaecol. 2009 Feb;29(2):169-70. doi: 10.1080/01443610802648971. PMID: 19274567. X-1, X-1g, X-3, X-3d

918. Cheng C, Zhao T, Xue M, et al. Use of suction curettage in operative hysteroscopy. J Minim Invasive Gynecol. 2009 Nov-Dec;16(6):739-42. doi: 10.1016/j.jmig.2009.07.010. PMID: 19896601. X-6, X-7

919. Chrisman HB, Rajeswaran S, Dhand S, et al. Effect of postprocedural pelvic MR imaging on medical decision-making in women who have undergone uterine artery embolization. J Vasc Interv Radiol. 2009 Jul;20(7):977-80. doi: 10.1016/j.jvir.2009.03.041. PMID: 19497764. X-1, X-3, X-3c, X-3f

920. Coddington CC, Grow DR, Ahmed MS, et al. Gonadotropin-releasing hormone agonist pretreatment did not decrease postoperative adhesion formation after abdominal myomectomy in a randomized control trial. Fertil Steril. 2009 May;91(5):1909-13. doi: 10.1016/j.fertnstert.2008.02.128. PMID: 18439584. X-1, X-1e, X-7

921. Engman M, Granberg S, Williams AR, et al. Mifepristone for treatment of uterine leiomyoma. A prospective randomized placebo controlled trial. Hum Reprod. 2009 Aug;24(8):1870-9. doi: 10.1093/humrep/dep100. PMID: 19389793. X-6, X-7

922. Goodwin SC, Spies JB. Uterine fibroid embolization. N Engl J Med. 2009 Aug 13;361(7):690-7. doi: 10.1056/NEJMct0806942. PMID: 19675331. X-2, X-3, X-3d

923. Halpern M, Jesmajian S, Rubin M. Uterine fibroid embolization. N Engl J Med. 2009 Dec 3;361(23):2293-4; author reply 4. PMID: 19967821. X-2

924. Hellebrekers BW, Trimbos-Kemper TC, Boesten L, et al. Preoperative predictors of postsurgical adhesion formation and the Prevention of Adhesions with Plasminogen Activator (PAPA-study): results of a clinical pilot study. Fertil Steril. 2009 Apr;91(4):1204-14. doi: 10.1016/j.fertnstert.2008.01.052. PMID: 18353314. X-6, X-7

925. Kim HS, Kim JW, Kim MK, et al. A randomized prospective trial of the postoperative quality of life between laparoscopic uterine artery ligation and laparoscopy-assisted vaginal hysterectomy for the treatment of symptomatic uterine fibroids: clinical trial design. Trials. 2009;10:8. doi: 10.1186/1745-6215-10-8. PMID: 19178748. X-2, X-6, X-7

926. Raga F, Sanz-Cortes M, Bonilla F, et al. Reducing blood loss at myomectomy with use of a gelatin-thrombin matrix hemostatic sealant. Fertil Steril. 2009 Jul;92(1):356-60. doi: 10.1016/j.fertnstert.2008.04.038. PMID: 19423098. X-1, X-7

927. Ren XL, Zhou XD, Yan RL, et al. Sonographically guided extracorporeal ablation of uterine fibroids with high-intensity focused ultrasound: midterm results. J Ultrasound Med. 2009 Jan;28(1):100-3. PMID: 19106367. X-2, X-3, X-3c

928. Rosen DM, Hamani Y, Cario GM, et al. Uterine perfusion following laparoscopic clipping of uterine arteries at myomectomy. Aust N Z J Obstet Gynaecol. 2009 Oct;49(5):559-60. doi: 10.1111/j.1479-828X.2009.01046.x. PMID: 19780746. X-3, X-3d

929. Silva-Filho AL, Rodrigues AM, Vale de Castro Monteiro M, et al. Randomized study of bipolar vessel sealing system versus conventional suture ligature for vaginal hysterectomy. Eur J Obstet Gynecol Reprod Biol. 2009 Oct;146(2):200-3. doi: 10.1016/j.ejogrb.2009.03.014. PMID: 19380188. X-7

930. Talaulikar V, Gorti M, Manyonda I. Prospective randomised trial comparing gonadotrophin-releasing hormone analogues with triple tourniquets at open myomectomy. Bjog. 2009 Oct;116(11):1531; author reply 2. doi: 10.1111/j.1471-0528.2009.02246.x. PMID: 19769751. X-2

931. Varma R, Soneja H, Clark TJ, et al. Hysteroscopic myomectomy for menorrhagia using Versascope bipolar system: efficacy and prognostic factors at a minimum of one year follow up. Eur J Obstet Gynecol Reprod Biol. 2009 Feb;142(2):154-9. doi: 10.1016/j.ejogrb.2008.10.006. PMID: 19036492. X-3, X-3a

932. Walsh CA. Uterine fibroid embolization. N Engl J Med. 2009 Dec 3;361(23):2292-3; author reply 4. doi: 10.1056/NEJMc091839. PMID: 19955532. X-2

933. Yue Q, Ma R, Mao DW, et al. Effects of laparoscopically-assisted vaginal hysterectomy compared with abdominal hysterectomy on immune function. J Int Med Res. 2009 May-Jun;37(3):855-61. PMID: 19589270. X-6, X-7

934. Abd El Fatah GH, Elhamamsy MH, Abd El Khalek MS, et al. Fibroid therapy. Internet Journal of Gynecology and Obstetrics. 2010;13(1) PMID: 2010367869. X-4

935. Agarwal R, Radhika AG, Malik R, et al. Cotyledonoid leiomyoma and non-descent vaginal hysterectomy. Arch Gynecol Obstet. 2010 May;281(5):971-2. doi: 10.1007/s00404-009-1274-y. PMID: 19885668. X-1, X-2, X-3

936. Ahn EH, Matsuo K. Area of uncertainty in uterine arterial embolization: does it increase the risk of ovarian cancer? J Obstet Gynaecol Res. 2010 Aug;36(4):920. doi: 10.1111/j.1447-0756.2010.01216.x. PMID: 20666971. X-2

937. Alessandri F, Remorgida V, Venturini PL, et al. Unidirectional barbed suture versus continuous suture with intracorporeal knots in laparoscopic myomectomy: a randomized study. J Minim Invasive Gynecol. 2010 Nov-Dec;17(6):725-9. doi: 10.1016/j.jmig.2010.06.007. PMID: 20674510. X-7

938. Allison SJ, Wolfman DJ. Sonographic evaluation of patients treated with uterine artery embolization. Ultrasound Clinics. 2010 April;5(2):277-88. doi: http://dx.doi.org/10.1016/j.cult.2010.03.004. PMID: 2010503484. X-2

939. Al-Shabibi N, Korkontzelos I, Gkioulekas N, et al. Cable ties as tourniquets at open myomectomy. Int J Gynaecol Obstet. 2010 Sep;110(3):265-6. doi: 10.1016/j.ijgo.2010.04.017. PMID: 20646705. X-2, X-3, X-3c

940. Cavkaytar S, Karaer A, Ozbagi T. Primary ovarian leiomyoma in a postmenopausal woman. J Obstet Gynaecol. 2010;30(7):746-7. doi: 10.3109/01443615.2010.501924. PMID: 20925633. X-1, X-1g, X-3, X-3d

941. Costantino M, Lee J, McCullough M, et al. Bilateral versus unilateral femoral access for uterine artery embolization: results of a randomized comparative trial. J Vasc Interv Radiol. 2010 Jun;21(6):829-35; quiz 35. doi: 10.1016/j.jvir.2010.01.042. PMID: 20399113. X-6, X-7

942. Csatlos E, Rigo J, Jr., Szabo I, et al. [Uterine leiomyoma]. Orv Hetil. 2010 Oct 17;151(42):1734-41. doi: 10.1556/oh.2010.28977. PMID: 20889441. X-2

943. Darwish AM, Hassan ZZ, Attia AM, et al. Biological effects of distension media in bipolar versus monopolar resectoscopic myomectomy: a randomized trial. J Obstet Gynaecol Res. 2010 Aug;36(4):810-7. doi: 10.1111/j.1447-0756.2010.01244.x. PMID: 20666950. X-4

944. Ding DC, Chu TY, Hsu YH. Lipoleiomyoma of the uterus. Taiwan J Obstet Gynecol. 2010 Mar;49(1):94-6. doi: 10.1016/s1028-4559(10)60018-6. PMID: 20466302. X-3, X-3d

945. Disu S, Kalu E. The effects of uterine artery embolisation and surgical treatment on ovarian function in women with uterine fibroids. Bjog. 2010 Dec;117(13):1663; author reply -4. doi: 10.1111/j.1471-0528.2010.02747.x. PMID: 21078059. X-2

946. Emons G, Kiesel L, Runnebaum I, et al. [Comment by the AGO Uterus Committee on the consensus publication of the 3rd Radiologic-Gynecologic Expert Assembly on the treatment of uterine leiomyoma by uterine artery embolization in Munich 15 January 2010]. Rofo. 2010 Nov;182(11):1016; author reply -7. doi: 10.1055/s-0029-1245774. PMID: 21031324. X-2

947. Ferrero S, Venturini PL, Remorgida V. Letrozole monotherapy in the treatment of uterine myomas. Fertil Steril. 2010 May 1;93(7):e31; author reply e2. doi: 10.1016/j.fertnstert.2010.01.072. PMID: 20356584. X-2

948. Gibson E, Schreiber CA. When uterine leiomyomas complicate uterine evacuation. Contraception. 2010 Dec;82(6):486-8. doi: 10.1016/j.contraception.2010.02.021. PMID: 21074008. X-2

949. Helal A, Mashaly Ael M, Amer T. Uterine artery occlusion for treatment of symptomatic uterine myomas. Jsls. 2010 Jul-Sep;14(3):386-90. doi: 10.4293/108680810x12924466007403. PMID: 21333193. X-4

950. Helal AS, Abdel-Hady el S, Refaie E, et al. Preliminary uterine artery ligation versus pericervical mechanical tourniquet in reducing hemorrhage during abdominal myomectomy. Int J Gynaecol Obstet. 2010 Mar;108(3):233-5. doi: 10.1016/j.ijgo.2009.09.022. PMID: 19945103. X-4

951. Jashnani KD, Kini S, Dhamija G. Perinodular hydropic degeneration in leiomyoma: an alarming histology. Indian J Pathol Microbiol. 2010 Jan-Mar;53(1):173-5. doi: 10.4103/0377-4929.59223. PMID: 20090262. X-3, X-3c, X-3d

952. Kalogiannidis I, Prapas N, Xiromeritis P, et al. Laparoscopically assisted myomectomy versus abdominal myomectomy in short-term outcomes: a prospective study. Arch Gynecol Obstet. 2010 May;281(5):865-70. doi: 10.1007/s00404-009-1187-9. PMID: 19655158. X-3, X-3a, X-3c

953. Kraemer B, Wallwiener M, Brochhausen C, et al. A pilot study of laparoscopic adhesion prophylaxis after myomectomy with a copolymer designed for endoscopic application. J Minim Invasive Gynecol. 2010 Mar-Apr;17(2):222-7. doi: 10.1016/j.jmig.2009.12.018. PMID: 20226412. X-1, X-1h, X-3, X-3f, X-7

954. Lee SL, Huang LW, Chang JZ, et al. Pelvic abscess after laparoscopic myomectomy with vaginal extraction. Taiwan J Obstet Gynecol. 2010 Dec;49(4):528-30. doi: 10.1016/s1028-4559(10)60112-x. PMID: 21199762. X-1, X-1g, X-3, X-3d

955. Li YT, Chang WH, Wang PH. Laparoscopy-aided myomectomy. J Obstet Gynaecol Res. 2010 Aug;36(4):922. doi: 10.1111/j.1447-0756.2010.01261.x. PMID: 20666973. X-2

956. Litta P, Fantinato S, Calonaci F, et al. A randomized controlled study comparing harmonic versus electrosurgery in laparoscopic myomectomy. Fertil Steril. 2010 Oct;94(5):1882-6. doi: 10.1016/j.fertnstert.2009.08.049. PMID: 19819439. X-7

957. Longano AB, Beech PA, Nelva P. p16 staining of subcutaneous smooth muscle tumours. Pathology. 2010 Feb;42(2):173-4. doi: 10.3109/00313020903494482. PMID: 20085520. X-1, X-1d, X-1h, X-2, X-3

958. Madelenat P. [Peri- or post-menopausal myomectomy: the pros]. Gynecol Obstet Fertil. 2010 Nov;38(11):705-8. doi: 10.1016/j.gyobfe.2010.09.013. PMID: 21067962. X-2

959. Majumdar A, Saleh S, Bird A, et al. Successful conservative management of inversion of a fibroid uterus by hydrostatic balloon. J Obstet Gynaecol. 2010 Feb;30(2):202-3. doi: 10.3109/01443610903440901. PMID: 20143989. X-3, X-3d

960. Mardi K, Kaushal V, Gupta S. Foregut duplication cysts of stomach masquerading as leiomyoma. Indian J Pathol Microbiol. 2010 Jan-Mar;53(1):160-1. doi: 10.4103/0377-4929.59214. PMID: 20090253. X-1, X-1g, X-1i

961. Marret H. [Peri- or postmenopausal myomectomy: the cons]. Gynecol Obstet Fertil. 2010 Nov;38(11):700-4. doi: 10.1016/j.gyobfe.2010.09.004. PMID: 21050791. X-2

962. Mavrelos D, Ben-Nagi J, Davies A, et al. The value of pre-operative treatment with GnRH analogues in women with submucous fibroids: a double-blind, placebo-controlled randomized trial. Hum Reprod. 2010 Sep;25(9):2264-9. doi: 10.1093/humrep/deq188. PMID: 20663795. X-1, X-1e, X-6, X-7

963. Mukhamed'ianov IF, Fedorov SV. [Clinical aspects of uterine artery embolization efficacy in uterine myomas]. Angiol Sosud Khir. 2010;16(2):43-6. PMID: 21032872. X-2, X-3, X-3c

964. Murat Naki M, Tekcan C, Ozcan N, et al. Levonorgestrel-releasing intrauterine device insertion ameliorates leiomyoma-dependent menorrhagia among women of reproductive age without a significant regression in the uterine and leiomyoma volumes. Fertil Steril. 2010 Jun;94(1):371-4. doi: 10.1016/j.fertnstert.2009.09.048. PMID: 19896649. X-3, X-3c

965. Muzii L, Boni T, Bellati F, et al. GnRH analogue treatment before hysteroscopic resection of submucous myomas: a prospective, randomized, multicenter study. Fertil Steril. 2010 Sep;94(4):1496-9. doi: 10.1016/j.fertnstert.2009.05.070. PMID: 19541299. X-1, X-1e, X-7

966. Shokeir T, El-Shafei M, Yousef H, et al. Submucous myomas and their implications in the pregnancy rates of patients with otherwise unexplained primary infertility undergoing hysteroscopic myomectomy: a randomized matched control study. Fertil Steril. 2010 Jul;94(2):724-9. doi: 10.1016/j.fertnstert.2009.03.075. PMID: 19406399. X-4

967. Tulandi T, Salamah K. Fertility and uterine artery embolization. Obstet Gynecol. 2010 Apr;115(4):857-60. doi: 10.1097/AOG.0b013e3181d4891e. PMID: 20308848. X-1, X-1g, X-2, X-3, X-3d, X-6, X-7

968. Walid MS, Heaton RL. Total laparoscopic hysterectomy for uteri over one kilogram. Jsls. 2010 Apr-Jun;14(2):178-82. doi: 10.4293/108680810x12785289143837. PMID: 20932364. X-3, X-3a, X-3c

969. Yen MS, Chao KC, Wang PH. Laparoscopic myomectomy. Taiwan J Obstet Gynecol. 2010 Sep;49(3):392-3. doi: 10.1016/s1028-4559(10)60086-1. PMID: 21056336. X-2

970. Youssef R, Chien PF, Coates P, et al. Transient ureteric obstruction as a possible complication of resection of submucous fibroid and endometrial rollerball ablation. Eur J Obstet Gynecol Reprod Biol. 2010 Feb;148(2):206-7. doi: 10.1016/j.ejogrb.2009.10.011. PMID: 19939548. X-1, X-2, X-3

971. Zullo F, Falbo A, Iuliano A, et al. Randomized controlled study comparing the Gynecare Morcellex and Rotocut G1 tissue morcellators. J Minim Invasive Gynecol. 2010 Mar-Apr;17(2):192-9. doi: 10.1016/j.jmig.2009.11.009. PMID: 20226407. X-7

972. . Treating uterine fibroids using MR-guided ultrasound. Manag Care. 2011 Dec;20(12):12-3. PMID: 22259871. X-2

973. . [Diagnosis and treatment of uterine myomatosis]. Ginecol Obstet Mex. 2011 Nov;79(11):711-8. PMID: 22168118. X-2

974. Arena S, Zupi E. Heavy menstrual bleeding: considering the most effective treatment option. Womens Health (Lond Engl). 2011 Mar;7(2):143-6. doi: 10.2217/whe.11.1. PMID: 21410340. X-2

975. Bouwsma EV, Hesley GK, Woodrum DA, et al. Comparing focused ultrasound and uterine artery embolization for uterine fibroids-rationale and design of the Fibroid Interventions: reducing symptoms today and tomorrow (FIRSTT) trial. Fertil Steril. 2011 Sep;96(3):704-10. doi: 10.1016/j.fertnstert.2011.06.062. PMID: 21794858. X-2

976. Catherino WH, Parrott E, Segars J. Proceedings from theNational Institute of Child Health and Human Development conference on the Uterine Fibroid Research Update Workshop. Fertil Steril. 2011 Jan;95(1):9-12. doi: 10.1016/j.fertnstert.2010.08.049. PMID: 20883986. X-2

977. Chang WC, Chou LY, Chang DY, et al. Simultaneous laparoscopic uterine artery ligation and laparoscopic myomectomy for symptomatic uterine myomas with and without in situ morcellation. Hum Reprod. 2011 Jul;26(7):1735-40. doi: 10.1093/humrep/der142. PMID: 21540245. X-3, X-3a

978. Eckey T, Neumann A, Bohlmann MK, et al. [Non-invasive thermoablation of symptomatic uterine fibroids with magnetic resonance-guided high-energy ultrasound]. Radiologe. 2011 Jul;51(7):610-9. doi: 10.1007/s00117-010-2117-3. PMID: 21660621. X-2, X-3, X-3c

979. El Behery MM, Zaitoun MM, Siam S, et al. Three-dimensional power Doppler study of changes in uterine vascularity after absorbable cervical tourniquet during open myomectomy. Arch Gynecol Obstet. 2011 Jul;284(1):157-61. doi: 10.1007/s00404-010-1615-x. PMID: 20700742. X-4

980. Fennessy FM, Tempany CM, Jolesz FA, et al. Re: "ACR Appropriateness Criteria(R) on treatment of uterine leiomyomas". J Am Coll Radiol. 2011 Sep;8(9):e1-2; author reply e-3. doi: 10.1016/j.jacr.2011.06.017. PMID: 21889739. X-1, X-2, X-3

981. Fernandez H. [Update of myoma management - introduction]. J Gynecol Obstet Biol Reprod (Paris). 2011 Dec;40(8):856. doi: 10.1016/j.jgyn.2011.09.017. PMID: 22056187. X-2

982. Fossum GT, Silverberg KM, Miller CE, et al. Gynecologic use of Sepraspray Adhesion Barrier for reduction of adhesion development after laparoscopic myomectomy: a pilot study. Fertil Steril. 2011 Aug;96(2):487-91. doi: 10.1016/j.fertnstert.2011.05.081. PMID: 21718999. X-1, X-1h, X-6, X-7

983. Fritel X. [Update of myoma management - method and organization]. J Gynecol Obstet Biol Reprod (Paris). 2011 Dec;40(8):857. doi: 10.1016/j.jgyn.2011.09.018. PMID: 22056191. X-2

984. Gambadauro P, Magos A. Endoscopic loops for laparoscopic myomectomy. Fertil Steril. 2011 Feb;95(2):e12; author reply e3. doi: 10.1016/j.fertnstert.2010.11.042. PMID: 21144507. X-2

985. Garza-Leal JG, Toub D, Leon IH, et al. Transcervical, intrauterine ultrasound-guided radiofrequency ablation of uterine fibroids with the VizAblate System: Safety, tolerability, and ablation results in a closed abdomen setting. Gynecological Surgery. 2011 September;8(3):327-34. doi: http://dx.doi.org/10.1007/s10397-010-0655-3. PMID: 2011593070. X-3, X-3a

986. Ghaffar N, Rahim M, Baloch SN. Morbidity and mortality associated with vaaginal hysterectomy. Medical Forum Monthly. 2011 May;22(5):39-43. PMID: 2011304820. X-3, X-3a, X-3c

987. Gillaux C, Panel P. [Surgical treatment of subserosal fibroids: the pros]. Gynecol Obstet Fertil. 2011 Jul-Aug;39(7-8):458-61. doi: 10.1016/j.gyobfe.2011.05.011. PMID: 21752684. X-2

988. Jung SG, Yoon SW, Park H, et al. Potential exploratory use of MR-guided focused ultrasound for disconnection of symptomatic intracavitary submucosal uterine myoma. J Vasc Interv Radiol. 2011 Nov;22(11):1635-7. doi: 10.1016/j.jvir.2011.07.009. PMID: 22024122. X-2, X-3, X-3d

989. Kalogiannidis I, Xiromeritis P, Prapas N, et al. Intravaginal misoprostol reduces intraoperative blood loss in minimally invasive myomectomy: a randomized clinical trial. Clin Exp Obstet Gynecol. 2011;38(1):46-9. PMID: 21485725. X-1e

990. Kamrava A, Abbas MA, Katz DS. Infralevator leiomyoma. Tech Coloproctol. 2011 Mar;15(1):127-8. doi: 10.1007/s10151-010-0653-5. PMID: 21086014. X-1, X-1g, X-3, X-3d

991. Kim YS, Bae DS, Kim BG, et al. A faster nonsurgical solution very large fibroid tumors yielded to a new ablation strategy. Am J Obstet Gynecol. 2011 Sep;205(3):292.e1-5. doi: 10.1016/j.ajog.2011.07.019. PMID: 22071069. X-3, X-3c, X-3d

992. Larson CA. Evidence-based medicine: An analysis of prophylactic bilateral oophorectomy at time of hysterectomy for benign conditions. Current Oncology. 2011;18(1):13-5. PMID: 2011082991. X-1, X-2

993. Laughlin SK, Stewart EA. Uterine leiomyomas: individualizing the approach to a heterogeneous condition. Obstet Gynecol. 2011 Feb;117(2 Pt 1):396-403. doi: 10.1097/AOG.0b013e31820780e3. PMID: 21252757. X-2

994. Li MH, Leng JH, Shi JH, et al. [Comparison of postoperative residue, recurrence and pregnancy outcome between laparoscopic and transabdominal myomectomy]. Zhonghua Fu Chan Ke Za Zhi. 2011 Sep;46(9):669-73. PMID: 22176991. X-3, X-3a, X-3f

995. Lipszyc M, Winters E, Engelman E, et al. Remifentanil patient-controlled analgesia effect-site target-controlled infusion compared with morphine patient-controlled analgesia for treatment of acute pain after uterine artery embolization. Br J Anaesth. 2011 May;106(5):724-31. doi: 10.1093/bja/aer041. PMID: 21441549. X-6, X-7

996. Marret H, Ouldamer L. [Surgical treatment of subserosal fibroids: the cons]. Gynecol Obstet Fertil. 2011 Jul-Aug;39(7-8):454-7. doi: 10.1016/j.gyobfe.2011.05.012. PMID: 21752689. X-2

997. Mitidieri M, Cosma S, Petruzzelli P, et al. Laparotomic myomectomy: B-Lynch suture to avoid hysterectomy. Eur J Obstet Gynecol Reprod Biol. 2011 Nov;159(1):238-40. doi: 10.1016/j.ejogrb.2011.07.013. PMID: 21831506. X-2, X-3, X-3d

998. Oehler MK, Scopacasa L, Brown M, et al. Intravenous uterine leiomyomatosis extending into the right heart. Aust N Z J Obstet Gynaecol. 2011 Feb;51(1):92-4. doi: 10.1111/j.1479-828X.2010.01249.x. PMID: 21299517. X-1, X-1g, X-3, X-3d

999. Sayed GH, Zakherah MS, El-Nashar SA, et al. A randomized clinical trial of a levonorgestrel-releasing intrauterine system and a low-dose combined oral contraceptive for fibroid-related menorrhagia. Int J Gynaecol Obstet. 2011 Feb;112(2):126-30. doi: 10.1016/j.ijgo.2010.08.009. PMID: 21092958. X-4

1000. Tinelli A, Malvasi A, Guido M, et al. Adhesion formation after intracapsular myomectomy with or without adhesion barrier. Fertil Steril. 2011 Apr;95(5):1780-5. doi: 10.1016/j.fertnstert.2010.12.049. PMID: 21256483. X-6, X-7

1001. Wang ZB. [To develop technique of ultrasound ablation, to promote minimal invasive surgery]. Zhonghua Fu Chan Ke Za Zhi. 2011 Jun;46(6):401-2. PMID: 21781576. X-2

1002. Williams PL, Coote JM, Watkinson AF. Pre-uterine artery embolization MRI: beyond fibroids. Cardiovasc Intervent Radiol. 2011 Dec;34(6):1143-50. doi: 10.1007/s00270-011-0124-z. PMID: 21331454. X-2

1003. Wilson C. Uterine fibroids: clinical and surgical management. Adv NPs PAs. 2011 Aug;2(8):46. PMID: 21853645. X-2

1004. Xiromeritis P, Kalogiannidis I, Papadopoulos E, et al. Improved recovery using multimodal perioperative analgesia in minimally invasive myomectomy: a randomised study. Aust N Z J Obstet Gynaecol. 2011 Aug;51(4):301-6. doi: 10.1111/j.1479-828X.2011.01333.x. PMID: 21806591. X-1, X-6, X-7

1005. Yesilkaya Y, Demirbas B, Kilincer A, et al. Primary anterior abdominal wall leiomyoma. Am Surg. 2011 Sep;77(9):E208-9. PMID: 21944613. X-2, X-3, X-3d

1006. . Uterine artery embolization. Clin Privil White Pap. 2012 Jul(63):1-12. PMID: 23082340. X-2

1007. . An emergency contraceptive pill helps treat fibroids. Harv Womens Health Watch. 2012 Apr;19(8):6. PMID: 22649808. X-2

1008. Aydin C, Yildiz A, Kasap B, et al. Efficacy of electrosurgical bipolar vessel sealing for abdominal hysterectomy with uterine myomas more than 14 weeks in size: a randomized controlled trial. Gynecol Obstet Invest. 2012;73(4):326-9. doi: 10.1159/000336400. PMID: 22517057. X-7

1009. Badiu D. Uterine myoma and infertility. Gineco.ro. 2012;8(3):103. PMID: 2013069244. X-1, X-2

1010. Buckley BT. Uterine artery embolisation: challenges and opportunities in cross-specialty care. Aust N Z J Obstet Gynaecol. 2012 Apr;52(2):103-5. doi: 10.1111/j.1479-828X.2012.01431.x. PMID: 22469021. X-1, X-1h, X-2

1011. Carbonell Esteve JL, Riveron AM, Cano M, et al. Mifepristone 2.5 mg versus 5 mg daily in the treatment of leiomyoma before surgery. Int J Womens Health. 2012;4:75-84. doi: 10.2147/ijwh.s28103. PMID: 22448109. X-4, X-7

1012. Croxtall JD. Ulipristal acetate: in uterine fibroids. Drugs. 2012 May 28;72(8):1075-85. doi: 10.2165/11209400-000000000-00000. PMID: 22568731. X-2

1013. Di Nardo MA, Annunziata ML, Ammirabile M, et al. Pelvic adhesion and gonadotropin-releasing hormone analogue: effects of triptorelin acetate depot on coagulation and fibrinolytic activities. Reprod Sci. 2012 Jun;19(6):615-22. doi: 10.1177/1933719111428517. PMID: 22344729. X-6, X-7

1014. Fletcher H, Burrell C, Bassaw B, et al. Complications of uterine fibroids and their management. Obstet Gynecol Int. 2012;2012:932436. doi: 10.1155/2012/932436. PMID: 22529859. X-1, X-2, X-3

1015. Garcia L, Isaacson K. Utero-ovarian vessel after uterine artery embolization. J Minim Invasive Gynecol. 2012 Jan-Feb;19(1):12. doi: 10.1016/j.jmig.2011.06.015. PMID: 22196257. X-3, X-3d

1016. Goldman KN, Hirshfeld-Cytron JE, Pavone ME, et al. Uterine artery embolization immediately preceding laparoscopic myomectomy. Int J Gynaecol Obstet. 2012 Feb;116(2):105-8. doi: 10.1016/j.ijgo.2011.08.022. PMID: 22098788. X-3, X-3e, X-3f

1017. Hudecek R, Ivanova Z, Smerdova M, et al. [Effect of GnRH analogues pre-treatment on myomectomy outcomes in reproductive age women]. Ceska Gynekol. 2012 Apr;77(2):109-17. PMID: 22702067. X-1, X-1e, X-3, X-3f

1018. Kitson SJ, Macphail S, Bulmer J. Is pregnancy safe after uterine artery embolisation? Bjog. 2012 Apr;119(5):519-21. doi: 10.1111/j.1471-0528.2012.03286.x. PMID: 22329577. X-2

1019. Lee MS, Kim MD, Lee M, et al. Contrast-enhanced MR angiography of uterine arteries for the prediction of ovarian artery embolization in 349 patients. J Vasc Interv Radiol. 2012 Sep;23(9):1174-9. doi: 10.1016/j.jvir.2012.06.015. PMID: 22920980. X-3, X-3a, X-3c

1020. Legendre G, Fallet C. [What to do with sub-mucosal type 2 myomas in the infertile woman?]. J Gynecol Obstet Biol Reprod (Paris). 2012 Apr;41(2 Suppl 1):H5-7. doi: 10.1016/s0368-2315(12)70003-0. PMID: 22445168. X-2

1021. Leone FPG, Calabrese S, Marciante C, et al. Feasibility and long-term efficacy of hysteroscopic myomectomy for myomas with intramural development by the use of non-electrical "cold" loops. Gynecological Surgery. 2012 May;9(2):155-61. doi: http://dx.doi.org/10.1007/s10397-011-0706-4. PMID: 2012278075. X-3, X-3c

1022. Li Q, Xiao YB, Liang ZG, et al. Ablation of leiomyomas using a combination of HIFU and iodized oil in vitro. Ultrasound Med Biol. 2012 Sep;38(9):1576-81. doi: 10.1016/j.ultrasmedbio.2012.04.019. PMID: 22749817. X-1, X-1a, X-1c, X-1d, X-5

1023. Mara M, Kubinova K, Maskova J, et al. Uterine artery embolization versus laparoscopic uterine artery occlusion: the outcomes of a prospective, nonrandomized clinical trial. Cardiovasc Intervent Radiol. 2012 Oct;35(5):1041-52. doi: 10.1007/s00270-012-0388-y. PMID: 22526109. X-3, X-3b

1024. McLucas B. Incidence and risk factors for clinical failure of uterine leiomyoma embolization. Obstet Gynecol. 2012 Nov;120(5):1210-1; author reply 1. doi: http://10.1097/AOG.0b013e3182721439. PMID: 23090549. X-1, X-1f, X-1h, X-2

1025. Mettler L, Schollmeyer T, Tinelli A, et al. Complications of Uterine Fibroids and Their Management, Surgical Management of Fibroids, Laparoscopy and Hysteroscopy versus Hysterectomy, Haemorrhage, Adhesions, and Complications. Obstet Gynecol Int. 2012;2012:791248. doi: 10.1155/2012/791248. PMID: 22619681. X-1, X-2, X-3, X-3a

1026. Nair SB, Sidhu HS, Watkinson AF. Variant obturator artery complicating uterine artery embolization. Clin Radiol. 2012 Mar;67(3):290-1. doi: 10.1016/j.crad.2011.09.006. PMID: 22079486. X-3, X-3d

1027. Nunez Martinez O, Salinas Moreno S, Mancenido Marcos N, et al. [Rectal leiomyoma: endoscopic resection]. Gastroenterol Hepatol. 2012 May;35(5):373-5. doi: 10.1016/j.gastrohep.2011.12.007. PMID: 22464269. X-1, X-1i

1028. Pourmatroud E, Hormozi L, Hemadi M, et al. Intravenous ascorbic acid (vitamin C) administration in myomectomy: a prospective, randomized, clinical trial. Arch Gynecol Obstet. 2012 Jan;285(1):111-5. doi: 10.1007/s00404-011-1897-7. PMID: 21448709. X-7

1029. Pundir J, Chandraharan E, Chui D. Profuse and persistent vaginal discharge following fibroid embolisation. J Obstet Gynaecol. 2012 May;32(4):404-5. doi: 10.3109/01443615.2012.658890. PMID: 22519499. X-1, X-1g, X-2, X-3, X-3d

1030. Rabe T, Ahrendt H, Albring C, et al. Ulipristal acetate in patients with symptomatic uterine leiomyoma and menorrhagia. Journal fur Reproduktionsmedizin und Endokrinologie. 2012;9(2):106-26. PMID: 2012390495. X-2

1031. Ricciardi R, Lanzone A, Tagliaferri V, et al. Using a 16-French resectoscope as an alternative device in the treatment of uterine lesions: a randomized controlled trial. Obstet Gynecol. 2012 Jul;120(1):160-5. doi: 10.1097/AOG.0b013e31825b9086. PMID: 22914405. X-5

1032. Shukla PA, Kumar A, Klyde D, et al. Pyomyoma after uterine artery embolization. J Vasc Interv Radiol. 2012 Mar;23(3):423-4. doi: 10.1016/j.jvir.2011.12.002. PMID: 22365300. X-1, X-1g, X-3, X-3d

1033. Wang KC, Chang WH, Liu WM, et al. Short-term advantages of laparoscopic uterine vessel occlusion in the management of women with symptomatic myoma. Taiwan J Obstet Gynecol. 2012 Dec;51(4):539-44. doi: 10.1016/j.tjog.2012.09.008. PMID: 23276556. X-3, X-3a, X-3b

1034. Wenderlein JM. [Nonsurgical therapy in symptomatic myomas]. Versicherungsmedizin. 2012 Mar 1;64(1):28-30. PMID: 22458009. X-2

1035. Williams AR, Bergeron C, Barlow DH, et al. Endometrial morphology after treatment of uterine fibroids with the selective progesterone receptor modulator, ulipristal acetate. Int J Gynecol Pathol. 2012 Nov;31(6):556-69. doi: 10.1097/PGP.0b013e318251035b. PMID: 23018219. X-6, X-7

1036. . Oral sciences research leads to uterine fibroid treatment. J Can Dent Assoc. 2013;79:d59. PMID: 23763737. X-2

1037. . High-intensity focused ultrasound effective on submucosal fibroids. Health Devices. 2013 Apr;42(4):136-7. PMID: 23687674. X-2

1038. Acharya J, Bancroft K, Lay J. Reply to letter re: Non-target embolization or local effect of infarction? Cardiovasc Intervent Radiol. 2013 Aug;36(4):1173. doi: 10.1007/s00270-013-0649-4. PMID: 23674275. X-1, X-2, X-3

1039. Barri-Soldevila PN, Vazquez A. [Current role of conservative surgery]. Med Clin (Barc). 2013 Jul;141 Suppl 1:7-12. doi: 10.1016/s0025-7753(13)70046-0. PMID: 24314561. X-2

1040. Brito LG, Panobianco MS, de Azevedo GD, et al. Motivational factors for women undergoing hysterectomy for uterine leiomyoma. Acta Obstet Gynecol Scand. 2013 Nov;92(11):1337-8. doi: 10.1111/aogs.12220. PMID: 23869575. X-1, X-1h, X-2

1041. Brun JL, Legendre G, Bendifallah S, et al. [Myomectomy]. Presse Med. 2013 Jul-Aug;42(7-8):1117-21. doi: 10.1016/j.lpm.2013.02.317. PMID: 23582900. X-2

1042. Calaf J, Arque M, Porta O, et al. [The fibroid as clinical problem]. Med Clin (Barc). 2013 Jul;141 Suppl 1:1-6. doi: 10.1016/s0025-7753(13)70045-9. PMID: 24314560. X-2

1043. Cancelo Hidalgo MJ. [Hormonal treatments for hemorrhaging secondary to fibroids. An alternative or complement to surgery?]. Med Clin (Barc). 2013 Jul;141 Suppl 1:30-4. doi: 10.1016/s0025-7753(13)70050-2. PMID: 24314565. X-2

1044. Carbonell JLL, Acosta R, Perez Y, et al. Safety and effectiveness of different dosage of mifepristone for the treatment of uterine fibroids: A double-blind randomized clinical trial. International Journal of Women's Health. 2013 13 Mar;5(1):115-24. doi: http://dx.doi.org/10.2147/IJWH.S33125. PMID: 2013190378. X-12

1045. Casella E, Grasso F, Bartolo E, et al. Use of haemostatic agents in the surgical conservative treatment of uterine myomas. Giornale Italiano di Ostetricia e Ginecologia. 2013 September-October;35(5):702-6. doi: http://dx.doi.org/10.11138/giog/2013.35.5.702. PMID: 2013743101. X-1, X-1h, X-3, X-3b, X-6, X-7

1046. Cuce F, Karasahin E, Sonmez G. Re: Uterine fibroid treatment planning with the diffusion weighted imaging tool. Korean J Radiol. 2013 May-Jun;14(3):547. doi: 10.3348/kjr.2013.14.3.547. PMID: 23690729. X-1, X-2, X-3

1047. Dajer-Fadel WL, Flores-Calderon O, Ramirez-Garcia AJ. Retroperitoneal leiomyoma that infiltrated into the right ventricle. Asian Cardiovasc Thorac Ann. 2013 Jun;21(3):370. doi: 10.1177/0218492312451919. PMID: 24570514. X-1, X-3, X-3d

1048. Dyer JD. Nontarget embolisation or local effect of infarction? Cardiovasc Intervent Radiol. 2013 Aug;36(4):1172. doi: 10.1007/s00270-013-0637-8. PMID: 23674272. X-2

1049. Esteve JLC, Acosta R, Perez Y, et al. Mifepristone versus placebo to treat uterine myoma: A double-blind, randomized clinical trial. International Journal of Women's Health. 2013 24 Jun;5(1):361-9. doi: http://dx.doi.org/10.2147/IJWH.S42770. PMID: 2013406582. X-12

1050. Falcone T, Parker WH. Surgical management of leiomyomas for fertility or uterine preservation. Obstet Gynecol. 2013 Apr;121(4):856-68. doi: 10.1097/AOG.0b013e3182888478. PMID: 23635687. X-2

1051. Firouznia K, Ghanaati H, Sharafi A, et al. Comparing ovarian radiation doses in flat-panel and conventional angiography during uterine artery embolization: a randomized clinical trial. Iran J Radiol. 2013 Sep;10(3):111-5. doi: 10.5812/iranjradiol.13264. PMID: 24348594. X-3, X-6, X-7

1052. Fontarensky M, Cassagnes L, Bouchet P, et al. Acute complications of benign uterine leiomyomas: treatment of intraperitoneal haemorrhage by embolisation of the uterine arteries. Diagn Interv Imaging. 2013 Sep;94(9):885-90. doi: 10.1016/j.diii.2013.01.021. PMID: 23602591. X-1, X-3, X-3c

1053. Frederick S, Frederick J, Fletcher H, et al. A trial comparing the use of rectal misoprostol plus perivascular vasopressin with perivascular vasopressin alone to decrease myometrial bleeding at the time of abdominal myomectomy. Fertil Steril. 2013 Oct;100(4):1044-9. doi: 10.1016/j.fertnstert.2013.06.022. PMID: 23876539. X-7

1054. Froeling V, Meckelburg K, Scheurig-Muenkler C, et al. Midterm results after uterine artery embolization versus MR-guided high-intensity focused ultrasound treatment for symptomatic uterine fibroids. Cardiovasc Intervent Radiol. 2013 Dec;36(6):1508-13. doi: 10.1007/s00270-013-0582-6. PMID: 23456309. X-3, X-3a

1055. Froeling V, Meckelburg K, Schreiter NF, et al. Outcome of uterine artery embolization versus MR-guided high-intensity focused ultrasound treatment for uterine fibroids: long-term results. Eur J Radiol. 2013 Dec;82(12):2265-9. doi: 10.1016/j.ejrad.2013.08.045. PMID: 24075785. X-3

1056. Griffin L, Feinglass J, Garrett A, et al. Postoperative outcomes after robotic versus abdominal myomectomy. Jsls. 2013 Jul-Sep;17(3):407-13. doi: 10.4293/108680813x13693422521557. PMID: 24018077. X-3, X-3a

1057. Guido RS, Macer JA, Abbott K, et al. Radiofrequency volumetric thermal ablation of fibroids: a prospective, clinical analysis of two years' outcome from the Halt trial. Health Qual Life Outcomes. 2013;11:139. doi: 10.1186/1477-7525-11-139. PMID: 23941588. X-3, X-3f

1058. Hsiao SM, Lin HH, Peng FS, et al. Comparison of robot-assisted laparoscopic myomectomy and traditional laparoscopic myomectomy. J Obstet Gynaecol Res. 2013 May;39(5):1024-9. doi: 10.1111/j.1447-0756.2012.02073.x. PMID: 23379670. X-3, X-3b

1059. Kim SY, Chang CH, Lee JS, et al. Comparison of the efficacy of dexmedetomidine plus fentanyl patient-controlled analgesia with fentanyl patient-controlled analgesia for pain control in uterine artery embolization for symptomatic fibroid tumors or adenomyosis: a prospective, randomized study. J Vasc Interv Radiol. 2013 Jun;24(6):779-86. doi: 10.1016/j.jvir.2013.02.034. PMID: 23707085. X-1, X-5, X-6, X-7

1060. Kulshrestha V, Kriplani A, Agarwal N, et al. Low dose mifepristone in medical management of uterine leiomyoma - an experience from a tertiary care hospital from north India. Indian J Med Res. 2013 Jun;137(6):1154-62. PMID: 23852296. X-4

1061. Kuppermann M, Learman LA, Schembri M, et al. Contributions of Hysterectomy and Uterus-Preserving Surgery to Health-Related Quality of Life. Obstet Gynecol. 2013 Jun 5doi: 10.1097/AOG.0b013e318292aea4. PMID: 23743451. X-3, X-3a

1062. Larsen L, Coyne K, Chwalisz K. Validation of the menstrual pictogram in women with leiomyomata associated with heavy menstrual bleeding. Reprod Sci. 2013 Jun;20(6):680-7. doi: 10.1177/1933719112463252. PMID: 23188490. X-1, X-1c, X-1h, X-3, X-6, X-7

1063. Pessarrodona A, Isern J, Rodriguez J, et al. [Treatment of uterine fibroids using high-intensity ultrasound]. Med Clin (Barc). 2013 Jul;141 Suppl 1:22-9. doi: 10.1016/s0025-7753(13)70049-6. PMID: 24314564. X-3, X-3c

1064. Roshdy E, Rajaratnam V, Maitra S, et al. Treatment of symptomatic Uterine fibroids with green tea extract: A pilot randomized controlled clinical study. International Journal of Women's Health. 2013 06 Aug;5(1):477-86. doi: http://dx.doi.org/10.2147/IJWH.S41021. PMID: 2013496484. X-12

1065. Roshdy E, Rajaratnam V, Maitra S, et al. Treatment of symptomatic uterine fibroids with green tea extract: a pilot randomized controlled clinical study. Int J Womens Health. 2013;5:477-86. doi: 10.2147/ijwh.s41021. PMID: 23950663. X-4

1066. Ruchalla E. [Symptomatic uterine fibroids - ultrasonic ablation of uterine fibroids]. Rofo. 2013 Jul;185(7):608-9. PMID: 23967465. X-2, X-11

1067. Rueff LE, Raman SS. Clinical and Technical Aspects of MR-Guided High Intensity Focused Ultrasound for Treatment of Symptomatic Uterine Fibroids. Semin Intervent Radiol. 2013 Dec;30(4):347-53. doi: 10.1055/s-0033-1359728. PMID: 24436561. X-2

1068. Sabourin G. [Fibristal: uterine fibroids' volume reduction]. Perspect Infirm. 2013 Nov-Dec;10(5):62. PMID: 24358679. X-2, X-11

1069. Sarici F, Babacan T, Altundag K, et al. Successful treatment of benign metastasizing leiomyoma with oral alternated chemotherapeutic agents. J buon. 2013 Jul-Sep;18(3):799. PMID: 24065503. X-1, X-3, X-3d

1070. Shokeir T, Shalaby H, Nabil H, et al. Reducing blood loss at abdominal myomectomy with preoperative use of dinoprostone intravaginal suppository: a randomized placebo-controlled pilot study. Eur J Obstet Gynecol Reprod Biol. 2013 Jan;166(1):61-4. doi: 10.1016/j.ejogrb.2012.09.014. PMID: 23083831. X-1, X-1e, X-7

1071. Song H, Lu D, Navaratnam K, et al. Aromatase inhibitors for uterine fibroids. Cochrane Database Syst Rev. 2013;10:Cd009505. doi: 10.1002/14651858.CD009505.pub2. PMID: 24151065. X-2

1072. Spencer EB, Stratil P, Mizones H. Clinical and periprocedural pain management for uterine artery embolization. Semin Intervent Radiol. 2013 Dec;30(4):354-63. doi: 10.1055/s-0033-1359729. PMID: 24436562. X-2

1073. Szamatowicz M, Kotarski J. [Selective progesterone receptor modulator (ulipristal acetate--a new option in the pharmacological treatment of uterine fibroids in women]. Ginekol Pol. 2013 Mar;84(3):219-22. PMID: 23700851. X-2

1074. Tarriel JE, Moreno CS, Ajenjo MC, et al. [Non-surgical approach for symptomatic fibroids. Physical methods: selective embolization]. Med Clin (Barc). 2013 Jul;141 Suppl 1:17-21. doi: 10.1016/s0025-7753(13)70048-4. PMID: 24314563. X-2

1075. Woo A, Scurry J, Jaaback K. Delayed diagnosis of vaginal leiomyoma following misrepresentative core biopsy. Pathology. 2013 Jun;45(4):429-30. doi: 10.1097/PAT.0b013e328360f085. PMID: 23635824. X-3, X-3d

1076. Wortman M. Sonographically guided hysteroscopic myomectomy (SGHM): minimizing the risks and maximizing efficiency. Surg Technol Int. 2013 Sep;23:181-9. PMID: 24081849. X-2, X-3, X-4, X-6, X-7

1077. Wozniakowska E, Milart P, Paszkowski T, et al. [Uterine artery embolization--clinical problems]. Ginekol Pol. 2013 Dec;84(12):1051-4. PMID: 24505954. X-3, X-3c

1078. . Uterine artery embolisation: an alternative to surgery? Prescrire Int. 2014 May;23(149):133. PMID: 24926521. X-2

1079. . Patient safety must be a priority in all aspects of care. Lancet Oncol. 2014 Feb;15(2):123. doi: 10.1016/s1470-2045(14)70042-7. PMID: 24480553. X-2, X-3, X-4, X-6, X-7

1080. Antila K, Nieminen HJ, Sequeiros RB, et al. Automatic segmentation for detecting uterine fibroid regions treated with MR-guided high intensity focused ultrasound (MR-HIFU). Med Phys. 2014 Jul;41(7):073502. doi: 10.1118/1.4881319. PMID: 24989416. X-1, X-3, X-3c

1081. Berman JM, Guido RS, Garza Leal JG, et al. Three-year outcome of the Halt trial: a prospective analysis of radiofrequency volumetric thermal ablation of myomas. J Minim Invasive Gynecol. 2014 Sep-Oct;21(5):767-74. doi: 10.1016/j.jmig.2014.02.015. PMID: 24613404. X-3, X-7

1082. Biglia N, Carinelli S, Maiorana A, et al. Ulipristal acetate: a novel pharmacological approach for the treatment of uterine fibroids. Drug Des Devel Ther. 2014;8:285-92. doi: 10.2147/dddt.s54565. PMID: 24591818. X-2

1083. Brower V. FDA considers restricting or banning laparoscopic morcellation. J Natl Cancer Inst. 2014 Oct;106(10)doi: 10.1093/jnci/dju339. PMID: 25313228. X-1, X-2, X-3, X-4, X-5, X-6, X-7

1084. Canis MJ, Triopon G, Darai E, et al. Adhesion prevention after myomectomy by laparotomy: a prospective multicenter comparative randomized single-blind study with second-look laparoscopy to assess the effectiveness of PREVADH. Eur J Obstet Gynecol Reprod Biol. 2014 Jul;178:42-7. doi: 10.1016/j.ejogrb.2014.03.020. PMID: 24841647. X-7

1085. Chang MH, Chew MH, Chew GK. Large abdominal-pelvic tumors: a diagnostic conundrum. Gastroenterology. 2014 May;146(5):e3-5. doi: 10.1053/j.gastro.2013.11.039. PMID: 24680806. X-1, X-2, X-3

1086. Chao HT, Wang PH. Fertility outcomes after uterine artery occlusion in the management of women with symptomatic uterine fibroids. Taiwan J Obstet Gynecol. 2014 Mar;53(1):1-2. doi: 10.1016/j.tjog.2012.10.006. PMID: 24767636. X-2

1087. Dariushnia SR, Nikolic B, Stokes LS, et al. Quality improvement guidelines for uterine artery embolization for symptomatic leiomyomata. J Vasc Interv Radiol. 2014 Nov;25(11):1737-47. doi: 10.1016/j.jvir.2014.08.029. PMID: 25442136. X-2

1088. Gizzo S, Ancona E, Anis O, et al. Could vessel ablation by magnetic resonance-guided focused ultrasound represent a next future gynecological fertility-sparing approach to fibroids? Surg Innov. 2014 Feb;21(1):118-9. doi: 10.1177/1553350613495115. PMID: 23843157. X-2

1089. Gizzo S, Saccardi C, Patrelli TS, et al. Magnetic resonance-guided focused ultrasound myomectomy: safety, efficacy, subsequent fertility and quality-of-life improvements, a systematic review. Reprod Sci. 2014 Apr;21(4):465-76. doi: 10.1177/1933719113497289. PMID: 23868442. X-2, X-3

1090. Goff BA. SGO not soft on morcellation: risks and benefits must be weighed. Lancet Oncol. 2014 Apr;15(4):e148. doi: 10.1016/s1470-2045(14)70075-0. PMID: 24694631. X-1, X-2, X-3, X-4, X-5, X-6, X-7

1091. Granberg S. Are two intrauterine contraceptive devices better than one? Ultrasound Obstet Gynecol. 2014 Jul;44(1):121. doi: 10.1002/uog.13414. PMID: 24861768. X-1, X-1c, X-1g, X-2, X-3, X-3d

1092. Hampton T. Critics of fibroid removal procedure question risks it may pose for women with undetected uterine cancer. Jama. 2014 Mar 5;311(9):891-3. doi: 10.1001/jama.2014.27. PMID: 24504342. X-2, X-3, X-4, X-5, X-6, X-7

1093. Kaufman C, Pollak J, Mojibian H. What is too big? Uterine artery embolization of a large fibroid causing abdominal compartment syndrome. Semin Intervent Radiol. 2014 Jun;31(2):207-11. doi: 10.1055/s-0034-1373795. PMID: 25049449. X-3, X-3d

1094. Kho KA, Nezhat CH. Evaluating the risks of electric uterine morcellation. Jama. 2014 Mar 5;311(9):905-6. doi: 10.1001/jama.2014.1093. PMID: 24504415. X-1, X-2, X-3, X-4, X-5, X-6, X-7

1095. Kim TH, Lee HH. Is uterine myomectomy a safe option during cesarean section? Arch Gynecol Obstet. 2014 Aug;290(2):201-2. doi: 10.1007/s00404-014-3239-z. PMID: 24728107. X-2

1096. Kim YS, Bae DS, Park MJ, et al. Techniques to expand patient selection for MRI-guided high-intensity focused ultrasound ablation of uterine fibroids. AJR Am J Roentgenol. 2014 Feb;202(2):443-51. doi: 10.2214/ajr.13.10753. PMID: 24450690. X-2

1097. Kornats'ka AH, Chubei HV, Brazhuk MV, et al. [Modern possibilities of prophylaxis of intraoperative complications in organ salvage operations on the small pelvis organs]. Klin Khir. 2014 Jun(6):62-5. PMID: 25252559. X-3, X-3c

1098. Li Y, Liu G, Gao L, et al. [Clinical study of gasless abdominal-wall lifting laparoscopic myomectomy with 5 mm laparoscope]. Zhonghua Yi Xue Za Zhi. 2014 Mar 25;94(11):852-4. PMID: 24854755. X-6, X-7

1099. Maleux G, Michielsen K, Timmerman D, et al. 2D versus 3D roadmap for uterine artery catheterization: impact on several angiographic parameters. Acta Radiol. 2014 Feb;55(1):62-70. doi: 10.1177/0284185113492457. PMID: 23873889. X-1, X-6, X-7

1100. Mayor S. Second opinion reduces hysterectomies for uterine fibroids, study shows. Bmj. 2014;348:g2765. doi: 10.1136/bmj.g2765. PMID: 24736108. X-1, X-2, X-3

1101. McCarthy M. US agency warns against morcellation in hysterectomies and myomectomies. Bmj. 2014;348:g2872. doi: 10.1136/bmj.g2872. PMID: 24755656. X-2

1102. McPherson K, Manyonda I, Lumsden MA, et al. A randomised trial of treating fibroids with either embolisation or myomectomy to measure the effect on quality of life among women wishing to avoid hysterectomy (the FEMME study): study protocol for a randomised controlled trial. Trials. 2014;15:468. doi: 10.1186/1745-6215-15-468. PMID: 25432688. X-2

1103. Melamed A. Electric uterine morcellation. Jama. 2014 Jul 2;312(1):96. doi: 10.1001/jama.2014.6169. PMID: 25058230. X-1, X-2, X-3, X-4, X-5, X-6, X-7

1104. Morice P. [Impact of tumor morcellation during the surgical extraction of solid tumors]. Bull Cancer. 2014 Jun;101(6):526-7. PMID: 25121163. X-1, X-1h, X-11

1105. Munro KI, Thrippleton MJ, Williams AR, et al. Quantitative serial MRI of the treated fibroid uterus. PLoS One. 2014;9(3):e89809. doi: 10.1371/journal.pone.0089809. PMID: 24608161. X-1, X-1e

1106. Nash ZJ, Kunde K, Mascarenhas LJ. The role of intraoperative cell salvage in abdominal myomectomy. Am J Obstet Gynecol. 2014 Oct;211(4):440-1. doi: 10.1016/j.ajog.2014.05.019. PMID: 24837035. X-2

1107. Nisolle M, Closon F, Firquet A, et al. [Ulipristal acetate (Esmya): a selective modulator of progesterone receptors, new treatment of uterine fibromatosis]. Rev Med Liege. 2014 Apr;69(4):220-5. PMID: 24923103. X-1, X-1h, X-2, X-3, X-3f

1108. Poojari VG, Bhat VV, Bhat R. Total laparoscopic hysterectomy with prior uterine artery ligation at its origin. Int J Reprod Med. 2014;2014:420926. doi: 10.1155/2014/420926. PMID: 25763400. X-4

1109. Ragab A, Khaiary M, Badawy A. The Use of Single Versus Double Dose of Intra-vaginal Prostaglandin E2 "Misoprostol" prior to Abdominal Myomectomy: A Randomized Controlled Clinical Trial. J Reprod Infertil. 2014 Jul;15(3):152-6. PMID: 25202673. X-4, X-7

1110. Ragab A, Khaiary M, Badawy A. The use of single versus double dose of intra-vaginal prostaglandin E <inf>2</inf> "misoprostol" prior to abdominal myomectomy: A randomized controlled clinical trial. Journal of Reproduction and Infertility. 2014 July-September;15(3):152-6. PMID: 2014508606. X-1, X-1e, X-12

1111. Rardin CR. Mitigating risks of specimen extraction: is in-bag power morcellation an answer? Obstet Gynecol. 2014 Sep;124(3):489-90. doi: 10.1097/aog.0000000000000434. PMID: 25162247. X-1, X-2, X-3, X-4, X-5, X-6, X-7

1112. Ross SM. Efficacy of a standardized isopropanolic black cohosh (Actaea racemosa) extract in treatment of uterine fibroids in comparison with tibolone among patients with menopausal symptoms. Holist Nurs Pract. 2014 Nov-Dec;28(6):386-91. doi: 10.1097/hnp.0000000000000055. PMID: 25314113. X-2, X-7

1113. Sirkeci F, Narang L, Naguib N, et al. Uterine artery embolization for severe symptomatic fibroids: effects on fertility and symptoms. Hum Reprod. 2014 Aug;29(8):1832-3. doi: 10.1093/humrep/deu147. PMID: 24939958. X-2, X-3, X-3c

1114. Solnik MJ, Munro MG. Indications and alternatives to hysterectomy. Clin Obstet Gynecol. 2014 Mar;57(1):14-42. doi: 10.1097/grf.0000000000000010. PMID: 24488051. X-2, X-3

1115. Son M, Wright JD. Reply: To PMID 24565686. Am J Obstet Gynecol. 2014 Oct;211(4):441. doi: 10.1016/j.ajog.2014.05.020. PMID: 24837033. X-2

1116. Sparic R. [Uterine myomas in pregnancy, childbirth and puerperium]. Srp Arh Celok Lek. 2014 Jan-Feb;142(1-2):118-24. PMID: 24684044. X-2

1117. Stoica R, Bistriceanu I, Sima R, et al. Laparoscopic myomectomy. J Med Life. 2014 Oct-Dec;7(4):522-4. PMID: 25713613. X-2, X-3

1118. Talaulikar VS, Manyonda I. Ulipristal acetate for use in moderate to severe symptoms of uterine fibroids. Womens Health (Lond Engl). 2014 Nov;10(6):565-70. doi: 10.2217/whe.14.60. PMID: 25482483. X-1, X-2, X-3

1119. Thiry T, Dohan A, Naneix AL, et al. Diffuse abdominopelvic leiomyomatosis: CT and MR imaging findings with histopathological correlation. Diagn Interv Imaging. 2014 Jan;95(1):105-8. doi: 10.1016/j.diii.2013.07.007. PMID: 23992919. X-3, x-3d

1120. Torre A, Paillusson B, Fain V, et al. Reply: uterine artery embolization for severe symptomatic fibroids: effects on fertility and symptoms. Hum Reprod. 2014 Aug;29(8):1833-4. doi: 10.1093/humrep/deu148. PMID: 24939959. X-2

1121. Turan E, Yesilova Y, Surucu HA, et al. Multiple flesh coloured nodules with unilateral segmental distribution. J Pak Med Assoc. 2014 Apr;64(4):479-80. PMID: 24864652. X-1, X-2, X-3, X-4, X-5, X-6, X-7

1122. Tyagi J, Jan H, Sarris J, et al. Parasitic pedunculated fibroid. Is laparoscopic management the best approach? J Obstet Gynaecol. 2014 Apr;34(3):273-4. doi: 10.3109/01443615.2013.851655. PMID: 24483597. X-3, X-3d

1123. van Overhagen H, Reekers JA. Uterine Artery Embolization for Symptomatic Leiomyomata. Cardiovasc Intervent Radiol. 2014 Dec 4doi: 10.1007/s00270-014-1031-x. PMID: 25465064. X-2

1124. Wong AS, Cheung CW, Yeung SW, et al. Transcervical intralesional vasopressin injection compared with placebo in hysteroscopic myomectomy: a randomized controlled trial. Obstet Gynecol. 2014 Nov;124(5):897-903. doi: 10.1097/aog.0000000000000515. PMID: 25437716. X-1, X-1e, X-7

1125. Xi S, Liske E, Wang S, et al. Effect of Isopropanolic Cimicifuga racemosa Extract on Uterine Fibroids in Comparison with Tibolone among Patients of a Recent Randomized, Double Blind, Parallel-Controlled Study in Chinese Women with Menopausal Symptoms. Evid Based Complement Alternat Med. 2014;2014:717686. doi: 10.1155/2014/717686. PMID: 24719645. X-3, X-7

1126. Xi S, Liske E, Wang S, et al. Effect of isopropanolic cimicifuga racemosa extract on uterine fibroids in comparison with tibolone among patients of a recent randomized, double blind, parallel-controlled study in chinese women with menopausal symptoms. Evidence-based Complementary and Alternative Medicine. 2014;2014 (no pagination)(717686)doi: http://dx.doi.org/10.1155/2014/717686. PMID: 2014201754. X-12

1127. Abdel-Hafeez M, Elnaggar A, Ali M, et al. Rectal misoprostol for myomectomy: A randomised placebo-controlled study. Aust N Z J Obstet Gynaecol. 2015 Aug;55(4):363-8. doi: 10.1111/ajo.12359. PMID: 26174128. X-1, X-1e

1128. Battista C, Capriglione S, Guzzo F, et al. The challenge of preoperative identification of uterine myomas: Is ultrasound trustworthy? A prospective cohort study. Arch Gynecol Obstet. 2015 Nov 2doi: 10.1007/s00404-015-3937-1. PMID: 26525700. X-1, X-1c

1129. Berman JM, Bolnick JM, Pemueller RR, et al. Reproductive Outcomes in Women Following Radiofrequency Volumetric Thermal Ablation of Symptomatic Fibroids. A Retrospective Case Series Analysis. J Reprod Med. 2015 May-Jun;60(5-6):194-8. PMID: 26126303. X-3, X-3a, X-3c

1130. Blagovest B, Magunska N, Kovachev E, et al. [LAPAROSCOPIC MYOMECTOMY WITH UTERINE ARTERY CLIPPING VERSUS CONVENTIONAL LAPAROSCOPIC MYOMECTOMY]. Akush Ginekol (Sofiia). 2015;54(7):8-10. PMID: 27025101. X-3, X-3a, X-10

1131. Chang WC, Chu LH, Huang PS, et al. Comparison of Laparoscopic Myomectomy in Large Myomas With and Without Leuprolide Acetate. J Minim Invasive Gynecol. 2015 Sep-Oct;22(6):992-6. doi: 10.1016/j.jmig.2015.04.026. PMID: 25958038. X-1, X-1e, X-3, X-3b

1132. Chikazawa K, Netsu S, Konno R. Myoma morcellation through the navel. Taiwan J Obstet Gynecol. 2015 Feb;54(1):106. doi: 10.1016/j.tjog.2014.11.020. PMID: 25675936. X-1, X-2

1133. Desai VB, Guo XM, Xu X. Alterations in surgical technique after FDA statement on power morcellation. Am J Obstet Gynecol. 2015 May;212(5):685-7. doi: 10.1016/j.ajog.2015.02.027. PMID: 25735888. X-1, X-1h, X-3

1134. El Hachem L, Small E, Chung P, et al. Randomized controlled double-blind trial of transversus abdominis plane block versus trocar site infiltration in gynecologic laparoscopy. Am J Obstet Gynecol. 2015 Feb;212(2):182.e1-9. doi: 10.1016/j.ajog.2014.07.049. PMID: 25088860. X-1, X-1h, X-5

1135. Galliano D. Ulipristal acetate in uterine fibroids. Fertil Steril. 2015 Feb;103(2):359-60. doi: 10.1016/j.fertnstert.2014.11.028. PMID: 25555419. X-1, X-2, X-3

1136. Gao Y, Jiang F, Wang X. Tri-acryl gelatin microsphere is better than polyvinyl alcohol in the treatment of uterine myomas with uterine artery embolization. Int J Clin Exp Med. 2015;8(6):8749-57. PMID: 26309526. X-2, X-3, X-3f

1137. Goudard Y, Canel V, Goin G, et al. Indications and surgical technique of subtotal hysterectomy for a general surgeon practicing in austere environment with limited resources. Med Sante Trop. 2015 Nov 1;25(4):352-7. doi: 10.1684/mst.2015.0503. PMID: 26377860. X-1, X-1h, X-2, X-3

1138. Harmanli O. Contained power morcellation within an insufflated isolation bag. Obstet Gynecol. 2015 Jan;125(1):229. doi: 10.1097/aog.0000000000000614. PMID: 25560131. X-1, X-2, X-3, X-4, X-5, X-6, X-7

1139. Kim TJ, Kim TH, Cho CH, et al. Multi-Institution, prospective randomized trial to compare the success rates of single-port versus multi-port laparoscopic hysterectomy for the treatment of uterine myoma or adenomyosis. J Minim Invasive Gynecol. 2015 Mar 7doi: 10.1016/j.jmig.2015.02.022. PMID: 25757810. X-5

1140. Kim TJ, Shin SJ, Kim TH, et al. Multi-institution, Prospective, Randomized Trial to Compare the Success Rates of Single-port Versus Multiport Laparoscopic Hysterectomy for the Treatment of Uterine Myoma or Adenomyosis. J Minim Invasive Gynecol. 2015 Jul-Aug;22(5):785-91. doi: 10.1016/j.jmig.2015.02.022. PMID: 25757810. X-5

1141. Krentel H, De Wilde RL. Complications in Laparoscopic Supracervical Hysterectomy(LASH), especially the morcellation related. Best Pract Res Clin Obstet Gynaecol. 2015 Nov 14doi: 10.1016/j.bpobgyn.2015.11.001. PMID: 26694587. X-2

1142. Kroncke T, David M. Uterine Artery Embolization (UAE) for Fibroid Treatment - Results of the 5th Radiological Gynecological Expert Meeting. Rofo. 2015 Apr 22doi: 10.1055/s-0034-1399345. PMID: 25901539. X-2

1143. Kwon YS, Roh HJ, Ahn JW, et al. Transient occlusion of uterine arteries in laparoscopic uterine surgery. Jsls. 2015 Jan-Mar;19(1)doi: 10.4294/jsls.2014.00189. PMID: 25848179. X-3, X-3a X-3f

1144. Lethaby A, Vollenhoven B. Fibroids (uterine myomatosis, leiomyomas). BMJ Clin Evid. 2015;2015 PMID: 26032466. X-1, X-2, X-3, X-3f

1145. Lonnerfors C, Reynisson P, Persson J. A randomized trial comparing vaginal and laparoscopic hysterectomy vs robot-assisted hysterectomy. J Minim Invasive Gynecol. 2015 Jan;22(1):78-86. doi: 10.1016/j.jmig.2014.07.010. PMID: 25045857. X-1, X-1h, X-5

1146. Lumsden MA, Hamoodi I, Gupta J, et al. Fibroids: diagnosis and management. Bmj. 2015;351:h4887. doi: 10.1136/bmj.h4887. PMID: 26463991. X-1, X-2, X-3

1147. Mindjuk I, Trumm CG, Herzog P, et al. MRI predictors of clinical success in MR-guided focused ultrasound (MRgFUS) treatments of uterine fibroids: results from a single centre. Eur Radiol. 2015 May;25(5):1317-28. doi: 10.1007/s00330-014-3538-6. PMID: 25510445. X-3, X-3c, X-3f

1148. Moroni RM, Martins WP, Dias SV, et al. Combined oral contraceptive for treatment of women with uterine fibroids and abnormal uterine bleeding: a systematic review. Gynecol Obstet Invest. 2015;79(3):145-52. doi: 10.1159/000369390. PMID: 25661737. X-2

1149. Ngichabe S, Obura T, Stones W. Intravenous tranexamic acid as an adjunct haemostat to ornipressin during open myomectomy. A randomized double blind placebo controlled trial. Ann Surg Innov Res. 2015;9:10. doi: 10.1186/s13022-015-0017-y. PMID: 26568770. X-1, X-1h, X-4, X-6, X-7

1150. Orsi F, Monfardini L, Bonomo G, et al. Ultrasound guided high intensity focused ultrasound (USgHIFU) ablation for uterine fibroids: Do we need the microbubbles? Int J Hyperthermia. 2015 May;31(3):233-9. doi: 10.3109/02656736.2015.1004134. PMID: 25758436. X-12

1151. Parazzini F, Tozzi L, Bianchi S. Pregnancy outcome and uterine fibroids. Best Pract Res Clin Obstet Gynaecol. 2015 Nov 25doi: 10.1016/j.bpobgyn.2015.11.017. PMID: 26723475. X-2, X-3, X-3f

1152. Perez-Lopez FR. Ulipristal acetate in the management of symptomatic uterine fibroids: facts and pending issues. Climacteric. 2015 Apr;18(2):177-81. doi: 10.3109/13697137.2014.981133. PMID: 25390187. X-2

1153. Pieri S, Di Felice M, Moreschi E, et al. Transbrachial approach to the treatment of uterine leiomyomas with embolization of the uterine arteries: a preliminary technical experience. Radiol Med. 2015 Feb 6doi: 10.1007/s11547-015-0498-0. PMID: 25656038. X-3

1154. Rubino RJ, Lukes AS. Twelve-month outcomes for patients undergoing hysteroscopic morcellation of uterine polyps and myomas in an office or ambulatory surgical center. J Minim Invasive Gynecol. 2015 Feb;22(2):285-90. doi: 10.1016/j.jmig.2014.10.015. PMID: 25446547. X-6, X-7

1155. Shaaban MM, Ahmed MR, Farhan RE, et al. Efficacy of Tranexamic Acid on Myomectomy-Associated Blood Loss in Patients With Multiple Myomas: A Randomized Controlled Clinical Trial. Reprod Sci. 2015 Dec 29doi: 10.1177/1933719115623646. PMID: 26718305. X-1, X-1e, X-1h, X-6, X-7

1156. Shu SR, Luo X, Song WX, et al. Ultra-structure changes and survivin expression in uterine fibroids after radiofrequency ablation. Int J Hyperthermia. 2015 Dec;31(8):896-9. doi: 10.3109/02656736.2015.1086497. PMID: 26446892. X-1, X-1d, X-1h, X-3, X-3b

1157. Siedhoff MT, Kim KH. Morcellation and myomas: Balancing decisions around minimally invasive treatments for fibroids. J Surg Oncol. 2015 Dec;112(7):769-71. doi: 10.1002/jso.24010. PMID: 26768314. X-2, X-3, X-3f, X-6

1158. Song T, Kim TJ, Kim WY, et al. Comparison of barbed suture versus traditional suture in laparoendoscopic single-site myomectomy. Eur J Obstet Gynecol Reprod Biol. 2015 Feb;185:99-102. doi: 10.1016/j.ejogrb.2014.11.022. PMID: 25549572. X-3, X-3a

1159. Song T, Kim TJ, Lee SH, et al. Laparoendoscopic single-site myomectomy compared with conventional laparoscopic myomectomy: a multicenter, randomized, controlled trial. Fertil Steril. 2015 Nov;104(5):1325-31. doi: 10.1016/j.fertnstert.2015.07.1137. PMID: 26263079. X-6

1160. Stewart EA, Morton CC. Cutaneous and Uterine Leiomyomas. Mayo Clin Proc. 2015 Jul;90(7):990. doi: 10.1016/j.mayocp.2015.04.014. PMID: 26141339. X-1, X-2, X-1a

1161. Tabatabai A, Karimi-Zarchi M, Meibodi B, et al. Effects of a single rectal dose of Misoprostol prior to abdominal hysterectomy in women with symptomatic leiomyoma: a randomized double blind clinical trial. Electron Physician. 2015 Oct;7(6):1372-5. doi: 10.14661/1372. PMID: 26516444. X-1, X-1e, X-7

1162. Tsai HW, Ocampo EJ, Huang BS, et al. Effect of semisimultaneous morcellation in situ during laparoscopic myomectomy. Gynecology and Minimally Invasive Therapy. 2015 November;4(4):132-6. doi: http://dx.doi.org/10.1016/j.gmit.2015.04.009 . PMID: 2015162573. X-3, X-3e, X-6, X-7

1163. van Overhagen H, Reekers JA. Uterine artery embolization for symptomatic leiomyomata. Cardiovasc Intervent Radiol. 2015 Jun;38(3):536-42. doi: 10.1007/s00270-014-1031-x. PMID: 25465064. X-2, X-3, X-3f

1164. Yuan H, Wang C, Wang D, et al. Comparison of the effect of laparoscopic supracervical and total hysterectomy for uterine fibroids on ovarian reserve by assessing serum anti-Mullerian hormone levels: a prospective cohort study. J Minim Invasive Gynecol. 2015 Jan 31doi: 10.1016/j.jmig.2015.01.025. PMID: 25653041. X-3, X-3a

1165. Yuk JS, Ji HY, Lee SH, et al. Unexpected uterine malignancy in women who have undergone myomectomy. Int J Gynaecol Obstet. 2015 Jun;129(3):270-1. doi: 10.1016/j.ijgo.2014.12.004. PMID: 25790796. X-1, X-3, X-3a, X-7

1166. Yun BS, Seong SJ, Cha DH, et al. Changes in proliferating and apoptotic markers of leiomyoma following treatment with a selective progesterone receptor modulator or gonadotropin-releasing hormone agonist. Eur J Obstet Gynecol Reprod Biol. 2015 Aug;191:62-7. doi: 10.1016/j.ejogrb.2015.05.022. PMID: 26093349. X-1, X-1a, X-1d

1167. Zhang X, Ding J, Hua K. The Utility of Hand-Assisted Laparoscopic Surgery (HALS) in Giant Pelvic Masses. Indian J Surg. 2015 Dec;77(Suppl 3):1214-8. doi: 10.1007/s12262-015-1254-3. PMID: 27011539. X-3, X-3c, X-3d

1168. Zhao JB, Luo ZL, Feng C, et al. Effects of the intermittent injection with super-low pressure on the postoperative pain control during the uterine artery embolization for uterine myoma. Int J Clin Exp Med. 2015;8(8):14303-7. PMID: 26550414. X-1, X-1h, X-3, X-3b, X-6, X-7

1169. Zhao WP, Chen JY, Chen WZ. Effect of biological characteristics of different types of uterine fibroids, as assessed with T2-weighted magnetic resonance imaging, on ultrasound-guided high-intensity focused ultrasound ablation. Ultrasound Med Biol. 2015 Feb;41(2):423-31. doi: 10.1016/j.ultrasmedbio.2014.09.022. PMID: 25542494. X-1, X-3, X-3c

1170. AbdElmagied AM, Vaughan LE, Weaver AL, et al. Fibroid interventions: reducing symptoms today and tomorrow; extending generalizability by using a comprehensive cohort design with a randomized controlled trial. Am J Obstet Gynecol. 2016 Apr 9doi: 10.1016/j.ajog.2016.04.001. PMID: 27073063. X-3, X-3f, X-6, X-7

1171. Angioni S, Pontis A, Multinu A, et al. Safe endobag morcellation in a single-port laparoscopy subtotal hysterectomy. Minim Invasive Ther Allied Technol. 2016 Apr;25(2):113-6. doi: 10.3109/13645706.2015.1109521. PMID: 26902985. X-1, X-1g, X-3, X-3d

1172. Bartels CB, Cayton KC, Chuong FS, et al. An Evidence-based Approach to the Medical Management of Fibroids: A Systematic Review. Clin Obstet Gynecol. 2016 Mar;59(1):30-52. doi: 10.1097/grf.0000000000000171. PMID: 26756261. X-2, X-3, X-3f

1173. Bing-Song Z, Jing Z, Zhi-Yu H, et al. Unplanned pregnancy after ultrasound-guided percutaneous microwave ablation of uterine fibroids: A follow-up study. Sci Rep. 2016;6:18924. doi: 10.1038/srep18924. PMID: 26733265. X-3, X-3c

1174. Bogani G, Chiappa V, Ditto A, et al. Morcellation of apparent benign uterine myoma: assessing risk to benefit ratio. J Gynecol Oncol. 2016 Apr 5:e37. doi: 10.3802/jgo.2016.27.e37. PMID: 27102246. X-2

1175. Chen S, Pitre E, Kaunelis D, et al. CADTH Rapid Response Reports. Uterine-Preserving Interventions for the Management of Symptomatic Uterine Fibroids: A Systematic Review of Clinical and Cost-Effectiveness. Ottawa (ON): Canadian Agency for Drugs and Technologies in Health 2015(c) CADTH.; 2016.

1176. Duvnjak S, Ravn P, Green A, et al. Clinical Long-Term Outcome and Reinterventional Rate After Uterine Fibroid Embolization with Nonspherical Versus Spherical Polyvinyl Alcohol Particles. Cardiovasc Intervent Radiol. 2016 Feb;39(2):204-9. doi: 10.1007/s00270-015-1157-5. PMID: 26122738. X-3, X-3a

1177. Ferrero S, Racca A, Tafi E, et al. Ulipristal Acetate Before High Complexity Hysteroscopic Myomectomy: A Retrospective Comparative Study. J Minim Invasive Gynecol. 2016 Mar-Apr;23(3):390-5. doi: 10.1016/j.jmig.2015.12.002. PMID: 26707918. X-3, X-3a

1178. Gurusamy KS, Vaughan J, Fraser IS, et al. Medical Therapies for Uterine Fibroids - A Systematic Review and Network Meta-Analysis of Randomised Controlled Trials. PLoS One. 2016;11(2):e0149631. doi: 10.1371/journal.pone.0149631. PMID: 26919185. X-2, X-3, X-3f

1179. Iavazzo C, Mamais I, Gkegkes ID. Robotic assisted vs laparoscopic and/or open myomectomy: systematic review and meta-analysis of the clinical evidence. Arch Gynecol Obstet. 2016 Mar 11doi: 10.1007/s00404-016-4061-6. PMID: 26969650. X-2

1180. Justin Clark T, Cooper NA. Heavy menstrual bleeding. Womens Health (Lond Engl). 2016 Jan;12(1):1. doi: 10.2217/whe.15.71. PMID: 26767314. X-2

1181. Kacperczyk J, Bartnik P, Romejko-Wolniewicz E, et al. Postmyomectomic Uterine Rupture Despite Cesarean Section. Anticancer Res. 2016 Mar;36(3):1011-3. PMID: 26976991. X-1, X-1g, X-3, X-3d

1182. Kalampokas T, Kamath M, Boutas I, et al. Ulipristal acetate for uterine fibroids: a systematic review and meta-analysis. Gynecol Endocrinol. 2016 Feb;32(2):91-6. doi: 10.3109/09513590.2015.1106471. PMID: 26572056. X-2

1183. Kim SY, Koo BN, Shin CS, et al. The effects of single-dose dexamethasone on inflammatory response and pain after uterine artery embolisation for symptomatic fibroids or adenomyosis: a randomised controlled study. Bjog. 2016 Mar;123(4):580-7. doi: 10.1111/1471-0528.13785. PMID: 26667403. X-1, X-1h, X-6, X-7

1184. Ksiezakowska-Lakoma K, Zyla M, Wilczynski J. Removal of uterine fibroids by mini-laparotomy technique in women who wish to preserve their uterus and fertility. Wideochir Inne Tech Maloinwazyjne. 2016 Jan;10(4):561-6. doi: 10.5114/wiitm.2015.56998. PMID: 26865893. X-3, X-3a

1185. Lee B, Kim K, Cho HY, et al. Effect of intravenous ascorbic acid infusion on blood loss during laparoscopic myomectomy: a randomized, double-blind, placebo-controlled trial. Eur J Obstet Gynecol Reprod Biol. 2016 Apr;199:187-91. doi: 10.1016/j.ejogrb.2016.02.014. PMID: 26946313. X-1, X-1e, X-6, X-7

1186. Lewis EI, Gargiulo AR. The Role of Hysteroscopic and Robot-assisted Laparoscopic Myomectomy in the Setting of Infertility. Clin Obstet Gynecol. 2016 Mar;59(1):53-65. doi: 10.1097/grf.0000000000000161. PMID: 26630075. X-1, X-2, X-3

1187. Luyckx M, Pirard C, Fellah L, et al. Long-term nonsurgical control with ulipristal acetate of multiple uterine fibroids, enabling pregnancy. Am J Obstet Gynecol. 2016 Mar 2doi: 10.1016/j.ajog.2016.02.049. PMID: 26945610. X-2, X-3, X-3d

1188. Maratea D. Repeated-intermittent use of ulipristal acetate for the management of uterine fibroids: an Italian pharmacoeconomic evaluation. Minerva Ginecol. 2016 Feb;68(1):15-20. PMID: 26990098. X-6, X-7

1189. Mu Y, Wang Y, Li M, et al. Comparison of efficacy of different embolic agents on uterine leiomyoma. Clin Exp Obstet Gynecol. 2016;43(1):114-8. PMID: 27048030. X-3a

1190. Raba G, Kotarski J, Szczupak K, et al. Uterus banding with the Osada method effectively reduces intraoperative blood loss during myomectomy. Minim Invasive Ther Allied Technol. 2016;25(1):43-7. doi: 10.3109/13645706.2015.1075558. PMID: 26329979. X-1, X-1h, X-6, X-7

1191. Ramaekers P, de Greef M, van Breugel JM, et al. Increasing the HIFU ablation rate through an MRI-guided sonication strategy using shock waves: feasibility in the in vivo porcine liver. Phys Med Biol. 2016 Feb 7;61(3):1057-77. doi: 10.1088/0031-9155/61/3/1057. PMID: 26757987. X-1, X-1a, X-1h, X-3

1192. Sayyah-Melli M, Bidadi S, Taghavi S, et al. Comparative study of vaginal danazol vs diphereline (a synthetic GnRH agonist) in the control of bleeding during hysteroscopic myomectomy in women with abnormal uterine bleeding: a randomized controlled clinical trial. Eur J Obstet Gynecol Reprod Biol. 2016 Jan;196:48-51. doi: 10.1016/j.ejogrb.2015.10.021. PMID: 26675055. X-1, X-1e, X-6

Table D-2. Reasons for exclusion: Key Question 3 (n = 539*)

Exclusion Code	Exclusion Reason	Count*
X-1	Not original research	178
X-2	Not women with fibroids	127
X-3	Does not report the histopathological status of tumors from all women treated for uterine fibroids	313
X-4	Does not include at least 5 patients	173
X-13	Non-english	1
X-14	Published before 2014	4

*Total count exceeds number of records as records can be excluded for more than one reason

1. Pfaendler KS, Mwanahamuntu MH, Sahasrabuddhe VV, et al. Management of cryotherapy-ineligible women in a "screen-and-treat" cervical cancer prevention program targeting HIV-infected women in Zambia: lessons from the field. Gynecol Oncol. 2008 Sep;110(3):402-7. doi: 10.1016/j.ygyno.2008.04.031. PMID: 18556050.L1: X-3

2. Hanafi M. Ultrasound diagnosis of adenomyosis, leiomyoma, or combined with histopathological correlation. J Hum Reprod Sci. 2013 Jul;6(3):189-93. doi: 10.4103/0974-1208.121421. PMID: 24347933.INCLUDE X-14

3. Grigoriadis C, Papaconstantinou E, Mellou A, et al. Clinicopathological changes of uterine leiomyomas after GnRH agonist therapy. Clin Exp Obstet Gynecol. 2012;39(2):191-4. PMID: 22905461.INCLUDE X-14

4. Vaniova Klimentova D, Braila AD, Simionescu C, et al. Clinical and paraclinical study regarding the macro- and microscopic diagnosis of various anatomo-clinical forms of operated uterine fibromyoma. Rom J Morphol Embryol. 2012;53(2):369-73. PMID: 22732808.INCLUDE X-14

5. Butt JL, Jeffery ST, Van der Spuy ZM. An audit of indications and complications associated with elective hysterectomy at a public service hospital in South Africa. Int J Gynaecol Obstet. 2012 Feb;116(2):112-6. doi: 10.1016/j.ijgo.2011.09.026. PMID: 22142874.INCLUDE X-14

6. Pritts EA, Vanness DJ, Berek JS, et al. The prevalence of occult leiomyosarcoma at surgery for presumed uterine fibroids: a meta-analysis. Gynecol Surg. 2015;12(3):165-77. doi: 10.1007/s10397-015-0894-4. PMID: 26283890.INCLUDE X-1

7. Tulandi T, Leung A, Jan N. Non-Malignant Sequelae of Unconfined Morcellation at Laparoscopic Hysterectomy or Myomectomy. J Minim Invasive Gynecol. 2016 Jan 20doi: 10.1016/j.jmig.2016.01.017. PMID: 26802909.X-1, X-3

8. Brolmann HA, Sizzi O, Hehenkamp WJ, et al. Laparoscopic power morcellation of presumed fibroids. Minerva Ginecol. 2016 Jan 22 PMID: 26799759.INCLUDE X-1

9. Cooney EJ, Borowsky M, Flynn C. Case report: Atypical, 'symplastic' leiomyoma recurring as leiomyosarcoma in the vagina. Gynecol Oncol Rep. 2015 Nov;14:4-5. doi: 10.1016/j.gore.2015.07.006. PMID: 26793761.X-4

10. Dastranj Tabrizi A, Ghojazadeh M, Thagizadeh Anvar H, et al. Immunohistochemical Profile of Uterine Leiomyoma With Bizarre Nuclei; Comparison With Conventional Leiomyoma, Smooth Muscle Tumors of Uncertain Malignant Potential and Leiomyosarcoma. Adv Pharm Bull. 2015 Dec;5(Suppl 1):683-7. doi: 10.15171/apb.2015.093. PMID: 26793616.X-1, X-3, X-4

11. Kelsey R. Prostate cancer: Increased adverse event risk with GnRHa therapy. Nat Rev Urol. 2016 Jan 20doi: 10.1038/nrurol.2016.5. PMID: 26787398.X-2, X-3, X-4

12. Tinelli A, Sparic R, Kadija S, et al. Myomas: anatomy and related issues. Minerva Ginecol. 2016 Jan 19 PMID: 26785282.X-1

13. Taniguchi F, Koike N, Niiro E, et al. Effectiveness of right-left inversion of a transverse-section magnetic resonance image during laparoscopic pelvic surgery. J Minim Invasive Gynecol. 2016 Jan 8doi: 10.1016/j.jmig.2016.01.003. PMID: 26776671.X-2, X-3

14. Parker WH. An open letter to the FDA regarding the use of morcellation procedures for women having surgery for presumed uterine fibroids. J Minim Invasive Gynecol. 2016 Jan 7doi: 10.1016/j.jmig.2015.12.012. PMID: 26773577.X-1

15. Ravid Y, Formanski M, Smith Y, et al. Uterine leiomyosarcoma and endometrial stromal sarcoma have unique miRNA signatures. Gynecol Oncol. 2016 Jan 6doi: 10.1016/j.ygyno.2016.01.001. PMID: 26768834.X-2, X-3, X-4

16. Siedhoff MT, Kim KH. Morcellation and myomas: Balancing decisions around minimally invasive treatments for fibroids. J Surg Oncol. 2015 Dec;112(7):769-71. doi: 10.1002/jso.24010. PMID: 26768314.X-1

17. Akkurt MO, Yavuz A, Tatar B, et al. Utero-cutaneous Fistula after Multiple Abdominal Myomectomies: A Case Report. Balkan Med J. 2015 Oct;32(4):426-8. doi: 10.5152/balkanmedj.2015.151206. PMID: 26740905.X-2, X-3, X-4

18. Bing-Song Z, Jing Z, Zhi-Yu H, et al. Unplanned pregnancy after ultrasound-guided percutaneous microwave ablation of uterine fibroids: A follow-up study. Sci Rep. 2016;6:18924. doi: 10.1038/srep18924. PMID: 26733265.X-3

19. Parazzini F, Tozzi L, Bianchi S. Pregnancy outcome and uterine fibroids. Best Pract Res Clin Obstet Gynaecol. 2015 Nov 25doi: 10.1016/j.bpobgyn.2015.11.017. PMID: 26723475.X-1

20. Shaaban MM, Ahmed MR, Farhan RE, et al. Efficacy of Tranexamic Acid on Myomectomy-Associated Blood Loss in Patients With Multiple Myomas: A Randomized Controlled Clinical Trial. Reprod Sci. 2015 Dec 29doi: 10.1177/1933719115623646. PMID: 26718305.X-3

21. Krentel H, De Wilde RL. Complications in Laparoscopic Supracervical Hysterectomy(LASH), especially the morcellation related. Best Pract Res Clin Obstet Gynaecol. 2015 Nov 14doi: 10.1016/j.bpobgyn.2015.11.001. PMID: 26694587.X-1

22. Saridogan E. Surgical treatment of fibroids in heavy menstrual bleeding. Womens Health (Lond Engl). 2016 Jan;12(1):53-62. doi: 10.2217/whe.15.89. PMID: 26693796.X-1

23. Rimbach S, Holzknecht A, Schmedler C, et al. First clinical experiences using a new in-bag morcellation system during laparoscopic hysterectomy. Arch Gynecol Obstet. 2015 Dec 21doi: 10.1007/s00404-015-3986-5. PMID: 26690354.INCLUDE X-3

24. Aksoy H, Aydin T, Ozdamar O, et al. Successful use of laparoscopic myomectomy to remove a giant uterine myoma: a case report. J Med Case Rep. 2015;9:286. doi: 10.1186/s13256-015-0771-9. PMID: 26674527.X-3, X-4

25. Lynam S, Young L, Morozov V, et al. Risk, risk reduction and management of occult malignancy diagnosed after uterine morcellation: a commentary. Womens Health (Lond Engl). 2015 Nov;11(6):929-44. doi: 10.2217/whe.15.63. PMID: 26673851.X-1

26. Bogani G, Chiappa V, Ditto A, et al. Morcellation of undiagnosed uterine sarcoma: A critical review. Crit Rev Oncol Hematol. 2016 Feb;98:302-8. doi: 10.1016/j.critrevonc.2015.11.015. PMID: 26672915.X-1

27. Hinchcliff EM, Cohen SL. Laparoscopic Hysterectomy for Uterine Fibroids: Is it Safe? Clin Obstet Gynecol. 2015 Dec 14doi: 10.1097/grf.0000000000000165. PMID: 26670837.X-1

28. Parker WH, Pritts EA, Olive DL. What is the Future of Open Intraperitoneal Power-Morcellation of Fibroids? Clin Obstet Gynecol. 2015 Dec 14doi: 10.1097/grf.0000000000000166. PMID: 26670834.X-1

29. Kho KA, Brown DN. Surgical Treatment of Uterine Fibroids Within a Containment System and Without Power Morcellation. Clin Obstet Gynecol. 2015 Dec 14doi: 10.1097/grf.0000000000000168. PMID: 26670832.X-1

30. Trivedi PH, Patil SS, Parekh NA, et al. Laparoscopic Morcellation of Fibroid and Uterus In-Bag. J Obstet Gynaecol India. 2015 Dec;65(6):396-400. doi: 10.1007/s13224-015-0795-5. PMID: 26663999.INCLUDE X-3

31. Ates S, Ozcan P, Aydin S, et al. Differences in clinical characteristics for the determination of adenomyosis coexisting with leiomyomas. J Obstet Gynaecol Res. 2015 Dec 10doi: 10.1111/jog.12905. PMID: 26663489.X-3

32. Guyon F, Cordeiro Vidal G, Babin G, et al. [A critical assessment of morcellation in case of uterine malignancies and its impact on gynecologic surgery: From "precautionary principle" to "realism"]. Bull Cancer. 2015 Dec 3doi: 10.1016/j.bulcan.2015.10.013. PMID: 26657189.X-1

33. Kim SM, Baek JM, Park EK, et al. A Comparison of Single-, Two- and Three-Port Laparoscopic Myomectomy. Jsls. 2015 Sep-Dec;19(4)doi: 10.4293/jsls.2015.00084. PMID: 26648680.X-3

34. Wright JD. Electric Power Morcellation in Gynecology: The Path Forward. Obstet Gynecol. 2016 Jan;127(1):7-9. doi: 10.1097/aog.0000000000001224. PMID: 26646139.X-1

35. Parker WH, Kaunitz AM, Pritts EA, et al. U.S. Food and Drug Administration's Guidance Regarding Morcellation of Leiomyomas: Well-Intentioned, But Is It Harmful for Women? Obstet Gynecol. 2016 Jan;127(1):18-22. doi: 10.1097/aog.0000000000001157. PMID: 26646134.X-1

36. Cui RR, Wright JD. Risk of Occult Uterine Sarcoma in Presumed Uterine Fibroids. Clin Obstet Gynecol. 2015 Dec 7doi: 10.1097/grf.0000000000000163. PMID: 26645385.X-1

37. Holzmann C, Markowski DN, I VONL, et al. Patterns of Chromosomal Abnormalities that Can Improve Diagnosis of Uterine Smooth Muscle Tumors. Anticancer Res. 2015 Dec;35(12):6445-56. PMID: 26637855.X-2, X-3, X-4

38. Lewis EI, Gargiulo AR. The Role of Hysteroscopic and Robot-assisted Laparoscopic Myomectomy in the Setting of Infertility. Clin Obstet Gynecol. 2015 Dec 1doi: 10.1097/grf.0000000000000161. PMID: 26630075.X-1

39. Muller E. Elmi Muller, MBChB, MMED: Head, Transplantation Service, Groote Schuur Hospital and Professor of Surgery, University of Cape Town, South Africa. Transplantation. 2015 Dec;99(12):2440-1. doi: 10.1097/tp.0000000000001017. PMID: 26627672.X-1

40. Zhang R, Shi H, Ren F, et al. Assessment of carboprost tromethamine for reducing hemorrhage in laparoscopic intramural myomectomy. Exp Ther Med. 2015 Sep;10(3):1171-4. doi: 10.3892/etm.2015.2649. PMID: 26622459.X-3

41. Driessen SR, Sandberg EM, la Chapelle CF, et al. Case-Mix Variables and Predictors for Outcomes of Laparoscopic Hysterectomy: A Systematic Review. J Minim Invasive Gynecol. 2015 Nov 22doi: 10.1016/j.jmig.2015.11.008. PMID: 26611613.X-1

42. Morgan-Ortiz F, Soto-Pineda JM, Alejandro C-I, et al. [Laparoscopic myomectomy and use of electromechanical morcellator: clinical results in a series of cases]. Ginecol Obstet Mex. 2015 Sep;83(9):529-36. PMID: 26591041.X-3

43. Dakhly DM, Abdel Moety GA, Saber W, et al. Accuracy of Hysteroscopic Endomyometrial Biopsy in Diagnosis of Adenomyosis. J Minim Invasive Gynecol. 2015 Nov 12doi: 10.1016/j.jmig.2015.11.004. PMID: 26581187.X-2, X-3

44. Tsuji I, Fujinami N, Kotani Y, et al. Reproductive Outcome of Infertile Patients with Fibroids Based on the Patient and Fibroid Characteristics; Optimal and Personalized Management. Gynecol Obstet Invest. 2015 Nov 19doi: 10.1159/000441788. PMID: 26581036.X-3

45. R OS, Abder R. Myomectomy at the time of cesarean delivery. Ir J Med Sci. 2015 Nov 12doi: 10.1007/s11845-015-1378-2. PMID: 26563108.X-3, X-4

46. Radhika BH, Naik K, Shreelatha S, et al. Case series: Pregnancy Outcome in Patients with Uterine Fibroids. J Clin Diagn Res. 2015 Oct;9(10):Qr01-4. doi: 10.7860/jcdr/2015/14375.6621. PMID: 26557577.X-3

47. Song T, Kim MK, Kim ML, et al. Use of vasopressin vs epinephrine to reduce haemorrhage during myomectomy: a randomized controlled trial. Eur J Obstet Gynecol Reprod Biol. 2015 Dec;195:177-81. doi: 10.1016/j.ejogrb.2015.10.003. PMID: 26550945.X-3

48. Stimamiglio A. Accidental ultrasound finding of a big asymptomatic intestinal leiomyoma in an anticoagulated patient with macrohematuria. J Ultrasound. 2015 Dec;18(4):421-2. doi: 10.1007/s40477-014-0138-x. PMID: 26550067.X-2, X-3, X-4

49. Amant F, Van den Bosch T, Vergote I, et al. Morcellation of uterine leiomyomas: a plea for patient triage. Lancet Oncol. 2015 Nov;16(15):1454-6. doi: 10.1016/s1470-2045(15)00375-7. PMID: 26545835.X-1, X-3, X-4

50. Closon F, Tulandi T. Uterine myomata: Organ-preserving surgery. Best Pract Res Clin Obstet Gynaecol. 2015 Oct 19doi: 10.1016/j.bpobgyn.2015.09.005. PMID: 26542930.X-1

51. Giampaolino P, De Rosa N, Tommaselli GA, et al. Comparison of bidirectional barbed suture Stratafix and conventional suture with intracorporeal knots in laparoscopic myomectomy by office transvaginal hydrolaparoscopic follow-up: a preliminary report. Eur J Obstet Gynecol Reprod Biol. 2015 Dec;195:146-50. doi: 10.1016/j.ejogrb.2015.10.011. PMID: 26540594.X-3

52. Di Spiezio Sardo A, Calagna G, Di Carlo C, et al. Cold loops applied to bipolar resectoscope: A safe "one-step" myomectomy for treatment of submucosal myomas with intramural development. J Obstet Gynaecol Res. 2015 Dec;41(12):1935-41. doi: 10.1111/jog.12831. PMID: 26534903.X-3

53. Deffieux X, de Rochambeau B, Chene G, et al. [Hysterectomy for benign pathology: Guidelines for clinical practice]. J Gynecol Obstet Biol Reprod (Paris). 2015 Dec;44(10):1219-27. doi: 10.1016/j.jgyn.2015.09.027. PMID: 26530174.X-1

54. Gauthier T, Huet S, Marcelli M, et al. [Hysterectomy for benign gynaecological disease: Surgical approach, vaginal suture method and morcellation: Guidelines]. J Gynecol Obstet Biol Reprod (Paris). 2015 Dec;44(10):1168-82. doi: 10.1016/j.jgyn.2015.09.032. PMID: 26527018.X-1

55. Mihmanli V, Cetinkaya N, Kilickaya A, et al. Giant cervical myoma associated with urinary incontinence and hydroureteronephrosis. Clin Exp Obstet Gynecol. 2015;42(5):690-1. PMID: 26524828.X-2, X-3, X-4

56. Bettaiah R, Mallappashetty CT, Chandramouli M. Thermal Bowel Injury During Difficult Laparoscopic Myomectomy. J Minim Invasive Gynecol. 2015 Oct 28doi: 10.1016/j.jmig.2015.10.010. PMID: 26520596.X-1, X-4

57. Adelman MR. The Morcellation Debate: The History and the Science. Clin Obstet Gynecol. 2015 Dec;58(4):710-7. doi: 10.1097/grf.0000000000000150. PMID: 26512438.X-1

58. Naftalin J, Hoo W, Nunes N, et al. The association between ultrasound features of adenomyosis and severity of menstrual pain. Ultrasound Obstet Gynecol. 2015 Oct 25doi: 10.1002/uog.15798. PMID: 26499878.X-2, X-3, X-4

59. Prins JR, Van Oven MW, Helder-Woolderink JM. Unexpected Leiomyosarcoma 4 Years after Laparoscopic Removal of the Uterus Using Morcellation. Case Rep Obstet Gynecol. 2015;2015:723606. doi: 10.1155/2015/723606. PMID: 26491585.X-4

60. Perutelli A, Garibaldi S, Basile S, et al. Combined robotically-assisted laparoscopic left hepatectomy and total hysterectomy of enlarged uterus. Minerva Chir. 2015 Oct;70(5):386-8. PMID: 26488763.X-1, X-3, X-4

61. Vitale SG, Padula F, Gulino FA. Management of uterine fibroids in pregnancy: recent trends. Curr Opin Obstet Gynecol. 2015 Dec;27(6):432-7. doi: 10.1097/gco.0000000000000220. PMID: 26485457.X-1

62. Tapmeier TT, Becker CM. Is pale the way to go to understand adenomyosis? Fertil Steril. 2015 Dec;104(6):1378. doi: 10.1016/j.fertnstert.2015.10.005. PMID: 26474736.X-1

63. Galen DI. Electromagnetic image guidance in gynecology: prospective study of a new laparoscopic imaging and targeting technique for the treatment of symptomatic uterine fibroids. Biomed Eng Online. 2015;14:90. doi: 10.1186/s12938-015-0086-5. PMID: 26471917.X-2, X-3, X-4

64. Hoste G, Van Trappen P. Robotic hysterectomy using the Vessel Sealer for myomatous uteri: technique and clinical outcome. Eur J Obstet Gynecol Reprod Biol. 2015 Nov;194:241-4. doi: 10.1016/j.ejogrb.2015.09.030. PMID: 26454809.X-3

65. Lee ET, Wong FW. Small bowel obstruction from barbed suture following laparoscopic myomectomy-A case report. Int J Surg Case Rep. 2015;16:146-9. doi: 10.1016/j.ijscr.2015.09.039. PMID: 26454501.X-2, X-3, X-4

66. van den Haak L, Arkenbout EA, Sandberg EM, et al. Power Morcellator Features Affecting Tissue Spill in Gynecologic Laparoscopy: An In-Vitro Study. J Minim Invasive Gynecol. 2016 Jan 1;23(1):107-12. doi: 10.1016/j.jmig.2015.09.014. PMID: 26432710.X-2, X-3, X-4

67. Yang Y, Jin C, Oh K, et al. Hybrid laparoscopic myomectomy: A novel technique. Obstet Gynecol Sci. 2015 Sep;58(5):401-4. doi: 10.5468/ogs.2015.58.5.401. PMID: 26430666.X-3

68. Blagovest B, Magunska N, Kovachev E, et al. [LAPAROSCOPIC ANTERIOR UTERINE LIGAMENTOPEXY--OUR EXPERIENCE]. Akush Ginekol (Sofiia). 2015;54(5):45-6. PMID: 26411196.X-2, X-3, X-4

69. Arleo EK, Schwartz PE, Hui P, et al. Review of Leiomyoma Variants. AJR Am J Roentgenol. 2015 Oct;205(4):912-21. doi: 10.2214/ajr.14.13946. PMID: 26397344.X-1

70. Hall T, Lee SI, Boruta DM, et al. Medical Device Safety and Surgical Dissemination of Unrecognized Uterine Malignancy: Morcellation in Minimally Invasive Gynecologic Surgery. Oncologist. 2015 Nov;20(11):1274-82. doi: 10.1634/theoncologist.2015-0061. PMID: 26382742.X-1, X-2, X-3, X-4

71. Kefeli M, Yildiz L, Gun S, et al. EMMPRIN (CD147) Expression in Smooth Muscle Tumors of the Uterus. Int J Gynecol Pathol. 2016 Jan;35(1):1-7. doi: 10.1097/pgp.0000000000000216. PMID: 26352545.X-2, X-3, X-4

72. Asmar J, Even M, Carbonnel M, et al. Myomectomy by Robotically Assisted Laparoscopic Surgery: Results at Foch Hospital, Paris. Front Surg. 2015;2:40. doi: 10.3389/fsurg.2015.00040. PMID: 26347871.X-3

73. Dubuisson J, Popescu S, Dubuisson JB, et al. Preventive Uterine Artery Occlusion: Benefits of the Laparoscopic Posterior Approach. J Minim Invasive Gynecol. 2015 Aug 31doi: 10.1016/j.jmig.2015.08.885. PMID: 26334789.X-1

74. Namazov A, Karakus R, Gencer E, et al. Do submucous myoma characteristics affect fertility and menstrual outcomes in patients underwent hysteroscopic myomectomy? Iran J Reprod Med. 2015 Jun;13(6):367-72. PMID: 26330852.X-3

75. Raba G, Kotarski J, Szczupak K, et al. Uterus banding with the Osada method effectively reduces intraoperative blood loss during myomectomy. Minim Invasive Ther Allied Technol. 2016 Feb;25(1):43-7. doi: 10.3109/13645706.2015.1075558. PMID: 26329979.X-3

76. Ahdad-Yata N, Fernandez H, Nazac A, et al. [Fertility after hysteroscopic resection of submucosal myoma in infertile women]. J Gynecol Obstet Biol Reprod (Paris). 2015 Aug 27doi: 10.1016/j.jgyn.2015.06.028. PMID: 26321611.X-3

77. Gargiulo AR, Lewis EI, Kaser DJ, et al. Robotic single-site myomectomy: a step-by-step tutorial. Fertil Steril. 2015 Nov;104(5):e13. doi: 10.1016/j.fertnstert.2015.07.1159. PMID: 26300020.X-3

78. Uccella S, Bonzini M, Palomba S, et al. Impact of Obesity on Surgical Treatment for Endometrial Cancer: A Multicenter Study Comparing Laparoscopy vs Open Surgery, with Propensity-Matched Analysis. J Minim Invasive Gynecol. 2016 Jan 1;23(1):53-61. doi: 10.1016/j.jmig.2015.08.007. PMID: 26282516.X-2, X-3, X-4

79. Oduyebo T, Hinchcliff E, Meserve EE, et al. Risk Factors for Occult Uterine Sarcoma Among Women Undergoing Minimally Invasive Gynecologic Surgery. J Minim Invasive Gynecol. 2016 Jan 1;23(1):34-9. doi: 10.1016/j.jmig.2015.07.017. PMID: 26253281.INCLUDE X-3

80. Waetjen LE, Parvataneni R, Varon S, et al. Obstacles to Studying Emerging Technologies. Obstet Gynecol. 2015 Aug;126(2):391-5. doi: 10.1097/aog.0000000000000914. PMID: 26241430.X-1

81. Ghezzi F, Serati M, Casarin J, et al. Minilaparoscopic Single-Site Total Hysterectomy. Obstet Gynecol. 2015 Jul;126(1):151-4. doi: 10.1097/aog.0000000000000906. PMID: 26241268.X-2, X-3, X-4

82. Chan JK, Gardner AB, Thompson CA, et al. The use of clinical characteristics to help prevent morcellation of leiomyosarcoma: An analysis of 491 cases. Am J Obstet Gynecol. 2015 Dec;213(6):873-4. doi: 10.1016/j.ajog.2015.07.040. PMID: 26226552.INCLUDE X-2, X-3

83. Andryjowicz E, Wray TB, Reinaldo Ruiz V, et al. Safely Increase the Minimally Invasive Hysterectomy Rate: A Novel Three-Tiered Preoperative Categorization System Can Predict the Difficulty for Benign Disease. Perm J. 2015 Fall;19(4):39-45. doi: 10.7812/tpp/15-023. PMID: 26222092.X-3

84. Solima E, Scagnelli G, Austoni V, et al. Vaginal Uterine Morcellation Within a Specimen Containment System: A Study of Bag Integrity. J Minim Invasive Gynecol. 2015 Nov-Dec;22(7):1244-6. doi: 10.1016/j.jmig.2015.07.007. PMID: 26205578.X-3

85. Conforti A, Mollo A, Alviggi C, et al. Techniques to reduce blood loss during open myomectomy: a qualitative review of literature. Eur J Obstet Gynecol Reprod Biol. 2015 Sep;192:90-5. doi: 10.1016/j.ejogrb.2015.05.027. PMID: 26189110.X-1

86. Katano K, Takeda Y, Sugiura-Ogasawara M. Conservative therapy with a gonadotropin-releasing hormone agonist for a uterine arteriovenous malformation in a patient with congenital heart disease. Clin Case Rep. 2015 Jun;3(6):479-82. doi: 10.1002/ccr3.233. PMID: 26185652.X-1, X-2, X-3, X-4

87. Guilbert MC, Samouelian V, Rahimi K. Uterine Leiomyoma With Osteoclast-like Giant Cells. Int J Gynecol Pathol. 2016 Jan;35(1):30-2. doi: 10.1097/pgp.0000000000000204. PMID: 26166717.X-4

88. Singh SS, Bougie O, Arendas K, et al. Morcellation in Canada: Perspectives on Current Practices and Future Implications. J Minim Invasive Gynecol. 2015 Nov-Dec;22(7):1142-4. doi: 10.1016/j.jmig.2015.07.001. PMID: 26166320.X-1

89. Walsh TM, Sangi-Haghpeykar H, Ng V, et al. Hand-Assisted Laparoscopic Hysterectomy for Large Uteri. J Minim Invasive Gynecol. 2015 Nov-Dec;22(7):1231-6. doi: 10.1016/j.jmig.2015.06.022. PMID: 26164535.X-2, X-3, X-4

90. Flyckt RL, Falcone T. Uterine Rupture After Laparoscopic Myomectomy. J Minim Invasive Gynecol. 2015 Sep-Oct;22(6):921-2. doi: 10.1016/j.jmig.2015.07.002. PMID: 26164534.X-3, X-4

91. Zeng W, Chen L, Du W, et al. Laparoscopic hysterectomy of large uteri using three-trocar technique. Int J Clin Exp Med. 2015;8(4):6319-26. PMID: 26131249.X-2, X-3, X-4

92. Berman JM, Bolnick JM, Pemueller RR, et al. Reproductive Outcomes in Women Following Radiofrequency Volumetric Thermal Ablation of Symptomatic Fibroids. A Retrospective Case Series Analysis. J Reprod Med. 2015 May-Jun;60(5-6):194-8. PMID: 26126303.X-3

93. Kainsbak J, Hansen ES, Dueholm M. Literature review of outcomes and prevalence and case report of leiomyosarcomas and non-typical uterine smooth muscle leiomyoma tumors treated with uterine artery embolization. Eur J Obstet Gynecol Reprod Biol. 2015 Aug;191:130-7. doi: 10.1016/j.ejogrb.2015.05.018. PMID: 26117442.X-1

94. Hahn M, Brucker S, Kraemer D, et al. Radiofrequency Volumetric Thermal Ablation of Fibroids and Laparoscopic Myomectomy: Long-Term Follow-up From a Randomized Trial. Geburtshilfe Frauenheilkd. 2015 May;75(5):442-9. doi: 10.1055/s-0035-1545931. PMID: 26097247.X-3

95. Choussein S, Srouji SS, Farland LV, et al. Flexible Carbon Dioxide Laser Fiber Versus Ultrasonic Scalpel in Robot-Assisted Laparoscopic Myomectomy. J Minim Invasive Gynecol. 2015 Nov-Dec;22(7):1183-90. doi: 10.1016/j.jmig.2015.06.005. PMID: 26092081.X-3

96. Kang JH, Kim WY, Lee KW, et al. Timing for a Laparoscopic Myomectomy During the Menstrual Cycle. J Minim Invasive Gynecol. 2015 Nov-Dec;22(7):1191-5. doi: 10.1016/j.jmig.2015.06.006. PMID: 26092079.X-3

97. Hayashi T, Ichimura T, Yaegashi N, et al. Expression of CAVEOLIN 1 in uterine mesenchymal tumors: No relationship between malignancy and CAVEOLIN 1 expression. Biochem Biophys Res Commun. 2015 Aug 7;463(4):982-7. doi: 10.1016/j.bbrc.2015.06.046. PMID: 26072376.X-1, X-3

98. Guan X, Walsh TM, Osial P, et al. Laparoscopic Single-Site Myomectomy of 11-cm Intramural Myoma. J Minim Invasive Gynecol. 2015 Sep-Oct;22(6):936-7. doi: 10.1016/j.jmig.2015.05.021. PMID: 26070726.X-1

99. Jeong JH, Kim YR, Kim EJ, et al. Comparison of Surgical Outcomes according to Suturing Methods in Single Port Access Laparoscopic Myomectomy. J Menopausal Med. 2015 Apr;21(1):47-55. doi: 10.6118/jmm.2015.21.1.47. PMID: 26046038.X-3

100. Lee J, Kim S, Nam EJ, et al. Single-port access versus conventional multi-port access total laparoscopic hysterectomy for very large uterus. Obstet Gynecol Sci. 2015 May;58(3):239-45. doi: 10.5468/ogs.2015.58.3.239. PMID: 26023674.X-3

101. Sharma K, Bora MK, Venkatesh BP, et al. Role of 3D Ultrasound and Doppler in Differentiating Clinically Suspected Cases of Leiomyoma and Adenomyosis of Uterus. J Clin Diagn Res. 2015 Apr;9(4):Qc08-12. doi: 10.7860/jcdr/2015/12240.5846. PMID: 26023602.X-3

102. Olvera-Maldonado AJ, Martinez-Uribe A, Rendon-Macias ME, et al. [Medical treatment of the uterine miomas in perimenopausal patients]. Ginecol Obstet Mex. 2015 Jan;83(1):41-7. PMID: 26016315.X-3

103. Koo YJ, Lee JK, Lee YK, et al. Pregnancy Outcomes and Risk Factors for Uterine Rupture After Laparoscopic Myomectomy: A Single-Center Experience and Literature Review. J Minim Invasive Gynecol. 2015 Sep-Oct;22(6):1022-8. doi: 10.1016/j.jmig.2015.05.016. PMID: 26012718.X-3

104. Carranza-Mamane B, Havelock J, Hemmings R, et al. The management of uterine fibroids in women with otherwise unexplained infertility. J Obstet Gynaecol Can. 2015 Mar;37(3):277-88. PMID: 26001875.X-1

105. Asgari Z, Hafizi L, Hosseini R, et al. Intrauterine synechiae after myomectomy; laparotomy versus laparoscopy: Non-randomized interventional trial. Iran J Reprod Med. 2015 Mar;13(3):161-8. PMID: 26000007.X-3

106. Fanfani F, Restaino S, Gueli Alletti S, et al. TELELAP ALF-X Robotic-assisted Laparoscopic Hysterectomy: Feasibility and Perioperative Outcomes. J Minim Invasive Gynecol. 2015 Sep-Oct;22(6):1011-7. doi: 10.1016/j.jmig.2015.05.004. PMID: 25982854.X-2, X-3, X-4

107. Aliakparov MT, Abishev B, Tazhibaev DM, et al. [Results of uterine artery embolization in the treatment of symptomatic uterine myoma]. Vestn Rentgenol Radiol. 2014 Nov-Dec(6):29-32. PMID: 25975130.X-3

108. Pitter MC, Srouji SS, Gargiulo AR, et al. Fertility and Symptom Relief following Robot-Assisted Laparoscopic Myomectomy. Obstet Gynecol Int. 2015;2015:967568. doi: 10.1155/2015/967568. PMID: 25969688.X-3

109. van den Haak L, Alleblas C, Nieboer TE, et al. Efficacy and safety of uterine manipulators in laparoscopic surgery: a review. Arch Gynecol Obstet. 2015 Nov;292(5):1003-11. doi: 10.1007/s00404-015-3727-9. PMID: 25967852.X-1

110. Seader K, Rao S, Hemida Y, et al. TREATMENT OUTCOMES OF PATIENTS WITH EARLY STAGE CERVICAL CANCER TREATED WITH LAPAROTOMY COMPARED TO ROBOTICALLY ASSISTED LAPAROSCOPIC APPROACH: IGCS-0089 Cervical Cancer. Int J Gynecol Cancer. 2015 May;25 Suppl 1:32-3. PMID: 25955917.X-2, X-3, X-4

111. Croce S, Ribeiro A, Brulard C, et al. Uterine smooth muscle tumor analysis by comparative genomic hybridization: a useful diagnostic tool in challenging lesions. Mod Pathol. 2015 Jul;28(7):1001-10. doi: 10.1038/modpathol.2015.3. PMID: 25932961.INCLUDE X-2, X-3

112. Favero G, Miglino G, Kohler C, et al. Vaginal Morcellation Inside Protective Pouch: A Safe Strategy for Uterine Extration in Cases of Bulky Endometrial Cancers: Operative and Oncological Safety of the Method. J Minim Invasive Gynecol. 2015 Sep-Oct;22(6):938-43. doi: 10.1016/j.jmig.2015.04.015. PMID: 25917277.X-2, X-3, X-4

113. Di Luigi G, D'Alfonso A, Patacchiola F, et al. Leiomyosarcoma: a rare malignant transformation of a uterine leiomyoma. Eur J Gynaecol Oncol. 2015;36(1):84-7. PMID: 25872341.X-4

114. Pujani M, Jairajpuri ZS, Rana S, et al. Cellular leiomyoma versus endometrial stromal tumor: A pathologists' dilemma. J Midlife Health. 2015 Jan-Mar;6(1):31-4. doi: 10.4103/0976-7800.153619. PMID: 25861206.INCLUDE X-4

115. Gueye M, Diouf AA, Cisse A, et al. [Consequences of hysterectomy at the national- hospital of Pikine in Dakar]. Tunis Med. 2014 Oct;92(10):635-8. PMID: 25860680.X-2, X-3, X-4

116. Keltz MD, Greene AD, Morrissey MB, et al. Sonohysterographic predictors of successful hysteroscopic myomectomies. Jsls. 2015 Jan-Mar;19(1):e2014.00105. doi: 10.4293/jsls.2014.00105. PMID: 25848194.X-3

117. Kwon YS, Roh HJ, Ahn JW, et al. Transient occlusion of uterine arteries in laparoscopic uterine surgery. Jsls. 2015 Jan-Mar;19(1):e2014.00189. doi: 10.4294/jsls.2014.00189. PMID: 25848179.X-3

118. Uccella S, Cromi A, Casarin J, et al. Minilaparoscopic versus standard laparoscopic hysterectomy for uteri >/= 16 weeks of gestation: surgical outcomes, postoperative quality of life, and cosmesis. J Laparoendosc Adv Surg Tech A. 2015 May;25(5):386-91. doi: 10.1089/lap.2014.0478. PMID: 25839384.X-2, X-3, X-4

119. Abu Saadeh F, Galvin D, Alsharbaty MJ, et al. Paravaginal aggressive angiomyxoma. BMJ Case Rep. 2015;2015doi: 10.1136/bcr-2014-207287. PMID: 25833906.X-2, X-3, X-4

120. Jahan S, Jahan A, Joarder M, et al. Laparoscopic hysterectomy in large uteri: Experience from a tertiary care hospital in Bangladesh. Asian J Endosc Surg. 2015 Aug;8(3):323-7. doi: 10.1111/ases.12184. PMID: 25809981.X-2, X-3, X-4

121. English D, Menderes G, Azodi M. Controlled removal of a large uterus within a bowel bag and morcellation in the bowel bag from the vagina. Gynecol Oncol. 2015 Jun;137(3):589-90. doi: 10.1016/j.ygyno.2015.03.014. PMID: 25797081.X-2, X-3, X-4

122. Mazzon I, Favilli A, Grasso M, et al. Is Cold Loop Hysteroscopic Myomectomy a Safe and Effective Technique for the Treatment of Submucous Myomas With Intramural Development? A Series of 1434 Surgical Procedures. J Minim Invasive Gynecol. 2015 Jul-Aug;22(5):792-8. doi: 10.1016/j.jmig.2015.03.004. PMID: 25796220.X-3

123. Yuk JS, Ji HY, Kim KH, et al. Single-port laparoscopically assisted-transumbilical ultraminilaparotomic myomectomy (SPLA-TUM) versus single port laparoscopic myomectomy: a randomized controlled trial. Eur J Obstet Gynecol Reprod Biol. 2015 May;188:83-7. doi: 10.1016/j.ejogrb.2015.03.004. PMID: 25796058.X-3

124. Lewis EI, Srouji SS, Gargiulo AR. Robotic single-site myomectomy: initial report and technique. Fertil Steril. 2015 May;103(5):1370-7.e1. doi: 10.1016/j.fertnstert.2015.02.021. PMID: 25792248.X-3, X-4

125. Huang X, Huang Q, Chen S, et al. Efficacy of laparoscopic adenomyomectomy using double-flap method for diffuse uterine adenomyosis. BMC Womens Health. 2015;15:24. doi: 10.1186/s12905-015-0182-5. PMID: 25783654.X-3, X-4

126. Bidzinski M, Siergiej M, Radkiewicz J, et al. [Acute urinary retention due to cervical myoma--a case report and a review of the literature]. Ginekol Pol. 2015 Jan;86(1):77-9. PMID: 25775880.X-2, X-3, X-4

127. Sparic R, Malvasi A, Tinelli A. Analysis of clinical, biological and obstetric factors influencing the decision to perform cesarean myomectomy. Ginekol Pol. 2015 Jan;86(1):40-5. PMID: 25775874.X-3

128. Kujansuu S, Salari BW, Galloway M, et al. Contained morcellation using the GelPOINT advance access platforms and 3M Steri-Drape endobag. Fertil Steril. 2015 May;103(5):e36. doi: 10.1016/j.fertnstert.2015.02.017. PMID: 25772767.X-3, X-4

129. Sangha R, Strickler R, Dahlman M, et al. Myomectomy to conserve fertility: seven-year follow-up. J Obstet Gynaecol Can. 2015 Jan;37(1):46-51. PMID: 25764036.X-3

130. Pinzauti S, Lazzeri L, Tosti C, et al. Transvaginal sonographic features of diffuse adenomyosis in 18-30-year-old nulligravid women without endometriosis: association with symptoms. Ultrasound Obstet Gynecol. 2015 Dec;46(6):730-6. doi: 10.1002/uog.14834. PMID: 25728241.X-2, X-3, X-4

131. Begum N, Anwary SA, Alfazzaman M, et al. Pregnancy outcome following myomectomy. Mymensingh Med J. 2015 Jan;24(1):84-8. PMID: 25725672.X-3

132. Okdemir D, Hatipoglu N, Akar HH, et al. A patient developing anaphylaxis and sensitivity to two different GnRH analogues and a review of literature. J Pediatr Endocrinol Metab. 2015 Jul;28(7-8):923-5. doi: 10.1515/jpem-2014-0402. PMID: 25719301.X-2, X-3, X-4

133. Ebner F, Friedl TW, Scholz C, et al. Is open surgery the solution to avoid morcellation of uterine sarcomas? A systematic literature review on the effect of tumor morcellation and surgical techniques. Arch Gynecol Obstet. 2015 Sep;292(3):499-506. doi: 10.1007/s00404-015-3664-7. PMID: 25716668.X-1

134. Stoica RA, Bistriceanu I, Sima R, et al. Laparoscopic myomectomy. J Med Life. 2014 Oct-Dec;7(4):522-4. PMID: 25713613.X-1

135. Srouji SS, Kaser DJ, Gargiulo AR. Techniques for contained morcellation in gynecologic surgery. Fertil Steril. 2015 Apr;103(4):e34. doi: 10.1016/j.fertnstert.2015.01.022. PMID: 25712576.X-1, X-3

136. Khan KN, Kitajima M, Hiraki K, et al. Decreased expression of human heat shock protein 70 in the endometria and pathological lesions of women with adenomyosis and uterine myoma after GnRH agonist therapy. Eur J Obstet Gynecol Reprod Biol. 2015 Apr;187:6-13. doi: 10.1016/j.ejogrb.2015.01.012. PMID: 25697974.X-2, X-3, X-4

137. Floss K, Garcia-Rocha GJ, Kundu S, et al. Fertility and Pregnancy Outcome after Myoma Enucleation by Minilaparotomy under Microsurgical Conditions in Pronounced Uterus Myomatosus. Geburtshilfe Frauenheilkd. 2015 Jan;75(1):56-63. doi: 10.1055/s-0034-1396163. PMID: 25684787.X-3

138. Donat LC, Menderes G, Tower AM, et al. A Technique for Vascular Control During Robotic-assisted Laparoscopic Myomectomy. J Minim Invasive Gynecol. 2015 May-Jun;22(4):543. doi: 10.1016/j.jmig.2015.02.003. PMID: 25680685.X-1

139. Cheng HY, Chen YJ, Wang PH, et al. Robotic-assisted laparoscopic complex myomectomy: a single medical center's experience. Taiwan J Obstet Gynecol. 2015 Feb;54(1):39-42. doi: 10.1016/j.tjog.2014.11.004. PMID: 25675917.X-3

140. Guzel AI, Akselim B, Erkilinc S, et al. Risk factors for adenomyosis, leiomyoma and concurrent adenomyosis and leiomyoma. J Obstet Gynaecol Res. 2015 Jun;41(6):932-7. doi: 10.1111/jog.12635. PMID: 25656315.X-2, X-3, X-4

141. Ton R, Kilic GS, Phelps JY. A medical-legal review of power morcellation in the face of the recent FDA warning and litigation. J Minim Invasive Gynecol. 2015 May-Jun;22(4):564-72. doi: 10.1016/j.jmig.2015.01.017. PMID: 25623369.X-1

142. Lee HJ, Kim JY, Kim SK, et al. Learning Curve Analysis and Surgical Outcomes of Single-port Laparoscopic Myomectomy. J Minim Invasive Gynecol. 2015 May-Jun;22(4):607-11. doi: 10.1016/j.jmig.2015.01.009. PMID: 25614346.X-3

143. Moroni RM, Vieira CS, Ferriani RA, et al. Presentation and treatment of uterine leiomyoma in adolescence: a systematic review. BMC Womens Health. 2015;15:4. doi: 10.1186/s12905-015-0162-9. PMID: 25609056.X-1

144. Mowers EL, Skinner B, McLean K, et al. Effects of morcellation of uterine smooth muscle tumor of uncertain malignant potential and endometrial stromal sarcoma: case series and recommendations for clinical practice. J Minim Invasive Gynecol. 2015 May-Jun;22(4):601-6. doi: 10.1016/j.jmig.2015.01.007. PMID: 25596464.INCLUDE X-3, X-4

145. Goetgheluck J, Carbonnel M, Ayoubi JM. Robotically assisted gynecologic surgery: 2-year experience in the French foch hospital. Front Surg. 2014;1:8. doi: 10.3389/fsurg.2014.00008. PMID: 25593933.X-1, X-3

146. Liu FW, Galvan-Turner VB, Pfaendler KS, et al. A critical assessment of morcellation and its impact on gynecologic surgery and the limitations of the existing literature. Am J Obstet Gynecol. 2015 Jun;212(6):717-24. doi: 10.1016/j.ajog.2015.01.012. PMID: 25582101.INCLUDE X-1

147. Dall'Asta A, Gizzo S, Musaro A, et al. Uterine smooth muscle tumors of uncertain malignant potential (STUMP): pathology, follow-up and recurrence. Int J Clin Exp Pathol. 2014;7(11):8136-42. PMID: 25550862.INCLUDE X-3, X-4

148. Khatuja R, Jain G, Mehta S, et al. Changing trends in use of laparoscopy: a clinical audit. Minim Invasive Surg. 2014;2014:562785. doi: 10.1155/2014/562785. PMID: 25548664.X-2, X-3, X-4

149. Sukur YE, Kankaya D, Ates C, et al. Clinical and histopathologic predictors of reoperation due to recurrence of leiomyoma after laparotomic myomectomy. Int J Gynaecol Obstet. 2015 Apr;129(1):75-8. doi: 10.1016/j.ijgo.2014.10.023. PMID: 25541504.INCLUDE X-2, X-3

150. Elessawy M, Schollmeyer T, Mettler L, et al. The incidence of complications by hysterectomy for benign disease in correlation to an assumed preoperative score. Arch Gynecol Obstet. 2015 Jul;292(1):127-33. doi: 10.1007/s00404-014-3594-9. PMID: 25534160.X-2, X-3, X-4

151. Newbold P, Vithayathil M, Fatania K, et al. Is vaginal hysterectomy is equally safe for the enlarged and normally sized non-prolapse uterus? A cohort study assessing outcomes. Eur J Obstet Gynecol Reprod Biol. 2015 Feb;185:74-7. doi: 10.1016/j.ejogrb.2014.11.031. PMID: 25528733.X-2, X-3, X-4

152. Hurrell A, Oliver R, Agarwal N, et al. Evaluation of the selective use of abdomino-pelvic drains at laparoscopic myomectomy: in enhanced recovery, do drains delay discharge home? Eur J Obstet Gynecol Reprod Biol. 2015 Feb;185:36-40. doi: 10.1016/j.ejogrb.2014.11.027. PMID: 25522116.X-3

153. Samejima T, Koga K, Nakae H, et al. Identifying patients who can improve fertility with myomectomy. Eur J Obstet Gynecol Reprod Biol. 2015 Feb;185:28-32. doi: 10.1016/j.ejogrb.2014.11.033. PMID: 25522114.X-3

154. Gambadauro P. Why is age a major determinant of reproductive outcomes after myomectomy in subfertile women? J Obstet Gynaecol. 2015;35(6):658. doi: 10.3109/01443615.2014.987116. PMID: 25517203.X-1, X-3

155. Huang CY, Wu KY, Su H, et al. Accessibility and surgical outcomes of transumbilical single-port laparoscopy using straight instruments for hysterectomy in difficult conditions. Taiwan J Obstet Gynecol. 2014 Dec;53(4):471-5. doi: 10.1016/j.tjog.2014.08.002. PMID: 25510685.X-2, X-3, X-4

156. Suganuma I, Mori T, Takahara T, et al. Autoamputation of a pedunculated, subserosal uterine leiomyoma presenting as a giant peritoneal loose body. Arch Gynecol Obstet. 2015 Apr;291(4):951-3. doi: 10.1007/s00404-014-3580-2. PMID: 25502368.X-4

157. Saccardi C, Visentin S, Noventa M, et al. Uncertainties about laparoscopic myomectomy during pregnancy: A lack of evidence or an inherited misconception? A critical literature review starting from a peculiar case. Minim Invasive Ther Allied Technol. 2015;24(4):189-94. doi: 10.3109/13645706.2014.987678. PMID: 25496138.X-3, X-4

158. Zhao X, Zeng W, Chen L, et al. Laparoscopic Myomectomy Using "Cold" Surgical Instruments for Uterine Corpus Leiomyoma: A Preliminary Report. Cell Biochem Biophys. 2014 Dec 10doi: 10.1007/s12013-014-0425-3. PMID: 25490906.INCLUDE X-3

159. Chen I, Lisonkova S, Allaire C, et al. Routes of hysterectomy in women with benign uterine disease in the Vancouver Coastal Health and Providence Health Care regions: a retrospective cohort analysis. CMAJ Open. 2014 Oct;2(4):E273-80. doi: 10.9778/cmajo.20130080. PMID: 25485254.INCLUDE X-3

160. Van Heertum K, Barmat L. Uterine fibroids associated with infertility. Womens Health (Lond Engl). 2014 Nov;10(6):645-53. doi: 10.2217/whe.14.27. PMID: 25482490.X-1

161. Ezugwu EC, Iyoke CA, Ezugwu FO, et al. Successful pregnancy following myomectomy for giant uterine fibroid in an infertile woman. J Reprod Infertil. 2014 Oct;15(4):233-6. PMID: 25469327.X-4

162. Corrado G, Fanfani F, Ghezzi F, et al. Mini-laparoscopic versus robotic radical hysterectomy plus systematic pelvic lymphadenectomy in early cervical cancer patients. A multi-institutional study. Eur J Surg Oncol. 2015 Jan;41(1):136-41. doi: 10.1016/j.ejso.2014.10.048. PMID: 25468748.X-2, X-3, X-4

163. Chen CY, Ward JP. A mathematical model of the growth of uterine myomas. Bull Math Biol. 2014 Dec;76(12):3088-121. doi: 10.1007/s11538-014-0045-5. PMID: 25466579.X-1, X-2, X-3, X-4

164. Bogani G, Cliby WA, Aletti GD. Impact of morcellation on survival outcomes of patients with unexpected uterine leiomyosarcoma: a systematic review and meta-analysis. Gynecol Oncol. 2015 Apr;137(1):167-72. doi: 10.1016/j.ygyno.2014.11.011. PMID: 25462199.X-1

165. Gunthert AR, Christmann C, Kostov P, et al. Safe vaginal uterine morcellation following total laparoscopic hysterectomy. Am J Obstet Gynecol. 2015 Apr;212(4):546.e1-4. doi: 10.1016/j.ajog.2014.11.020. PMID: 25460836.X-1

166. Brazet E, Ghassani A, Voglimacci M, et al. [Previa uterine leiomyoma: a rare case of bowel obstruction during pregnancy]. Gynecol Obstet Fertil. 2014 Nov;42(11):806-9. doi: 10.1016/j.gyobfe.2014.09.012. PMID: 25444702.X-3, X-4

167. Anuradha T, Suchi G, Vasundhara K. Large Uterine Fibromyoma: Association with DVT of Pelvic veins and Pulmonary Thromboembolism. A Series of Four Such Rare Cases. J Obstet Gynaecol India. 2014 Dec;64(Suppl 1):70-2. doi: 10.1007/s13224-012-0278-x. PMID: 25404817.X-3, X-4

168. Matsuda M, Ichimura T, Kasai M, et al. Preoperative diagnosis of usual leiomyoma, atypical leiomyoma, and leiomyosarcoma. Sarcoma. 2014;2014:498682. doi: 10.1155/2014/498682. PMID: 25400500.X-1, X-2, X-4

169. Nezhat C, Main J, Paka C, et al. Advanced gynecologic laparoscopy in a fast-track ambulatory surgery center. Jsls. 2014 Jul-Sep;18(3)doi: 10.4293/jsls.2014.00291. PMID: 25392631.INCLUDE X-3

170. Kumar RR, Patil M, Sa S. The utility of caesarean myomectomy as a safe procedure: a retrospective analysis of 21 cases with review of literature. J Clin Diagn Res. 2014 Sep;8(9):Oc05-8. doi: 10.7860/jcdr/2014/8630.4795. PMID: 25386485.X-3

171. Di Tommaso S, Massari S, Malvasi A, et al. Selective genetic analysis of myoma pseudocapsule and potential biological impact on uterine fibroid medical therapy. Expert Opin Ther Targets. 2015 Jan;19(1):7-12. doi: 10.1517/14728222.2014.975793. PMID: 25363374.X-3, X-4

172. Zhao X, Chen L, Zeng W, et al. Laparoscopic tumorectomy for a primary ovarian leiomyoma during pregnancy: A case report. Oncol Lett. 2014 Dec;8(6):2523-6. doi: 10.3892/ol.2014.2596. PMID: 25360170.X-2, X-3, X-4

173. Tian Y, Dai Y. [Analysis of the risk factors for postoperative residue, relapse following myomectomy]. Zhonghua Fu Chan Ke Za Zhi. 2014 Aug;49(8):594-8. PMID: 25354860.X-3

174. Aoki Y, Kikuchi I, Kumakiri J, et al. Long unidirectional barbed suturing technique with extracorporeal traction in laparoscopic myomectomy. BMC Surg. 2014;14:84. doi: 10.1186/1471-2482-14-84. PMID: 25345546.X-3

175. Temizkan O, Erenel H, Arici B, et al. A case of parasitic myoma 4 years after laparoscopic myomectomy. J Minim Access Surg. 2014 Oct;10(4):202-3. doi: 10.4103/0972-9941.141524. PMID: 25336821.X-3, X-4

176. Mazzon I, Favilli A, Grasso M, et al. Is 'cold loop' hysteroscopic myomectomy a better option for reproduction in women with diffuse uterine leiomyomatosis? A case report of successful repeated pregnancies. J Obstet Gynaecol Res. 2015 Mar;41(3):474-7. doi: 10.1111/jog.12548. PMID: 25330711.X-3, X-4

177. Song JY. Laparoscopic resection of a rare, large broad ligament myoma. J Minim Invasive Gynecol. 2015 May-Jun;22(4):530-1. doi: 10.1016/j.jmig.2014.10.003. PMID: 25305571.X-3, X-4

178. Hayashi T, Horiuchi A, Sano K, et al. Potential diagnostic biomarkers: differential expression of LMP2/beta1i and cyclin B1 in human uterine leiomyosarcoma. Tumori. 2014 Jul-Aug;100(4):99e-106e. doi: 10.1700/1636.17918. PMID: 25296613.X-3, X-4

179. Tiwana KK, Nibhoria S, Monga T, et al. Histopathological audit of 373 nononcological hysterectomies in a teaching hospital. Patholog Res Int. 2014;2014:468715. doi: 10.1155/2014/468715. PMID: 25295217.INCLUDE X-3

180. Markowski DN, Helmke BM, Bartnitzke S, et al. Uterine fibroids: do we deal with more than one disease? Int J Gynecol Pathol. 2014 Nov;33(6):568-72. doi: 10.1097/pgp.0000000000000096. PMID: 25272295.X-2, X-3, X-4

181. Kwon DH, Song JE, Yoon KR, et al. The safety of cesarean myomectomy in women with large myomas. Obstet Gynecol Sci. 2014 Sep;57(5):367-72. doi: 10.5468/ogs.2014.57.5.367. PMID: 25264526.X-3

182. Tian YC, Long TF, Dai YM. Pregnancy outcomes following different surgical approaches of myomectomy. J Obstet Gynaecol Res. 2015 Mar;41(3):350-7. doi: 10.1111/jog.12532. PMID: 25256675.X-3

183. Kornats'ka AH, Chubei HV, Brazhuk MV, et al. [Modern possibilities of prophylaxis of intraoperative complications in organ salvage operations on the small pelvis organs]. Klin Khir. 2014 Jun(6):62-5. PMID: 25252559.X-2, X-3, X-4

184. Yi C, Li L, Wang X, et al. Recurrence of uterine tissue residues after laparoscopic hysterectomy or myomectomy. Pak J Med Sci. 2014 Sep;30(5):1134-6. doi: 10.12669/pjms.305.4509. PMID: 25225541.X-3, X-4

185. Chen I, Lisonkova S, Joseph KS, et al. Laparoscopic versus abdominal myomectomy: practice patterns and health care use in British Columbia. J Obstet Gynaecol Can. 2014 Sep;36(9):817-21. PMID: 25222361.INCLUDE X-3

186. Odejinmi F, Maclaran K, Agarwal N. Laparoscopic treatment of uterine fibroids: a comparison of peri-operative outcomes in laparoscopic hysterectomy and myomectomy. Arch Gynecol Obstet. 2015 Mar;291(3):579-84. doi: 10.1007/s00404-014-3434-y. PMID: 25216960.X-3

187. Ragab A, Khaiary M, Badawy A. The Use of Single Versus Double Dose of Intra-vaginal Prostaglandin E2 "Misoprostol" prior to Abdominal Myomectomy: A Randomized Controlled Clinical Trial. J Reprod Infertil. 2014 Jul;15(3):152-6. PMID: 25202673.X-3

188. Oda K, Ikeda Y, Maeda D, et al. Huge pyogenic cervical cyst with endometriosis, developing 13 years after myomectomy at the lower uterine segment: a case report. BMC Womens Health. 2014;14:104. doi: 10.1186/1472-6874-14-104. PMID: 25186472.X-2, X-3, X-4

189. Leone Roberti Maggiore U, Scala C, Venturini PL, et al. Preoperative treatment with letrozole in patients undergoing laparoscopic myomectomy of large uterine myomas: a prospective non-randomized study. Eur J Obstet Gynecol Reprod Biol. 2014 Oct;181:157-62. doi: 10.1016/j.ejogrb.2014.07.040. PMID: 25150954.X-3

190. McCool WF, Durain D, Davis M. Overview of latest evidence on uterine fibroids. Nurs Womens Health. 2014 Aug-Sep;18(4):314-31; quiz 32. doi: 10.1111/1751-486x.12137. PMID: 25145720.X-1

191. Kaygusuz EI. Immunohistochemical expression of CD44 standard and E-cadherin in atypical leiomyoma and leiomyosarcoma of the uterus. J Obstet Gynaecol. 2015 Apr;35(3):279-82. doi: 10.3109/01443615.2014.948821. PMID: 25140670.X-2, X-3, X-4

192. Nam JH, Lyu GS. Abdominal ultrasound-guided transvaginal myometrial core needle biopsy for the definitive diagnosis of suspected adenomyosis in 1032 patients: a retrospective study. J Minim Invasive Gynecol. 2015 Mar-Apr;22(3):395-402. doi: 10.1016/j.jmig.2014.08.006. PMID: 25125243.INCLUDE X-2

193. Yoshida A, Nii S, Matsushita H, et al. Parasitic myoma in women after laparoscopic myomectomy: A late sequela of morcellation? J Obstet Gynaecol. 2015 Apr;35(3):322-3. doi: 10.3109/01443615.2014.948404. PMID: 25111124.X-3

194. Scheib SA, Fader AN. Gynecologic robotic laparoendoscopic single-site surgery: prospective analysis of feasibility, safety, and technique. Am J Obstet Gynecol. 2015 Feb;212(2):179.e1-8. doi: 10.1016/j.ajog.2014.07.057. PMID: 25088863.X-3

195. Ghahiry AA, Refaei Aliabadi E, Taherian AA, et al. Effectiveness of hysteroscopic repair of uterine lesions in reproductive outcome. Int J Fertil Steril. 2014 Jul;8(2):129-34. PMID: 25083176.X-3

196. Jeppson PC, Rahimi S, Gattoc L, et al. Impact of robotic technology on hysterectomy route and associated implications for resident education. Am J Obstet Gynecol. 2015 Feb;212(2):196.e1-6. doi: 10.1016/j.ajog.2014.07.037. PMID: 25068556.X-2, X-3, X-4

197. Obara M, Hatakeyama Y, Shimizu Y. Vaginal Myomectomy for Semipedunculated Cervical Myoma during Pregnancy. AJP Rep. 2014 May;4(1):37-40. doi: 10.1055/s-0034-1370352. PMID: 25032058.X-3, X-4

198. Patsikas M, Papazoglou LG, Jakovljevic S, et al. Radiographic and ultrasonographic findings of uterine neoplasms in nine dogs. J Am Anim Hosp Assoc. 2014 Sep-Oct;50(5):330-7. doi: 10.5326/jaaha-ms-6130. PMID: 25028432.X-2, X-3, X-4

199. Furukawa S, Soeda S, Watanabe T, et al. The measurement of stiffness of uterine smooth muscle tumor by elastography. Springerplus. 2014;3:294. doi: 10.1186/2193-1801-3-294. PMID: 25019043.X-4

200. Nemeth G. [Indications and methods of hysterectomy]. Orv Hetil. 2014 Jul 20;155(29):1152-7. doi: 10.1556/oh.2014.29942. PMID: 25016447.X-1

201. Sun Y, Zhu L, Huang X, et al. Immunohistochemical localization of nerve fibers in the pseudocapsule of fibroids. Eur J Histochem. 2014;58(2):2249. doi: 10.4081/ejh.2014.2249. PMID: 24998917.X-2, X-3

202. Yin XH, Gao LL, Gu Y, et al. Clinical efficiency investigation of laparoscopic uterine artery occlusion combined with myomectomy for uterine fibroids. Int J Clin Exp Med. 2014;7(5):1366-9. PMID: 24995096.X-3

203. Zhang Q, Ubago J, Li L, et al. Molecular analyses of 6 different types of uterine smooth muscle tumors: Emphasis in atypical leiomyoma. Cancer. 2014 Oct 15;120(20):3165-77. doi: 10.1002/cncr.28900. PMID: 24986214.X-2

204. Islam MS, Akhtar MM, Ciavattini A, et al. Use of dietary phytochemicals to target inflammation, fibrosis, proliferation, and angiogenesis in uterine tissues: promising options for prevention and treatment of uterine fibroids? Mol Nutr Food Res. 2014 Aug;58(8):1667-84. doi: 10.1002/mnfr.201400134. PMID: 24976593.X-1

205. Pundir J, Kopeika J, Harris L, et al. Reproductive outcome following abdominal myomectomy for a very large fibroid uterus. J Obstet Gynaecol. 2015 Jan;35(1):37-41. doi: 10.3109/01443615.2014.930097. PMID: 24960287.X-3

206. Xia M, Jing Z, Zhi-Yu H, et al. Feasibility study on energy prediction of microwave ablation upon uterine adenomyosis and leiomyomas by MRI. Br J Radiol. 2014 Aug;87(1040):20130770. doi: 10.1259/bjr.20130770. PMID: 24947033.X-3

207. Otsubo Y, Nishida M, Arai Y, et al. Diffuse uterine leiomyomatosis in patient with successful pregnancy following new surgical management. Arch Gynecol Obstet. 2014 Oct;290(4):815-8. doi: 10.1007/s00404-014-3309-2. PMID: 24930118.X-3, X-4

208. Judson IR, Miah AB. Uterine sarcoma dissemination during myomectomy: if not "acceptable collateral damage," is it possible to mitigate the risk? Cancer. 2014 Oct 15;120(20):3100-2. doi: 10.1002/cncr.28841. PMID: 24925689.INCLUDE X-1

209. Saccardi C, Gizzo S, Noventa M, et al. Limits and complications of laparoscopic myomectomy: which are the best predictors? A large cohort single-center experience. Arch Gynecol Obstet. 2014 Nov;290(5):951-6. doi: 10.1007/s00404-014-3289-2. PMID: 24895193.X-3

210. Nishida M, Ichikawa R, Arai Y, et al. New myomectomy technique for diffuse uterine leiomyomatosis. J Obstet Gynaecol Res. 2014 Jun;40(6):1689-94. doi: 10.1111/jog.12382. PMID: 24888935.X-3

211. Tinelli A, Mynbaev OA, Mettler L, et al. A combined ultrasound and histologic approach for analysis of uterine fibroid pseudocapsule thickness. Reprod Sci. 2014 Sep;21(9):1177-86. doi: 10.1177/1933719114537719. PMID: 24879045.INCLUDE X-3

212. Kim JY, Kim KH, Choi JS, et al. A prospective matched case-control study of laparoendoscopic single-site vs conventional laparoscopic myomectomy. J Minim Invasive Gynecol. 2014 Nov-Dec;21(6):1036-40. doi: 10.1016/j.jmig.2014.04.017. PMID: 24858942.X-3

213. Fernandez H. [Uterine fibroids]. Rev Prat. 2014 Apr;64(4):540-4. PMID: 24855792.X-1

214. Li Y, Liu G, Gao L, et al. [Clinical study of gasless abdominal-wall lifting laparoscopic myomectomy with 5 mm laparoscope]. Zhonghua Yi Xue Za Zhi. 2014 Mar 25;94(11):852-4. PMID: 24854755.X-3

215. Stephenson J. FDA warns against procedure used in removing fibroids. Jama. 2014 May 21;311(19):1956. doi: 10.1001/jama.2014.5182. PMID: 24846021.X-1

216. Canis MJ, Triopon G, Darai E, et al. Adhesion prevention after myomectomy by laparotomy: a prospective multicenter comparative randomized single-blind study with second-look laparoscopy to assess the effectiveness of PREVADH. Eur J Obstet Gynecol Reprod Biol. 2014 Jul;178:42-7. doi: 10.1016/j.ejogrb.2014.03.020. PMID: 24841647.X-3

217. Momeni M, Kalir T, Farag S, et al. Immunohistochemical detection of promyelocytic leukemia zinc finger and histone 1.5 in uterine leiomyosarcoma and leiomyoma. Reprod Sci. 2014 Sep;21(9):1171-6. doi: 10.1177/1933719114532845. PMID: 24784718.X-2, X-3, X-4

218. Kim da H, Kim ML, Song T, et al. Is myomectomy in women aged 45 years and older an effective option? Eur J Obstet Gynecol Reprod Biol. 2014 Jun;177:57-60. doi: 10.1016/j.ejogrb.2014.04.006. PMID: 24768231.X-3

219. Chao HT, Wang PH. Fertility outcomes after uterine artery occlusion in the management of women with symptomatic uterine fibroids. Taiwan J Obstet Gynecol. 2014 Mar;53(1):1-2. doi: 10.1016/j.tjog.2012.10.006. PMID: 24767636.X-3

220. Jiang X, Thapa A, Lu J, et al. Ultrasound-guided transvaginal radiofrequency myolysis for symptomatic uterine myomas. Eur J Obstet Gynecol Reprod Biol. 2014 Jun;177:38-43. doi: 10.1016/j.ejogrb.2014.03.017. PMID: 24766899.X-3

221. Domenici L, Di Donato V, Gasparri ML, et al. Laparotomic myomectomy in the 16th week of pregnancy: a case report. Case Rep Obstet Gynecol. 2014;2014:154347. doi: 10.1155/2014/154347. PMID: 24716028.X-3, X-4

222. Sesti F, Cosi V, Calonzi F, et al. Randomized comparison of total laparoscopic, laparoscopically assisted vaginal and vaginal hysterectomies for myomatous uteri. Arch Gynecol Obstet. 2014 Sep;290(3):485-91. doi: 10.1007/s00404-014-3228-2. PMID: 24710800.X-3

223. Lam SJ, Best S, Kumar S. The impact of fibroid characteristics on pregnancy outcome. Am J Obstet Gynecol. 2014 Oct;211(4):395.e1-5. doi: 10.1016/j.ajog.2014.03.066. PMID: 24705132.X-3

224. Chuang YC, Lu HF, Peng FS, et al. Modified novel technique for improving the success rate of applying seprafilm by using laparoscopy. J Minim Invasive Gynecol. 2014 Sep-Oct;21(5):787-90. doi: 10.1016/j.jmig.2014.02.016. PMID: 24703907.X-3

225. Brucker SY, Hahn M, Kraemer D, et al. Laparoscopic radiofrequency volumetric thermal ablation of fibroids versus laparoscopic myomectomy. Int J Gynaecol Obstet. 2014 Jun;125(3):261-5. doi: 10.1016/j.ijgo.2013.11.012. PMID: 24698202.X-3

226. Tan YL, Naidu A. Rare postpartum ruptured degenerated fibroid: a case report. J Obstet Gynaecol Res. 2014 May;40(5):1423-5. doi: 10.1111/jog.12334. PMID: 24689652.X-2, X-3, X-4

227. Kang JH, Lee DH, Lee JH. Single-port laparoscopically assisted transumbilical ultraminilaparotomic myomectomy. J Minim Invasive Gynecol. 2014 Sep-Oct;21(5):945-50. doi: 10.1016/j.jmig.2014.03.014. PMID: 24681232.X-3

228. Lee CL, Wu KY, Su H, et al. Hysterectomy by transvaginal natural orifice transluminal endoscopic surgery (NOTES): a series of 137 patients. J Minim Invasive Gynecol. 2014 Sep-Oct;21(5):818-24. doi: 10.1016/j.jmig.2014.03.011. PMID: 24681063.X-2, X-3, X-4

229. Bassaw B, Mohammed N, Jaggat A, et al. Experience with a gonadotrophin-releasing hormone agonist prior to myomectomy--comparison of twice- vs thrice-monthly doses and a control group. J Obstet Gynaecol. 2014 Jul;34(5):415-9. doi: 10.3109/01443615.2014.896884. PMID: 24678813.X-3

230. Kim SK, Lee JH, Lee JR, et al. Laparoendoscopic single-site myomectomy versus conventional laparoscopic myomectomy: a comparison of surgical outcomes. J Minim Invasive Gynecol. 2014 Sep-Oct;21(5):775-81. doi: 10.1016/j.jmig.2014.03.002. PMID: 24632396.X-3

231. Grant-Orser A, El Sugy R, Singh SS. Does laparoscopy safely improve technicity for complex hysterectomy cases? J Obstet Gynaecol Can. 2014 Mar;36(3):248-52. PMID: 24612894.X-3

232. Dababneh AS, Nagpal A, Palraj BR, et al. Clostridium hathewayi bacteraemia and surgical site infection after uterine myomectomy. BMJ Case Rep. 2014;2014doi: 10.1136/bcr-2013-009322. PMID: 24596408.X-3, X-4

233. Gallardo Valencia LE, Arredondo RR, Gallardo JJ. Uterine myomas with diffuse abdominal leiomyomatosis. J Minim Invasive Gynecol. 2014 Nov-Dec;21(6):976-7. doi: 10.1016/j.jmig.2014.02.004. PMID: 24518618.X-3

234. Yoon A, Kim TJ, Lee YY, et al. Laparoendoscopic single-site (LESS) myomectomy: characteristics of the appropriate myoma. Eur J Obstet Gynecol Reprod Biol. 2014 Apr;175:58-61. doi: 10.1016/j.ejogrb.2014.01.004. PMID: 24502871.X-3

235. Cattaneo R, 2nd, Hanna RK, Jacobsen G, et al. Interval between hysterectomy and start of radiation treatment is predictive of recurrence in patients with endometrial carcinoma. Int J Radiat Oncol Biol Phys. 2014 Mar 15;88(4):866-71. doi: 10.1016/j.ijrobp.2013.11.247. PMID: 24444758.X-2, X-3, X-4

236. Torre A, Paillusson B, Fain V, et al. Uterine artery embolization for severe symptomatic fibroids: effects on fertility and symptoms. Hum Reprod. 2014 Mar;29(3):490-501. doi: 10.1093/humrep/det459. PMID: 24430777.X-3

237. Fatania K, Vithayathil M, Newbold P, et al. Vaginal versus abdominal hysterectomy for the enlarged non-prolapsed uterus: a retrospective cohort study. Eur J Obstet Gynecol Reprod Biol. 2014 Mar;174:111-4. doi: 10.1016/j.ejogrb.2013.12.003. PMID: 24412144.X-2, X-3, X-4

238. Mboudou E, Morfaw FL, Foumane P, et al. Gynaecological laparoscopic surgery: eight years experience in the Yaounde Gynaeco-Obstetric and Paediatric Hospital, Cameroon. Trop Doct. 2014 Apr;44(2):71-6. doi: 10.1177/0049475513517116. PMID: 24395883.X-2, X-3, X-4

239. Boeer B, Wallwiener M, Rom J, et al. Differences in the clinical phenotype of adenomyosis and leiomyomas: a retrospective, questionnaire-based study. Arch Gynecol Obstet. 2014 Jun;289(6):1235-9. doi: 10.1007/s00404-013-3141-0. PMID: 24389921.X-3

240. Chavez-Lopez M, Reyna-Olivera G, Pedroza-Herrera G. Vascular leiomyoma of the foot: Ultrasound and histologic correlation. Reumatol Clin. 2014 Sep-Oct;10(5):342-3. doi: 10.1016/j.reuma.2013.07.012. PMID: 24269072.X-1, X-2, X-3, X-4

241. Kent A, Shakir F, Jan H. Demonstration of laparoscopic resection of uterine sacculation (niche) with uterine reconstruction. J Minim Invasive Gynecol. 2014 May-Jun;21(3):327. doi: 10.1016/j.jmig.2013.10.013. PMID: 24211376.X-1

242. Yavuzcan A, Caglar M, Ustun Y, et al. Evaluation of the outcomes of laparoscopic hysterectomy for normal and enlarged uterus (>280 g). Arch Gynecol Obstet. 2014 Apr;289(4):831-7. doi: 10.1007/s00404-013-3065-8. PMID: 24178482.X-2, X-3, X-4

243. Borja de Mozota D, Kadhel P, Janky E. Fertility, pregnancy outcomes and deliveries following myomectomy: experience of a French Caribbean University Hospital. Arch Gynecol Obstet. 2014 Mar;289(3):681-6. doi: 10.1007/s00404-013-3038-y. PMID: 24096721.X-3

244. Wang F, Tang L, Wang L, et al. Ultrasound-guided high-intensity focused ultrasound vs laparoscopic myomectomy for symptomatic uterine myomas. J Minim Invasive Gynecol. 2014 Mar-Apr;21(2):279-84. doi: 10.1016/j.jmig.2013.09.004. PMID: 24075837.X-3

245. Incebiyik A, Hilali NG, Camuzcuoglu A, et al. Myomectomy during caesarean: a retrospective evaluation of 16 cases. Arch Gynecol Obstet. 2014 Mar;289(3):569-73. doi: 10.1007/s00404-013-3019-1. PMID: 24013433.X-3

246. Patel PR, Lee J, Rodriguez AM, et al. Disparities in use of laparoscopic hysterectomies: a nationwide analysis. J Minim Invasive Gynecol. 2014 Mar-Apr;21(2):223-7. doi: 10.1016/j.jmig.2013.08.709. PMID: 24012920.X-2, X-3, X-4

247. Douysset X, Verspyck E, Diguet A, et al. [Interstitial pregnancy: experience at Rouen's hospital]. Gynecol Obstet Fertil. 2014 Apr;42(4):216-21. doi: 10.1016/j.gyobfe.2012.09.012. PMID: 23602139.X-2, X-3, X-4

248. Kim YS, Kim BG, Rhim H, et al. Uterine fibroids: semiquantitative perfusion MR imaging parameters associated with the intraprocedural and immediate postprocedural treatment efficiencies of MR imaging-guided high-intensity focused ultrasound ablation. Radiology. 2014 Nov;273(2):462-71. doi: 10.1148/radiol.14132719. PMID: 24988436.X-3

249. Ikink ME, Voogt MJ, van den Bosch MA, et al. Diffusion-weighted magnetic resonance imaging using different b-value combinations for the evaluation of treatment results after volumetric MR-guided high-intensity focused ultrasound ablation of uterine fibroids. Eur Radiol. 2014 Sep;24(9):2118-27. doi: 10.1007/s00330-014-3274-y. PMID: 24962829.X-3

250. Wijlemans JW, de Greef M, Schubert G, et al. A clinically feasible treatment protocol for magnetic resonance-guided high-intensity focused ultrasound ablation in the liver. Invest Radiol. 2015 Jan;50(1):24-31. doi: 10.1097/rli.0000000000000091. PMID: 25198833.X-2, X-3, X-4

251. Leung JH, Yu SC, Cheung EC, et al. Safety and efficacy of sonographically guided high-intensity focused ultrasound for symptomatic uterine fibroids: preliminary study of a modified protocol. J Ultrasound Med. 2014 Oct;33(10):1811-8. doi: 10.7863/ultra.33.10.1811. PMID: 25253828.X-3

252. Jiang N, Xie B, Zhang X, et al. Enhancing ablation effects of a microbubble-enhancing contrast agent ("SonoVue") in the treatment of uterine fibroids with high-intensity focused ultrasound: a randomized controlled trial. Cardiovasc Intervent Radiol. 2014 Oct;37(5):1321-8. doi: 10.1007/s00270-013-0803-z. PMID: 24549267.X-3

253. Zhao WP, Chen JY, Chen WZ. Effect of biological characteristics of different types of uterine fibroids, as assessed with T2-weighted magnetic resonance imaging, on ultrasound-guided high-intensity focused ultrasound ablation. Ultrasound Med Biol. 2015 Feb;41(2):423-31. doi: 10.1016/j.ultrasmedbio.2014.09.022. PMID: 25542494.INCLUDE X-3

254. Quinn SD, Vedelago J, Gedroyc W, et al. Safety and five-year re-intervention following magnetic resonance-guided focused ultrasound (MRgFUS) for uterine fibroids. Eur J Obstet Gynecol Reprod Biol. 2014 Nov;182:247-51. doi: 10.1016/j.ejogrb.2014.09.039. PMID: 25445107.X-3

255. Peng S, Hu L, Chen W, et al. Intraprocedure contrast enhanced ultrasound: the value in assessing the effect of ultrasound-guided high intensity focused ultrasound ablation for uterine fibroids. Ultrasonics. 2015 Apr;58:123-8. doi: 10.1016/j.ultras.2015.01.005. PMID: 25627929.X-3, X-4

256. Wijlemans JW, de Greef M, Schubert G, et al. Intrapleural fluid infusion for MR-guided high-intensity focused ultrasound ablation in the liver dome. Acad Radiol. 2014 Dec;21(12):1597-602. doi: 10.1016/j.acra.2014.06.015. PMID: 25126972.X-2, X-3, X-4

257. Stoelinga B, Huirne J, Heymans MW, et al. The estimated volume of the fibroid uterus: a comparison of ultrasound and bimanual examination versus volume at MRI or hysterectomy. Eur J Obstet Gynecol Reprod Biol. 2015 Jan;184:89-96. doi: 10.1016/j.ejogrb.2014.11.011. PMID: 25481364.X-3, X-4

258. Ikink ME, van Breugel JM, Schubert G, et al. Volumetric MR-Guided High-Intensity Focused Ultrasound with Direct Skin Cooling for the Treatment of Symptomatic Uterine Fibroids: Proof-of-Concept Study. Biomed Res Int. 2015;2015:684250. doi: 10.1155/2015/684250. PMID: 26413538.X-3

259. Geiger D, Napoli A, Conchiglia A, et al. MR-guided focused ultrasound (MRgFUS) ablation for the treatment of nonspinal osteoid osteoma: a prospective multicenter evaluation. J Bone Joint Surg Am. 2014 May 7;96(9):743-51. doi: 10.2106/jbjs.m.00903. PMID: 24806011.X-2, X-3, X-4

260. Filipowska J, Lozinski T. Magnetic Resonance-Guided High-Intensity Focused Ultrasound (MR-HIFU) in Treatment of Symptomatic Uterine Myomas. Pol J Radiol. 2014;79:439-43. doi: 10.12659/pjr.890606. PMID: 25469176.X-1

261. Bucknor MD, Rieke V, Seo Y, et al. Bone remodeling after MR imaging-guided high-intensity focused ultrasound ablation: evaluation with MR imaging, CT, Na(18)F-PET, and histopathologic examination in a swine model. Radiology. 2015 Feb;274(2):387-94. doi: 10.1148/radiol.14132605. PMID: 25302829.X-2, X-3, X-4

262. Courivaud F, Kazaryan AM, Lund A, et al. Thermal fixation of swine liver tissue after magnetic resonance-guided high-intensity focused ultrasound ablation. Ultrasound Med Biol. 2014 Jul;40(7):1564-77. doi: 10.1016/j.ultrasmedbio.2014.02.007. PMID: 24768489.X-2, X-3, X-4

263. Antila K, Nieminen HJ, Sequeiros RB, et al. Automatic segmentation for detecting uterine fibroid regions treated with MR-guided high intensity focused ultrasound (MR-HIFU). Med Phys. 2014 Jul;41(7):073502. doi: 10.1118/1.4881319. PMID: 24989416.X-3

264. Koesters C, Powerski MJ, Froeling V, et al. Uterine artery embolization in single symptomatic leiomyoma: do anatomical imaging criteria predict clinical presentation and long-term outcome? Acta Radiol. 2014 May;55(4):441-9. doi: 10.1177/0284185113497943. PMID: 23943627.X-3

265. Liu J, Keserci B, Yang X, et al. Volume transfer constant (K(trans)) maps from dynamic contrast enhanced MRI as potential guidance for MR-guided high intensity focused ultrasound treatment of hypervascular uterine fibroids. Magn Reson Imaging. 2014 Nov;32(9):1156-61. doi: 10.1016/j.mri.2014.05.005. PMID: 25091628.X-1

266. Burtnyk M, Hill T, Cadieux-Pitre H, et al. Magnetic resonance image guided transurethral ultrasound prostate ablation: a preclinical safety and feasibility study with 28-day followup. J Urol. 2015 May;193(5):1669-75. doi: 10.1016/j.juro.2014.11.089. PMID: 25464003.X-2, X-3, X-4

267. Salgaonkar VA, Prakash P, Rieke V, et al. Model-based feasibility assessment and evaluation of prostate hyperthermia with a commercial MR-guided endorectal HIFU ablation array. Med Phys. 2014 Mar;41(3):033301. doi: 10.1118/1.4866226. PMID: 24593742.X-2, X-3, X-4

268. Huisman M, Lam MK, Bartels LW, et al. Feasibility of volumetric MRI-guided high intensity focused ultrasound (MR-HIFU) for painful bone metastases. J Ther Ultrasound. 2014;2:16. doi: 10.1186/2050-5736-2-16. PMID: 25309743.X-2, X-3, X-4

269. Knuttel FM, Waaijer L, Merckel LG, et al. Histopathology of breast cancer after magnetic resonance-guided high intensity focused ultrasound and radiofrequency ablation. Histopathology. 2016 Jan 5doi: 10.1111/his.12926. PMID: 26732321.X-2, X-3, X-4

270. Tan N, McClure TD, Tarnay C, et al. Women seeking second opinion for symptomatic uterine leiomyoma: role of comprehensive fibroid center. J Ther Ultrasound. 2014;2:3. doi: 10.1186/2050-5736-2-3. PMID: 25512867.X-3

271. Gupta JK, Sinha A, Lumsden MA, et al. Uterine artery embolization for symptomatic uterine fibroids. Cochrane Database Syst Rev. 2014;12:Cd005073. doi: 10.1002/14651858.CD005073.pub4. PMID: 25541260.X-1

272. Xu Y, Fu Z, Yang L, et al. Feasibility, Safety, and Efficacy of Accurate Uterine Fibroid Ablation Using Magnetic Resonance Imaging-Guided High-Intensity Focused Ultrasound With Shot Sonication. J Ultrasound Med. 2015 Dec;34(12):2293-303. doi: 10.7863/ultra.14.12080. PMID: 26518278.X-3

273. Huisman M, Staruch RM, Ladouceur-Wodzak M, et al. Non-Invasive Targeted Peripheral Nerve Ablation Using 3D MR Neurography and MRI-Guided High-Intensity Focused Ultrasound (MR-HIFU): Pilot Study in a Swine Model. PLoS One. 2015;10(12):e0144742. doi: 10.1371/journal.pone.0144742. PMID: 26659073.X-2, X-3, X-4

274. Kroncke T, David M. Magnetic resonance guided focused ultrasound for fibroid treatment--results of the second radiological gynecological expert meeting. Rofo. 2015 Jun;187(6):480-2. doi: 10.1055/s-0034-1399342. PMID: 25901538.X-1

275. Kim YS, Lim HK, Park MJ, et al. Screening Magnetic Resonance Imaging-Based Prediction Model for Assessing Immediate Therapeutic Response to Magnetic Resonance Imaging-Guided High-Intensity Focused Ultrasound Ablation of Uterine Fibroids. Invest Radiol. 2016 Jan;51(1):15-24. doi: 10.1097/rli.0000000000000199. PMID: 26309184.X-3

276. Panagiotopoulou N, Nethra S, Karavolos S, et al. Uterine-sparing minimally invasive interventions in women with uterine fibroids: a systematic review and indirect treatment comparison meta-analysis. Acta Obstet Gynecol Scand. 2014 Sep;93(9):858-67. doi: 10.1111/aogs.12441. PMID: 24909191.X-1

277. Hoogenboom M, van Amerongen MJ, Eikelenboom DC, et al. Development of a high-field MR-guided HIFU setup for thermal and mechanical ablation methods in small animals. J Ther Ultrasound. 2015;3:14. doi: 10.1186/s40349-015-0035-6. PMID: 26269744.X-2, X-3, X-4

278. Cain-Nielsen AH, Moriarty JP, Stewart EA, et al. Cost-effectiveness of uterine-preserving procedures for the treatment of uterine fibroid symptoms in the USA. J Comp Eff Res. 2014 Sep;3(5):503-14. doi: 10.2217/cer.14.32. PMID: 24878319.X-1

279. van Breugel JM, Nijenhuis RJ, Ries MG, et al. Non-invasive magnetic resonance-guided high intensity focused ultrasound ablation of a vascular malformation in the lower extremity: a case report. J Ther Ultrasound. 2015;3:23. doi: 10.1186/s40349-015-0042-7. PMID: 26719802.X-2, X-3, X-4

280. Kim YS, Lee JW, Choi CH, et al. Uterine Fibroids: Correlation of T2 Signal Intensity with Semiquantitative Perfusion MR Parameters in Patients Screened for MR-guided High-Intensity Focused Ultrasound Ablation. Radiology. 2015 Aug 27:150608. doi: 10.1148/radiol.2015150608. PMID: 26313526.X-3, X-4

281. Kim YS. Advances in MR image-guided high-intensity focused ultrasound therapy. Int J Hyperthermia. 2015 May;31(3):225-32. doi: 10.3109/02656736.2014.976773. PMID: 25373687.X-1

282. Zachiu C, Denis de Senneville B, Moonen C, et al. A framework for the correction of slow physiological drifts during MR-guided HIFU therapies: Proof of concept. Med Phys. 2015 Jul;42(7):4137-48. doi: 10.1118/1.4922403. PMID: 26133614.X-2, X-3, X-4

283. Kadlecova J, Hudecek R, Mekinova L, et al. [Histological types of uterine fibroids in reproductive age and postmenopausal women]. Ceska Gynekol. 2015 Oct;80(5):360-4. PMID: 26606122.INCLUDE X-13

284. Yeo SY, Elevelt A, Donato K, et al. Bone metastasis treatment using magnetic resonance-guided high intensity focused ultrasound. Bone. 2015 Dec;81:513-23. doi: 10.1016/j.bone.2015.08.025. PMID: 26325304.X-2, X-3, X-4

285. Anzidei M, Napoli A, Sandolo F, et al. Magnetic resonance-guided focused ultrasound ablation in abdominal moving organs: a feasibility study in selected cases of pancreatic and liver cancer. Cardiovasc Intervent Radiol. 2014 Dec;37(6):1611-7. doi: 10.1007/s00270-014-0861-x. PMID: 24595660.X-2, X-3, X-4

286. Dobrakowski PP, Machowska-Majchrzak AK, Labuz-Roszak B, et al. MR-guided focused ultrasound: a new generation treatment of Parkinson's disease, essential tremor and neuropathic pain. Interv Neuroradiol. 2014 May-Jun;20(3):275-82. doi: 10.15274/nrj-2014-10033. PMID: 24976088.X-1

287. Sofuni A, Moriyasu F, Sano T, et al. Safety trial of high-intensity focused ultrasound therapy for pancreatic cancer. World J Gastroenterol. 2014 Jul 28;20(28):9570-7. doi: 10.3748/wjg.v20.i28.9570. PMID: 25071354.X-2, X-3, X-4

288. Yeo SY, Arias Moreno AJ, van Rietbergen B, et al. Effects of magnetic resonance-guided high-intensity focused ultrasound ablation on bone mechanical properties and modeling. J Ther Ultrasound. 2015;3:13. doi: 10.1186/s40349-015-0033-8. PMID: 26261720.X-2, X-3, X-4

289. Knuttel FM, van den Bosch MA. Magnetic Resonance-Guided High Intensity Focused Ultrasound Ablation of Breast Cancer. Adv Exp Med Biol. 2016;880:65-81. doi: 10.1007/978-3-319-22536-4_4. PMID: 26486332.X-1

290. Hectors SJ, Jacobs I, Heijman E, et al. Multiparametric MRI analysis for the evaluation of MR-guided high intensity focused ultrasound tumor treatment. NMR Biomed. 2015 Sep;28(9):1125-40. doi: 10.1002/nbm.3350. PMID: 26198899.X-1, X-2, X-3, X-4

291. Kosmidis C, Pantos G, Efthimiadis C, et al. Laparoscopic Excision of a Pedunculated Uterine Leiomyoma in Torsion as a Cause of Acute Abdomen at 10 Weeks of Pregnancy. Am J Case Rep. 2015;16:505-8. doi: 10.12659/ajcr.893382. PMID: 26227425.X-3, X-4

292. Sea JC, Bahler CD, Ring JD, et al. Calibration of a novel, laparoscopic, 12-mm, ultrasound, image-guided, high-intensity focused ultrasound probe for ablation of renal neoplasms. Urology. 2015 Apr;85(4):953-8. doi: 10.1016/j.urology.2014.10.063. PMID: 25817123.X-2, X-3, X-4

293. Long L, Chen J, Xiong Y, et al. Efficacy of high-intensity focused ultrasound ablation for adenomyosis therapy and sexual life quality. Int J Clin Exp Med. 2015;8(7):11701-7. PMID: 26380007.X-3

294. Copelan A, Hartman J, Chehab M, et al. High-Intensity Focused Ultrasound: Current Status for Image-Guided Therapy. Semin Intervent Radiol. 2015 Dec;32(4):398-415. doi: 10.1055/s-0035-1564793. PMID: 26622104.X-1

295. Bitton RR, Webb TD, Pauly KB, et al. Improving thermal dose accuracy in magnetic resonance-guided focused ultrasound surgery: Long-term thermometry using a prior baseline as a reference. J Magn Reson Imaging. 2016 Jan;43(1):181-9. doi: 10.1002/jmri.24978. PMID: 26119129.X-2, X-3, X-4

296. Deckers R, Merckel LG, Denis de Senneville B, et al. Performance analysis of a dedicated breast MR-HIFU system for tumor ablation in breast cancer patients. Phys Med Biol. 2015 Jul 21;60(14):5527-42. doi: 10.1088/0031-9155/60/14/5527. PMID: 26133986.X-2, X-3, X-4

297. Kobus T, McDannold N. Update on Clinical Magnetic Resonance-Guided Focused Ultrasound Applications. Magn Reson Imaging Clin N Am. 2015 Nov;23(4):657-67. doi: 10.1016/j.mric.2015.05.013. PMID: 26499282.X-1

298. Kaye EA, Gutta NB, Monette S, et al. Feasibility Study on MR-Guided High-Intensity Focused Ultrasound Ablation of Sciatic Nerve in a Swine Model: Preliminary Results. Cardiovasc Intervent Radiol. 2015 Aug;38(4):985-92. doi: 10.1007/s00270-015-1141-0. PMID: 26040256.X-2, X-3, X-4

299. Chen L, Xiao X, Wang Q, et al. High-intensity focused ultrasound ablation for diffuse uterine leiomyomatosis: A case report. Ultrason Sonochem. 2015 Nov;27:717-21. doi: 10.1016/j.ultsonch.2015.05.032. PMID: 26065820.X-3, X-4

300. Klepac Pulanic T, Venkatesan AM, Segars J, et al. Vaginal Pessary for Uterine Repositioning during High-Intensity Focused Ultrasound Ablation of Uterine Leiomyomas. Gynecol Obstet Invest. 2015 Nov 20doi: 10.1159/000441782. PMID: 26584482.X-3, X-4

301. Diaz-Delgado J, Fernandez A, Edwards JF, et al. Uterine Leiomyoma and Prolapse in a Live-stranded Atlantic Spotted Dolphin (Stenella frontalis). J Comp Pathol. 2015 Jul;153(1):58-63. doi: 10.1016/j.jcpa.2015.04.004. PMID: 25979681.X-2, X-3, X-4

302. Yuk JS, Ji HY, Lee SH, et al. Unexpected uterine malignancy in women who have undergone myomectomy. Int J Gynaecol Obstet. 2015 Jun;129(3):270-1. doi: 10.1016/j.ijgo.2014.12.004. PMID: 25790796.INCLUDE X-3

303. Marshall MB, Haddad NG. Laparoscopic intragastric approach for gastroesophageal leiomyoma and cancer. J Thorac Cardiovasc Surg. 2015 Apr;149(4):1210-2. doi: 10.1016/j.jtcvs.2014.12.030. PMID: 25623901.X-2, X-3, X-4

304. Canto MJ, Palmero S, Palau J, et al. Laparoscopic management of a leiomyoma of the round ligament. J Obstet Gynaecol. 2015 Nov;35(8):856. doi: 10.3109/01443615.2015.1009422. PMID: 25692782.X-3, X-4

305. Wright JD, Cui RR, Wang A, et al. Economic and Survival Implications of Use of Electric Power Morcellation for Hysterectomy for Presumed Benign Gynecologic Disease. J Natl Cancer Inst. 2015 Nov;107(11)doi: 10.1093/jnci/djv251. PMID: 26449386.X-1

306. Choo KJ, Lee HJ, Lee TS, et al. Intrapelvic dissemination of early low-grade endometrioid stromal sarcoma due to electronic morcellation. Obstet Gynecol Sci. 2015 Sep;58(5):414-7. doi: 10.5468/ogs.2015.58.5.414. PMID: 26430669.X-4

307. Erenel H, Temizkan O, Mathyk BA, et al. Parasitic myoma after laparoscopic surgery: a mini-review. J Turk Ger Gynecol Assoc. 2015;16(3):181-6. doi: 10.5152/jtgga.2015.15242. PMID: 26401114.X-1

308. Cohen SL, Morris SN, Brown DN, et al. Contained tissue extraction using power morcellation: prospective evaluation of leakage parameters. Am J Obstet Gynecol. 2015 Sep 6doi: 10.1016/j.ajog.2015.08.076. PMID: 26348384.X-3

309. Winner B, Porter A, Velloze S, et al. Uncontained Compared With Contained Power Morcellation in Total Laparoscopic Hysterectomy. Obstet Gynecol. 2015 Oct;126(4):834-8. doi: 10.1097/aog.0000000000001039. PMID: 26348168.INCLUDE X-3

310. Gajewska M, Wielgos M, Panek G. Critical analysis of cases of endometrial carcinoma of the uterine corpus incidentally diagnosed after incomplete surgery for other indications. Three case reports and a review of the literature. Prz Menopauzalny. 2014 Oct;13(5):305-9. doi: 10.5114/pm.2014.46469. PMID: 26327871.X-2, X-4

311. Tan A, Salfinger S, Tan J, et al. Morcellation of occult uterine malignancies: an Australian single institution retrospective study. Aust N Z J Obstet Gynaecol. 2015 Oct;55(5):503-6. doi: 10.1111/ajo.12401. PMID: 26314239.INCLUDE X-3

312. Akintobi AO, Bello O, Asaolu OA, et al. Laparoscopic supracervical hysterectomy and uterine morcellation: A case report from Asokoro District Hospital, Abuja, Nigeria. Niger J Clin Pract. 2015 Nov-Dec;18(6):824-7. doi: 10.4103/1119-3077.163280. PMID: 26289526.X-3, X-4

313. Montella F, Cosma S, Riboni F, et al. A Safe and Simple Laparoscopic Cold Knife Section Technique for Bulky Uterus Removal. J Laparoendosc Adv Surg Tech A. 2015 Sep;25(9):755-9. doi: 10.1089/lap.2014.0640. PMID: 26275047.X-3

314. Turgal M, Ozgu-Erdinc AS, Beksac K, et al. Myomectomy during cesarean section and adhesion formation as a long-term postoperative complication. Ginekol Pol. 2015 Jun;86(6):457-60. PMID: 26255455.X-3

315. Brito LG, Rosa e Silva JC, Nogueira AA. [Reflections about the impact caused by the Food and Drug Administration (FDA) warning against uterine and/or fibroid power morcellation]. Rev Bras Ginecol Obstet. 2015 Jul;37(7):299-301. doi: 10.1590/s0100-720320150005428. PMID: 26247248.X-1

316. Taylor DK, Holthouser K, Segars JH, et al. Recent scientific advances in leiomyoma (uterine fibroids) research facilitates better understanding and management. F1000Res. 2015;4(F1000 Faculty Rev):183. doi: 10.12688/f1000research.6189.1. PMID: 26236472.X-1

317. Chung YH, Lee SW, Shin SY, et al. Single-port laparoscopic debulking surgery of variant benign metastatic leiomyomatosis with simultaneous lymphatic spreading and intraperitoneal seeding. Obstet Gynecol Sci. 2015 Jul;58(4):314-8. doi: 10.5468/ogs.2015.58.4.314. PMID: 26217603.X-3

318. Wright JD, Tergas AI, Cui R, et al. Use of Electric Power Morcellation and Prevalence of Underlying Cancer in Women Who Undergo Myomectomy. JAMA Oncol. 2015 Apr;1(1):69-77. doi: 10.1001/jamaoncol.2014.206. PMID: 26182307.INCLUDE X-3

319. Chen I, Hopkins L, Firth B, et al. Incidence of Tissue Morcellation During Surgery for Uterine Sarcoma at a Canadian Academic Centre. J Obstet Gynaecol Can. 2015 May;37(5):421-5. PMID: 26168102.X-2, X-3, X-4

320. Ciszak T, Mittal PK, Sullivan P, et al. Case report: MR imaging features of disseminated uterine leiomyosarcoma presenting after hysterectomy with morcellation. Abdom Imaging. 2015 Oct;40(7):2600-5. doi: 10.1007/s00261-015-0486-9. PMID: 26093623.X-4

321. Rimbach S, Holzknecht A, Nemes C, et al. A new in-bag system to reduce the risk of tissue morcellation: development and experimental evaluation during laparoscopic hysterectomy. Arch Gynecol Obstet. 2015 Dec;292(6):1311-20. doi: 10.1007/s00404-015-3788-9. PMID: 26093523.X-2, X-3, X-4

322. Dioun SM, Soliman PT. Laparoscopic hysterectomy with morcellation for a suspected uterine fibroid resulting in dissemination of cervical adenocarcinoma: A case report. Gynecol Oncol Rep. 2015 Apr;12:5-6. doi: 10.1016/j.gore.2014.12.001. PMID: 26076147.X-4

323. Inoue K, Tsubamoto H, Oku H, et al. Complete remission achieved by oophorectomy for recurrent endometrial stromal sarcoma after laparoscopic morcellation. Gynecol Oncol Rep. 2015 Jan;11:1-3. doi: 10.1016/j.gore.2014.10.003. PMID: 26076082.X-2, X-4

324. Chang WC, Chu LH, Huang PS, et al. Comparison of Laparoscopic Myomectomy in Large Myomas With and Without Leuprolide Acetate. J Minim Invasive Gynecol. 2015 Sep-Oct;22(6):992-6. doi: 10.1016/j.jmig.2015.04.026. PMID: 25958038.X-3

325. Lin KH, Torng PL, Tsai KH, et al. Clinical outcome affected by tumor morcellation in unexpected early uterine leiomyosarcoma. Taiwan J Obstet Gynecol. 2015 Apr;54(2):172-7. doi: 10.1016/j.tjog.2015.03.001. PMID: 25951723.X-2, X-3, X-4

326. Leanza V, Gulino FA, Leanza G, et al. Surgical removal of multiple mesenteric fibroids (Kg 4,500) by abdominal spread of previous laparoscopic uterine myomectomy. G Chir. 2015 Jan-Feb;36(1):32-5. PMID: 25827668.X-4

327. Beckmann MW, Juhasz-Boss I, Denschlag D, et al. Surgical Methods for the Treatment of Uterine Fibroids - Risk of Uterine Sarcoma and Problems of Morcellation: Position Paper of the DGGG. Geburtshilfe Frauenheilkd. 2015 Feb;75(2):148-64. doi: 10.1055/s-0035-1545684. PMID: 25797958.X-1

328. Odejinmi F, Agarwal N, Maclaran K, et al. Should we abandon all conservative treatments for uterine fibroids? The problem with leiomyosarcomas. Womens Health (Lond Engl). 2015 Mar;11(2):151-9. doi: 10.2217/whe.14.71. PMID: 25776289.X-1

329. Brolmann H, Tanos V, Grimbizis G, et al. Options on fibroid morcellation: a literature review. Gynecol Surg. 2015;12(1):3-15. doi: 10.1007/s10397-015-0878-4. PMID: 25774118.X-1

330. Vilos GA, Allaire C, Laberge PY, et al. The management of uterine leiomyomas. J Obstet Gynaecol Can. 2015 Feb;37(2):157-81. PMID: 25767949.X-1

331. Singh SS, Scott S, Bougie O, et al. Technical update on tissue morcellation during gynaecologic surgery: its uses, complications, and risks of unsuspected malignancy. J Obstet Gynaecol Can. 2015 Jan;37(1):68-81. PMID: 25764040.X-1

332. Holloran-Schwartz MB, Fierro M, Tritto A. Delayed presentation of a paracytic myoma fragment after laparoscopic supracervical hysterectomy requiring small bowel resection. A case report. J Reprod Med. 2015 Jan-Feb;60(1-2):75-7. PMID: 25745756.X-3, X-4

333. Wallis L. FDA warns against power morcellation for hysterectomy and fibroids. Am J Nurs. 2014 Jul;114(7):16. doi: 10.1097/01.naj.0000451664.53878.83. PMID: 25742335.X-1

334. Graebe K, Garcia-Soto A, Aziz M, et al. Incidental power morcellation of malignancy: a retrospective cohort study. Gynecol Oncol. 2015 Feb;136(2):274-7. doi: 10.1016/j.ygyno.2014.11.018. PMID: 25740603.INCLUDE X-3

335. Leigh B. To morcellate or not to morcellate - is that the question? Bjog. 2015 Mar;122(4):461. doi: 10.1111/1471-0528.13044. PMID: 25702539.X-1

336. Yang R, Xu T, Fu Y, et al. Leiomyomatosis peritonealis disseminata associated with endometriosis: A case report and review of the literature. Oncol Lett. 2015 Feb;9(2):717-20. doi: 10.3892/ol.2014.2741. PMID: 25621042.X-3, X-4

337. Mahnert N, Morgan D, Campbell D, et al. Unexpected gynecologic malignancy diagnosed after hysterectomy performed for benign indications. Obstet Gynecol. 2015 Feb;125(2):397-405. doi: 10.1097/aog.0000000000000642. PMID: 25569001.INCLUDE X-3

338. Harmanli O. Contained power morcellation within an insufflated isolation bag. Obstet Gynecol. 2015 Jan;125(1):229. doi: 10.1097/aog.0000000000000614. PMID: 25560131.X-1

339. Ramos A, Fader AN, Roche KL. Surgical cytoreduction for disseminated benign disease after open power uterine morcellation. Obstet Gynecol. 2015 Jan;125(1):99-102. doi: 10.1097/aog.0000000000000549. PMID: 25560110.X-4

340. Wang CJ, Lee JM, Yu HT, et al. Comparison of morcellator and culdotomy for extraction of uterine fibroids laparoscopically. Eur J Obstet Gynecol Reprod Biol. 2014 Dec;183:183-7. doi: 10.1016/j.ejogrb.2014.10.035. PMID: 25461376.X-3

341. Lieng M, Berner E, Busund B. Risk of morcellation of uterine leiomyosarcomas in laparoscopic supracervical hysterectomy and laparoscopic myomectomy, a retrospective trial including 4791 women. J Minim Invasive Gynecol. 2015 Mar-Apr;22(3):410-4. doi: 10.1016/j.jmig.2014.10.022. PMID: 25460521.INCLUDE X-2

342. Arkenbout EA, van den Haak L, Driessen SR, et al. Assessing basic "physiology" of the morcellation process and tissue spread: a time-action analysis. J Minim Invasive Gynecol. 2015 Feb;22(2):255-60. doi: 10.1016/j.jmig.2014.10.009. PMID: 25460321.X-3

343. Cholkeri-Singh A, Miller CE. Power morcellation in a specimen bag. J Minim Invasive Gynecol. 2015 Feb;22(2):160. doi: 10.1016/j.jmig.2014.10.012. PMID: 25460317.X-1

344. Kondrup JD, Anderson F, Sylvester B, et al. Laparoscopic Morcellation and Tissue Spillage Containment Using the LI Endofield Bag. Surg Technol Int. 2014 Nov;25:162-6. PMID: 25419952.X-1

345. Arora KS, Spillman M, Milad M. Bits and pieces: the ethics of uterine morcellation. Obstet Gynecol. 2014 Dec;124(6):1199-201. doi: 10.1097/aog.0000000000000525. PMID: 25415172.X-1

346. Chin H, Ong XH, Yam PK, et al. Extrauterine fibroids: a diagnostic challenge and a long-term battle. BMJ Case Rep. 2014;2014doi: 10.1136/bcr-2014-204928. PMID: 25395465.X-2, X-3, X-4

347. Brower V. FDA considers restricting or banning laparoscopic morcellation. J Natl Cancer Inst. 2014 Oct;106(10)doi: 10.1093/jnci/dju339. PMID: 25313228.X-1

348. Huang PS, Chang WC, Huang SC. Iatrogenic parasitic myoma: a case report and review of the literature. Taiwan J Obstet Gynecol. 2014 Sep;53(3):392-6. doi: 10.1016/j.tjog.2013.11.007. PMID: 25286798.X-3, X-4

349. Graziano A, Lo Monte G, Hanni H, et al. Laparoscopic supracervical hysterectomy with transcervical morcellation: our experience. J Minim Invasive Gynecol. 2015 Feb;22(2):212-8. doi: 10.1016/j.jmig.2014.09.013. PMID: 25285774.X-3

350. Shen Q, Chen M, Wang Y, et al. Effects of laparoscopic versus minilaparotomic myomectomy on uterine leiomyoma: a meta-analysis. J Minim Invasive Gynecol. 2015 Feb;22(2):177-84. doi: 10.1016/j.jmig.2014.09.007. PMID: 25265886.X-1

351. Ehdaivand S, Simon RA, Sung CJ, et al. Incidental gynecologic neoplasms in morcellated uterine specimens: a case series with follow-up. Hum Pathol. 2014 Nov;45(11):2311-7. doi: 10.1016/j.humpath.2014.07.018. PMID: 25257577.INCLUDE X-3

352. Pereira N, Buchanan TR, Wishall KM, et al. Electric morcellation-related reoperations after laparoscopic myomectomy and nonmyomectomy procedures. J Minim Invasive Gynecol. 2015 Feb;22(2):163-76. doi: 10.1016/j.jmig.2014.09.006. PMID: 25218993.X-1

353. Brown J. AAGL advancing minimally invasive gynecology worldwide: statement to the FDA on power morcellation. J Minim Invasive Gynecol. 2014 Nov-Dec;21(6):970-1. doi: 10.1016/j.jmig.2014.08.780. PMID: 25195157.X-1

354. Pritts EA, Parker WH, Brown J, et al. Outcome of occult uterine leiomyosarcoma after surgery for presumed uterine fibroids: a systematic review. J Minim Invasive Gynecol. 2015 Jan;22(1):26-33. doi: 10.1016/j.jmig.2014.08.781. PMID: 25193444.X-1

355. Cohen SL, Einarsson JI, Wang KC, et al. Contained power morcellation within an insufflated isolation bag. Obstet Gynecol. 2014 Sep;124(3):491-7. doi: 10.1097/aog.0000000000000421. PMID: 25162248.X-3

356. Rardin CR. Mitigating risks of specimen extraction: is in-bag power morcellation an answer? Obstet Gynecol. 2014 Sep;124(3):489-90. doi: 10.1097/aog.0000000000000434. PMID: 25162247.X-3

357. Lee JR, Lee JH, Kim JY, et al. Single port laparoscopic myomectomy with intracorporeal suture-tying and transumbilical morcellation. Eur J Obstet Gynecol Reprod Biol. 2014 Oct;181:200-4. doi: 10.1016/j.ejogrb.2014.07.051. PMID: 25150961.X-3

358. Morice P. [Impact of tumor morcellation during the surgical extraction of solid tumors]. Bull Cancer. 2014 Jun;101(6):526-7. PMID: 25121163.X-3

359. Buckley VA, Nesbitt-Hawes EM, Atkinson P, et al. Laparoscopic myomectomy: clinical outcomes and comparative evidence. J Minim Invasive Gynecol. 2015 Jan;22(1):11-25. doi: 10.1016/j.jmig.2014.08.007. PMID: 25117840.X-1

360. Hampton T. Use of morcellation to remove fibroids scrutinized at FDA hearings. Jama. 2014 Aug 13;312(6):588. doi: 10.1001/jama.2014.10041. PMID: 25117116.X-1

361. Stine JE, Clarke-Pearson DL, Gehrig PA. Uterine morcellation at the time of hysterectomy: techniques, risks, and recommendations. Obstet Gynecol Surv. 2014 Jul;69(7):415-25. doi: 10.1097/ogx.0000000000000088. PMID: 25112590.X-1

362. Bogani G, Serati M, Uccella S, et al. In-bag morcellation for presumed myoma retrieval at laparoscopy. Cancer. 2014 Dec 15;120(24):4004-5. doi: 10.1002/cncr.28959. PMID: 25102972.X-3

363. George S, Muto MG. Reply to in-bag morcellation for presumed myoma retrieval at laparoscopy. Cancer. 2014 Dec 15;120(24):4005. doi: 10.1002/cncr.28957. PMID: 25102828.X-1

364. Ceccaroni M, Roviglione G, Pesci A, et al. Total laparoscopic hysterectomy of very enlarged uterus (3030 g): case report and review of the literature. Wideochir Inne Tech Maloinwazyjne. 2014 Jun;9(2):302-7. doi: 10.5114/wiitm.2014.43026. PMID: 25097706.X-2, X-3, X-4

365. Senapati S, Tu FF, Magrina JF. Power morcellators: a review of current practice and assessment of risk. Am J Obstet Gynecol. 2015 Jan;212(1):18-23. doi: 10.1016/j.ajog.2014.07.046. PMID: 25072737.X-1

366. Kho KA, Nezhat CH. Electric uterine morcellation--reply. Jama. 2014 Jul 2;312(1):96-7. doi: 10.1001/jama.2014.6172. PMID: 25058231.X-1

367. Melamed A. Electric uterine morcellation. Jama. 2014 Jul 2;312(1):96. doi: 10.1001/jama.2014.6169. PMID: 25058230.X-1

368. Wright JD, Tergas AI, Burke WM, et al. Uterine pathology in women undergoing minimally invasive hysterectomy using morcellation. Jama. 2014 Sep 24;312(12):1253-5. doi: 10.1001/jama.2014.9005. PMID: 25051495.INCLUDE X-3

369. Kanade TT, McKenna JB, Choi S, et al. Sydney contained in bag morcellation for laparoscopic myomectomy. J Minim Invasive Gynecol. 2014 Nov-Dec;21(6):981. doi: 10.1016/j.jmig.2014.07.005. PMID: 25048568.X-1

370. Tulandi T, Ferenczy A. Biopsy of uterine leiomyomata and frozen sections before laparoscopic morcellation. J Minim Invasive Gynecol. 2014 Sep-Oct;21(5):963-6. doi: 10.1016/j.jmig.2014.06.010. PMID: 24993657.X-4

371. Cohen SL, Greenberg JA, Wang KC, et al. Risk of leakage and tissue dissemination with various contained tissue extraction (CTE) techniques: an in vitro pilot study. J Minim Invasive Gynecol. 2014 Sep-Oct;21(5):935-9. doi: 10.1016/j.jmig.2014.06.004. PMID: 24928740.X-2, X-3, X-4

372. George S, Barysauskas C, Serrano C, et al. Retrospective cohort study evaluating the impact of intraperitoneal morcellation on outcomes of localized uterine leiomyosarcoma. Cancer. 2014 Oct 15;120(20):3154-8. doi: 10.1002/cncr.28844. PMID: 24923260.INCLUDE X-3

373. Maclaran K, Agarwal N, Odejinmi F. Co-existence of uterine myomas and endometriosis in women undergoing laparoscopic myomectomy: risk factors and surgical implications. J Minim Invasive Gynecol. 2014 Nov-Dec;21(6):1086-90. doi: 10.1016/j.jmig.2014.05.013. PMID: 24905479.X-3

374. . AAGL practice report: Morcellation during uterine tissue extraction. J Minim Invasive Gynecol. 2014 Jul-Aug;21(4):517-30. doi: 10.1016/j.jmig.2014.05.010. PMID: 24865630.X-1

375. Bogani G, Uccella S, Cromi A, et al. Electric motorized morcellator versus transvaginal extraction for myoma retrieval after laparoscopic myomectomy: a propensity-matched analysis. J Minim Invasive Gynecol. 2014 Sep-Oct;21(5):928-34. doi: 10.1016/j.jmig.2014.04.012. PMID: 24780382.X-2, X-3, X-4

376. McCarthy M. US agency warns against morcellation in hysterectomies and myomectomies. Bmj. 2014;348:g2872. doi: 10.1136/bmj.g2872. PMID: 24755656.X-1

377. Goff BA. SGO not soft on morcellation: risks and benefits must be weighed. Lancet Oncol. 2014 Apr;15(4):e148. doi: 10.1016/s1470-2045(14)70075-0. PMID: 24694631.X-1

378. Berman JM, Guido RS, Garza Leal JG, et al. Three-year outcome of the Halt trial: a prospective analysis of radiofrequency volumetric thermal ablation of myomas. J Minim Invasive Gynecol. 2014 Sep-Oct;21(5):767-74. doi: 10.1016/j.jmig.2014.02.015. PMID: 24613404.X-3

379. Hill AJ, Carroll AW, Matthews CA. Unanticipated uterine pathologic finding after morcellation during robotic-assisted supracervical hysterectomy and cervicosacropexy for uterine prolapse. Female Pelvic Med Reconstr Surg. 2014 Mar-Apr;20(2):113-5. doi: 10.1097/SPV.0b013e31829ff5b8. PMID: 24566217.X-2, X-3, X-4

380. Bernardi TS, Radosa MP, Weisheit A, et al. Laparoscopic myomectomy: a 6-year follow-up single-center cohort analysis of fertility and obstetric outcome measures. Arch Gynecol Obstet. 2014 Jul;290(1):87-91. doi: 10.1007/s00404-014-3155-2. PMID: 24504422.X-3

381. Kho KA, Nezhat CH. Evaluating the risks of electric uterine morcellation. Jama. 2014 Mar 5;311(9):905-6. doi: 10.1001/jama.2014.1093. PMID: 24504415.X-1

382. Heller DS, Cracchiolo B. Peritoneal nodules after laparoscopic surgery with uterine morcellation: review of a rare complication. J Minim Invasive Gynecol. 2014 May-Jun;21(3):384-8. doi: 10.1016/j.jmig.2014.01.003. PMID: 24462597.X-1

383. Choi CH, Kim TH, Kim SH, et al. Surgical outcomes of a new approach to laparoscopic myomectomy: single-port and modified suture technique. J Minim Invasive Gynecol. 2014 Jul-Aug;21(4):580-5. doi: 10.1016/j.jmig.2013.12.096. PMID: 24384072.X-3

384. Pluchino N, Litta P, Freschi L, et al. Comparison of the initial surgical experience with robotic and laparoscopic myomectomy. Int J Med Robot. 2014 Jun;10(2):208-12. doi: 10.1002/rcs.1542. PMID: 24123629.X-3

385. Tinelli A, Mettler L, Malvasi A, et al. Impact of surgical approach on blood loss during intracapsular myomectomy. Minim Invasive Ther Allied Technol. 2014 Mar;23(2):87-95. doi: 10.3109/13645706.2013.839951. PMID: 24044380.X-3

386. Uccella S, Cromi A, Serati M, et al. Laparoscopic hysterectomy in case of uteri weighing >/=1 kilogram: a series of 71 cases and review of the literature. J Minim Invasive Gynecol. 2014 May-Jun;21(3):460-5. doi: 10.1016/j.jmig.2013.08.706. PMID: 24012921.X-2, X-3, X-4

387. Gizzo S, Saccardi C, Patrelli TS, et al. Magnetic resonance-guided focused ultrasound myomectomy: safety, efficacy, subsequent fertility and quality-of-life improvements, a systematic review. Reprod Sci. 2014 Apr;21(4):465-76. doi: 10.1177/1933719113497289. PMID: 23868442.X-1

388. Bhave Chittawar P, Franik S, Pouwer AW, et al. Minimally invasive surgical techniques versus open myomectomy for uterine fibroids. Cochrane Database Syst Rev. 2014;10:Cd004638. doi: 10.1002/14651858.CD004638.pub3. PMID: 25331441.X-1

389. McPherson K, Manyonda I, Lumsden MA, et al. A randomised trial of treating fibroids with either embolisation or myomectomy to measure the effect on quality of life among women wishing to avoid hysterectomy (the FEMME study): study protocol for a randomised controlled trial. Trials. 2014;15:468. doi: 10.1186/1745-6215-15-468. PMID: 25432688.X-1, X-3

390. Akkurt MO, Yavuz A, Eris Yalcin S, et al. Can we consider cesarean myomectomy as a safe procedure without long-term outcome? J Matern Fetal Neonatal Med. 2016 Sep 9:1-6. doi: 10.1080/14767058.2016.1228057. PMID: 27550524.X-3

391. Leal MA, Pinera A, De Santiago J, et al. Novel Technique for Contained Power Morcellation through Umbilicus with Insufflated Bag. Gynecol Obstet Invest. 2016 Sep 6doi: 10.1159/000449157. PMID: 27595411.X-4

392. Maccio A, Chiappe G, Kotsonis P, et al. Surgical outcome and complications of total laparoscopic hysterectomy for very large myomatous uteri in relation to uterine weight: a prospective study in a continuous series of 461 procedures. Arch Gynecol Obstet. 2016 Sep;294(3):525-31. doi: 10.1007/s00404-016-4075-0. PMID: 27016346.X-3

393. Yang W, Cheng Z, Yu J, et al. Multicentre study to evaluate the clinical effects of laparoscopic uterine artery occlusion in combination with myomectomy to treat symptomatic uterine leiomyomas. Eur J Obstet Gynecol Reprod Biol. 2016 Sep;204:9-15. doi: 10.1016/j.ejogrb.2016.05.033. PMID: 27471836.INCLUDE X-5

394. Boruta DM, Shibley T. Power Morcellation of Unsuspected High-grade Leiomyosarcoma Within an Inflated Containment Bag: 2-year Follow-up. J Minim Invasive Gynecol. 2016 Sep-Oct;23(6):1009-11. doi: 10.1016/j.jmig.2016.06.017. PMID: 27393286.X-4

395. Kho RM. In the Aftermath of the Storm Called Power Morcellation. J Minim Invasive Gynecol. 2016 Sep-Oct;23(6):847-8. doi: 10.1016/j.jmig.2016.07.001. PMID: 27393284.X-1

396. Fanfani F, Restaino S, Rossitto C, et al. Total Laparoscopic (S-LPS) versus TELELAP ALF-X Robotic-Assisted Hysterectomy: A Case-Control Study. J Minim Invasive Gynecol. 2016 Sep-Oct;23(6):933-8. doi: 10.1016/j.jmig.2016.05.008. PMID: 27247263.X-2, X-3, X-4

397. Uccella S, Casarin J, Marconi N, et al. Laparoscopic Versus Open Hysterectomy for Benign Disease in Women with Giant Uteri (>/=1500 g): Feasibility and Outcomes. J Minim Invasive Gynecol. 2016 Sep-Oct;23(6):922-7. doi: 10.1016/j.jmig.2016.05.002. PMID: 27223048.X-3

398. Sangha R, Katukuri V, Palmer M, et al. Recurrence after robotic myomectomy: is it associated with use of GnRH agonist? J Robot Surg. 2016 Sep;10(3):245-9. doi: 10.1007/s11701-016-0583-y. PMID: 27072151.INCLUDE X-3

399. Hansson BM, Morales-Conde S, Mussack T, et al. Erratum to: The laparoscopic modified Sugarbaker technique is safe and has a low recurrence rate: a multicenter cohort study. Surg Endosc. 2016 Sep;30(9):4160. doi: 10.1007/s00464-016-5079-3. PMID: 27384546.X-1

400. Dedes I, Schaffer L, Zimmermann R, et al. Outcome and risk factors of cesarean delivery with and without cesarean myomectomy in women with uterine myomatas. Arch Gynecol Obstet. 2016 Aug 24doi: 10.1007/s00404-016-4177-8. PMID: 27557891.X-3

401. Istre O. Unexpected Uterine Leiomyosarcoma During Laparoscopic Hysterectomy Treated 6 Months With Ulipristal Acetate and Contained Power Morcellation. J Minim Invasive Gynecol. 2016 Aug 15doi: 10.1016/j.jmig.2016.08.004. PMID: 27539216.X-4

402. Shah DK, Van Voorhis BJ, Vitonis AF, et al. Association Between Body Mass Index, Uterine Size, and Operative Morbidity in Women Undergoing Minimally Invasive Hysterectomy. J Minim Invasive Gynecol. 2016 Aug 11doi: 10.1016/j.jmig.2016.08.003. PMID: 27523922.X-3

403. Ferrero S, Alessandri F, Vellone VG, et al. Three-month treatment with ulipristal acetate prior to laparoscopic myomectomy of large uterine myomas: a retrospective study. Eur J Obstet Gynecol Reprod Biol. 2016 Aug 10;205:43-7. doi: 10.1016/j.ejogrb.2016.08.021. PMID: 27566221.X-3

404. Sato S, Maekawa R, Yamagata Y, et al. Identification of uterine leiomyoma-specific marker genes based on DNA methylation and their clinical application. Sci Rep. 2016;6:30652. doi: 10.1038/srep30652. PMID: 27498619.X-3, X-4

405. Cezar C, Tchartchian G, Korell M, et al. Long term follow-up concerning safety and efficacy of novel adhesion prophylactic agent for laparoscopic myomectomy in the prospective randomized ADBEE study. Best Pract Res Clin Obstet Gynaecol. 2016 Aug;35:97-112. doi: 10.1016/j.bpobgyn.2016.06.003. PMID: 27449312.X-3

406. Noel NL, Isaacson KB. Morcellation complications: From direct trauma to inoculation. Best Pract Res Clin Obstet Gynaecol. 2016 Aug;35:37-43. doi: 10.1016/j.bpobgyn.2015.12.002. PMID: 26879674.X-1

407. Krentel H, De Wilde RL. Complications in Laparoscopic Supracervical Hysterectomy(LASH), especially the morcellation related. Best Pract Res Clin Obstet Gynaecol. 2016 Aug;35:44-50. doi: 10.1016/j.bpobgyn.2015.11.001. PMID: 26694587.INCLUDE X-11

408. Cohen SL, Hariton E, Afshar Y, et al. Updates in uterine fibroid tissue extraction. Curr Opin Obstet Gynecol. 2016 Aug;28(4):277-82. doi: 10.1097/gco.0000000000000280. PMID: 27253236.X-1

409. Lete I, Gonzalez J, Ugarte L, et al. Parasitic leiomyomas: a systematic review. Eur J Obstet Gynecol Reprod Biol. 2016 Aug;203:250-9. doi: 10.1016/j.ejogrb.2016.05.025. PMID: 27359081.X-1

410. Mann C, Karl K, Ertl-Wagner B, et al. Laparoscopic Chromopertubation, Myomectomy with Opening of the Uterine Cavity and Hysteroscopy during the Early Implantation Phase of an Undetected Pregnancy: Delivery of a Child with a Complex Brain Malformation. Geburtshilfe Frauenheilkd. 2016 Aug;76(8):906-9. doi: 10.1055/s-0042-106086. PMID: 27570253.X-4

411. Kanthi JM, Sumathy S, Sreedhar S, et al. Comparative Study of Cesarean Myomectomy with Abdominal Myomectomy in Terms of Blood Loss in Single Fibroid. J Obstet Gynaecol India. 2016 Aug;66(4):287-91. doi: 10.1007/s13224-015-0685-x. PMID: 27382224.X-3

412. Lu B, Xu J, Pan Z. Iatrogenic parasitic leiomyoma and leiomyomatosis peritonealis disseminata following uterine morcellation. J Obstet Gynaecol Res. 2016 Aug;42(8):990-9. doi: 10.1111/jog.13011. PMID: 27125448.INCLUDE X-3

413. Miloro P, Civale J, Rivens I, et al. The Feasibility of Thermal Imaging as a Future Portal Imaging Device for Therapeutic Ultrasound. Ultrasound Med Biol. 2016 Aug;42(8):2033-8. doi: 10.1016/j.ultrasmedbio.2016.03.028. PMID: 27174419.X-1

414. Naval S, Naval R, Naval S, et al. Tips for Safe Laparoscopic Multiple Myomectomy. J Minim Invasive Gynecol. 2016 Jul 20doi: 10.1016/j.jmig.2016.07.012. PMID: 27449692.X-4

415. Sparic R, Malvasi A, Kadija S, et al. Cesarean myomectomy trends and controversies: an appraisal. J Matern Fetal Neonatal Med. 2016 Jul 17:1-10. doi: 10.1080/14767058.2016.1205024. PMID: 27328626.X-1

416. Wilson NM, Faber L, Lidang M, et al. Unexpected uterine malignancy following laparoscopic hysterectomy with morcellation. Acta Oncol. 2016 Jul;55(7):932-4. doi: 10.3109/0284186x.2015.1136752. PMID: 26898521.INCLUDE X-4

417. Thubert T, Foulot H, Vinchant M, et al. Surgical treatment: Myomectomy and hysterectomy; Endoscopy: A major advancement. Best Pract Res Clin Obstet Gynaecol. 2016 Jul;34:104-21. doi: 10.1016/j.bpobgyn.2015.11.021. PMID: 27400649.X-1

418. Petraglia F. Uterine fibroid: from pathogenesis to clinical management. Best Pract Res Clin Obstet Gynaecol. 2016 Jul;34:1-2. doi: 10.1016/j.bpobgyn.2016.01.002. PMID: 26969399.X-1

419. Zepiridis LI, Grimbizis GF, Tarlatzis BC. Infertility and uterine fibroids. Best Pract Res Clin Obstet Gynaecol. 2016 Jul;34:66-73. doi: 10.1016/j.bpobgyn.2015.12.001. PMID: 26856931.X-1

420. Deffieux X, Rochambeau B, Chene G, et al. Hysterectomy for benign disease: clinical practice guidelines from the French College of Obstetrics and Gynecology. Eur J Obstet Gynecol Reprod Biol. 2016 Jul;202:83-91. doi: 10.1016/j.ejogrb.2016.04.006. PMID: 27196085.X-1

421. Vallabh-Patel V, Saiz C, Salamon C, et al. Prevalence of Occult Malignancy Within Morcellated Specimens Removed During Laparoscopic Sacrocolpopexy. Female Pelvic Med Reconstr Surg. 2016 Jul-Aug;22(4):190-3. doi: 10.1097/spv.0000000000000257. PMID: 26945272.INCLUDE X-2

422. Ayaz D, Diniz G, Kahraman DS, et al. The evaluation of the caveolin-1 and AT-rich interactive domain 1 alpha expressions in uterine smooth muscle tumors. Indian J Pathol Microbiol. 2016 Jul-Sep;59(3):301-4. doi: 10.4103/0377-4929.181891. PMID: 27510664.X-4

423. Tinelli R, Litta P, Angioni S, et al. A multicenter study comparing surgical outcomes and ultrasonographic evaluation of scarring after laparoscopic myomectomy with conventional versus barbed sutures. Int J Gynaecol Obstet. 2016 Jul;134(1):18-21. doi: 10.1016/j.ijgo.2015.10.029. PMID: 27209335.X-3

424. Bogani G, Chiappa V, Ditto A, et al. Morcellation of apparent benign uterine myoma: assessing risk to benefit ratio. J Gynecol Oncol. 2016 Jul;27(4):e37. doi: 10.3802/jgo.2016.27.e37. PMID: 27102246.X-1

425. Vizzielli G, Lucidi A, Gallotta V, et al. Robotic Total Mesometrial Resection versus Laparoscopic Total Mesometrial Resection in Early Cervical Cancer: A Case-Control Study. J Minim Invasive Gynecol. 2016 Jul-Aug;23(5):804-9. doi: 10.1016/j.jmig.2016.04.006. PMID: 27109189.X-2

426. Russo M, Suen M, Bedaiwy M, et al. Prevalence of Uterine Myomas Among Women with 2 or More Recurrent Pregnancy Losses: A Systematic Review. J Minim Invasive Gynecol. 2016 Jul-Aug;23(5):702-6. doi: 10.1016/j.jmig.2016.03.018. PMID: 27041652.X-1

427. Noorchashm H, Reed AJ. Tragedy, Trade-offs, and the Demise of Morcellation. N Engl J Med. 2016 Jun 30;374(26):2605. doi: 10.1056/NEJMc1605896. PMID: 27355554.X-1

428. Wallis CJ, Cheung DC, Garbens A, et al. Occurrence of and Risk Factors for Urological Intervention During Benign Hysterectomy: Analysis of the National Surgical Quality Improvement Program Database. Urology. 2016 Jun 29doi: 10.1016/j.urology.2016.06.037. PMID: 27374733.INCLUDE X-3

429. Borahay MA, Fang X, Baillargeon JG, et al. Statin use and uterine fibroid risk in hyperlipidemia patients: a nested case-control study. Am J Obstet Gynecol. 2016 Jun 28doi: 10.1016/j.ajog.2016.06.036. PMID: 27371355.X-3

430. Alkatout I, Mettler L, Gunther V, et al. Safety and economical innovations regarding surgical treatment of fibroids. Minim Invasive Ther Allied Technol. 2016 Jun 22:1-13. doi: 10.1080/13645706.2016.1190380. PMID: 27331342.X-1

431. Gerges B, Mongelli M, Casikar I, et al. 3D transvaginal sonography as pre-operative predictor of the need to morcellate in women undergoing laparoscopic hysterectomy. Ultrasound Obstet Gynecol. 2016 Jun 9doi: 10.1002/uog.15991. PMID: 27281513.INCLUDE X-2

432. Bronshtein M, Blumenfeld Z. The value of TVS after cervical suture. Ultrasound Obstet Gynecol. 2016 Jun 3doi: 10.1002/uog.15984. PMID: 27255211.X-2

433. Salehi PP, Tyson N. Laparoscopic Myomectomy of a Symptomatic Uterine Leiomyoma in a 15-Year-Old Adolescent. J Pediatr Adolesc Gynecol. 2016 Jun 2doi: 10.1016/j.jpag.2016.05.007. PMID: 27262836.X-4

434. Levast F, Legendre G, Bouet PE, et al. [Management of uterine myomas during pregnancy]. Gynecol Obstet Fertil. 2016 Jun;44(6):350-4. doi: 10.1016/j.gyobfe.2016.04.007. PMID: 27216952.X-1

435. Tovar-Spinoza Z, Choi H. Magnetic resonance-guided laser interstitial thermal therapy: report of a series of pediatric brain tumors. J Neurosurg Pediatr. 2016 Jun;17(6):723-33. doi: 10.3171/2015.11.peds15242. PMID: 26849811.X-2

436. Mazzon I, Bettocchi S, Fascilla F, et al. Resectoscopic myomectomy. Minerva Ginecol. 2016 Jun;68(3):334-44. PMID: 27008062.X-1

437. A DISS, Ceci O, Zizolfi B, et al. Office myomectomy. Minerva Ginecol. 2016 Jun;68(3):321-7. PMID: 26928418.X-1

438. Dubuisson JB, O'Leary T, Feki A, et al. Laparoscopic myomectomy. Minerva Ginecol. 2016 Jun;68(3):345-51. PMID: 26928417.X-1

439. Yuk JS, Kim LY, Kim SH, et al. The Incidence of Unexpected Uterine Malignancy in Women Undergoing Hysterectomy for a Benign Condition: A National Population-Based Study. Ann Surg Oncol. 2016 May 24doi: 10.1245/s10434-016-5287-z. PMID: 27221362.INCLUDE X-2

440. Torok P, Poka R. [Diagnosis and treatment of uterine myoma]. Orv Hetil. 2016 May 22;157(21):813-9. doi: 10.1556/650.2016.30435. PMID: 27177787.X-1

441. Anapolski M, Panayotopoulos D, Alkatout I, et al. Preclinical safety testing for morcellation and extraction for an endobag with sealable ports: in vitro pilot study. Surg Endosc. 2016 May 18doi: 10.1007/s00464-016-4969-8. PMID: 27194256.X-2

442. Gargiulo AR, Choussein S, Srouji SS, et al. Coaxial robot-assisted laparoendoscopic single-site myomectomy. J Robot Surg. 2016 May 10doi: 10.1007/s11701-016-0603-y. PMID: 27165100.X-3

443. Sugarbaker P, Ihemelandu C, Bijelic L. Cytoreductive Surgery and HIPEC as a Treatment Option for Laparoscopic Resection of Uterine Leiomyosarcoma with Morcellation: Early Results. Ann Surg Oncol. 2016 May;23(5):1501-7. doi: 10.1245/s10434-015-4960-y. PMID: 26545375.X-2

444. Falcone T, Flyckt R. Tissue extraction technique at the time of laparoscopic myomectomy. Fertil Steril. 2016 May;105(5):1158-9. doi: 10.1016/j.fertnstert.2016.01.038. PMID: 26900978.X-1

445. Kramer B, Hahn M, Taran FA, et al. Interim analysis of a randomized controlled trial comparing laparoscopic radiofrequency volumetric thermal ablation of uterine fibroids with laparoscopic myomectomy. Int J Gynaecol Obstet. 2016 May;133(2):206-11. doi: 10.1016/j.ijgo.2015.10.008. PMID: 26892690.INCLUDE X-2

446. Hickman LC, Kotlyar A, Shue S, et al. Hemostatic Techniques for Myomectomy: An Evidence-Based Approach. J Minim Invasive Gynecol. 2016 May-Jun;23(4):497-504. doi: 10.1016/j.jmig.2016.01.026. PMID: 26855249.X-1

447. Guan X, Walsh TM. Hand-Assisted Laparoscopic Hysterectomy for Large Uteri. J Minim Invasive Gynecol. 2016 May-Jun;23(4):652-3. doi: 10.1016/j.jmig.2016.01.023. PMID: 26851416.INCLUDE X-1

448. Bogani G, Ditto A, Martinelli F, et al. Morcellator's Port-site Metastasis of a Uterine Smooth Muscle Tumor of Uncertain Malignant Potential After Minimally Invasive Myomectomy. J Minim Invasive Gynecol. 2016 May-Jun;23(4):647-9. doi: 10.1016/j.jmig.2016.01.021. PMID: 26851127.X-4

449. Balgobin S, Maldonado PA, Chin K, et al. Safety of Manual Morcellation After Vaginal or Laparoscopic-assisted Vaginal Hysterectomy. J Minim Invasive Gynecol. 2016 May-Jun;23(4):542-7. doi: 10.1016/j.jmig.2016.01.014. PMID: 26802908.INCLUDE X-11

450. Gagliardo C, Geraci L, Napoli A, et al. [Non-invasive trans-cranial magnetic resonance imaging-guided focused ultrasounds surgery to treat neurologic disorders]. Recenti Prog Med. 2016 May;107(5):242-5. doi: 10.1701/2260.24338. PMID: 27311124.INCLUDE X-1

451. Sparic R. Intraoperative hemorrhage as a complication of cesarean myomectomy: analysis of risk factors. Vojnosanit Pregl. 2016 May;73(5):415-21. PMID: 27430104.X-3

452. Bourdel N, Collins T, Pizarro D, et al. Augmented reality in gynecologic surgery: evaluation of potential benefits for myomectomy in an experimental uterine model. Surg Endosc. 2016 Apr 29doi: 10.1007/s00464-016-4932-8. PMID: 27129565.X-2

453. Neis KJ, Zubke W, Fehr M, et al. Hysterectomy for Benign Uterine Disease. Dtsch Arztebl Int. 2016 Apr 8;113(14):242-9. doi: 10.3238/arztebl.2016.0242. PMID: 27146592.X-1

454. Leone Roberti Maggiore U, Biscaldi E, Vellone GV, et al. Magnetic resonance enema versus rectal water contrast transvaginal ultrasonography in the diagnosis of rectosigmoid endometriosis. Ultrasound Obstet Gynecol. 2016 Apr 8doi: 10.1002/uog.15934. PMID: 27060846.X-2

455. Yuk JS, Ji HY, Shin JY, et al. Comparison of Survival Outcomes in Women with Unsuspected Uterine Malignancy Diagnosed After Laparotomic Versus Laparoscopic Myomectomy: A National, Population-Based Study. Ann Surg Oncol. 2016 Apr;23(4):1287-93. doi: 10.1245/s10434-015-4976-3. PMID: 26577118.INCLUDE X-2

456. Olah KS. Re: Laparoscopic morcellation: an acceptable risk or an Achilles heel? Are there safer alternatives to morcellation? BJOG. 2016 Apr;123(5):840-1. doi: 10.1111/1471-0528.13833. PMID: 27149352.X-1

457. Willame A, Marci R, Petignat P, et al. Myoma migration: an unexpected "effect" with Ulipristal acetate treatment. Eur Rev Med Pharmacol Sci. 2016 Apr;20(8):1439-44. PMID: 27160112.X-3, X-4

458. Deffieux X, Vinchant M, Thubert T. [How I perform... a uterine morcellation in an isolation bag?]. Gynecol Obstet Fertil. 2016 Apr;44(4):250-2. doi: 10.1016/j.gyobfe.2016.02.017. PMID: 27032762.X-1

459. Bhandari S, Ganguly I, Agarwal P, et al. Effect of myomectomy on endometrial cavity: A prospective study of 51 cases. J Hum Reprod Sci. 2016 Apr-Jun;9(2):107-11. doi: 10.4103/0974-1208.183509. PMID: 27382236.X-3

460. Urman B, Ata B, Arslan T, et al. Parasitic Myomas and an Adenomyoma Obstructing the Ureter After Power Morcellation of Myomas and Endometriotic Nodule Resection. J Obstet Gynaecol Can. 2016 Apr;38(4):362-5. doi: 10.1016/j.jogc.2016.02.011. PMID: 27208606.X-3, X-4

461. Madigan CD, Daley AJ, Lewis AL, et al. Erratum to: Is self-weighing an effective tool for weight loss: a systematic literature review and meta-analysis. Int J Behav Nutr Phys Act. 2016;13:42. doi: 10.1186/s12966-016-0366-x. PMID: 27029188.X-1

462. McCarthy M. New England Journal of Medicine essay on morcellation prompts a call for retraction. BMJ. 2016;352:i1752. doi: 10.1136/bmj.i1752. PMID: 27013619.X-1

463. Van den Bosch T, Votino A, Cornelis A, et al. Optimizing the Histological Diagnosis of Adenomyosis Using in vitro Three-Dimensional Ultrasonography. Gynecol Obstet Invest. 2016 Mar 23doi: 10.1159/000445072. PMID: 27002642.X-2

464. Tinelli A, Mynbaev OA, Sparic R, et al. Angiogenesis and Vascularization of Uterine Leiomyoma: Clinical Value of Pseudocapsule Containing Peptides and Neurotransmitters. Curr Protein Pept Sci. 2016 Mar 22 PMID: 27001060.INCLUDE X-1

465. Ojo-Carons M, Mumford SL, Armstrong AY, et al. Is Myomectomy Prior to Assisted Reproductive Technology Cost Effective in Women with Intramural Fibroids? Gynecol Obstet Invest. 2016 Mar 19doi: 10.1159/000443391. PMID: 26990761.X-2

466. Kang SY, Jeung IC, Chung YJ, et al. Robot-assisted laparoscopic myomectomy for deep intramural myomas. Int J Med Robot. 2016 Mar 16doi: 10.1002/rcs.1742. PMID: 26989866.X-3

467. Rosenbaum L. N-of-1 Policymaking--Tragedy, Trade-offs, and the Demise of Morcellation. N Engl J Med. 2016 Mar 10;374(10):986-90. doi: 10.1056/NEJMms1516161. PMID: 26962735.X-1

468. Kacperczyk J, Bartnik P, Romejko-Wolniewicz E, et al. Postmyomectomic Uterine Rupture Despite Cesarean Section. Anticancer Res. 2016 Mar;36(3):1011-3. PMID: 26976991.X-4

469. Bongers M. Advances in laparoscopic surgery have made vaginal hysterectomy in the absence of prolapse obsolete: FOR: The laparoscopic approach is suitable for almost all hysterectomies. BJOG. 2016 Mar;123(4):633. doi: 10.1111/1471-0528.13905. PMID: 26914896.X-1

470. Shehata A, Hussein N, El Halwagy A, et al. Ileo-uterine fistula in a degenerated posterior wall fibroid after Caesarean section. Clin Exp Reprod Med. 2016 Mar;43(1):51-3. doi: 10.5653/cerm.2016.43.1.51. PMID: 27104158.X-4

471. Jeong JH, Kim YR, Hong KP, et al. Clinical experience with single-port access laparoscopic cystectomy and myomectomy. Clin Exp Reprod Med. 2016 Mar;43(1):44-50. doi: 10.5653/cerm.2016.43.1.44. PMID: 27104157.X-3

472. Endo Y. CORR Insights((R)): Is MR-guided High-intensity Focused Ultrasound a Feasible Treatment Modality for Desmoid Tumors? Clin Orthop Relat Res. 2016 Mar;474(3):705-6. doi: 10.1007/s11999-015-4427-2. PMID: 26126990.X-1

473. Avedian RS, Bitton R, Gold G, et al. Is MR-guided High-intensity Focused Ultrasound a Feasible Treatment Modality for Desmoid Tumors? Clin Orthop Relat Res. 2016 Mar;474(3):697-704. doi: 10.1007/s11999-015-4364-0. PMID: 26040967.X-2

474. Duvnjak S. Intermediate and long-term outcomes following uterine artery fibroid embolization. Eur J Obstet Gynecol Reprod Biol. 2016 Mar;198:153. doi: 10.1016/j.ejogrb.2015.11.005. PMID: 26691290.X-1

475. Jacoby VL, Kohi MP, Poder L, et al. PROMISe trial: a pilot, randomized, placebo-controlled trial of magnetic resonance guided focused ultrasound for uterine fibroids. Fertil Steril. 2016 Mar;105(3):773-80. doi: 10.1016/j.fertnstert.2015.11.014. PMID: 26658133.X-3

476. Rivas-Lopez R, Duron-Padilla R, Romero-Hernandez S, et al. [Robotic-assisted laparoscopic myomectomy and pregnancy. Case report]. Ginecol Obstet Mex. 2016 Mar;84(3):194-200. PMID: 27424446.X-3, X-4

477. Dubuisson J, Veit-Rubin N. [Uterine volume and vaginal hysterectomy: Interest and limits of uterine morcellation]. Gynecol Obstet Fertil. 2016 Mar;44(3):175-80. doi: 10.1016/j.gyobfe.2016.01.008. PMID: 26966037.X-1

478. Parker W, Berek JS, Pritts E, et al. An Open Letter to the Food and Drug Administration Regarding the Use of Morcellation Procedures in Women Having Surgery for Presumed Uterine Myomas. J Minim Invasive Gynecol. 2016 Mar-Apr;23(3):303-8. doi: 10.1016/j.jmig.2015.12.012. PMID: 26773577.X-1

479. Dakhly DM, Abdel Moety GA, Saber W, et al. Accuracy of Hysteroscopic Endomyometrial Biopsy in Diagnosis of Adenomyosis. J Minim Invasive Gynecol. 2016 Mar-Apr;23(3):364-71. doi: 10.1016/j.jmig.2015.11.004. PMID: 26581187.X-2

480. Kho KA, Lin K, Hechanova M, et al. Risk of Occult Uterine Sarcoma in Women Undergoing Hysterectomy for Benign Indications. Obstet Gynecol. 2016 Mar;127(3):468-73. doi: 10.1097/aog.0000000000001242. PMID: 26855091.INCLUDE X-2

481. Wang H, Zhao J, Li X, et al. The indication and curative effect of hysteroscopic and laparoscopic myomectomy for type II submucous myomas. BMC Surg. 2016;16:9. doi: 10.1186/s12893-016-0124-7. PMID: 26922480.X-3

482. Merckel LG, Knuttel FM, Deckers R, et al. First clinical experience with a dedicated MRI-guided high-intensity focused ultrasound system for breast cancer ablation. Eur Radiol. 2016 Feb 6doi: 10.1007/s00330-016-4222-9. PMID: 26852219.X-2

483. Chattopadhyay S. Modified Frailty Index (mFI) in major gynaecological surgery: does it predict outcome? BJOG. 2016 Feb;123(3):462. doi: 10.1111/1471-0528.13690. PMID: 26552733.X-1

484. Rodriguez AM, Asoglu MR, Sak ME, et al. Incidence of occult leiomyosarcoma in presumed morcellation cases: a database study. Eur J Obstet Gynecol Reprod Biol. 2016 Feb;197:31-5. doi: 10.1016/j.ejogrb.2015.11.009. PMID: 26699101.INCLUDE X-11

485. Garcia-de la Torre JI, Aguirre-Ramos MA, Ramos-Alvarado AM, et al. [Myomectomy and uterine desarterialization as conservative treatment for uterine fibroids: Review of clinic case]. Ginecol Obstet Mex. 2016 Feb;84(2):112-21. PMID: 27323417.X-4

486. Asnani M, Srivastava K, Gupta HP, et al. A rare case of giant vaginal fibromyoma. Intractable Rare Dis Res. 2016 Feb;5(1):44-6. doi: 10.5582/irdr.2015.01037. PMID: 26989649.X-2

487. Mandato VD, Torricelli F, Pirillo D, et al. Impact of the Food and Drug Administration Safety Communication on the Use of Power Morcellator in Daily Clinical Practice: An Italian Survey. J Minim Invasive Gynecol. 2016 Feb 1;23(2):206-14. doi: 10.1016/j.jmig.2015.09.021. PMID: 26454195.X-2, X-4

488. . College Publications (December 2015): Correction. Obstet Gynecol. 2016 Feb;127(2):405. doi: 10.1097/01.AOG.0000480402.22371.a4. PMID: 26942376.X-1

489. Chi AM, Curran DS, Morgan DM, et al. Universal Cystoscopy After Benign Hysterectomy: Examining the Effects of an Institutional Policy. Obstet Gynecol. 2016 Feb;127(2):369-75. doi: 10.1097/aog.0000000000001271. PMID: 26942367.X-3

490. Kalogiannidis I, Stavrakis T, Dagklis T, et al. A clinicopathological study of atypical leiomyomas: Benign variant leiomyoma or smooth-muscle tumor of uncertain malignant potential. Oncol Lett. 2016 Feb;11(2):1425-8. doi: 10.3892/ol.2015.4062. PMID: 26893755.INCLUDE X-2

491. Gulati N, Raman S, Srinivasan M, et al. Rare gynaecological emergency: massive intraperitoneal haemorrhage from spontaneous rupture of a superficial vessel on a large leiomyoma. BMJ Case Rep. 2016;2016doi: 10.1136/bcr-2015-212576. PMID: 26825935.X-4

492. Bohlin KS, Ankardal M, Stjerndahl JH, et al. Influence of the modifiable life-style factors body mass index and smoking on the outcome of hysterectomy. Acta Obstet Gynecol Scand. 2016 Jan;95(1):65-73. doi: 10.1111/aogs.12794. PMID: 26459279.X-3

493. Aubry JF, Tanter M. MR-Guided Transcranial Focused Ultrasound. Adv Exp Med Biol. 2016;880:97-111. doi: 10.1007/978-3-319-22536-4_6. PMID: 26486334.X-1

494. de Senneville BD, Moonen C, Ries M. MRI-Guided HIFU Methods for the Ablation of Liver and Renal Cancers. Adv Exp Med Biol. 2016;880:43-63. doi: 10.1007/978-3-319-22536-4_3. PMID: 26486331.X-1

495. Gincheva D, Nikolova M. [Disseminated Peritoneal Leyomyomatosis after Laparoscopic Morcellation--a Case Report]. Akush Ginekol (Sofiia). 2016;55(3):36-9. PMID: 27514144.X-4

496. Kehde BH, van Herendael BJ, Tas B, et al. Large uterus: what is the limit for a laparoscopic approach? Autops Case Rep. 2016 Jan-Mar;6(1):51-6. doi: 10.4322/acr.2016.025. PMID: 27284542.X-4

497. Wang H, Li P, Li X, et al. Total Laparoscopic Hysterectomy in Patients with Large Uteri: Comparison of Uterine Removal by Transvaginal and Uterine Morcellation Approaches. Biomed Res Int. 2016;2016:8784601. doi: 10.1155/2016/8784601. PMID: 27419141.X-3

498. Van der Meulen JF, Pijnenborg JM, Boomsma CM, et al. Parasitic myoma after laparoscopic morcellation: a systematic review of the literature. BJOG. 2016 Jan;123(1):69-75. doi: 10.1111/1471-0528.13541. PMID: 26234998.X-1

499. Takeda A, Nakamura H. Torsion of a Subserosal Myoma Managed by Gasless Laparoendoscopic Single-Site Myomectomy with In-Bag Manual Extraction. Case Rep Obstet Gynecol. 2016;2016:7831270. doi: 10.1155/2016/7831270. PMID: 27034863.X-4

500. Sato K, Fukushima Y. Minilaparotomy Hysterectomy as a Suitable Choice of Hysterectomy for Large Myoma Uteri: Literature Review. Case Rep Obstet Gynecol. 2016;2016:6945061. doi: 10.1155/2016/6945061. PMID: 26925276.X-4

501. Sutton C, Standen P, Acton J, et al. Spontaneous Uterine Rupture in a Preterm Pregnancy following Myomectomy. Case Rep Obstet Gynecol. 2016;2016:6195621. doi: 10.1155/2016/6195621. PMID: 26925275.X-4

502. Purohit P, Vigneswaran K. Fibroids and Infertility. Curr Obstet Gynecol Rep. 2016;5:81-8. doi: 10.1007/s13669-016-0162-2. PMID: 27217980.X-1

503. Peeters N, Hulsbosch S, Ballaux F, et al. Uterine smooth muscle tumors of uncertain malignant potential: analysis of diagnoses and therapies illustrated by two case reports. Eur J Gynaecol Oncol. 2016;37(3):367-73. PMID: 27352566.X-2

504. Lo Monte G, Piva I, Graziano A, et al. Ulipristal acetate prior to in vitro fertilization in a female patient affected by uterine fibroids: a case report. Eur Rev Med Pharmacol Sci. 2016;20(2):202-7. PMID: 26875885.X-4

505. Romanek-Piva K, Galczynski K, Adamiak-Godlewska A, et al. Hysterectomy trends for benign indications over a 15-year period in an academic teaching center in Poland: a retrospective cohort study. Ginekol Pol. 2016;87(6):411-6. doi: 10.5603/gp.2016.0017. PMID: 27418216.X-3

506. Campbell JE, Knudtson JF, Valente PT, et al. Successful pregnancy following myomectomy for uterine smooth muscle tumor of uncertain malignant potential: A case report and review of the literature. Gynecol Oncol Rep. 2016 Jan;15:1-3. doi: 10.1016/j.gore.2015.07.005. PMID: 26937476.X-2

507. Van den Bosch T. Ex abundanti cautela: From the tragedy of inadvertent sarcoma morcellation to inappropriate myoma screening. Gynecol Surg. 2016;13:73-4. doi: 10.1007/s10397-016-0932-x. PMID: 27226785.X-1

508. Thompson MJ, Carr BR. Intramural myomas: to treat or not to treat. Int J Womens Health. 2016;8:145-9. doi: 10.2147/ijwh.s105955. PMID: 27274313.X-3

509. Cheung VY, Pun TC. Contained Morcellation for Laparoscopic Myomectomy Within a Specially Designed Bag. J Minim Invasive Gynecol. 2016 Jan;23(1):139-40. doi: 10.1016/j.jmig.2015.08.889. PMID: 26391058.X-1

510. Paul PG, Thomas M, Das T, et al. Reply to Letter: Contained Morcellation for Laparoscopic Myomectomy Within a Specially Designed Bag. J Minim Invasive Gynecol. 2016 Jan;23(1):140. doi: 10.1016/j.jmig.2015.09.007. PMID: 26391056.X-1

511. Arendas K, Leyland NA. Use of Ulipristal Acetate for the Management of Fibroid-Related Acute Abnormal Uterine Bleeding. J Obstet Gynaecol Can. 2016 Jan;38(1):80-3. doi: 10.1016/j.jogc.2015.11.005. PMID: 26872761.X-4

512. Murad K. Spontaneous Pregnancy Following Ulipristal Acetate Treatment in a Woman with a Symptomatic Uterine Fibroid. J Obstet Gynaecol Can. 2016 Jan;38(1):75-9. doi: 10.1016/j.jogc.2015.11.004. PMID: 26872760.X-4

513. Dogan S, Ozyuncu O, Atak Z. Fibroids During Pregnancy: Effects on Pregnancy and Neonatal Outcomes. J Reprod Med. 2016 Jan-Feb;61(1-2):52-7. PMID: 26995889.X-3

514. Zhu Y, Keserci B, Viitala A, et al. Volumetric MR-guided high-intensity focused ultrasound ablation to treat uterine fibroids through the abdominal scars using scar patch: a case report. J Ther Ultrasound. 2016;4:20. doi: 10.1186/s40349-016-0064-9. PMID: 27525101.X-4

515. Gunnala V, Setton R, Pereira N, et al. Robot-Assisted Myomectomy for Large Uterine Myomas: A Single Center Experience. Minim Invasive Surg. 2016;2016:4905292. doi: 10.1155/2016/4905292. PMID: 27034828.X-3

516. Cho IA, Baek JC, Park JK, et al. Torsion of a parasitic myoma that developed after abdominal myomectomy. Obstet Gynecol Sci. 2016 Jan;59(1):75-8. doi: 10.5468/ogs.2016.59.1.75. PMID: 26866042.X-4

517. Kim YS, Lim HK, Rhim H. Magnetic Resonance Imaging-Guided High-Intensity Focused Ultrasound Ablation of Uterine Fibroids: Effect of Bowel Interposition on Procedure Feasibility and a Unique Bowel Displacement Technique. PLoS One. 2016;11(5):e0155670. doi: 10.1371/journal.pone.0155670. PMID: 27186881.X-3

518. Gao Z, Li L, Meng Y. Correction: A Retrospective Analysis of the Impact of Myomectomy on Survival in Uterine Sarcoma. PLoS One. 2016;11(4):e0153996. doi: 10.1371/journal.pone.0153996. PMID: 27078148.X-1

519. Ksiezakowska-Lakoma K, Zyla M, Wilczynski J. Removal of uterine fibroids by mini-laparotomy technique in women who wish to preserve their uterus and fertility. Wideochir Inne Tech Maloinwazyjne. 2016 Jan;10(4):561-6. doi: 10.5114/wiitm.2015.56998. PMID: 26865893.INCLUDE X-3

520. Perkins RB, Handal-Orefice R, Hanchate AD, et al. Risk of Undetected Cancer at the Time of Laparoscopic Supracervical Hysterectomy and Laparoscopic Myomectomy: Implications for the Use of Power Morcellation. Womens Health Issues. 2016 Jan-Feb;26(1):21-6. doi: 10.1016/j.whi.2015.09.008. PMID: 26701205.INCLUDE X-3

521. Park H, Yoon SW, Sokolov A. Scaled signal intensity of uterine fibroids based on T2-weighted MR images: a potential objective method to determine the suitability for magnetic resonance-guided focused ultrasound surgery of uterine fibroids. Eur Radiol. 2015 Dec;25(12):3455-8. doi: 10.1007/s00330-015-3806-0. PMID: 25956935.X-3

522. Zayed M, Fouda UM, Zayed SM, et al. Hysteroscopic Myomectomy of Large Submucous Myomas in a 1-Step Procedure Using Multiple Slicing Sessions Technique. J Minim Invasive Gynecol. 2015 Nov-Dec;22(7):1196-202. doi: 10.1016/j.jmig.2015.06.008. PMID: 26093183.X-3

523. Algara AC, Rodriguez AG, Vazquez AC, et al. Laparoscopic Approach for Fibroid Removal at 18 Weeks of Pregnancy. Surg Technol Int. 2015 Nov;27:195-7. PMID: 26680396.X-4

524. Isern J, Pessarrodona A, Rodriguez J, et al. Using microbubble sonographic contrast agent to enhance the effect of high intensity focused ultrasound for the treatment of uterine fibroids. Ultrason Sonochem. 2015 Nov;27:688-93. doi: 10.1016/j.ultsonch.2015.05.027. PMID: 26113390.X-3

525. Brany D, Dvorska D, Nachajova M, et al. Malignant tumors of the uterine corpus: molecular background of their origin. Tumour Biol. 2015 Sep;36(9):6615-21. doi: 10.1007/s13277-015-3824-1. PMID: 26307392.X-1

526. Hamoda H, Pepas L, Tasker F, et al. Intermediate and long-term outcomes following uterine artery fibroid embolization. Eur J Obstet Gynecol Reprod Biol. 2015 Aug;191:33-8. doi: 10.1016/j.ejogrb.2015.05.016. PMID: 26070125.X-1

527. Sousa WB, Garcia JB, Nogueira Neto J, et al. Xenotransplantation of uterine leiomyoma in Wistar rats: a pilot study. Eur J Obstet Gynecol Reprod Biol. 2015 Jul;190:71-5. doi: 10.1016/j.ejogrb.2015.04.012. PMID: 25996518.X-2

528. Swenson CW, Lanham MS, Morgan DM, et al. Predicting postoperative day 1 hematocrit levels after uncomplicated hysterectomy. Int J Gynaecol Obstet. 2015 Jul;130(1):19-22. doi: 10.1016/j.ijgo.2015.01.014. PMID: 25863540.X-3

529. Parikh P, Maheshwari A, Rekhi B. Two uncommon cases of uterine leiomyosarcomas displaying heterologous osteosarcomatous de-differentiation. J Cancer Res Ther. 2015 Jul-Sep;11(3):654. doi: 10.4103/0973-1482.140984. PMID: 26458644.X-4

530. Zhang J, Fischer J, Warner L, et al. Noninvasive, in vivo determination of uterine fibroid thermal conductivity in MRI-guided high intensity focused ultrasound therapy. J Magn Reson Imaging. 2015 Jun;41(6):1654-61. doi: 10.1002/jmri.24724. PMID: 25160768.X-3

531. Matytsina-Quinlan L, Matytsina L. Abnormal excessive per vagina (PV) bleeding on Esmya-selective progesterone receptor modulator (SPRM) in a symptomatic patient with uterine fibroid. BMJ Case Rep. 2015;2015doi: 10.1136/bcr-2014-209015. PMID: 25976198.X-4

532. Quinn SD, Gedroyc WM. Thermal ablative treatment of uterine fibroids. Int J Hyperthermia. 2015 May;31(3):272-9. doi: 10.3109/02656736.2015.1010608. PMID: 25815582.X-1

533. Orsi F, Monfardini L, Bonomo G, et al. Ultrasound guided high intensity focused ultrasound (USgHIFU) ablation for uterine fibroids: Do we need the microbubbles? Int J Hyperthermia. 2015 May;31(3):233-9. doi: 10.3109/02656736.2015.1004134. PMID: 25758436.X-3

534. Zhang L, Zhang W, Orsi F, et al. Ultrasound-guided high intensity focused ultrasound for the treatment of gynaecological diseases: A review of safety and efficacy. Int J Hyperthermia. 2015 May;31(3):280-4. doi: 10.3109/02656736.2014.996790. PMID: 25609456.X-1

535. Dubuisson J, Ramyead L, Streuli I. The role of preventive uterine artery occlusion during laparoscopic myomectomy: a review of the literature. Arch Gynecol Obstet. 2015 Apr;291(4):737-43. doi: 10.1007/s00404-014-3546-4. PMID: 25391639.X-1

536. Odejinmi F, Agarwal N, Maclaran K, et al. Should we abandon all conservative treatments for uterine fibroids? The problem with leiomyosarcomas. Womens Health (Lond). 2015 Mar;11(2):151-9. doi: 10.2217/whe.14.71. PMID: 25776289.X-1

537. Ray A, Pant L, Magon N. Deciding the route for hysterectomy: Indian triage system. J Obstet Gynaecol India. 2015 Feb;65(1):39-44. doi: 10.1007/s13224-014-0578-4. PMID: 25737621.X-3

538. Blagovest B, Magunska N, Kovachev E, et al. [Laparoscopic Myomectomy with Uterine Artery Clipping Versus Conventional Laparoscopic Myomectomy]. Akush Ginekol (Sofiia). 2015;54(6):52-4. PMID: 26817264.X-1

539. Gincheva D, Gorchev G, Tomov S. [Opportunities of Hifu Technology for Treatment Fibroids Diseases Such as Non-Invasive and Alternative Method to Surgery]. Akush Ginekol (Sofiia). 2015;54(7):26-30. PMID: 27025105.X-1

540. Blagovest B, Magunska N, Kovachev E, et al. [Laparoscopic Myomectomy with Uterine Artery Clipping Versus Conventional Laparoscopic Myomectomy]. Akush Ginekol (Sofiia). 2015;54(7):8-10. PMID: 27025101.X-3

541. Fiaschetti V, Fornari M, Cama V, et al. MRI in the assessment of prolapsed pedunculated submucous leiomyomas: two case reports. Clin Exp Obstet Gynecol. 2015;42(6):827-32. PMID: 26753498.X-4

542. Aleksandrovych V, Bereza T, Sajewicz M, et al. Uterine fibroid: common features of widespread tumor (Review article). Folia Med Cracov. 2015;55(1):61-75. PMID: 26774633.X-1

543. Xie B, Zhang C, Xiong C, et al. High intensity focused ultrasound ablation for submucosal fibroids: A comparison between type I and type II. Int J Hyperthermia. 2015;31(6):593-9. doi: 10.3109/02656736.2015.1046406. PMID: 26044873.X-3

544. Pron G. Magnetic Resonance-Guided High-Intensity Focused Ultrasound (MRgHIFU) Treatment of Symptomatic Uterine Fibroids: An Evidence-Based Analysis. Ont Health Technol Assess Ser. 2015;15(4):1-86. PMID: 26357530.X-1

545. Nezhat FR, Sirota I. Perioperative outcomes of robotic assisted laparoscopic surgery versus conventional laparoscopy surgery for advanced-stage endometriosis. JSLS. 2014 Oct-Dec;18(4)doi: 10.4293/JSLS.2014.00094. PMID: 25489208.X-2

546. Hjorto S, Gronbeck L, Nielsen TF. Hydrothermal ablation complicated by acute peritonitis due to thermal injury to the intestines. Eur J Obstet Gynecol Reprod Biol. 2014 Sep;180:207-8. doi: 10.1016/j.ejogrb.2014.06.010. PMID: 25012395.X-2

547. Dartmouth K. A systematic review with meta-analysis: the common sonographic characteristics of adenomyosis. Ultrasound. 2014 Aug;22(3):148-57. doi: 10.1177/1742271x14528837. PMID: 27433212.X-1

548. Cohen SL, Vitonis AF, Einarsson JI. Updated hysterectomy surveillance and factors associated with minimally invasive hysterectomy. JSLS. 2014 Jul-Sep;18(3)doi: 10.4293/JSLS.2014.00096. PMID: 25392662.X-3

549. Eaton JL, Milad MP. Pregnancy outcomes after myomectomy with polytetrafluoroethylene placement. JSLS. 2014 Jul-Sep;18(3)doi: 10.4293/JSLS.2014.00013. PMID: 25392651.X-3

550. Galen DI, Pemueller RR, Leal JG, et al. Laparoscopic radiofrequency fibroid ablation: phase II and phase III results. JSLS. 2014 Apr-Jun;18(2):182-90. doi: 10.4293/108680813X13693422518353. PMID: 24960480.INCLUDE X-3

551. Skorstad M, Kent A, Lieng M. Uterine leiomyosarcoma - incidence, treatment, and the impact of morcellation. A nationwide cohort study. Acta obstetricia et gynecologica Scandinavica. 2016;95(9):984-990. PMID: 27223683. doi:10.1111/aogs.12930. EXCLUDE x-2

Table D-3. Reasons for exclusion: Key Question 4 (n = 979*)

Exclusion Code	Exclusion Reason	Count*
L1: X-1; L2: X-1	Not original research	272
L1: X-2	Not women with fibroids	345
L1: X-3; L2: X-4	Does not include at least patients treated for uterine fibroids	491
L1: X-4; L2: X-2	Does not report method for tissue removal	200
L1: X-5; L2: X-5	Does not report outcome(s) related to leiomyosarcoma subsequent to treatment for uterine fibroids	584
L2: X-3	Ineligible study design or article type	9
L2: X-10	Unavailable	1
L2: X-11	Non-English	1

*Total count exceeds number of records as records can be excluded for more than one reason

1. Beckmann MW, Juhasz-Boss I, Denschlag D, et al. Surgical Methods for the Treatment of Uterine Fibroids - Risk of Uterine Sarcoma and Problems of Morcellation: Position Paper of the DGGG. Geburtshilfe Frauenheilkd. 2015 Feb;75(2):148-64. doi: 10.1055/s-0035-1545684. PMID: 25797958.L1: X-1

2. English D, Menderes G, Azodi M. Controlled removal of a large uterus within a bowel bag and morcellation in the bowel bag from the vagina. Gynecol Oncol. 2015 Mar 19doi: 10.1016/j.ygyno.2015.03.014. PMID: 25797081.L1: X-3, X-5

3. Lewis EI, Srouji SS, Gargiulo AR. Robotic single-site myomectomy: initial report and technique. Fertil Steril. 2015 Mar 16doi: 10.1016/j.fertnstert.2015.02.021. PMID: 25792248.L1: X-4, X-5

4. Robert G, Cornu JN, Fourmarier M, et al. Multicenter prospective evaluation of the learning curve of the holmium laser enucleation of the prostate (HoLEP). BJU Int. 2015 Mar 17doi: 10.1111/bju.13124. PMID: 25781490.L1: X-2, X-3, X-5

5. Odejinmi F, Agarwal N, Maclaran K, et al. Should we abandon all conservative treatments for uterine fibroids? The problem with leiomyosarcomas. Womens Health (Lond Engl). 2015 Mar;11(2):151-9. doi: 10.2217/whe.14.71. PMID: 25776289.L1: X-1

6. Brolmann H, Tanos V, Grimbizis G, et al. Options on fibroid morcellation: a literature review. Gynecol Surg. 2015;12(1):3-15. doi: 10.1007/s10397-015-0878-4. PMID: 25774118.L1: X-1

7. Kujansuu S, Salari BW, Galloway M, et al. Contained morcellation using the GelPOINT advance access platforms and 3M Steri-Drape endobag. Fertil Steril. 2015 Mar 12doi: 10.1016/j.fertnstert.2015.02.017. PMID: 25772767.L1: X-1, X-5

8. Vilos GA, Allaire C, Laberge PY, et al. The management of uterine leiomyomas. J Obstet Gynaecol Can. 2015 Feb;37(2):157-81. PMID: 25767949.L1: X-1

9. Singh SS, Scott S, Bougie O, et al. Technical update on tissue morcellation during gynaecologic surgery: its uses, complications, and risks of unsuspected malignancy. J Obstet Gynaecol Can. 2015 Jan;37(1):68-81. PMID: 25764040.L1: X-1

10. Kim M, Piao S, Lee HE, et al. Efficacy and safety of holmium laser enucleation of the prostate for extremely large prostatic adenoma in patients with benign prostatic hyperplasia. Korean J Urol. 2015 Mar;56(3):218-26. doi: 10.4111/kju.2015.56.3.218. PMID: 25763126.L1: X-2, X-3, X-4, X-5

11. Holloran-Schwartz MB, Fierro M, Tritto A. Delayed presentation of a paracytic myoma fragment after laparoscopic supracervical hysterectomy requiring small bowel resection. A case report. J Reprod Med. 2015 Jan-Feb;60(1-2):75-7. PMID: 25745756.L1: X-5

12. Wallis L. FDA warns against power morcellation for hysterectomy and fibroids. Am J Nurs. 2014 Jul;114(7):16. doi: 10.1097/01.naj.0000451664.53878.83. PMID: 25742335.L1: X-1

13. Guo XM, Xu X, Desai VB. Alterations in surgical technique after FDA statement on power morcellation. Am J Obstet Gynecol. 2015 Feb 28doi: 10.1016/j.ajog.2015.02.027. PMID: 25735888.L1: X-2, X-3, X-4, X-5

14. Pluchino N, Wenger JM, Petignat P. Intracorporeal electromechanical tissue morcellation: a critical review and recommendations for clinical practice. Obstet Gynecol. 2015 Mar;125(3):739. doi: 10.1097/aog.0000000000000709. PMID: 25730241.L1: X-1

15. Ebner F, Friedl TW, Scholz C, et al. Is open surgery the solution to avoid morcellation of uterine sarcomas? A systematic literature review on the effect of tumor morcellation and surgical techniques. Arch Gynecol Obstet. 2015 Feb 26doi: 10.1007/s00404-015-3664-7. PMID: 25716668.L1: X-1

16. Srouji SS, Kaser DJ, Gargiulo AR. Techniques for contained morcellation in gynecologic surgery. Fertil Steril. 2015 Feb 21doi: 10.1016/j.fertnstert.2015.01.022. PMID: 25712576.L1: X-1

17. Leigh B. To morcellate or not to morcellate - is that the question? Bjog. 2015 Mar;122(4):461. doi: 10.1111/1471-0528.13044. PMID: 25702539.L1: X-1

18. Farina-Perez LA. To morcellate, morcellator, morcellation. Actas Urol Esp. 2015 Feb 9doi: 10.1016/j.acuro.2015.01.001. PMID: 25676526.L1: X-1

19. Chikazawa K, Netsu S, Konno R. Myoma morcellation through the navel. Taiwan J Obstet Gynecol. 2015 Feb;54(1):106. doi: 10.1016/j.tjog.2014.11.020. PMID: 25675936.L1: X-1

20. Nyilas A, Paszt A, Simonka Z, et al. Laparoscopic splenectomy is a safe method in cases of extremely large spleens. J Laparoendosc Adv Surg Tech A. 2015 Mar;25(3):212-6. doi: 10.1089/lap.2014.0615. PMID: 25654169.L1: X-3, X-5

21. Aitchison LP, Flint J, Nesbitt-Hawes E, et al. A Feasibility Study Determining Surgical Ergonomics in a Live Surgical Setting. J Minim Invasive Gynecol. 2015 Jan 28doi: 10.1016/j.jmig.2015.01.022. PMID: 25638044.L1: X-2, X-3, X-5

22. Parker W, Pritts E, Olive D. Risk of Morcellation of Uterine Leiomyosarcomas in Laparoscopic Supracervical Hysterectomy and Laparoscopic Myomectomy, a Retrospective Trial Including 4791 Women. J Minim Invasive Gynecol. 2015 Jan 23doi: 10.1016/j.jmig.2015.01.015. PMID: 25623370.L1: X-1

23. Ton R, Kilic GS, Phelps JY. A Medical-Legal Review of Power Morcellation in the Face of the Recent FDA Warning and Litigation. J Minim Invasive Gynecol. 2015 Jan 24doi: 10.1016/j.jmig.2015.01.017. PMID: 25623369.L1: X-1

24. Mathias JM. FDA, Joint Commission cite safety concerns with power morcellation. OR Manager. 2015 Jan;31(1):5. PMID: 25622398.L1: X-1

25. Yang R, Xu T, Fu Y, et al. Leiomyomatosis peritonealis disseminata associated with endometriosis: A case report and review of the literature. Oncol Lett. 2015 Feb;9(2):717-20. doi: 10.3892/ol.2014.2741. PMID: 25621042.L1: X-5

26. Mowers EL, Skinner B, McLean K, et al. Effects of Morcellation of Uterine Smooth Muscle Tumor of Uncertain Malignant Potential and Endometrial Stromal Sarcoma: Case Series and Recommendations for Clinical Practice. J Minim Invasive Gynecol. 2015 Jan 14doi: 10.1016/j.jmig.2015.01.007. PMID: 25596464.L1: INCLUDE L2: X-4, X-5

27. Hamidouche A, Vincienne M, Thubert T, et al. [Hysteroscopic morcellation versus bipolar resection for endometrial polyp removal]. Gynecol Obstet Fertil. 2015 Feb;43(2):104-8. doi: 10.1016/j.gyobfe.2014.12.012. PMID: 25595942.L1: X-3, X-5

28. De Cuypere M, Martinez A, Kridelka F, et al. Disseminated ovarian Growing Teratoma Syndrome: a case -report highlighting surgical safety issues. Facts Views Vis Obgyn. 2014;6(4):250-3. PMID: 25593702.L1: X-3, X-5

29. Liu FW, Galvan-Turner VB, Pfaendler KS, et al. A critical assessment of morcellation and its impact on gynecologic surgery and the limitations of the existing literature. Am J Obstet Gynecol. 2015 Jan 9doi: 10.1016/j.ajog.2015.01.012. PMID: 25582101.L1: X-1

30. Harmanli O. Contained power morcellation within an insufflated isolation bag. Obstet Gynecol. 2015 Jan;125(1):229. doi: 10.1097/aog.0000000000000614. PMID: 25560131.L1: X-1

31. Ramos A, Fader AN, Roche KL. Surgical cytoreduction for disseminated benign disease after open power uterine morcellation. Obstet Gynecol. 2015 Jan;125(1):99-102. doi: 10.1097/aog.0000000000000549. PMID: 25560110.L1: X-3

32. Bechev B, Magunska N, Ivanov S, et al. [Laparoscopic myomectomy using bidirectional barbed suture: report of the new technique in 82 cases]. Akush Ginekol (Sofiia). 2014;53(5):13-6. PMID: 25558665.L1: X-4, X-5

33. Bai DS, Chen P, Qian JJ, et al. Modified laparoscopic hepatectomy for hepatic hemangioma. Surg Endosc. 2015 Jan 1doi: 10.1007/s00464-014-4048-y. PMID: 25552235.L1: X-2, X-3, X-5

34. Holloran-Schwartz MB, Harrison K, Gimpelson R. Direct injection of vasopressin during hysteroscopic myomectomy: a case report. J Reprod Med. 2014 Nov-Dec;59(11-12):614-6. PMID: 25552139.L1: X-4, X-5

35. Motluk A. Caution issued against use of morcellators. Cmaj. 2015 Feb 3;187(2):99. doi: 10.1503/cmaj.109-4962. PMID: 25534604.L1: X-1

36. Shokeir T. Safe vaginal uterine morcellation following total laparoscopic hysterectomy. Am J Obstet Gynecol. 2014 Dec 18doi: 10.1016/j.ajog.2014.12.024. PMID: 25530593.L1: X-1

37. Anderson KM, Alsyouf M, Richards G, et al. Hybrid transureteral nephrectomy in a survival porcine model. Jsls. 2014 Oct;18(4)doi: 10.4293/jsls.2014.00144. PMID: 25489210.L1: X-2, X-3, X-5

38. Bogani G, Cliby WA, Aletti GD. Impact of morcellation on survival outcomes of patients with unexpected uterine leiomyosarcoma: A systematic review and meta-analysis. Gynecol Oncol. 2014 Nov 20doi: 10.1016/j.ygyno.2014.11.011. PMID: 25462199.L1: X-1

39. Wang CJ, Lee JM, Yu HT, et al. Comparison of morcellator and culdotomy for extraction of uterine fibroids laparoscopically. Eur J Obstet Gynecol Reprod Biol. 2014 Dec;183:183-7. doi: 10.1016/j.ejogrb.2014.10.035. PMID: 25461376.L1: X-5

40. Gunthert AR, Christmann C, Kostov P, et al. Safe vaginal uterine morcellation following total laparoscopic hysterectomy. Am J Obstet Gynecol. 2014 Nov 25doi: 10.1016/j.ajog.2014.11.020. PMID: 25460836.L1: X-5

41. Arkenbout EA, van den Haak L, Driessen SR, et al. Assessing basic "physiology" of the morcellation process and tissue spread: a time-action analysis. J Minim Invasive Gynecol. 2015 Feb;22(2):255-60. doi: 10.1016/j.jmig.2014.10.009. PMID: 25460321.L1: X-5

42. Cholkeri-Singh A, Miller CE. Power morcellation in a specimen bag. J Minim Invasive Gynecol. 2015 Feb;22(2):160. doi: 10.1016/j.jmig.2014.10.012. PMID: 25460317.L1: X-1, X-5

43. Garbin O, Schwartz L. [New in hysteroscopy: hysteroscopic morcellators]. Gynecol Obstet Fertil. 2014 Dec;42(12):872-6. doi: 10.1016/j.gyobfe.2014.10.002. PMID: 25453907.L1: X-5

44. Vargas MV, Cohen SL, Fuchs-Weizman N, et al. Open power morcellation versus contained power morcellation within an insufflated isolation bag: comparison of perioperative outcomes. J Minim Invasive Gynecol. 2015 Mar-Apr;22(3):433-8. doi: 10.1016/j.jmig.2014.11.010. PMID: 25452122.L1: INCLUDE L2: X-5

45. Rubino RJ, Lukes AS. Twelve-month outcomes for patients undergoing hysteroscopic morcellation of uterine polyps and myomas in an office or ambulatory surgical center. J Minim Invasive Gynecol. 2015 Feb;22(2):285-90. doi: 10.1016/j.jmig.2014.10.015. PMID: 25446547.L1: X-5

46. McCarthy M. US toughens warning on power morcellators. Bmj. 2014;349:g7225. doi: 10.1136/bmj.g7225. PMID: 25424182.L1: X-1

47. Kondrup JD, Anderson F, Sylvester B, et al. Laparoscopic Morcellation and Tissue Spillage Containment Using the LI Endofield Bag. Surg Technol Int. 2014 Nov;25:162-6. PMID: 25419952.L1: X-1

48. Arora KS, Spillman M, Milad M. Bits and pieces: the ethics of uterine morcellation. Obstet Gynecol. 2014 Dec;124(6):1199-201. doi: 10.1097/aog.0000000000000525. PMID: 25415172.L1: X-1

49. Ramesh B, Sharma P, Gunge D. Abdominal wall parasitic myoma following electromechanical morcellation. J Obstet Gynaecol India. 2014 Dec;64(Suppl 1):73-5. doi: 10.1007/s13224-012-0302-1. PMID: 25404818.L1: X-1, X-5

50. Chin H, Ong XH, Yam PK, et al. Extrauterine fibroids: a diagnostic challenge and a long-term battle. BMJ Case Rep. 2014;2014doi: 10.1136/bcr-2014-204928. PMID: 25395465.L1: INCLUDE L2: X-2, X-3, X-3a, X-5

51. Kato T, Sugimoto M, Matsuoka Y, et al. Case of vascular air embolism during holmium laser enucleation of the prostate. Int J Urol. 2015 Feb;22(2):227-9. doi: 10.1111/iju.12651. PMID: 25394391.L1: X-2, X-3, X-5

52. Smorgick N. Laparoscopic specimen retrieval bags. J Obstet Gynaecol India. 2014 Oct;64(5):370-2. doi: 10.1007/s13224-014-0598-0. PMID: 25368466.L1: X-1

53. Bhave Chittawar P, Franik S, Pouwer AW, et al. Minimally invasive surgical techniques versus open myomectomy for uterine fibroids. Cochrane Database Syst Rev. 2014;10:Cd004638. doi: 10.1002/14651858.CD004638.pub3. PMID: 25331441.L1: X-1

54. Brower V. FDA considers restricting or banning laparoscopic morcellation. J Natl Cancer Inst. 2014 Oct;106(10)doi: 10.1093/jnci/dju339. PMID: 25313228.L1: X-1

55. Teplica D, Bohorquez M, Podbielski FJ. Morcellized Omental Transfer for Severe HIV Facial Wasting. Plast Reconstr Surg Glob Open. 2013 Nov;1(8):e73. doi: 10.1097/gox.0000000000000006. PMID: 25289268.L1: X-2, X-3, X-5

56. Hamidouche A, Vincienne M, Thubert T, et al. [Operative hysteroscopy for myoma removal: Morcellation versus bipolar loop resection.]. J Gynecol Obstet Biol Reprod (Paris). 2014 Oct 3doi: 10.1016/j.jgyn.2014.09.006. PMID: 25287109.L1: X-5

57. Huang PS, Chang WC, Huang SC. Iatrogenic parasitic myoma: a case report and review of the literature. Taiwan J Obstet Gynecol. 2014 Sep;53(3):392-6. doi: 10.1016/j.tjog.2013.11.007. PMID: 25286798.L1: X-5

58. Graziano A, Lo Monte G, Hanni H, et al. Laparoscopic supracervical hysterectomy with transcervical morcellation: our experience. J Minim Invasive Gynecol. 2015 Feb;22(2):212-8. doi: 10.1016/j.jmig.2014.09.013. PMID: 25285774.L1: INCLUDE L2: X-5

59. Ehdaivand S, Simon RA, Sung CJ, et al. Incidental gynecologic neoplasms in morcellated uterine specimens: a case series with follow-up. Hum Pathol. 2014 Nov;45(11):2311-7. doi: 10.1016/j.humpath.2014.07.018. PMID: 25257577.L1: INCLUDE L2: X-5

60. Brown J, Taylor K, Ramirez PT, et al. Laparoscopic supracervical hysterectomy with morcellation: should it stay or should it go? J Minim Invasive Gynecol. 2015 Feb;22(2):185-92. doi: 10.1016/j.jmig.2014.09.005. PMID: 25242233.L1: INCLUDE L2: X-5

61. Garry R. Laparoscopic morcellation: an acceptable risk or an Achilles heel? Bjog. 2015 Mar;122(4):458-60. doi: 10.1111/1471-0528.13045. PMID: 25236787.L1: X-1

62. Brower V. FDA likely to further restrict or ban morcellation. Lancet Oncol. 2014 Aug;15(9):e369. PMID: 25225696.L1: X-1

63. Pereira N, Buchanan TR, Wishall KM, et al. Electric morcellation-related reoperations after laparoscopic myomectomy and nonmyomectomy procedures. J Minim Invasive Gynecol. 2015 Feb;22(2):163-76. doi: 10.1016/j.jmig.2014.09.006. PMID: 25218993.L1: X-1

64. Kho KA, Anderson TL, Nezhat CH. Intracorporeal electromechanical tissue morcellation: a critical review and recommendations for clinical practice. Obstet Gynecol. 2014 Oct;124(4):787-93. doi: 10.1097/aog.0000000000000448. PMID: 25198260.L1: X-1

65. Brown J. AAGL advancing minimally invasive gynecology worldwide: statement to the FDA on power morcellation. J Minim Invasive Gynecol. 2014 Nov-Dec;21(6):970-1. doi: 10.1016/j.jmig.2014.08.780. PMID: 25195157.L1: X-1

66. Pritts EA, Parker WH, Brown J, et al. Outcome of occult uterine leiomyosarcoma after surgery for presumed uterine fibroids: a systematic review. J Minim Invasive Gynecol. 2015 Jan;22(1):26-33. doi: 10.1016/j.jmig.2014.08.781. PMID: 25193444.L1: X-1

67. Cohen SL, Einarsson JI, Wang KC, et al. Contained power morcellation within an insufflated isolation bag. Obstet Gynecol. 2014 Sep;124(3):491-7. doi: 10.1097/aog.0000000000000421. PMID: 25162248.L1: INCLUDE L2: X-5

68. Rardin CR. Mitigating risks of specimen extraction: is in-bag power morcellation an answer? Obstet Gynecol. 2014 Sep;124(3):489-90. doi: 10.1097/aog.0000000000000434. PMID: 25162247.L1: X-1

69. Lee JR, Lee JH, Kim JY, et al. Single port laparoscopic myomectomy with intracorporeal suture-tying and transumbilical morcellation. Eur J Obstet Gynecol Reprod Biol. 2014 Oct;181:200-4. doi: 10.1016/j.ejogrb.2014.07.051. PMID: 25150961.L1: X-5

70. Haber K, Hawkins E, Levie M, et al. Hysteroscopic morcellation: review of the manufacturer and user facility device experience (MAUDE) database. J Minim Invasive Gynecol. 2015 Jan;22(1):110-4. doi: 10.1016/j.jmig.2014.08.008. PMID: 25128851.L1: X-1

71. Espinoza C, Ellis HB, Wilson P. Arthroscopic delivery of cancellous tibial autograft for unstable osteochondral lesions in the adolescent knee. Arthrosc Tech. 2014 Jun;3(3):e339-42. doi: 10.1016/j.eats.2014.01.016. PMID: 25126499.L1: X-2, X-3, X-5

72. Kongnyuy EJ, Wiysonge CS. Interventions to reduce haemorrhage during myomectomy for fibroids. Cochrane Database Syst Rev. 2014;8:Cd005355. doi: 10.1002/14651858.CD005355.pub5. PMID: 25125317.L1: X-1

73. Asimakopoulos AD, Gaston R, Miano R, et al. Laparoscopic pretransplant nephrectomy with morcellation in autosomic-dominant polycystic kidney disease patients with end-stage renal disease. Surg Endosc. 2015 Jan;29(1):236-44. doi: 10.1007/s00464-014-3663-y. PMID: 25125090.L1: X-2, X-3, X-5

74. Morice P. [Impact of tumor morcellation during the surgical extraction of solid tumors]. Bull Cancer. 2014 Jun;101(6):526-7. PMID: 25121163.L1: X-1

75. Buckley VA, Nesbitt-Hawes EM, Atkinson P, et al. Laparoscopic myomectomy: clinical outcomes and comparative evidence. J Minim Invasive Gynecol. 2015 Jan;22(1):11-25. doi: 10.1016/j.jmig.2014.08.007. PMID: 25117840.L1: X-1

76. Hampton T. Use of morcellation to remove fibroids scrutinized at FDA hearings. Jama. 2014 Aug 13;312(6):588. doi: 10.1001/jama.2014.10041. PMID: 25117116.L1: X-1

77. Stine JE, Clarke-Pearson DL, Gehrig PA. Uterine morcellation at the time of hysterectomy: techniques, risks, and recommendations. Obstet Gynecol Surv. 2014 Jul;69(7):415-25. doi: 10.1097/ogx.0000000000000088. PMID: 25112590.L1: X-1

78. Yoshida A, Nii S, Matsushita H, et al. Parasitic myoma in women after laparoscopic myomectomy: A late sequela of morcellation? J Obstet Gynaecol. 2014 Aug 11:1-2. doi: 10.3109/01443615.2014.948404. PMID: 25111124.L1: X-5

79. Bogani G, Serati M, Uccella S, et al. In-bag morcellation for presumed myoma retrieval at laparoscopy. Cancer. 2014 Dec 15;120(24):4004-5. doi: 10.1002/cncr.28959. PMID: 25102972.L1: X-1

80. George S, Muto MG. Reply to in-bag morcellation for presumed myoma retrieval at laparoscopy. Cancer. 2014 Dec 15;120(24):4005. doi: 10.1002/cncr.28957. PMID: 25102828.L1: X-1

81. Bechev B, Nacheva A, Magunska N, et al. ["Second look" after laparoscopic myomectomy--is that a prevention of postoperative adhesions]. Akush Ginekol (Sofiia). 2014;53(2):18-21. PMID: 25098104.L1: X-4, X-5

82. Ceccaroni M, Roviglione G, Pesci A, et al. Total laparoscopic hysterectomy of very enlarged uterus (3030 g): case report and review of the literature. Wideochir Inne Tech Malo Inwazyjne. 2014 Jun;9(2):302-7. doi: 10.5114/wiitm.2014.43026. PMID: 25097706.L1: X-1, X-5

83. Senapati S, Tu FF, Magrina JF. Power morcellators: a review of current practice and assessment of risk. Am J Obstet Gynecol. 2015 Jan;212(1):18-23. doi: 10.1016/j.ajog.2014.07.046. PMID: 25072737.L1: X-1

84. Kho KA, Nezhat CH. Electric uterine morcellation--reply. Jama. 2014 Jul 2;312(1):96-7. doi: 10.1001/jama.2014.6172. PMID: 25058231.L1: X-1

85. Melamed A. Electric uterine morcellation. Jama. 2014 Jul 2;312(1):96. doi: 10.1001/jama.2014.6169. PMID: 25058230.L1: X-1

86. Wright JD, Tergas AI, Burke WM, et al. Uterine pathology in women undergoing minimally invasive hysterectomy using morcellation. Jama. 2014 Sep 24;312(12):1253-5. doi: 10.1001/jama.2014.9005. PMID: 25051495.L1: INCLUDE L2: X-5

87. Kanade TT, McKenna JB, Choi S, et al. Sydney contained in bag morcellation for laparoscopic myomectomy. J Minim Invasive Gynecol. 2014 Nov-Dec;21(6):981. doi: 10.1016/j.jmig.2014.07.005. PMID: 25048568.L1: X-1, X-5

88. McKenna JB, Kanade T, Choi S, et al. The Sydney Contained In Bag Morcellation technique. J Minim Invasive Gynecol. 2014 Nov-Dec;21(6):984-5. doi: 10.1016/j.jmig.2014.07.007. PMID: 25048565.L1: X-1, X-5

89. Chung JS, Kang PM, Seo WI, et al. Thulium laser (RevoLix) vaporesection versus vapoenucleation with morcellator (Piranha) for the treatment of benign prostatic obstruction: a propensity-matched multicenter analysis. Int J Urol. 2014 Nov;21(11):1156-61. doi: 10.1111/iju.12547. PMID: 25040293.L1: X-2, X-3, X-5

90. Garcia-Segui A, Verges A, Galan-Llopis JA, et al. "Knotless" Laparoscopic Extraperitoneal Adenomectomy. Actas Urol Esp. 2015 Mar;39(2):128-36. doi: 10.1016/j.acuro.2014.05.011. PMID: 25034540.L1: X-2, X-3, X-5

91. Amant F, Floquet A, Friedlander M, et al. Gynecologic Cancer InterGroup (GCIG) consensus review for endometrial stromal sarcoma. Int J Gynecol Cancer. 2014 Nov;24(9 Suppl 3):S67-72. doi: 10.1097/igc.0000000000000205. PMID: 25033257.L1: X-1

92. Frishman GN. Should we bag tissue morcellation? Looking backward and forward. J Minim Invasive Gynecol. 2014 Sep-Oct;21(5):713-4. doi: 10.1016/j.jmig.2014.06.012. PMID: 25016071.L1: X-1

93. Estrade JP, Crochet P, Aumiphin J, et al. Supracervical hysterectomy by laparoendoscopic single site surgery. Arch Gynecol Obstet. 2014 Dec;290(6):1169-72. doi: 10.1007/s00404-014-3360-z. PMID: 25012604.L1: X-5

94. Tulandi T, Ferenczy A. Biopsy of uterine leiomyomata and frozen sections before laparoscopic morcellation. J Minim Invasive Gynecol. 2014 Sep-Oct;21(5):963-6. doi: 10.1016/j.jmig.2014.06.010. PMID: 24993657.L1: X-1, X-5

95. Litta P, Leggieri C, Conte L, et al. Monopolar versus bipolar device: safety, feasibility, limits and perioperative complications in performing hysteroscopic myomectomy. Clin Exp Obstet Gynecol. 2014;41(3):335-8. PMID: 24992788.L1: X-4, X-5

96. Pakrashi T. New hysteroscopic techniques for submucosal uterine fibroids. Curr Opin Obstet Gynecol. 2014 Aug;26(4):308-13. doi: 10.1097/gco.0000000000000076. PMID: 24950124.L1: X-1, X-4, X-5

97. Conner SN, Frey HA, Tuuli MG. In reply. Obstet Gynecol. 2014 Jul;124(1):163. doi: 10.1097/aog.0000000000000354. PMID: 24945448.L1: X-1

98. Danhof N, Kamphuis E, Mol B. Loop electrosurgical excision procedure and risk of preterm birth. Obstet Gynecol. 2014 Jul;124(1):163. doi: 10.1097/aog.0000000000000353. PMID: 24945447.L1: X-1

99. Cohen SL, Greenberg JA, Wang KC, et al. Risk of leakage and tissue dissemination with various contained tissue extraction (CTE) techniques: an in vitro pilot study. J Minim Invasive Gynecol. 2014 Sep-Oct;21(5):935-9. doi: 10.1016/j.jmig.2014.06.004. PMID: 24928740.L1: X-2, X-3, X-5

100. George S, Barysauskas C, Serrano C, et al. Retrospective cohort study evaluating the impact of intraperitoneal morcellation on outcomes of localized uterine leiomyosarcoma. Cancer. 2014 Oct 15;120(20):3154-8. doi: 10.1002/cncr.28844. PMID: 24923260.L1: INCLUDE L2: X-3, X-3e, X-4, X-5

101. Tobi KU, Imarengiaye CO, Amadasun FE. The effects of dexamethasone and metoclopramide on early and late postoperative nausea and vomiting in women undergoing myomectomy under spinal anaesthesia. Niger J Clin Pract. 2014 Jul-Aug;17(4):449-55. doi: 10.4103/1119-3077.134036. PMID: 24909468.L1: X-4, X-5

102. Sakamoto Y, Nakajima H, Tamada I. Outcome analysis of morcellation craniotomy with distraction osteogenesis for scaphocephaly. Pediatr Neurosurg. 2013;49(4):248-53. doi: 10.1159/000362690. PMID: 24903312.L1: X-2, X-3, X-5

103. Harpham M, Abbott J. Use of a hysteroscopic morcellator to resect miscarriage in a woman with recurrent Asherman's syndrome. J Minim Invasive Gynecol. 2014 Nov-Dec;21(6):1118-20. doi: 10.1016/j.jmig.2014.05.006. PMID: 24865632.L1: X-3, X-5

104. . AAGL practice report: Morcellation during uterine tissue extraction. J Minim Invasive Gynecol. 2014 Jul-Aug;21(4):517-30. doi: 10.1016/j.jmig.2014.05.010. PMID: 24865630.L1: X-1

105. Lund CM, Ragle CA, Lutter JD, et al. Use of a motorized morcellator for elective bilateral laparoscopic ovariectomy in standing equids: 30 cases (2007-2013). J Am Vet Med Assoc. 2014 May 15;244(10):1191-7. doi: 10.2460/javma.244.10.1191. PMID: 24786168.L1: X-2, X-3, X-5

106. Conner SN, Macones GA. In reply. Obstet Gynecol. 2014 Apr;123(4):886. doi: 10.1097/aog.0000000000000193. PMID: 24785622.L1: X-1

107. Mungo C, Groen RS. Interval from loop electrosurgical excision procedure to pregnancy and pregnancy outcomes. Obstet Gynecol. 2014 Apr;123(4):886. doi: 10.1097/aog.0000000000000192. PMID: 24785621.L1: X-1

108. Conner SN, Frey HA, Cahill AG, et al. Loop electrosurgical excision procedure and risk of preterm birth: a systematic review and meta-analysis. Obstet Gynecol. 2014 Apr;123(4):752-61. doi: 10.1097/aog.0000000000000174. PMID: 24785601.L1: X-1, X-3

109. Smith PP, Middleton LJ, Connor M, et al. Hysteroscopic morcellation compared with electrical resection of endometrial polyps: a randomized controlled trial. Obstet Gynecol. 2014 Apr;123(4):745-51. doi: 10.1097/aog.0000000000000187. PMID: 24785600.L1: X-3, X-5

110. Bogani G, Uccella S, Cromi A, et al. Electric motorized morcellator versus transvaginal extraction for myoma retrieval after laparoscopic myomectomy: a propensity-matched analysis. J Minim Invasive Gynecol. 2014 Sep-Oct;21(5):928-34. doi: 10.1016/j.jmig.2014.04.012. PMID: 24780382.L1: X-5

111. Song MJ, Lee CW, Yoon JH, et al. Transection of the obturator nerve by an electrosurgical instrument and its immediate repair during laparoscopic pelvic lymphadenectomy: a case report. Eur J Gynaecol Oncol. 2014;35(2):167-9. PMID: 24772921.L1: X-3, X-5

112. Einarsson JI, Cohen SL, Fuchs N, et al. In-bag morcellation. J Minim Invasive Gynecol. 2014 Sep-Oct;21(5):951-3. doi: 10.1016/j.jmig.2014.04.010. PMID: 24769447.L1: X-5

113. McCarthy M. US agency warns against morcellation in hysterectomies and myomectomies. Bmj. 2014;348:g2872. doi: 10.1136/bmj.g2872. PMID: 24755656.L1: X-1

114. Bisceglia M, Galliani CA, Pizzolitto S, et al. Selected case from the Arkadi M. Rywlin International Pathology Slide Series: Leiomyomatosis peritonealis disseminata: report of 3 cases with extensive review of the literature. Adv Anat Pathol. 2014 May;21(3):201-15. doi: 10.1097/pap.0000000000000024. PMID: 24713991.L1: X-1, X-5

115. Sklavos MM, Spracklen CN, Saftlas AF, et al. Does loop electrosurgical excision procedure of the uterine cervix affect anti-Mullerian hormone levels? Biomed Res Int. 2014;2014:875438. doi: 10.1155/2014/875438. PMID: 24707500.L1: X-3, X-4, X-5

116. Kamath MS, Kalampokas EE, Kalampokas TE. Use of GnRH analogues pre-operatively for hysteroscopic resection of submucous fibroids: a systematic review and meta-analysis. Eur J Obstet Gynecol Reprod Biol. 2014 Jun;177:11-8. doi: 10.1016/j.ejogrb.2014.03.009. PMID: 24702901.L1: X-1

117. Goff BA. SGO not soft on morcellation: risks and benefits must be weighed. Lancet Oncol. 2014 Apr;15(4):e148. doi: 10.1016/s1470-2045(14)70075-0. PMID: 24694631.L1: X-1

118. Knight J, Falcone T. Tissue extraction by morcellation: a clinical dilemma. J Minim Invasive Gynecol. 2014 May-Jun;21(3):319-20. doi: 10.1016/j.jmig.2014.03.005. PMID: 24646445.L1: X-1

119. Zhang C, Havrilesky LJ, Broadwater G, et al. Relationship between minimally invasive hysterectomy, pelvic cytology, and lymph vascular space invasion: a single institution study of 458 patients. Gynecol Oncol. 2014 May;133(2):211-5. doi: 10.1016/j.ygyno.2014.02.025. PMID: 24582867.L1: X-4, X-5

120. Song J, Kim E, Mobley J, et al. Port site metastasis after surgery for renal cell carcinoma: harbinger of future metastasis. J Urol. 2014 Aug;192(2):364-8. doi: 10.1016/j.juro.2014.02.089. PMID: 24582771.L1: X-1, X-3

121. Bekhit M, Jackson T, Advincula AP. Simulation study comparing the effectiveness of the Gynecare Morcellex(R), the MOREsolution, and the Rotocut G1 tissue Morcellators. Surg Technol Int. 2014 Mar;24:237-42. PMID: 24574011.L1: X-1

122. Montella F, Riboni F, Cosma S, et al. A safe method of vaginal longitudinal morcellation of bulky uterus with endometrial cancer in a bag at laparoscopy. Surg Endosc. 2014 Jun;28(6):1949-53. doi: 10.1007/s00464-014-3422-0. PMID: 24566741.L1: X-3, X-5

123. Hill AJ, Carroll AW, Matthews CA. Unanticipated uterine pathologic finding after morcellation during robotic-assisted supracervical hysterectomy and cervicosacropexy for uterine prolapse. Female Pelvic Med Reconstr Surg. 2014 Mar-Apr;20(2):113-5. doi: 10.1097/SPV.0b013e31829ff5b8. PMID: 24566217.L1: X-3, X-5

124. Papoutsis D, Georgantzis D, Dacco MD, et al. A rare case of Asherman's syndrome after open myomectomy: sonographic investigations and possible underlying mechanisms. Gynecol Obstet Invest. 2014;77(3):194-200. doi: 10.1159/000357489. PMID: 24557451.L1: X-1, X-5

125. Netsch C, Engbert A, Bach T, et al. Long-term outcome following Thulium VapoEnucleation of the prostate. World J Urol. 2014 Dec;32(6):1551-8. doi: 10.1007/s00345-014-1260-2. PMID: 24531878.L1: X-2, X-3

126. Weibel HS, Jarcevic R, Gagnon R, et al. Perspectives of obstetricians on labour and delivery after abdominal or laparoscopic myomectomy. J Obstet Gynaecol Can. 2014 Feb;36(2):128-32. PMID: 24518911.L1: X-2

127. Bernardi TS, Radosa MP, Weisheit A, et al. Laparoscopic myomectomy: a 6-year follow-up single-center cohort analysis of fertility and obstetric outcome measures. Arch Gynecol Obstet. 2014 Jul;290(1):87-91. doi: 10.1007/s00404-014-3155-2. PMID: 24504422.L1: X-5

128. Kho KA, Nezhat CH. Evaluating the risks of electric uterine morcellation. Jama. 2014 Mar 5;311(9):905-6. doi: 10.1001/jama.2014.1093. PMID: 24504415.L1: X-1

129. Pavlakis K, Vrekoussis T, Pistofidis G, et al. Methylene blue: how to visualize the endometrium in uterine morcellation material. Int J Gynecol Pathol. 2014 Mar;33(2):135-9. doi: 10.1097/PGP.0b013e318289437c. PMID: 24487467.L1: X-5

130. Cabezali Barbancho D, Guerrero Ramos F, Lopez Vazquez F, et al. Laparoscopic approach for Wilms tumor. Surg Laparosc Endosc Percutan Tech. 2014 Feb;24(1):22-5. doi: 10.1097/SLE.0b013e31829cebf1. PMID: 24487153.L1: X-2, X-3

131. Kim SH, Yoo C, Choo M, et al. Factors affecting de novo urinary retention after Holmium laser enucleation of the prostate. PLoS One. 2014;9(1):e84938. doi: 10.1371/journal.pone.0084938. PMID: 24465454.L1: X-2, X-3

132. Heller DS, Cracchiolo B. Peritoneal nodules after laparoscopic surgery with uterine morcellation: review of a rare complication. J Minim Invasive Gynecol. 2014 May-Jun;21(3):384-8. doi: 10.1016/j.jmig.2014.01.003. PMID: 24462597.L1: X-1

133. Driessen SR, Arkenbout EA, Thurkow AL, et al. Electromechanical morcellators in minimally invasive gynecologic surgery: an update. J Minim Invasive Gynecol. 2014 May-Jun;21(3):377-83. doi: 10.1016/j.jmig.2013.12.121. PMID: 24462590.L1: X-1

134. Currie A, Bradley E, McEwen M, et al. Laparoscopic approach to fibroid torsion presenting as an acute abdomen in pregnancy. Jsls. 2013 Oct-Dec;17(4):665-7. doi: 10.4293/108680813x13794522666400. PMID: 24398215.L1: X-1, X-5

135. Choi CH, Kim TH, Kim SH, et al. Surgical outcomes of a new approach to laparoscopic myomectomy: single-port and modified suture technique. J Minim Invasive Gynecol. 2014 Jul-Aug;21(4):580-5. doi: 10.1016/j.jmig.2013.12.096. PMID: 24384072.L1: X-5

136. Verberg MF, Boomsma CM, Pijnenborg JM. [A parasitic myoma: unexpected finding after laparoscopic hysterectomy]. Ned Tijdschr Geneeskd. 2013;157(52):A6683. PMID: 24382038.L1: X-5

137. Poojari VG, Bhat VV, Bhat R. Total laparoscopic hysterectomy with prior uterine artery ligation at its origin. Int J Reprod Med. 2014;2014:420926. doi: 10.1155/2014/420926. PMID: 25763400.L1: X-5

138. Turner T, Secord AA, Lowery WJ, et al. Metastatic adenocarcinoma after laparoscopic supracervical hysterectomy with morcellation: A case report. Gynecol Oncol Case Rep. 2013;5:19-21. doi: 10.1016/j.gynor.2013.03.002. PMID: 24371686.L1: X-3

139. Milad MP, Milad EA. Laparoscopic morcellator-related complications. J Minim Invasive Gynecol. 2014 May-Jun;21(3):486-91. doi: 10.1016/j.jmig.2013.12.003. PMID: 24333632.L1: X-1

140. Lindsay R, Burton K, Shanbhag S, et al. Fertility conserving management of early cervical cancer: our experience of LLETZ and pelvic lymph node dissection. Int J Gynecol Cancer. 2014 Jan;24(1):118-23. doi: 10.1097/igc.0000000000000023. PMID: 24300465.L1: X-3, X-5

141. Ramalingam M, King J, Jaacks L. Transvaginal specimen extraction after combined laparoscopic splenectomy and hysterectomy: Introduction to NOSE (Natural Orifice Specimen Extraction) in a community hospital. Int J Surg Case Rep. 2013;4(12):1138-41. doi: 10.1016/j.ijscr.2013.07.039. PMID: 24270286.L1: X-3, X-4, X-5

142. Conner SN, Cahill AG, Tuuli MG, et al. Interval from loop electrosurgical excision procedure to pregnancy and pregnancy outcomes. Obstet Gynecol. 2013 Dec;122(6):1154-9. doi: 10.1097/01.aog.0000435454.31850.79. PMID: 24201682.L1: X-3, X-4, X-5

143. Koyama S, Kobayashi M, Tanaka Y, et al. Laparoscopic repair of a post-myomectomy spontaneous uterine perforation accompanied by a bizarre tumor resembling polypoid endometriosis. J Minim Invasive Gynecol. 2013 Nov-Dec;20(6):912-6. doi: 10.1016/j.jmig.2013.05.018. PMID: 24183281.L1: X-3, X-4, X-5

144. Hamerlynck TW, Blikkendaal MD, Schoot BC, et al. An alternative approach for removal of placental remnants: hysteroscopic morcellation. J Minim Invasive Gynecol. 2013 Nov-Dec;20(6):796-802. doi: 10.1016/j.jmig.2013.04.024. PMID: 24183271.L1: X-3, X-5

145. Wang HY, Quan S, Zhang RL, et al. Comparison of serum anti-Mullerian hormone levels following hysterectomy and myomectomy for benign gynaecological conditions. Eur J Obstet Gynecol Reprod Biol. 2013 Dec;171(2):368-71. doi: 10.1016/j.ejogrb.2013.09.043. PMID: 24172648.L1: X-3, X-4, X-5

146. Magan A, Ripamonti U. Biological aspects of periodontal tissue regeneration: cementogenesis and the induction of Sharpey's fibres. Sadj. 2013 Aug;68(7):304-6, 8-12, 14 passim. PMID: 24133950.L1: X-1, X-2, X-3

147. Pundir J, Walawalkar R, Seshadri S, et al. Perioperative morbidity associated with abdominal myomectomy compared with total abdominal hysterectomy for uterine fibroids. J Obstet Gynaecol. 2013 Oct;33(7):655-62. doi: 10.3109/01443615.2013.816661. PMID: 24127947.L1: X-1

148. Fukuda M, Tanaka T, Kamada M, et al. Comparison of the perinatal outcomes after laparoscopic myomectomy versus abdominal myomectomy. Gynecol Obstet Invest. 2013;76(4):203-8. doi: 10.1159/000355098. PMID: 24107786.L1: X-1, X-4, X-5

149. Wortman M. Sonographically guided hysteroscopic myomectomy (SGHM): minimizing the risks and maximizing efficiency. Surg Technol Int. 2013 Sep;23:181-9. PMID: 24081849.L1: X-1, X-3, X-5

150. Tan YL, Lo TS, Khanuengkitkong S, et al. Lower urinary tract dysfunction resulting from a 10-year retained intravesical absorbable suture from a uterine myomectomy. Taiwan J Obstet Gynecol. 2013 Sep;52(3):435-6. doi: 10.1016/j.tjog.2013.01.027. PMID: 24075389.L1: X-4, X-5

151. Kim YK, Park SJ, Lee SY, et al. Laparoscopic nephrectomy in dogs: an initial experience of 16 experimental procedures. Vet J. 2013 Nov;198(2):513-7. doi: 10.1016/j.tvjl.2013.08.021. PMID: 24053989.L1: X-2, X-3

152. Tinelli A, Mettler L, Malvasi A, et al. Impact of surgical approach on blood loss during intracapsular myomectomy. Minim Invasive Ther Allied Technol. 2014 Mar;23(2):87-95. doi: 10.3109/13645706.2013.839951. PMID: 24044380.L1: X-4, X-5

153. Kim M, Lee HE, Oh SJ. Technical aspects of holmium laser enucleation of the prostate for benign prostatic hyperplasia. Korean J Urol. 2013 Sep;54(9):570-9. doi: 10.4111/kju.2013.54.9.570. PMID: 24044089.L1: X-1, X-2, X-3

154. Cingel V, Zabojnikova L, Kurucova P, et al. First experience with single incision laparoscopic surgery in Slovakia: concomitant cholecystectomy and splenectomy in an 11-year-old girl with hereditary spherocytosis. Biomed Pap Med Fac Univ Palacky Olomouc Czech Repub. 2014 Sep;158(3):479-85. doi: 10.5507/bp.2013.058. PMID: 24026144.L1: X-2, X-3, X-5

155. Ardovino M, Ardovino I, Castaldi MA, et al. Minilaparoscopic myomectomy: a mini-invasive technical variant. J Laparoendosc Adv Surg Tech A. 2013 Oct;23(10):871-5. doi: 10.1089/lap.2013.0037. PMID: 23992206.L1: X-5

156. Rabischong B, Beguinot M, Compan C, et al. [Long-term complication of laparoscopic uterine morcellation: iatrogenic parasitic myomas]. J Gynecol Obstet Biol Reprod (Paris). 2013 Oct;42(6):577-84. doi: 10.1016/j.jgyn.2013.07.006. PMID: 23973119.L1: X-5

157. Litta P, Pluchino N, Freschi L, et al. Evaluation of adhesions after laparoscopic myomectomy using the Harmonic Ace and the auto-crosslinked hyaluronan gel vs Ringer's lactate solution. Clin Exp Obstet Gynecol. 2013;40(2):210-4. PMID: 23971239.L1: X-4, X-5

158. Shinojima T, Yoshimine S. Difficulty in the intravesical morcellation procedure for leiomyoma of the prostate enucleated by HoLEP. BMJ Case Rep. 2013;2013doi: 10.1136/bcr-2013-200200. PMID: 23966460.L1: X-2, X-3

159. Buda A, Marco C, Dolci C, et al. Sentinel node mapping in high risk endometrial cancer after laparoscopic supracervical hysterectomy with morcellation. Int J Surg Case Rep. 2013;4(10):809-12. doi: 10.1016/j.ijscr.2013.06.010. PMID: 23959405.L1: X-3

160. Ibinaiye PO, Onwuhafua P, Usman B. Utero-peritoneal fistula, a rare complication of laparoscopic myomectomy scar dehiscence: a case Report. Niger Postgrad Med J. 2013 Jun;20(2):165-6. PMID: 23959361.L1: X-4, X-5

161. Scribner DR, Jr., Lara-Torre E, Weiss PM. Single-site laparoscopic management of a large adnexal mass. Jsls. 2013 Apr-Jun;17(2):350-3. doi: 10.4293/108680812x13517013318193. PMID: 23925036.L1: X-3, X-5

162. Vanichtantikul A, Charoenkwan K. Lidocaine spray compared with submucosal injection for reducing pain during loop electrosurgical excision procedure: a randomized controlled trial. Obstet Gynecol. 2013 Sep;122(3):553-7. doi: 10.1097/AOG.0b013e31829d888e. PMID: 23921860.L1: X-3, X-4, X-5

163. Mathiesen E, Hohenwalter M, Basir Z, et al. Placenta increta after hysteroscopic myomectomy. Obstet Gynecol. 2013 Aug;122(2 Pt 2):478-81. doi: 10.1097/AOG.0b013e31828aef0a. PMID: 23884266.L1: X-3, X-4, X-5

164. Xu A, Zou Y, Li B, et al. A randomized trial comparing diode laser enucleation of the prostate with plasmakinetic enucleation and resection of the prostate for the treatment of benign prostatic hyperplasia. J Endourol. 2013 Oct;27(10):1254-60. doi: 10.1089/end.2013.0107. PMID: 23879477.L1: X-2, X-3

165. Frederick S, Frederick J, Fletcher H, et al. A trial comparing the use of rectal misoprostol plus perivascular vasopressin with perivascular vasopressin alone to decrease myometrial bleeding at the time of abdominal myomectomy. Fertil Steril. 2013 Oct;100(4):1044-9. doi: 10.1016/j.fertnstert.2013.06.022. PMID: 23876539.L1: X-4, X-5

166. Hasegawa A, Koga K, Asada K, et al. Laparoscopic ovarian-sparing surgery for a young woman with an exophytic ovarian fibroma. J Obstet Gynaecol Res. 2013 Dec;39(12):1610-3. doi: 10.1111/jog.12107. PMID: 23875949.L1: X-3, X-5

167. Rosenblatt PL, Adams SR, Shapiro A. Microlaparoscopy in urogynecology: LSH and sacrocervicopexy. J Minim Invasive Gynecol. 2013 Jul-Aug;20(4):411. doi: 10.1016/j.jmig.2013.02.019. PMID: 23870237.L1: X-3, X-5

168. Lindekaer AL, Halvor Springborg H, Istre O. Deep neuromuscular blockade leads to a larger intraabdominal volume during laparoscopy. J Vis Exp. 2013(76)doi: 10.3791/50045. PMID: 23851450.L1: X-4, X-5

169. Jin G, LanLan Z, Li C, et al. Pregnancy outcome following loop electrosurgical excision procedure (LEEP) a systematic review and meta-analysis. Arch Gynecol Obstet. 2014 Jan;289(1):85-99. doi: 10.1007/s00404-013-2955-0. PMID: 23843155.L1: X-1, X-3

170. Jiang G, Qian J, Yao J, et al. A New Technique for Laparoscopic Splenectomy and Azygoportal Disconnection. Surg Innov. 2013 Jun 26;21(3):256-62. doi: 10.1177/1553350613492587. PMID: 23804998.L1: X-2, X-3, X-5

171. Kahokehr AA, Gilling PJ. Which laser works best for benign prostatic hyperplasia? Curr Urol Rep. 2013 Dec;14(6):614-9. doi: 10.1007/s11934-013-0351-8. PMID: 23780301.L1: X-1, X-2, X-3, X-4

172. Long S, Leeman L. Treatment options for high-grade squamous intraepithelial lesions. Obstet Gynecol Clin North Am. 2013 Jun;40(2):291-316. doi: 10.1016/j.ogc.2013.03.004. PMID: 23732033.L1: X-1

173. Tam T, Harkins G, Caldwell T, et al. Endometrial dye instillation: a novel approach to histopathologic evaluation of morcellated hysterectomy specimens. J Minim Invasive Gynecol. 2013 Sep-Oct;20(5):667-71. doi: 10.1016/j.jmig.2013.04.009. PMID: 23714746.L1: X-5

174. Seong Tan PC, Nik Mohamad NA, Gan SH. Factors that influence pain intensity and fentanyl requirements after a gynecologic laparotomy. Pain Manag Nurs. 2013 Jun;14(2):102-9. doi: 10.1016/j.pmn.2010.12.004. PMID: 23688364.L1: X-4, X-5

175. Olonisakin RP, Amanor-Boadu SD, Akinyemi AO. Morphine-sparing effect of intravenous paracetamol for post operative pain management following gynaecological surgery. Afr J Med Med Sci. 2012 Dec;41(4):429-36. PMID: 23672109.L1: X-5

176. Burchett MA, Mattar SG, McKenna DT. Iatrogenic intestinal and mesenteric injuries with small bowel volvulus following use of barbed suture during laparoscopic myomectomy. J Laparoendosc Adv Surg Tech A. 2013 Jul;23(7):632-4. doi: 10.1089/lap.2013.0065. PMID: 23638851.L1: X-4, X-5

177. Chudnoff SG, Berman JM, Levine DJ, et al. Outpatient procedure for the treatment and relief of symptomatic uterine myomas. Obstet Gynecol. 2013 May;121(5):1075-82. doi: 10.1097/AOG.0b013e31828b7962. PMID: 23635746.L1: X-4, X-5

178. Heinonen A, Gissler M, Riska A, et al. Loop electrosurgical excision procedure and the risk for preterm delivery. Obstet Gynecol. 2013 May;121(5):1063-8. doi: 10.1097/AOG.0b013e31828caa31. PMID: 23635744.L1: X-3, X-4, X-5

179. Ramirez Mendoza A, Ramirez Zambrana A, Ramirez Zambrana MC. [Transurethral enucleation prostate with plasmakinetic energy. A new technique of enucleation]. Arch Esp Urol. 2013 Mar;66(2):195-200. PMID: 23589596.L1: X-2, X-3

180. Matsubara S, Usui R, Sato T, et al. Adenomyomectomy, curettage, and then uterine artery pseudoaneurysm occupying the entire uterine cavity. J Obstet Gynaecol Res. 2013 May;39(5):1103-6. doi: 10.1111/jog.12021. PMID: 23551573.L1: X-3, X-4, X-5

181. McPencow AM, Erekson EA, Guess MK, et al. Cost-effectiveness of endometrial evaluation prior to morcellation in surgical procedures for prolapse. Am J Obstet Gynecol. 2013 Jul;209(1):22.e1-9. doi: 10.1016/j.ajog.2013.03.033. PMID: 23545164.L1: X-3, X-5

182. Wang X, Qin J, Chen J, et al. The effect of high-intensity focused ultrasound treatment on immune function in patients with uterine fibroids. Int J Hyperthermia. 2013 May;29(3):225-33. doi: 10.3109/02656736.2013.775672. PMID: 23537008.L1: X-4, X-5

183. Shigemura K, Tanaka K, Haraguchi T, et al. Postoperative infectious complications in our early experience with holmium laser enucleation of the prostate for benign prostatic hyperplasia. Korean J Urol. 2013 Mar;54(3):189-93. doi: 10.4111/kju.2013.54.3.189. PMID: 23526729.L1: X-2, X-3

184. Bogusiewicz M, Rosinska-Bogusiewicz K, Walczyna B, et al. Leiomyomatosis peritonealis disseminata with formation of endometrial cysts within tumors arising after supracervical laparoscopic hysterectomy. Ginekol Pol. 2013 Jan;84(1):68-71. PMID: 23488314.L1: X-3, X-5

185. Pakrashi T, Ressler IB, Sroga JM, et al. Hysteroscopic enucleation of type II submucosal uterine leiomyomas using a TRUCLEAR hysteroscopic morcellator: case report and review of the literature. J Laparoendosc Adv Surg Tech A. 2013 Apr;23(4):378-82. doi: 10.1089/lap.2012.0425. PMID: 23477370.L1: X-5

186. Bahar R, Shimonovitz M, Benshushan A, et al. Case-control study of complications associated with bipolar and monopolar hysteroscopic operations. J Minim Invasive Gynecol. 2013 May-Jun;20(3):376-80. doi: 10.1016/j.jmig.2012.12.012. PMID: 23453765.L1: X-4, X-5

187. Jebunnaher S, Begum SA. Parasitic leiomyoma: a case report. Mymensingh Med J. 2013 Jan;22(1):173-5. PMID: 23416827.L1: X-4, X-5

188. Nevarez Bernal RA, Chaya Hajj M, Velazquez Magana M, et al. [A technique for total laparoscopic hysterectomy with vaginal morcellation on large uteri in order to maintain minimal invasion]. Ginecol Obstet Mex. 2012 Dec;80(12):769-71. PMID: 23405507.L1: X-1, X-3, X-5

189. Emanuel MH. New developments in hysteroscopy. Best Pract Res Clin Obstet Gynaecol. 2013 Jun;27(3):421-9. doi: 10.1016/j.bpobgyn.2012.11.005. PMID: 23385113.L1: X-1

190. Hsiao SM, Lin HH, Peng FS, et al. Comparison of robot-assisted laparoscopic myomectomy and traditional laparoscopic myomectomy. J Obstet Gynaecol Res. 2013 May;39(5):1024-9. doi: 10.1111/j.1447-0756.2012.02073.x. PMID: 23379670.L1: X-5

191. Haimovich S, Mancebo G, Alameda F, et al. Feasibility of a new two-step procedure for office hysteroscopic resection of submucous myomas: results of a pilot study. Eur J Obstet Gynecol Reprod Biol. 2013 Jun;168(2):191-4. doi: 10.1016/j.ejogrb.2013.01.002. PMID: 23375904.L1: X-4, X-5

192. Ito N, Natimatsu Y, Tsukada J, et al. Two cases of postmyomectomy pseudoaneurysm treated by transarterial embolization. Cardiovasc Intervent Radiol. 2013 Dec;36(6):1681-5. doi: 10.1007/s00270-013-0551-0. PMID: 23354964.L1: X-4, X-5

193. Seok Y, Lee E. Morcellation in semi-exteriorized pouch in thoracoscopic surgery. Thorac Cardiovasc Surg. 2014 Mar;62(2):184-5. doi: 10.1055/s-0032-1333139. PMID: 23344760.L1: X-2, X-3

194. AlHilli MM, Nixon KE, Hopkins MR, et al. Long-term outcomes after intrauterine morcellation vs hysteroscopic resection of endometrial polyps. J Minim Invasive Gynecol. 2013 Mar-Apr;20(2):215-21. doi: 10.1016/j.jmig.2012.10.013. PMID: 23295201.L1: X-3, X-5

195. Hequet D, Ricbourg A, Sebbag D, et al. [Placenta accreta: screening, management and complications]. Gynecol Obstet Fertil. 2013 Jan;41(1):31-7. doi: 10.1016/j.gyobfe.2012.11.001. PMID: 23291052.L1: X-1, X-2, X-3

196. Pundir J, Krishnan N, Siozos A, et al. Peri-operative morbidity associated with abdominal myomectomy for very large fibroid uteri. Eur J Obstet Gynecol Reprod Biol. 2013 Apr;167(2):219-24. doi: 10.1016/j.ejogrb.2012.12.010. PMID: 23290249.L1: X-4, X-5

197. Giannella L, Mfuta K, Lamantea R, et al. Loop electrosurgical excision procedure as a life event that impacts on postmenopausal women. J Obstet Gynaecol Res. 2013 Apr;39(4):842-8. doi: 10.1111/j.1447-0756.2012.02061.x. PMID: 23279072.L1: X-3, X-4, X-5

198. Hu CF, Chi SY, Huang KH, et al. Strangulated small intestinal hernia through infraumbilical port site following laparoscopic myomectomy. Taiwan J Obstet Gynecol. 2012 Dec;51(4):654-5. doi: 10.1016/j.tjog.2012.09.026. PMID: 23276576.L1: X-4, X-5

199. Wang KC, Chang WH, Liu WM, et al. Short-term advantages of laparoscopic uterine vessel occlusion in the management of women with symptomatic myoma. Taiwan J Obstet Gynecol. 2012 Dec;51(4):539-44. doi: 10.1016/j.tjog.2012.09.008. PMID: 23276556.L1: INCLUDE L2: X-5

200. Frey HA, Stout MJ, Odibo AO, et al. Risk of cesarean delivery after loop electrosurgical excision procedure. Obstet Gynecol. 2013 Jan;121(1):39-45. doi: http://10.1097/AOG.0b013e318278f904. PMID: 23262926.L1: X-3, X-4

201. Stojanovic M, Brasanac D, Stojicic M. Cutaneous inguinal scar endosalpingiosis and endometriosis: case report with review of literature. Am J Dermatopathol. 2013 Apr;35(2):254-60. doi: 10.1097/DAD.0b013e3182726e09. PMID: 23249836.L1: X-3, X-4, X-5

202. Florez Pena EG, Angarita Africano AM, Cardoso Medina B, et al. [Uterine myoma in remnant cervix]. Ginecol Obstet Mex. 2012 Oct;80(10):659-62. PMID: 23240230.L1: X-5

203. Tsankova M, Nikolov A, Bosev D, et al. [Spontaneous uterine rupture in third trimester twin ivf pregnancy following myomectomy]. Akush Ginekol (Sofiia). 2012;51(5):50-3. PMID: 23234036.L1: X-4, X-5

204. An J, Shin SK, Kwon JY, et al. Incidence of venous air embolism during myomectomy: the effect of patient position. Yonsei Med J. 2013 Jan 1;54(1):209-14. doi: 10.3349/ymj.2013.54.1.209. PMID: 23225821.L1: X-4, X-5

205. Lee SH, Choi JI, Moon KY, et al. Holmium laser enucleation of the prostate: modified morcellation technique and results. Korean J Urol. 2012 Nov;53(11):779-84. doi: 10.4111/kju.2012.53.11.779. PMID: 23185670.L1: X-2, X-3

206. Deffieux X, Faivre E, Fournet S, et al. [Hysteroscopic morcellation: Myosure procedure]. J Gynecol Obstet Biol Reprod (Paris). 2013 Feb;42(1):86-90. doi: 10.1016/j.jgyn.2012.10.009. PMID: 23182784.L1: X-1, X-5

207. Iacono F, Prezioso D, Di Lauro G, et al. Efficacy and safety profile of a novel technique, ThuLEP (Thulium laser enucleation of the prostate) for the treatment of benign prostate hypertrophy. Our experience on 148 patients. BMC Surg. 2012;12 Suppl 1:S21. doi: 10.1186/1471-2482-12-s1-s21. PMID: 23173611.L1: X-2, X-3

208. Gyamfi-Bannerman C, Gilbert S, Landon MB, et al. Risk of uterine rupture and placenta accreta with prior uterine surgery outside of the lower segment. Obstet Gynecol. 2012 Dec;120(6):1332-7. doi: http://10.1097/AOG.0b013e318273695b. PMID: 23168757.L1: X-3

209. Rosenblatt PL, Apostolis CA, Hacker MR, et al. Laparoscopic supracervical hysterectomy with transcervical morcellation and sacrocervicopexy: initial experience with a novel surgical approach to uterovaginal prolapse. J Minim Invasive Gynecol. 2012 Nov-Dec;19(6):749-55. doi: 10.1016/j.jmig.2012.06.009. PMID: 23084680.L1: X-3, X-5

210. Chang WC, Huang PS, Wang PH, et al. Comparison of laparoscopic myomectomy using in situ morcellation with and without uterine artery ligation for treatment of symptomatic myomas. J Minim Invasive Gynecol. 2012 Nov-Dec;19(6):715-21. doi: 10.1016/j.jmig.2012.07.008. PMID: 23084675.L1: X-5

211. Shokeir T, Shalaby H, Nabil H, et al. Reducing blood loss at abdominal myomectomy with preoperative use of dinoprostone intravaginal suppository: a randomized placebo-controlled pilot study. Eur J Obstet Gynecol Reprod Biol. 2013 Jan;166(1):61-4. doi: 10.1016/j.ejogrb.2012.09.014. PMID: 23083831.L1: X-4, X-5

212. Pitter MC, Gargiulo AR, Bonaventura LM, et al. Pregnancy outcomes following robot-assisted myomectomy. Hum Reprod. 2013 Jan;28(1):99-108. doi: 10.1093/humrep/des365. PMID: 23081871.L1: X-4, X-5

213. Favero G. Tips and tricks for successful manual morcellation: a response to "vaginal morcellation: a new strategy for large gynecological malignant tumors extraction. A pilot study". Gynecol Oncol. 2013 Jan;128(1):151. doi: 10.1016/j.ygyno.2012.09.028. PMID: 23041582.L1: X-1

214. Chang KM, Chen MJ, Lee MH, et al. Fertility and pregnancy outcomes after uterine artery occlusion with or without myomectomy. Taiwan J Obstet Gynecol. 2012 Sep;51(3):331-5. doi: 10.1016/j.tjog.2012.07.002. PMID: 23040912.L1: X-1

215. Rowland M, Lesnock J, Edwards R, et al. Occult uterine cancer in patients undergoing laparoscopic hysterectomy with morcellation. Gynecol Oncol. 2012 Oct;127(1 Suppl):S29. doi: 10.1016/j.ygyno.2012.07.080. PMID: 24989567.L1: INCLUDE L2: X-5

216. Stott D, Zakaria M. The transcervical expulsion of a large fibroid. BMJ Case Rep. 2012;2012doi: 10.1136/bcr.01.2012.5523. PMID: 23008360.L1: X-3

217. Oishi H, Wada-Hiraike O, Osuga Y, et al. Spontaneous cessation and recurrence of massive uterine bleeding can occur in uterine artery pseudoaneurysm after laparoscopically assisted myomectomy. J Obstet Gynaecol Res. 2013 Feb;39(2):598-602. doi: 10.1111/j.1447-0756.2012.01993.x. PMID: 23002950.L1: X-4, X-5

218. Serur E, Lakhi N. Tips and tricks for successful manual morcellation: a response to "vaginal morcellation: a new strategy for large gynecological malignant tumor extraction". Gynecol Oncol. 2013 Jan;128(1):150. doi: 10.1016/j.ygyno.2012.09.007. PMID: 22986142.L1: X-1

219. Valentin L, Canis M, Mage G, et al. [How I do... a transient uterine artery occlusion by laparoscopy]. Gynecol Obstet Fertil. 2012 Oct;40(10):623-4. doi: 10.1016/j.gyobfe.2012.07.031. PMID: 22959490.L1: X-1

220. Zeng SY, Liang MR, Li LY, et al. Comparison of the efficacy and complications of different surgical methods for cervical intraepithelial neoplasia. Eur J Gynaecol Oncol. 2012;33(3):257-60. PMID: 22873094.L1: X-3, X-4

221. Duesing N, Schwarz J, Choschzick M, et al. Assessment of cervical intraepithelial neoplasia (CIN) with colposcopic biopsy and efficacy of loop electrosurgical excision procedure (LEEP). Arch Gynecol Obstet. 2012 Dec;286(6):1549-54. doi: 10.1007/s00404-012-2493-1. PMID: 22865036.L1: X-3

222. Chung SH, Lee HH, Kim TH, et al. A patient who was burned in the operative field: a case report. Ulus Travma Acil Cerrahi Derg. 2012 May;18(3):274-6. doi: 10.5505/tjtes.2012.49225. PMID: 22864724.L1: X-4, X-5

223. Torbe A, Mikolajek-Bedner W, Kaluzynski W, et al. Uterine rupture in the second trimester of pregnancy as an iatrogenic complication of laparoscopic myomectomy. Medicina (Kaunas). 2012;48(4):182-5. PMID: 22836290.L1: X-4, X-5

224. Cela V, Freschi L, Simi G, et al. Fertility and endocrine outcome after robot-assisted laparoscopic myomectomy (RALM). Gynecol Endocrinol. 2013 Jan;29(1):79-82. doi: 10.3109/09513590.2012.705393. PMID: 22835042.L1: INCLUDE L2: X-5

225. Wild TT, Bradley CS, Erickson BA. Successful conservative management of a large iatrogenic vesicovaginal fistula after loop electrosurgical excision procedure. Am J Obstet Gynecol. 2012 Sep;207(3):e4-6. doi: 10.1016/j.ajog.2012.06.013. PMID: 22831811.L1: X-3, X-4, X-5

226. Munoz-Cano R, Pascal M, Lombardero M, et al. Nasal challenge test in the diagnosis of latex-related systemic reactions. J Investig Allergol Clin Immunol. 2012;22(4):299-300. PMID: 22812205.L1: X-4, X-5

227. Wyman A, Fuhrig L, Bedaiwy MA, et al. A Novel Technique for Transvaginal Retrieval of Enlarged Pelvic Viscera during Minimally Invasive Surgery. Minim Invasive Surg. 2012;2012:454120. doi: 10.1155/2012/454120. PMID: 22811899.L1: X-1, X-3, X-4, X-5

228. Dan D, Harnanan D, Hariharan S, et al. Extrauterine leiomyomata presenting with sepsis requiring hemicolectomy. Rev Bras Ginecol Obstet. 2012 Jun;34(6):285-9. PMID: 22801604.L1: X-3, X-4, X-5

229. Chen Q, Chen YB, Wang Z, et al. An improved morcellation procedure for holmium laser enucleation of the prostate. J Endourol. 2012 Dec;26(12):1625-8. doi: 10.1089/end.2012.0265. PMID: 22788738.L1: X-2, X-3

230. Jeong CW, Oh JK, Cho MC, et al. Enucleation ratio efficacy might be a better predictor to assess learning curve of holmium laser enucleation of the prostate. Int Braz J Urol. 2012 May-Jun;38(3):362-71; discussions 72. PMID: 22765867.L1: X-2, X-3

231. Netsch C, Bach T, Herrmann TR, et al. Evaluation of the learning curve for Thulium VapoEnucleation of the prostate (ThuVEP) using a mentor-based approach. World J Urol. 2013 Oct;31(5):1231-8. doi: 10.1007/s00345-012-0894-1. PMID: 22733237.L1: X-2, X-3

232. Vercellino G, Erdemoglu E, Joe A, et al. Laparoscopic temporary clipping of uterine artery during laparoscopic myomectomy. Arch Gynecol Obstet. 2012 Nov;286(5):1181-6. doi: 10.1007/s00404-012-2419-y. PMID: 22714065.L1: X-4, X-5

233. Boonlikit S, Thitisagulwong S. C-LETZ versus large loop excision of the transformation zone for the treatment of cervical intraepithelial neoplasia: a randomized controlled trial. Arch Gynecol Obstet. 2012 Nov;286(5):1173-9. doi: 10.1007/s00404-012-2420-5. PMID: 22710953.L1: X-3, X-4, X-5

234. Wijesekera NT, Mauri G, Gupta S, et al. MR imaging evaluation of fibroid clearance following open myomectomy for massive/multiple symptomatic fibroids. Arch Gynecol Obstet. 2012 Nov;286(5):1165-71. doi: 10.1007/s00404-012-2404-5. PMID: 22710951.L1: X-4, X-5

235. Favero G, Anton C, Silva e Silva A, et al. Vaginal morcellation: a new strategy for large gynecological malignant tumor extraction: a pilot study. Gynecol Oncol. 2012 Sep;126(3):443-7. doi: 10.1016/j.ygyno.2012.05.023. PMID: 22634019.L1: X-3, X-5

236. Leren V, Langebrekke A, Qvigstad E. Parasitic leiomyomas after laparoscopic surgery with morcellation. Acta Obstet Gynecol Scand. 2012 Oct;91(10):1233-6. doi: 10.1111/j.1600-0412.2012.01453.x. PMID: 22574911.L1: X-5

237. Sun LL, Cao DY, Yang JX, et al. Value-based medicine analysis on loop electrosurgical excision procedure and CO2 laser vaporization for the treatment of cervical intraepithelial neoplasia 2. J Obstet Gynaecol Res. 2012 Aug;38(8):1064-70. doi: 10.1111/j.1447-0756.2011.01832.x. PMID: 22568858.L1: X-3, X-4, X-5

238. Bittencourt DD, Zanine RM, Sebastiao AM, et al. Number of fragments, margin status and thermal artifacts of conized specimens from LLETZ surgery to treat cervical intraepithelial neoplasia. Sao Paulo Med J. 2012;130(2):92-6. PMID: 22481754.L1: X-3, X-4, X-5

239. Geavlete B, Multescu R, Moldoveanu C, et al. [Innovative technique in large benign prostatic hyperplasia--enucleation by plasma vaporization]. Chirurgia (Bucur). 2012 Jan-Feb;107(1):89-94. PMID: 22480122.L1: X-2, X-3

240. Mencaglia L, Carri G, Prasciolu C, et al. Feasibility and complications in bipolar resectoscopy: preliminary experience. Minim Invasive Ther Allied Technol. 2013 Feb;22(1):50-5. doi: 10.3109/13645706.2012.670117. PMID: 22455618.L1: X-4, X-5

241. Antosh DD, Gutman RE, Iglesia CB, et al. Resident opinions on vaginal hysterectomy training. Female Pelvic Med Reconstr Surg. 2011 Nov;17(6):314-7. doi: 10.1097/SPV.0b013e31823a08bf. PMID: 22453229.L1: X-2, X-3, X-4, X-5

242. Ahyai SA, Chun FK, Lehrich K, et al. Transurethral holmium laser enucleation versus transurethral resection of the prostate and simple open prostatectomy--which procedure is faster? J Urol. 2012 May;187(5):1608-13. doi: 10.1016/j.juro.2011.12.107. PMID: 22425091.L1: X-2, X-3

243. Rivard C, Salhadar A, Kenton K. New challenges in detecting, grading, and staging endometrial cancer after uterine morcellation. J Minim Invasive Gynecol. 2012 May-Jun;19(3):313-6. doi: 10.1016/j.jmig.2011.12.019. PMID: 22417903.L1: X-3, X-5

244. Yanazume S, Tsuji T, Yoshioka T, et al. Large parasitic myomas in abdominal subcutaneous adipose tissue along a previous myomectomy scar. J Obstet Gynaecol Res. 2012 May;38(5):875-9. doi: 10.1111/j.1447-0756.2011.01784.x. PMID: 22413957.L1: X-4, X-5

245. Ramm O, Gleason JL, Segal S, et al. Utility of preoperative endometrial assessment in asymptomatic women undergoing hysterectomy for pelvic floor dysfunction. Int Urogynecol J. 2012 Jul;23(7):913-7. doi: 10.1007/s00192-012-1694-2. PMID: 22398824.L1: X-3, X-5

246. Zhang F, Shao Q, Herrmann TR, et al. Thulium laser versus holmium laser transurethral enucleation of the prostate: 18-month follow-up data of a single center. Urology. 2012 Apr;79(4):869-74. doi: 10.1016/j.urology.2011.12.018. PMID: 22342411.L1: X-2, X-3

247. Kelly DC, Das A. Holmium laser enucleation of the prostate technique for benign prostatic hyperplasia. Can J Urol. 2012 Feb;19(1):6131-4. PMID: 22316518.L1: X-1, X-2, X-3

248. Wang Y, Ji Y, Zhu Y, et al. Laparoscopic splenectomy and azygoportal disconnection with intraoperative splenic blood salvage. Surg Endosc. 2012 Aug;26(8):2195-201. doi: 10.1007/s00464-012-2159-x. PMID: 22278104.L1: X-2, X-3

249. Schuster MW, Wheeler TL, 2nd, Richter HE. Endometriosis after laparoscopic supracervical hysterectomy with uterine morcellation: a case control study. J Minim Invasive Gynecol. 2012 Mar-Apr;19(2):183-7. doi: 10.1016/j.jmig.2011.09.014. PMID: 22265051.L1: X-2, X-3, X-5

250. Cornu JN, Terrasa JB, Lukacs B. Ex vivo comparison of available morcellation devices during holmium laser enucleation of the prostate through objective parameters. J Endourol. 2014 Oct;28(10):1237-40. doi: 10.1089/end.2011.0454. PMID: 22260635.L1: X-1, X-2, X-3

251. Pawel Swiniarski P, Stepien S, Dudzic W, et al. Thulium laser enucleation of the prostate (TmLEP) vs. transurethral resection of the prostate (TURP): evaluation of early results. Cent European J Urol. 2012;65(3):130-4. doi: 10.5173/ceju.2012.03.art6. PMID: 24578948.L1: X-2, X-3

252. Netsch C, Bach T, Pohlmann L, et al. Comparison of 120-200 W 2 mum thulium:yttrium-aluminum-garnet vapoenucleation of the prostate. J Endourol. 2012 Mar;26(3):224-9. doi: 10.1089/end.2011.0173. PMID: 22191688.L1: X-2, X-3

253. Ishikawa R, Shitara T, Wakatabe Y, et al. [Relationship between morcellation efficiency and enucleated tissue weight in holmium laser enucleation of the prostate (HoLEP) for patients with benign prostatic hyperplasia]. Nihon Hinyokika Gakkai Zasshi. 2011 Sep;102(5):675-8. PMID: 22191275.L1: X-2, X-3

254. Lima E, Branco F, Parente J, et al. Transvesical natural orifice transluminal endoscopic surgery (NOTES) nephrectomy with kidney morcellation: a proof of concept study. BJU Int. 2012 May;109(10):1533-7. doi: 10.1111/j.1464-410X.2011.10772.x. PMID: 22176894.L1: X-1, X-2, X-3

255. Teare JA, Petit JC, Ripamonti U. Synergistic induction of periodontal tissue regeneration by binary application of human osteogenic protein-1 and human transforming growth factor-beta3 in Class II furcation defects of Papio ursinus. J Periodontal Res. 2012 Jun;47(3):336-44. doi: 10.1111/j.1600-0765.2011.01438.x. PMID: 22142147.L1: X-2, X-3

256. Ritter M, Krombach P, Bolenz C, et al. Standardized comparison of prostate morcellators using a new ex-vivo model. J Endourol. 2012 Jun;26(6):697-700. doi: 10.1089/end.2011.0536. PMID: 22141409.L1: X-2, X-3

257. Wenger JM, Dubuisson JB, Dallenbach P. Laparoendoscopic single-site supracervical hysterectomy with endocervical resection. J Minim Invasive Gynecol. 2012 Mar-Apr;19(2):217-9. doi: 10.1016/j.jmig.2011.10.009. PMID: 22118885.L1: X-1, X-5

258. Cohen S, Greenberg JA. Hysteroscopic morcellation for treating intrauterine pathology. Rev Obstet Gynecol. 2011 Summer;4(2):73-80. PMID: 22102930.L1: X-1

259. Netsch C, Pohlmann L, Herrmann TR, et al. 120-W 2-microm thulium:yttrium-aluminium-garnet vapoenucleation of the prostate: 12-month follow-up. BJU Int. 2012 Jul;110(1):96-101. doi: 10.1111/j.1464-410X.2011.10767.x. PMID: 22085294.L1: X-2, X-3

260. Kongnyuy EJ, Wiysonge CS. Interventions to reduce haemorrhage during myomectomy for fibroids. Cochrane Database Syst Rev. 2011(11):Cd005355. doi: 10.1002/14651858.CD005355.pub4. PMID: 22071823.L1: X-1

261. Alobaid A, Alqadri T, Serat F, et al. The effect of uterine blood supply cutoff during myomectomy. Ann Saudi Med. 2011 Nov-Dec;31(6):598-601. doi: 10.4103/0256-4947.87096. PMID: 22048505.L1: X-4, X-5

262. Bach T, Netsch C, Pohlmann L, et al. Thulium:YAG vapoenucleation in large volume prostates. J Urol. 2011 Dec;186(6):2323-7. doi: 10.1016/j.juro.2011.07.073. PMID: 22014812.L1: X-2, X-3

263. Park BJ, Kim YW, Maeng LS, et al. Disseminated peritoneal leiomyomatosis after hysterectomy: a case report. J Reprod Med. 2011 Sep-Oct;56(9-10):456-60. PMID: 22010532.L1: X-5

264. Leung F, Terzibachian JJ. Re: "The impact of tumor morcellation during surgery on the prognosis of patients with apparently early uterine leiomyosarcoma". Gynecol Oncol. 2012 Jan;124(1):172-3; author reply 3. doi: 10.1016/j.ygyno.2011.08.035. PMID: 21955481.L1: X-1

265. Oizumi H, Kanauchi N, Kato H, et al. Morcellation technique to remove large tumor in thoracoscopic surgery. Ann Thorac Surg. 2011 Sep;92(3):1141-3. doi: 10.1016/j.athoracsur.2011.03.117. PMID: 21871326.L1: X-2, X-3

266. Boosz A, Lermann J, Mehlhorn G, et al. Is laparoscopic extirpation of the cervical stump after laparoscopic supracervical hysterectomy justified in women with incidentally found atypical endometrial hyperplasia? J Laparoendosc Adv Surg Tech A. 2011 Oct;21(8):705-9. doi: 10.1089/lap.2010.0497. PMID: 21859308.L1: INCLUDE L2: X-5

267. Siegler E, Bornstein J. Loop electrosurgical excision procedures in Israel. Gynecol Obstet Invest. 2011;72(2):85-9. doi: 10.1159/000329324. PMID: 21829002.L1: X-3

268. Hagemann IS, Hagemann AR, LiVolsi VA, et al. Risk of occult malignancy in morcellated hysterectomy: a case series. Int J Gynecol Pathol. 2011 Sep;30(5):476-83. doi: 10.1097/PGP.0b013e3182107ecf. PMID: 21804400.L1: INCLUDE L2: X-5

269. Nakajima H, Sakamoto Y, Tamada I, et al. Dynamic total skull remodeling by a combination of morcellation craniotomy with distraction osteogenesis: the MoD procedure. J Craniofac Surg. 2011 Jul;22(4):1240-6. doi: 10.1097/SCS.0b013e31821c0fef. PMID: 21772208.L1: X-2, X-3

270. Perino AC, Python J, Thompson LC. Management of hematocervix after loop electrosurgical excision procedure. Obstet Gynecol. 2011 Aug;118(2 Pt 2):484-6. doi: 10.1097/AOG.0b013e3182234f5e. PMID: 21768861.L1: X-3, X-4, X-5

271. Zhang P, Song K, Li L, et al. Application of simultaneous morcellation in situ in laparoscopic myomectomy of larger uterine leiomyomas. Med Princ Pract. 2011;20(5):455-8. doi: 10.1159/000327671. PMID: 21757936.L1: X-3, X-5

272. Serur E, Lakhi N. Laparoscopic hysterectomy with manual morcellation of the uterus: an original technique that permits the safe and quick removal of a large uterus. Am J Obstet Gynecol. 2011 Jun;204(6):566.e1-2. doi: 10.1016/j.ajog.2011.03.042. PMID: 21752759.L1: X-1, X-5

273. Cucinella G, Granese R, Calagna G, et al. Parasitic myomas after laparoscopic surgery: an emerging complication in the use of morcellator? Description of four cases. Fertil Steril. 2011 Aug;96(2):e90-6. doi: 10.1016/j.fertnstert.2011.05.095. PMID: 21719004.L1: X-5

274. Simons M, Hamerlynck TW, Abdulkadir L, et al. Hysteroscopic morcellator system can be used for removal of a uterine septum. Fertil Steril. 2011 Aug;96(2):e118-21. doi: 10.1016/j.fertnstert.2011.05.098. PMID: 21718984.L1: X-3, X-5

275. Sami Walid M, Heaton RL. The role of laparoscopic myomectomy in the management of uterine fibroids. Curr Opin Obstet Gynecol. 2011 Aug;23(4):273-7. doi: 10.1097/GCO.0b013e328348a245. PMID: 21666469.L1: X-1

276. Hamerlynck TW, Dietz V, Schoot BC. Clinical implementation of the hysteroscopic morcellator for removal of intrauterine myomas and polyps. A retrospective descriptive study. Gynecol Surg. 2011 May;8(2):193-6. doi: 10.1007/s10397-010-0627-7. PMID: 21654903.L1: X-5

277. Aust T, Gale P, Cario G, et al. Bowel resection for iatrogenic parasitic fibroids with preoperative investigations suggestive of malignancy. Fertil Steril. 2011 Jul;96(1):e1-3. doi: 10.1016/j.fertnstert.2011.04.097. PMID: 21620392.L1: X-5

278. Chou LY, Sheu BC, Chang DY, et al. Operating time and blood loss during laparoscopic-assisted vaginal hysterectomy with in situ morcellation. Acta Obstet Gynecol Scand. 2011 Sep;90(9):985-9. doi: 10.1111/j.1600-0412.2011.01196.x. PMID: 21615713.L1: X-5

279. Anupama R, Ahmad SZ, Kuriakose S, et al. Disseminated peritoneal leiomyosarcomas after laparoscopic "myomectomy" and morcellation. J Minim Invasive Gynecol. 2011 May-Jun;18(3):386-9. doi: 10.1016/j.jmig.2011.01.014. PMID: 21545964.L1: X-3

280. Park JY, Kim DY, Kim JH, et al. The impact of tumor morcellation during surgery on the outcomes of patients with apparently early low-grade endometrial stromal sarcoma of the uterus. Ann Surg Oncol. 2011 Nov;18(12):3453-61. doi: 10.1245/s10434-011-1751-y. PMID: 21541824. X-5

281. Chang WC, Chou LY, Chang DY, et al. Simultaneous laparoscopic uterine artery ligation and laparoscopic myomectomy for symptomatic uterine myomas with and without in situ morcellation. Hum Reprod. 2011 Jul;26(7):1735-40. doi: 10.1093/humrep/der142. PMID: 21540245.L1: X-5

282. Cho MC, Park JH, Jeong MS, et al. Predictor of de novo urinary incontinence following holmium laser enucleation of the prostate. Neurourol Urodyn. 2011 Sep;30(7):1343-9. doi: 10.1002/nau.21050. PMID: 21538499.L1: X-2, X-3

283. Zhang W, Yuan JJ, Kan QC, et al. Influence of CYP3A5*3 polymorphism and interaction between CYP3A5*3 and CYP3A4*1G polymorphisms on post-operative fentanyl analgesia in Chinese patients undergoing gynaecological surgery. Eur J Anaesthesiol. 2011 Apr;28(4):245-50. PMID: 21513075.L1: X-4, X-5

284. Findlay JM, Mihai R. Complications of thyroid surgery. Br J Hosp Med (Lond). 2011 Mar;72(3):M44-7. PMID: 21475108.L1: X-1, X-2, X-3

285. Bae J, Choo M, Park JH, et al. Holmium laser enucleation of prostate for benign prostatic hyperplasia: seoul national university hospital experience. Int Neurourol J. 2011 Mar;15(1):29-34. doi: 10.5213/inj.2011.15.1.29. PMID: 21468284.L1: X-2, X-3

286. Dubuisson J, Golfier F, Raudrant D. [Hysteroscopic myomectomy using bipolar energy: a gold standard?]. J Gynecol Obstet Biol Reprod (Paris). 2011 Jun;40(4):291-6. doi: 10.1016/j.jgyn.2011.01.011. PMID: 21367539.L1: X-1

287. Armarnik S, Sheiner E, Piura B, et al. Obstetric outcome following cervical conization. Arch Gynecol Obstet. 2011 Apr;283(4):765-9. doi: 10.1007/s00404-011-1848-3. PMID: 21327802.L1: X-3, X-4, X-5

288. Goto T, Shimizu Y, Inoue T, et al. [A case of bladder paraganglioma managed by transurethral approach, using holmium laser]. Hinyokika Kiyo. 2010 Dec;56(12):705-7. PMID: 21273811.L1: X-2, X-3

289. Buisan O, Saladie JM, Ruiz JM, et al. [Diode laser enucleation of the prostate (Dilep): technique and initial results]. Actas Urol Esp. 2011 Jan;35(1):37-41. doi: 10.1016/j.acuro.2010.08.003. PMID: 21256393.L1: X-2, X-3

290. Kill LM, Kapetanakis V, McCullough AE, et al. Progression of pelvic implants to complex atypical endometrial hyperplasia after uterine morcellation. Obstet Gynecol. 2011 Feb;117(2 Pt 2):447-9. doi: 10.1097/AOG.0b013e3181f2e0c6. PMID: 21252784.L1: X-5

291. Lim MC, Song YJ, Seo SS, et al. Embryonic-natural orifice transumbilical endoscopic surgery for myomectomy with traction of multidirectional sutures: a new surgical approach. J Laparoendosc Adv Surg Tech A. 2011 Jan-Feb;21(1):35-7. doi: 10.1089/lap.2010.0268. PMID: 21214489.L1: X-5

292. Jain N. Multiple layer closure of myoma bed in laparoscopic myomectomy. J Gynecol Endosc Surg. 2011 Jan;2(1):43-6. doi: 10.4103/0974-1216.85281. PMID: 22442535.L1: INCLUDE L2: X-5

293. Quinlan D, Quinlan DK. Vaginal hysterectomy for the enlarged fibroid uterus: a report of 85 cases. J Obstet Gynaecol Can. 2010 Oct;32(10):980-3. PMID: 21176308.L1: X-4, X-5

294. Hirayama T, Shitara T, Fujita T, et al. [Holmium laser enucleation of the prostate (HoLEP) in patients with continuous oral anticoagulation: first reported cases in Japan]. Nihon Hinyokika Gakkai Zasshi. 2010 Nov;101(7):754-7. PMID: 21174742.L1: X-1, X-2, X-3

295. Eltabey MA, Sherif H, Hussein AA. Holmium laser enucleation versus transurethral resection of the prostate. Can J Urol. 2010 Dec;17(6):5447-52. PMID: 21172109.L1: X-2, X-3

296. Krambeck AE. Evolution and success of holmium laser enucleation of the prostate. Indian J Urol. 2010 Jul;26(3):404-9. doi: 10.4103/0970-1591.70582. PMID: 21116363.L1: X-1, X-2, X-3

297. Baldwin DD, Tenggardjaja C, Bowman R, et al. Hybrid transureteral natural orifice translumenal endoscopic nephrectomy: a feasibility study in the porcine model. J Endourol. 2011 Feb;25(2):245-50. doi: 10.1089/end.2010.0311. PMID: 21058889.L1: X-2, X-3

298. Chen SY, Huang SC, Sheu BC, et al. Simultaneous enucleation and in situ morcellation of myomas in laparoscopic myomectomy. Taiwan J Obstet Gynecol. 2010 Sep;49(3):279-84. doi: 10.1016/s1028-4559(10)60061-7. PMID: 21056311.L1: X-5

299. Jashnani KD, Baviskar RR. The surgical pathologist and laparoscopic gynecologic surgeries. Indian J Pathol Microbiol. 2010 Oct-Dec;53(4):634-9. doi: 10.4103/0377-4929.72006. PMID: 21045383.L1: X-2, X-5

300. Sun DC, Yang Y, Wei ZT, et al. Transurethral dividing vaporesection for the treatment of large volume benign prostatic hyperplasia using 2 micron continuous wave laser. Chin Med J (Engl). 2010 Sep;123(17):2370-4. PMID: 21034551.L1: X-2, X-3

301. Bae J, Oh SJ, Paick JS. The learning curve for holmium laser enucleation of the prostate: a single-center experience. Korean J Urol. 2010 Oct;51(10):688-93. doi: 10.4111/kju.2010.51.10.688. PMID: 21031088.L1: X-2, X-3

302. Della Badia C, Karini H. Endometrial stromal sarcoma diagnosed after uterine morcellation in laparoscopic supracervical hysterectomy. J Minim Invasive Gynecol. 2010 Nov-Dec;17(6):791-3. doi: 10.1016/j.jmig.2010.07.001. PMID: 20955991.L1: X-3

303. Hansen EN, Muensterer OJ. Single incision laparoscopic splenectomy in a 5-year-old with hereditary spherocytosis. Jsls. 2010 Apr-Jun;14(2):286-8. doi: 10.4293/108680810x12785289144809. PMID: 20932387.L1: X-2, X-3, X-5

304. Hwang JC, Park SM, Lee JB. Holmium laser enucleation of the prostate for benign prostatic hyperplasia: effectiveness, safety, and overcoming of the learning curve. Korean J Urol. 2010 Sep;51(9):619-24. doi: 10.4111/kju.2010.51.9.619. PMID: 20856646.L1: X-2, X-3

305. Ordulu Z, Dal Cin P, Chong WW, et al. Disseminated peritoneal leiomyomatosis after laparoscopic supracervical hysterectomy with characteristic molecular cytogenetic findings of uterine leiomyoma. Genes Chromosomes Cancer. 2010 Dec;49(12):1152-60. doi: 10.1002/gcc.20824. PMID: 20842731.L1: X-5

306. Hirayama T, Shitara T, Fujita T, et al. [An effective method to shorten the learning curve of HoLEP]. Hinyokika Kiyo. 2010 Aug;56(8):431-4. PMID: 20808060.L1: X-2, X-3, X-5

307. Krambeck AE, Humphreys MR, Andrews PE, et al. Natural orifice translumenal endoscopic surgery: radical prostatectomy in the canine model. J Endourol. 2010 Sep;24(9):1493-6. doi: 10.1089/end.2009.0276. PMID: 20804436.L1: X-1, X-2, X-3

308. Vannucci J, Pecoriello R, Ragusa M, et al. Multiple pleuropericardial implants of thymoma after videothoracoscopic resection. Interact Cardiovasc Thorac Surg. 2010 Nov;11(5):696-7. doi: 10.1510/icvts.2010.246322. PMID: 20719905.L1: X-2, X-3

309. Munro MG. Complications of hysteroscopic and uterine resectoscopic surgery. Obstet Gynecol Clin North Am. 2010 Sep;37(3):399-425. doi: 10.1016/j.ogc.2010.05.006. PMID: 20674783.L1: X-1

310. Larrain D, Rabischong B, Khoo CK, et al. "Iatrogenic" parasitic myomas: unusual late complication of laparoscopic morcellation procedures. J Minim Invasive Gynecol. 2010 Nov-Dec;17(6):719-24. doi: 10.1016/j.jmig.2010.05.013. PMID: 20655285.L1: X-3, X-5

311. Parker WH, Einarsson J, Istre O, et al. Risk factors for uterine rupture after laparoscopic myomectomy. J Minim Invasive Gynecol. 2010 Sep-Oct;17(5):551-4. doi: 10.1016/j.jmig.2010.04.015. PMID: 20591749.L1: X-1, X-5

312. Kim YW, Park BJ, Ro DY, et al. Single-port laparoscopic myomectomy using a new single-port transumbilical morcellation system: initial clinical study. J Minim Invasive Gynecol. 2010 Sep-Oct;17(5):587-92. doi: 10.1016/j.jmig.2010.04.009. PMID: 20576473.L1: X-5

313. Pezzuto A, Serboli G, Ceccaroni M, et al. Two case reports of bowel leiomyomas and review of literature. Gynecol Endocrinol. 2010 Dec;26(12):894-6. doi: 10.3109/09513590.2010.488767. PMID: 20515257.L1: X-3, X-4, X-5

314. Song T, Kim TJ, Kim MK, et al. Single port access laparoscopic-assisted vaginal hysterectomy for large uterus weighing exceeding 500 grams: technique and initial report. J Minim Invasive Gynecol. 2010 Jul-Aug;17(4):456-60. doi: 10.1016/j.jmig.2010.02.009. PMID: 20471918.L1: X-5

315. Ercan CM. Letter to the editor. J Minim Invasive Gynecol. 2010 May-Jun;17(3):402; author reply 3. doi: 10.1016/j.jmig.2009.12.023. PMID: 20417439.L1: X-1

316. Wong WS, Lee TC, Lim CE. Novel Vaginal "paper roll" uterine morcellation technique for removal of large (>500 g) uterus. J Minim Invasive Gynecol. 2010 May-Jun;17(3):374-8. doi: 10.1016/j.jmig.2010.02.005. PMID: 20417430.L1: X-5

317. Rosenblatt P, Makai G, DiSciullo A. Laparoscopic supracervical hysterectomy with transcervical morcellation: initial experience. J Minim Invasive Gynecol. 2010 May-Jun;17(3):331-6. doi: 10.1016/j.jmig.2010.02.004. PMID: 20417424.L1: X-5

318. Erman-Akar M, Mullany S, Huffman J, et al. Early postoperative small bowel obstruction after laparoscopic myomectomy. Fertil Steril. 2010 Nov;94(6):2329.e9-12. doi: 10.1016/j.fertnstert.2010.03.032. PMID: 20416869.L1: X-5

319. Kummer M, Theiss F, Jackson M, et al. Evaluation of a motorized morcellator for laparoscopic removal of granulosa-theca cell tumors in standing mares. Vet Surg. 2010 Jul;39(5):649-53. doi: 10.1111/j.1532-950X.2010.00688.x. PMID: 20345529.L1: X-2, X-3, X-5

320. Sinha R, Sethi S, Mahajan C, et al. Multiple and bilateral dermoids: a case report. J Minim Invasive Gynecol. 2010 Mar-Apr;17(2):235-8. doi: 10.1016/j.jmig.2009.11.005. PMID: 20226415.L1: X-3, X-5

321. Zullo F, Falbo A, Iuliano A, et al. Randomized controlled study comparing the Gynecare Morcellex and Rotocut G1 tissue morcellators. J Minim Invasive Gynecol. 2010 Mar-Apr;17(2):192-9. doi: 10.1016/j.jmig.2009.11.009. PMID: 20226407.L1: X-5

322. Abdel-Hakim AM, Habib EI, El-Feel AS, et al. Holmium laser enucleation of the prostate: initial report of the first 230 Egyptian cases performed in a single center. Urology. 2010 Aug;76(2):448-52. doi: 10.1016/j.urology.2009.12.035. PMID: 20223507.L1: X-2, X-3

323. Altchek A, Brodman M, Schlosshauer P, et al. Laparoscopic morcellation of didelphic uterus with cervical and renal aplasia. Jsls. 2009 Oct-Dec;13(4):620-4. doi: 10.4293/108680809x12589999538237. PMID: 20202407.L1: X-2, X-3

324. Werner CL, Lo JY, Heffernan T, et al. Loop electrosurgical excision procedure and risk of preterm birth. Obstet Gynecol. 2010 Mar;115(3):605-8. doi: 10.1097/AOG.0b013e3181d068a3. PMID: 20177293.L1: X-3, X-4, X-5

325. Sinha R, Lakhotia S, Sundaram M, et al. Retained uterine fundus after vaginal hysterectomy. J Minim Invasive Gynecol. 2010 Jan-Feb;17(1):94-6. doi: 10.1016/j.jmig.2009.09.004. PMID: 20129338.L1: X-3, X-5

326. Rokita W, Stanislawska M, Spaczynski M, et al. [Electrosurgery of cervical changes and its place in cervical cancer prophylaxis]. Ginekol Pol. 2009 Nov;80(11):856-60. PMID: 20088401.L1: X-1, X-2, X-4, X-5

327. Al-Talib A, Tulandi T. Pathophysiology and possible iatrogenic cause of leiomyomatosis peritonealis disseminata. Gynecol Obstet Invest. 2010;69(4):239-44. doi: 10.1159/000274487. PMID: 20068330.L1: X-1, X-5

328. Tchartchian G, Dietzel J, Bojahr B, et al. No more abdominal hysterectomy for myomata using a new minimally-invasive technique. Int J Surg Case Rep. 2010;1(1):7-8. doi: 10.1016/j.ijscr.2010.06.001. PMID: 22096663.L1: X-3, X-5

329. Targarona EM, Balague C, Martinez C, et al. Single-port access: a feasible alternative to conventional laparoscopic splenectomy. Surg Innov. 2009 Dec;16(4):348-52. doi: 10.1177/1553350609353765. PMID: 20031948.L1: X-2, X-3, X-4, X-5

330. Sotomayor-Ramirez RK. Efficacy and safety of laparoscopic splenectomy: review of 14 adult cases using the lateral approach. Bol Asoc Med P R. 2009 Apr-Jun;101(2):43-9. PMID: 19954101.L1: X-1, X-2, X-3

331. Noehr B, Jensen A, Frederiksen K, et al. Depth of cervical cone removed by loop electrosurgical excision procedure and subsequent risk of spontaneous preterm delivery. Obstet Gynecol. 2009 Dec;114(6):1232-8. doi: 10.1097/AOG.0b013e3181bf1ef2. PMID: 19935024.L1: X-3, X-4, X-5

332. Yoon G, Kim TJ, Lee YY, et al. Single-port access subtotal hysterectomy with transcervical morcellation: a pilot study. J Minim Invasive Gynecol. 2010 Jan-Feb;17(1):78-81. doi: 10.1016/j.jmig.2009.09.018. PMID: 19926345.L1: X-5

333. Shanbhag S, Clark H, Timmaraju V, et al. Pregnancy outcome after treatment for cervical intraepithelial neoplasia. Obstet Gynecol. 2009 Oct;114(4):727-35. doi: 10.1097/AOG.0b013e3181b5cba3. PMID: 19888028.L1: X-3, X-4, X-5

334. Litta P, Fantinato S, Calonaci F, et al. A randomized controlled study comparing harmonic versus electrosurgery in laparoscopic myomectomy. Fertil Steril. 2010 Oct;94(5):1882-6. doi: 10.1016/j.fertnstert.2009.08.049. PMID: 19819439.L1: X-5

335. Shashoua AR, Gill D, Locher SR. Robotic-assisted total laparoscopic hysterectomy versus conventional total laparoscopic hysterectomy. Jsls. 2009 Jul-Sep;13(3):364-9. PMID: 19793478.L1: X-5

336. Abrolat R, Langer K, Roos N. [Day-case holmium laser enucleation and mechanical morcellation of the prostate]. Urologe A. 2009 Dec;48(12):1490-4. doi: 10.1007/s00120-009-2099-9. PMID: 19760387.L1: X-2, X-3

337. Kho KA, Nezhat C. Parasitic myomas. Obstet Gynecol. 2009 Sep;114(3):611-5. doi: 10.1097/AOG.0b013e3181b2b09a. PMID: 19701042.L1: X-2, X-5

338. Boggess JF, Gehrig PA, Cantrell L, et al. Perioperative outcomes of robotically assisted hysterectomy for benign cases with complex pathology. Obstet Gynecol. 2009 Sep;114(3):585-93. doi: 10.1097/AOG.0b013e3181b47030. PMID: 19701039.L1: X-5

339. Wu SD, Lesani OA, Zhao LC, et al. A multi-institutional study on the safety and efficacy of specimen morcellation after laparoscopic radical nephrectomy for clinical stage T1 or T2 renal cell carcinoma. J Endourol. 2009 Sep;23(9):1513-8. doi: 10.1089/end.2009.0387. PMID: 19694517.L1: X-2, X-3, X-5

340. Bach T, Netsch C, Haecker A, et al. Thulium:YAG laser enucleation (VapoEnucleation) of the prostate: safety and durability during intermediate-term follow-up. World J Urol. 2010 Feb;28(1):39-43. doi: 10.1007/s00345-009-0461-6. PMID: 19669645.L1: X-2, X-3

341. Zografos GN, Vasiliadis G, Farfaras AN, et al. Laparoscopic surgery for malignant adrenal tumors. Jsls. 2009 Apr-Jun;13(2):196-202. PMID: 19660215.L1: X-1, X-3

342. Gabr AH, Gdor Y, Strope SA, et al. Approach and specimen handling do not influence oncological perioperative and long-term outcomes after laparoscopic radical nephrectomy. J Urol. 2009 Sep;182(3):874-80. doi: 10.1016/j.juro.2009.05.034. PMID: 19616234.L1: X-3

343. Low YS, Adams T, Clement-Jones M. Uterine rupture during the mid-trimester management of intrauterine fetal death. J Obstet Gynaecol. 2009 Jul;29(5):443. doi: 10.1080/01443610902919165. PMID: 19603331.L1: X-3, X-4, X-5

344. Martinez-Zamora MA, Castelo-Branco C, Balasch J, et al. Comparison of a new reusable gynecologic laparoscopic electric morcellator with a disposable morcellator: a preliminary trial. J Minim Invasive Gynecol. 2009 Sep-Oct;16(5):595-8. doi: 10.1016/j.jmig.2009.05.010. PMID: 19596217.L1: X-5

345. Zhang JT, Wang HB, Liu YF, et al. Laparoscopic splenectomy in goats. Vet Surg. 2009 Apr;38(3):406-10. doi: 10.1111/j.1532-950X.2009.00507.x. PMID: 19573106.L1: X-2, X-3, X-5

346. Sinha R, Sundaram M, Lakhotia S, et al. Parasitic myoma after morcellation. J Gynecol Endosc Surg. 2009 Jul;1(2):113-5. doi: 10.4103/0974-1216.71612. PMID: 22442523.L1: X-3, X-5

347. Walid MS, Heaton RL. Laparoscopic myomectomy: an intent-to-treat study. Arch Gynecol Obstet. 2010 Apr;281(4):645-9. doi: 10.1007/s00404-009-1154-5. PMID: 19536553.L1: X-5

348. Kietpeerakool C, Cheewakriangkrai C, Suprasert P, et al. Feasibility of the 'see and treat' approach in management of women with 'atypical squamous cell, cannot exclude high-grade squamous intraepithelial lesion' smears. J Obstet Gynaecol Res. 2009 Jun;35(3):507-13. doi: 10.1111/j.1447-0756.2008.00992.x. PMID: 19527391.L1: X-2, X-3, X-4, X-5

349. Garuti G, Luerti M. Hysteroscopic bipolar surgery: a valuable progress or a technique under investigation? Curr Opin Obstet Gynecol. 2009 Aug;21(4):329-34. doi: 10.1097/GCO.0b013e32832e07ac. PMID: 19512926.L1: X-1, X-2

350. Duarte RJ, Denes FT, Cristofani LM, et al. Laparoscopic nephrectomy for Wilms' tumor. Expert Rev Anticancer Ther. 2009 Jun;9(6):753-61. doi: 10.1586/era.09.44. PMID: 19496712.L1: X-2, X-3, X-4, X-5

351. Farrugia M, Hussain SY, Perrett D. Particulate matter generated during monopolar and bipolar hysteroscopic human uterine tissue vaporization. J Minim Invasive Gynecol. 2009 Jul-Aug;16(4):458-64. doi: 10.1016/j.jmig.2009.04.006. PMID: 19482521.L1: X-4, X-5

352. Chung DE, Te AE. New techniques for laser prostatectomy: an update. Ther Adv Urol. 2009 Jun;1(2):85-97. doi: 10.1177/1756287209105436. PMID: 21789057.L1: X-1, X-2, X-3

353. Michelin MA, Merino LM, Franco CA, et al. Pregnancy outcome after treatment of cervical intraepithelial neoplasia by the loop electrosurgical excision procedure and cold knife conization. Clin Exp Obstet Gynecol. 2009;36(1):17-9. PMID: 19400411.L1: X-3, X-4, X-5

354. Xia SJ. Two-micron (thulium) laser resection of the prostate-tangerine technique: a new method for BPH treatment. Asian J Androl. 2009 May;11(3):277-81. doi: 10.1038/aja.2009.17. PMID: 19398957.L1: X-2, X-3

355. Placer J, Gelabert-Mas A, Vallmanya F, et al. Holmium laser enucleation of prostate: outcome and complications of self-taught learning curve. Urology. 2009 May;73(5):1042-8. doi: 10.1016/j.urology.2008.12.052. PMID: 19394500.L1: X-2, X-3

356. Varlet F, Stephan JL, Guye E, et al. Laparoscopic radical nephrectomy for unilateral renal cancer in children. Surg Laparosc Endosc Percutan Tech. 2009 Apr;19(2):148-52. doi: 10.1097/SLE.0b013e31819f204d. PMID: 19390283.L1: X-2, X-3

357. Lincoln MR, Ramagopalan SV, Chao MJ, et al. Epistasis among HLA-DRB1, HLA-DQA1, and HLA-DQB1 loci determines multiple sclerosis susceptibility. Proc Natl Acad Sci U S A. 2009 May 5;106(18):7542-7. doi: 10.1073/pnas.0812664106. PMID: 19380721.L1: X-1, X-2, X-3

358. Istre O. Managing bleeding, fluid absorption and uterine perforation at hysteroscopy. Best Pract Res Clin Obstet Gynaecol. 2009 Oct;23(5):619-29. doi: 10.1016/j.bpobgyn.2009.03.003. PMID: 19375391.L1: X-1, X-4, X-5

359. Ohdaira T, Endo K, Abe N, et al. Transintestinal hepatectomy performed by hybrid NOTES using a customized X-TRACT Tissue Morcellator with an electrifiable round cutter. J Hepatobiliary Pancreat Surg. 2009;16(3):274-82. doi: 10.1007/s00534-009-0084-8. PMID: 19363585.L1: X-2, X-3, X-5

360. Humphreys MR, Krambeck AE, Andrews PE, et al. Natural orifice translumenal endoscopic surgical radical prostatectomy: proof of concept. J Endourol. 2009 Apr;23(4):669-75. doi: 10.1089/end.2008.0670. PMID: 19335320.L1: X-1, X-2, X-3

361. Brown CT, Hindley RG, Rimington PD, et al. The Eastbourne extraction: forceps removal of large laparoscopic nephrectomy specimens without morcellation. Surg Laparosc Endosc Percutan Tech. 2009 Feb;19(1):82-3. doi: 10.1097/SLE.0b013e31818a6d76. PMID: 19238074.L1: X-1, X-2, X-3

362. Bach T, Wendt-Nordahl G, Michel MS, et al. Feasibility and efficacy of Thulium:YAG laser enucleation (VapoEnucleation) of the prostate. World J Urol. 2009 Aug;27(4):541-5. doi: 10.1007/s00345-008-0370-0. PMID: 19184038.L1: X-2, X-3

363. Mackenzie KA, Davis C, Yang A, et al. Evolution of surgery for sagittal synostosis: the role of new technologies. J Craniofac Surg. 2009 Jan;20(1):129-33. doi: 10.1097/SCS.0b013e318190e1cf. PMID: 19165009.L1: X-2, X-3

364. Parikh R, Horne H, Feinstein SJ, et al. Cervical length screening in patients who have undergone loop electrosurgical excision procedure. J Reprod Med. 2008 Dec;53(12):909-13. PMID: 19160648.L1: X-3, X-4, X-5

365. Parkar RB, Chudasama A, Chudasama M. Laparoscopic myomectomy of a large pedunculated fibroid: case report. East Afr Med J. 2008 Jul;85(7):362-4. PMID: 19133426.L1: X-3, X-4, X-5

366. Sinha R, Sundaram M, Lakhotia S, et al. Total laparoscopic hysterectomy for large uterus. J Gynecol Endosc Surg. 2009 Jan;1(1):34-9. doi: 10.4103/0974-1216.51908. PMID: 22442509.L1: INCLUDE L2: X-5

367. Kietpeerakool C, Suprasert P, Srisomboon J. Outcome of loop electrosurgical excision for HIV-positive women in a low-resource outpatient setting. Int J Gynaecol Obstet. 2009 Apr;105(1):10-3. doi: 10.1016/j.ijgo.2008.11.006. PMID: 19084838.L1: X-3, X-4, X-5

368. Condous G, Bignardi T, Alhamdan D, et al. What determines the need to morcellate the uterus during total laparoscopic hysterectomy? J Minim Invasive Gynecol. 2009 Jan-Feb;16(1):52-5. doi: 10.1016/j.jmig.2008.09.618. PMID: 18996059.L1: X-5

369. Sankaranarayanan R, Keshkar V, Kothari A, et al. Effectiveness and safety of loop electrosurgical excision procedure for cervical neoplasia in rural India. Int J Gynaecol Obstet. 2009 Feb;104(2):95-9. doi: 10.1016/j.ijgo.2008.09.009. PMID: 18962583.L1: X-3, X-4, X-5

370. Elzayat EA, Khalaf I, Elgallad M, et al. Holmium laser enucleation of prostate in patients with prostate size </=60 cm3. Urology. 2009 Jan;73(1):95-9. doi: 10.1016/j.urology.2008.06.049. PMID: 18952269.L1: X-2, X-3

371. Miyake T, Enomoto T, Ueda Y, et al. A case of disseminated peritoneal leiomyomatosis developing after laparoscope-assisted myomectomy. Gynecol Obstet Invest. 2009;67(2):96-102. doi: 10.1159/000164949. PMID: 18946223.L1: X-5

372. Leung F, Terzibachian JJ, Gay C, et al. [Hysterectomies performed for presumed leiomyomas: should the fear of leiomyosarcoma make us apprehend non laparotomic surgical routes?]. Gynecol Obstet Fertil 2009 Feb;37(2):109-14. PMID: 19200764. X-5

373. Hsiao W, Pattaras JG. Not so "simple" laparoscopic nephrectomy: outcomes and complications of a 7-year experience. J Endourol. 2008 Oct;22(10):2285-90. doi: 10.1089/end.2008.9718. PMID: 18937592.L1: X-3, X-5

374. Epstein JH, Nejat EJ, Tsai T. Parasitic myomas after laparoscopic myomectomy: case report. Fertil Steril. 2009 Mar;91(3):932.e13-4. doi: 10.1016/j.fertnstert.2008.08.014. PMID: 18922520.L1: X-5

375. Monteiro AC, Russomano FB, Camargo MJ, et al. Cervical stenosis following electrosurgical conization. Sao Paulo Med J. 2008 Jul;126(4):209-14. PMID: 18853028.L1: X-3, X-4, X-5

376. Takiuchi H, Nakao A, Ihara H. [Prevention of transient urinary incontinence in peri-operative period of modified holmium laser enucleation of the prostate (HoLEP)]. Hinyokika Kiyo. 2008 Jul;54(7):475-8. PMID: 18697491.L1: X-2, X-3

377. Chen SY, Chang DY, Sheu BC, et al. Laparoscopic-assisted vaginal hysterectomy with in situ morcellation for large uteri. J Minim Invasive Gynecol. 2008 Sep-Oct;15(5):559-65. doi: 10.1016/j.jmig.2008.06.002. PMID: 18657481.L1: X-5

378. Torng PL, Hwang JS, Huang SC, et al. Effect of simultaneous morcellation in situ on operative time during laparoscopic myomectomy. Hum Reprod. 2008 Oct;23(10):2220-6. doi: 10.1093/humrep/den256. PMID: 18617593.L1: X-5

379. van Dongen H, Emanuel MH, Wolterbeek R, et al. Hysteroscopic morcellator for removal of intrauterine polyps and myomas: a randomized controlled pilot study among residents in training. J Minim Invasive Gynecol. 2008 Jul-Aug;15(4):466-71. doi: 10.1016/j.jmig.2008.02.002. PMID: 18588849.L1: X-5

380. Lesani OA, Zhao LC, Han J, et al. Safety and efficacy of laparoscopic radical nephrectomy with manual specimen morcellation for stage cT1 renal-cell carcinoma. J Endourol. 2008 Jun;22(6):1257-9. doi: 10.1089/end.2008.0171. PMID: 18578659.L1: X-3

381. Pfaendler KS, Mwanahamuntu MH, Sahasrabuddhe VV, et al. Management of cryotherapy-ineligible women in a "screen-and-treat" cervical cancer prevention program targeting HIV-infected women in Zambia: lessons from the field. Gynecol Oncol. 2008 Sep;110(3):402-7. doi: 10.1016/j.ygyno.2008.04.031. PMID: 18556050.L1: X-3

382. Iwamoto K, Hiraoka Y, Shimizu Y. Transurethral detachment prostatectomy using a tissue morcellator for large benign prostatic hyperplasia. J Nippon Med Sch. 2008 Apr;75(2):77-84. PMID: 18475027.L1: X-2, X-3

383. Sinha R, Sundaram M, Nikam YA, et al. Total laparoscopic hysterectomy with earlier uterine artery ligation. J Minim Invasive Gynecol. 2008 May-Jun;15(3):355-9. doi: 10.1016/j.jmig.2008.01.012. PMID: 18439511.L1: X-5

384. Erian J, Hassan M, Pachydakis A, et al. Efficacy of laparoscopic subtotal hysterectomy in the management of menorrhagia: 400 consecutive cases. Bjog. 2008 May;115(6):742-8. doi: 10.1111/j.1471-0528.2008.01698.x. PMID: 18410659.L1: X-5

385. Rassweiler J, Roder M, Schulze M, et al. [Transurethral enucleation of the prostate with the holmium: YAG laser system: how much power is necessary?]. Urologe A. 2008 Apr;47(4):441-8. doi: 10.1007/s00120-008-1684-7. PMID: 18338152.L1: X-2, X-3

386. Duarte RJ, Mitre AI, Chambo JL, et al. Laparoscopic nephrectomy outside gerota fascia for management of inflammatory kidney. J Endourol. 2008 Apr;22(4):681-6. doi: 10.1089/end.2007.0291. PMID: 18324896.L1: X-2, X-3

387. Litta P, Cosmi E, Saccardi C, et al. Outpatient operative polypectomy using a 5 mm-hysteroscope without anaesthesia and/or analgesia: advantages and limits. Eur J Obstet Gynecol Reprod Biol. 2008 Aug;139(2):210-4. doi: 10.1016/j.ejogrb.2007.11.008. PMID: 18248873.L1: X-3, X-4, X-5

388. Kumar S, Sharma JB, Verma D, et al. Disseminated peritoneal leiomyomatosis: an unusual complication of laparoscopic myomectomy. Arch Gynecol Obstet. 2008 Jul;278(1):93-5. doi: 10.1007/s00404-007-0536-9. PMID: 18193441.L1: X-5

389. Kietpeerakool C, Srisomboon J, Tiyayon J, et al. Appropriate interval for repeat excision in women undergoing prior loop electrosurgical excision procedure for cervical neoplasia. Asian Pac J Cancer Prev. 2007 Jul-Sep;8(3):379-82. PMID: 18159972.L1: X-3, X-4, X-5

390. Di Spiezio Sardo A, Mazzon I, Bramante S, et al. Hysteroscopic myomectomy: a comprehensive review of surgical techniques. Hum Reprod Update. 2008 Mar-Apr;14(2):101-19. doi: 10.1093/humupd/dmm041. PMID: 18063608.L1: X-1

391. Vavassori I, Valenti S, Naspro R, et al. Three-year outcome following holmium laser enucleation of the prostate combined with mechanical morcellation in 330 consecutive patients. Eur Urol. 2008 Mar;53(3):599-604. doi: 10.1016/j.eururo.2007.10.059. PMID: 17997021.L1: X-2, X-3

392. Giannarini G. Editorial comment on: Three-year outcome following holmium laser enucleation of the prostate combined with mechanical morcellation in 330 consecutive patients. Eur Urol. 2008 Mar;53(3):605-6. doi: 10.1016/j.eururo.2007.10.061. PMID: 17997018.L1: X-1, X-2, X-3

393. de Reijke TM. Editorial comment on: Three-year outcome following holmium laser enucleation of the prostate combined with mechanical morcellation in 330 consecutive patients. Eur Urol. 2008 Mar;53(3):604-5. doi: 10.1016/j.eururo.2007.10.060. PMID: 17997015.L1: X-1, X-2, X-3

394. Takeda A, Mori M, Sakai K, et al. Parasitic peritoneal leiomyomatosis diagnosed 6 years after laparoscopic myomectomy with electric tissue morcellation: report of a case and review of the literature. J Minim Invasive Gynecol. 2007 Nov-Dec;14(6):770-5. doi: 10.1016/j.jmig.2007.07.004. PMID: 17980343.L1: X-5

395. Granberg CF, Krambeck AE, Leibovich BC, et al. Potential underdetection of pT(3a) renal-cell carcinoma with laparoscopic morcellation. J Endourol. 2007 Oct;21(10):1183-6. doi: 10.1089/end.2007.9910. PMID: 17949322.L1: X-2, X-3

396. Kongnyuy EJ, van den Broek N, Wiysonge CS. A systematic review of randomized controlled trials to reduce hemorrhage during myomectomy for uterine fibroids. Int J Gynaecol Obstet. 2008 Jan;100(1):4-9. doi: 10.1016/j.ijgo.2007.05.050. PMID: 17894936.L1: X-1

397. Tanaka K, Kawabata G, Takeda M, et al. Posterior approach for retroperitoneal laparoscopic bilateral native nephrectomy in prone position: initial experience with four cases. Int J Urol. 2007 Oct;14(10):975-7. doi: 10.1111/j.1442-2042.2007.01864.x. PMID: 17880307.L1: X-3

398. Colacurci N, De Franciscis P, Mollo A, et al. Small-diameter hysteroscopy with Versapoint versus resectoscopy with a unipolar knife for the treatment of septate uterus: a prospective randomized study. J Minim Invasive Gynecol. 2007 Sep-Oct;14(5):622-7. doi: 10.1016/j.jmig.2007.04.010. PMID: 17848325.L1: X-3, X-4, X-5

399. Hemal AK, Kumar A, Gupta NP, et al. Oncologic outcome of 132 cases of laparoscopic radical nephrectomy with intact specimen removal for T1-2N0M0 renal cell carcinoma. World J Urol. 2007 Dec;25(6):619-26. doi: 10.1007/s00345-007-0210-7. PMID: 17786453.L1: X-3

400. Rossetti A, Sizzi O, Chiarotti F, et al. Developments in techniques for laparoscopic myomectomy. Jsls. 2007 Jan-Mar;11(1):34-40. PMID: 17651554.L1: X-4, X-5

401. Hiraoka Y, Shimizu Y, Iwamoto K, et al. Trial of complete detachment of the whole prostate lobes in benign prostate hyperplasia by transurethral enucleation of the prostate. Urol Int. 2007;79(1):50-4. doi: 10.1159/000102914. PMID: 17627169.L1: X-2, X-3

402. Erian J, Hassan M, Hill N. Electromechanical morcellation in laparoscopic subtotal hysterectomy. Int J Gynaecol Obstet. 2007 Oct;99(1):67-8. doi: 10.1016/j.ijgo.2007.04.014. PMID: 17588576.L1: X-5

403. Kietpeerakool C, Srisomboon J, Suprasert P, et al. Routine prophylactic application of Monsel's solution after loop electrosurgical excision procedure of the cervix: is it necessary? J Obstet Gynaecol Res. 2007 Jun;33(3):299-304. doi: 10.1111/j.1447-0756.2007.00528.x. PMID: 17578359.L1: X-3, X-4, X-5

404. Lansdale N, Marven S, Welch J, et al. Intra-abdominal splenosis following laparoscopic splenectomy causing recurrence in a child with chronic immune thrombocytopenic purpura. J Laparoendosc Adv Surg Tech A. 2007 Jun;17(3):387-90. doi: 10.1089/lap.2006.0156. PMID: 17570795.L1: X-2, X-3, X-5

405. Strawbridge LC, Crouch NS, Cutner AS, et al. Obstructive mullerian anomalies and modern laparoscopic management. J Pediatr Adolesc Gynecol. 2007 Jun;20(3):195-200. doi: 10.1016/j.jpag.2006.08.003. PMID: 17561190.L1: X-2, X-3, X-5

406. Elzayat EA, Elhilali MM. Holmium laser enucleation of the prostate (HoLEP): long-term results, reoperation rate, and possible impact of the learning curve. Eur Urol. 2007 Nov;52(5):1465-71. doi: 10.1016/j.eururo.2007.04.074. PMID: 17498867.L1: X-2, X-3

407. Thoma V, Salvatores M, Mereu L, et al. [Laparoscopic hysterectomy: technique, indications]. Ann Urol (Paris). 2007 Apr;41(2):80-90. PMID: 17486915.L1: X-1

408. Sjoborg KD, Vistad I, Myhr SS, et al. Pregnancy outcome after cervical cone excision: a case-control study. Acta Obstet Gynecol Scand. 2007;86(4):423-8. doi: 10.1080/11038120701208158. PMID: 17486463.L1: X-3, X-4, X-5

409. Nohr B, Tabor A, Frederiksen K, et al. Loop electrosurgical excision of the cervix and the subsequent risk of preterm delivery. Acta Obstet Gynecol Scand. 2007;86(5):596-603. doi: 10.1080/00016340701279145. PMID: 17464590.L1: X-3, X-4, X-5

410. Chen C. Laparoscopic myomectomy for large myomas. Int Surg. 2006 Sep-Oct;91(5 Suppl):S77-80. PMID: 17436607.L1: X-5

411. Janetschek G. [Radical and partial nephrectomy for RCC: laparoscopy or open surgery]. Urologe A. 2007 May;46(5):496-503. doi: 10.1007/s00120-007-1335-4. PMID: 17435990.L1: X-1, X-2, X-3

412. Shah HN, Mahajan AP, Hegde SS, et al. Peri-operative complications of holmium laser enucleation of the prostate: experience in the first 280 patients, and a review of literature. BJU Int. 2007 Jul;100(1):94-101. doi: 10.1111/j.1464-410X.2007.06867.x. PMID: 17419697.L1: X-2, X-3

413. Shah HN, Mahajan AP, Sodha HS, et al. Prospective evaluation of the learning curve for holmium laser enucleation of the prostate. J Urol. 2007 Apr;177(4):1468-74. doi: 10.1016/j.juro.2006.11.091. PMID: 17382757.L1: X-2, X-3

414. Brucker S, Solomayer E, Zubke W, et al. A newly developed morcellator creates a new dimension in minimally invasive surgery. J Minim Invasive Gynecol. 2007 Mar-Apr;14(2):233-9. doi: 10.1016/j.jmig.2006.10.004. PMID: 17368263.L1: X-5

415. Donnez O, Squifflet J, Leconte I, et al. Posthysterectomy pelvic adenomyotic masses observed in 8 cases out of a series of 1405 laparoscopic subtotal hysterectomies. J Minim Invasive Gynecol. 2007 Mar-Apr;14(2):156-60. doi: 10.1016/j.jmig.2006.09.008. PMID: 17368249.L1: X-5

416. Seki N, Tatsugami K, Naito S. Holmium laser enucleation of the prostate: comparison of outcomes according to prostate size in 97 Japanese patients. J Endourol. 2007 Feb;21(2):192-6. doi: 10.1089/end.2006.0123. PMID: 17338621.L1: X-2, X-3

417. Tisdale BE, Kapoor A, Hussain A, et al. Intact specimen extraction in laparoscopic nephrectomy procedures: Pfannenstiel versus expanded port site incisions. Urology. 2007 Feb;69(2):241-4. doi: 10.1016/j.urology.2006.09.061. PMID: 17320656.L1: X-2, X-3

418. Sadler L, Saftlas A. Cervical surgery and preterm birth. J Perinat Med. 2007;35(1):5-9. doi: 10.1515/jpm.2007.001. PMID: 17313304.L1: X-1

419. Lee CL, Huang KG, Wang CJ, et al. Laparoscopic radical hysterectomy using pulsed bipolar system: comparison with conventional bipolar electrosurgery. Gynecol Oncol. 2007 Jun;105(3):620-4. doi: 10.1016/j.ygyno.2007.01.029. PMID: 17303226.L1: X-2, X-3, X-4, X-5

420. Binsaleh S, Luke PP, Nguan C, et al. Comparison of laparoscopic and open nephrectomy for adult polycystic kidney disease: operative challenges and technique. Can J Urol. 2006 Dec;13(6):3340-5. PMID: 17187698.L1: X-3

421. Mahmood A, Silbergleit A. The utilization of a morcellator during laparoscopic sleeve gastrectomy. Technol Health Care. 2006;14(6):537-9. PMID: 17148866.L1: X-1, X-3, X-5

422. Gyang A, Mirando S. Haematometra following large loop excision of the transformation zone. J Obstet Gynaecol. 2006 Nov;26(8):835. doi: 10.1080/01443610600994882. PMID: 17130059.L1: X-3

423. Wittich AC. Transvaginal hysterectomy for enlarged leiomyomata uteri in a Medical Department Activity environment. Mil Med. 2006 Sep;171(9):838-40. PMID: 17036602.L1: X-5

424. Gilling PJ, Fraundorfer MR. Holmium laser prostatectomy: a technique in evolution. Curr Opin Urol. 1998 Jan;8(1):11-5. PMID: 17035836.L1: X-1, X-2, X-3

425. Malzoni M, Sizzi O, Rossetti A, et al. Laparoscopic myomectomy: a report of 982 procedures. Surg Technol Int. 2006;15:123-9. PMID: 17029172.L1: INCLUDE L2: X-5

426. Hilger WS, Magrina JF. Removal of pelvic leiomyomata and endometriosis five years after supracervical hysterectomy. Obstet Gynecol. 2006 Sep;108(3 Pt 2):772-4. doi: 10.1097/01.AOG.0000209187.90019.d3. PMID: 17018497.L1: X-3, X-5

427. Donnez O, Jadoul P, Squifflet J, et al. Iatrogenic peritoneal adenomyoma after laparoscopic subtotal hysterectomy and uterine morcellation. Fertil Steril. 2006 Nov;86(5):1511-2. doi: 10.1016/j.fertnstert.2006.06.009. PMID: 16996511.L1: X-3, X-5

428. Kaouk JH, Gill IS. Laparoscopic radical nephrectomy: morcellate or leave intact? Leave intact. Rev Urol. 2002 Winter;4(1):38-42. PMID: 16985651.L1: X-1, X-2, X-3

429. Bishoff JT. Laparoscopic radical nephrectomy: morcellate or leave intact? Definitely morcellate! Rev Urol. 2002 Winter;4(1):34-7. PMID: 16985650.L1: X-1, X-3

430. Wang CJ, Yuen LT, Lee CL, et al. A prospective comparison of morcellator and culdotomy for extracting of uterine myomas laparoscopically in nullipara. J Minim Invasive Gynecol. 2006 Sep-Oct;13(5):463-6. doi: 10.1016/j.jmig.2006.05.005. PMID: 16962533.L1: X-5

431. Carminati R, Ragusa A, Giannice R, et al. Anterior and posterior vaginal myomectomy: a new surgical technique. MedGenMed. 2006;8(1):42. PMID: 16915172.L1: X-5

432. Duarte RJ, Denes FT, Cristofani LM, et al. Further experience with laparoscopic nephrectomy for Wilms' tumour after chemotherapy. BJU Int. 2006 Jul;98(1):155-9. doi: 10.1111/j.1464-410X.2006.06214.x. PMID: 16831161.L1: X-3

433. Greenberg JA, Miner JD, O'Horo SK. Uterine artery embolization and hysteroscopic resection to treat retained placenta accreta: A case report. J Minim Invasive Gynecol. 2006 Jul-Aug;13(4):342-4. doi: 10.1016/j.jmig.2006.04.008. PMID: 16825079.L1: X-1, X-3

434. Camargo AH, Rubenstein JN, Ershoff BD, et al. The effect of kidney morcellation on operative time, incision complications, and postoperative analgesia after laparoscopic nephrectomy. Int Braz J Urol. 2006 May-Jun;32(3):273-9; discussion 9-80. PMID: 16813669.L1: X-3

435. Eguchi D, Nishizaki T, Ohta M, et al. Laparoscopy-assisted right hepatic lobectomy using a wall-lifting procedure. Surg Endosc. 2006 Aug;20(8):1326-8. doi: 10.1007/s00464-005-0723-3. PMID: 16763923.L1: X-3, X-4, X-5

436. Kietpeerakool C, Srisomboon J, Khobjai A, et al. Complications of loop electrosurgical excision procedure for cervical neoplasia: a prospective study. J Med Assoc Thai. 2006 May;89(5):583-7. PMID: 16756040.L1: X-3, X-4, X-5

437. . Safe techniques for abdominal access and wound closure in laparoscopic surgery. Minim Invasive Ther Allied Technol. 2001 Jan;10(1):41-6. doi: 10.1080/13645700152598905. PMID: 16753989.L1: X-5

438. Lieng M, Istre O, Busund B, et al. Severe complications caused by retained tissue in laparoscopic supracervical hysterectomy. J Minim Invasive Gynecol. 2006 May-Jun;13(3):231-3. doi: 10.1016/j.jmig.2006.01.006. PMID: 16698531.L1: INCLUDE L2: X-3, X-3a, X-4, X-5

439. Bojahr B, Raatz D, Schonleber G, et al. Perioperative complication rate in 1706 patients after a standardized laparoscopic supracervical hysterectomy technique. J Minim Invasive Gynecol. 2006 May-Jun;13(3):183-9. doi: 10.1016/j.jmig.2006.01.010. PMID: 16698522.L1: X-5

440. Suh-Burgmann B, Kinney W. On maintaining the balance. J Low Genit Tract Dis. 2006 Apr;10(2):109-10. doi: 10.1097/01.lgt.0000210129.93392.2c. PMID: 16633241.L1: X-1

441. Paul PG, Koshy AK. Multiple peritoneal parasitic myomas after laparoscopic myomectomy and morcellation. Fertil Steril. 2006 Feb;85(2):492-3. doi: 10.1016/j.fertnstert.2005.10.017. PMID: 16595233.L1: X-3, X-5

442. Elzayat E, Habib E, Elhilali M. Holmium laser enucleation of the prostate in patients on anticoagulant therapy or with bleeding disorders. J Urol. 2006 Apr;175(4):1428-32. doi: 10.1016/s0022-5347(05)00645-2. PMID: 16516015.L1: X-2, X-3

443. Nadler RB, Loeb S, Clemens JQ, et al. A prospective study of laparoscopic radical nephrectomy for T1 tumors--is transperitoneal, retroperitoneal or hand assisted the best approach? J Urol. 2006 Apr;175(4):1230-3; discussion 4. doi: 10.1016/s0022-5347(05)00686-5. PMID: 16515966.L1: X-3

444. Szymanski LM, Little R, Matthews DC, et al. Post-loop electrosurgical excision procedure sepsis in a human immunodeficiency virus-infected woman. Obstet Gynecol. 2006 Feb;107(2 Pt 2):496-8. doi: 10.1097/01.aog.0000171107.88468.29. PMID: 16449162.L1: X-2, X-3, X-4, X-5

445. Whitten MG, Van der Werf W, Belnap L. A novel approach to bilateral hand-assisted laparoscopic nephrectomy for autosomal dominant polycystic kidney disease. Surg Endosc. 2006 Apr;20(4):679-84. doi: 10.1007/s00464-005-0229-z. PMID: 16432653.L1: X-2, X-3

446. Elzayat EA, Elhilali MM. Holmium laser enucleation of the prostate (HoLEP): the endourologic alternative to open prostatectomy. Eur Urol. 2006 Jan;49(1):87-91. doi: 10.1016/j.eururo.2005.08.015. PMID: 16314033.L1: X-2, X-3

447. Sagiv R, Ben-Shem E, Condrea A, et al. Endometrial carcinoma after endometrial resection for dysfunctional uterine bleeding. Obstet Gynecol. 2005 Nov;106(5 Pt 2):1174-6. doi: 10.1097/01.AOG.0000160484.20261.fd. PMID: 16260560.L1: X-3, X-4, X-5

448. Neppe C, Land R, Obermair A. Wrigley forceps to deliver a bulky uterus following a total laparoscopic hysterectomy for endometrial cancer. Aust N Z J Obstet Gynaecol. 2005 Oct;45(5):444-5. doi: 10.1111/j.1479-828X.2005.00460.x. PMID: 16171485.L1: X-2, X-3, X-4, X-5

449. Vilos GA, Abu-Rafea B. New developments in ambulatory hysteroscopic surgery. Best Pract Res Clin Obstet Gynaecol. 2005 Aug;19(5):727-42. doi: 10.1016/j.bpobgyn.2005.06.012. PMID: 16126460.L1: X-1

450. Erian J, El-Toukhy T, Chandakas S, et al. One hundred cases of laparoscopic subtotal hysterectomy using the PK and Lap Loop systems. J Minim Invasive Gynecol. 2005 Jul-Aug;12(4):365-9. doi: 10.1016/j.jmig.2005.05.007. PMID: 16036200.L1: X-2, X-5

451. Kim SC, Matlaga BR, Kuo RL, et al. Holmium laser enucleation of the prostate: a comparison of efficiency measures at two institutions. J Endourol. 2005 Jun;19(5):555-8. doi: 10.1089/end.2005.19.555. PMID: 15989444.L1: X-2, X-3

452. Sinha R, Hegde A, Warty N, et al. Laparoscopic myomectomy: enucleation of the myoma by morcellation while it is attached to the uterus. J Minim Invasive Gynecol. 2005 May-Jun;12(3):284-9. doi: 10.1016/j.jmig.2005.03.018. PMID: 15922988.L1: X-5

453. Glasser MH. Minilaparotomy myomectomy: a minimally invasive alternative for the large fibroid uterus. J Minim Invasive Gynecol. 2005 May-Jun;12(3):275-83. doi: 10.1016/j.jmig.2005.03.009. PMID: 15922987.L1: X-4, X-5

454. LaCoursiere DY, Kennedy J, Hoffman CP. Retained fragments after total laparoscopic hysterectomy. J Minim Invasive Gynecol. 2005 Jan-Feb;12(1):67-9. doi: 10.1016/j.jmig.2004.12.021. PMID: 15904602.L1: INCLUDE L2: X-3, X-3a, X-4, X-5

455. Emanuel MH, Wamsteker K. The Intra Uterine Morcellator: a new hysteroscopic operating technique to remove intrauterine polyps and myomas. J Minim Invasive Gynecol. 2005 Jan-Feb;12(1):62-6. doi: 10.1016/j.jmig.2004.12.011. PMID: 15904601.L1: X-5

456. Rekha W, Amita M, Sudeep G, et al. Unexpected complication of uterine myoma morcellation. Aust N Z J Obstet Gynaecol. 2005 Jun;45(3):248-9. doi: 10.1111/j.1479-828X.2005.00397.x. PMID: 15904454.L1: X-3

457. Cohen DD, Matin SF, Steinberg JR, et al. Evaluation of the intact specimen after laparoscopic radical nephrectomy for clinically localized renal cell carcinoma identifies a subset of patients at increased risk for recurrence. J Urol. 2005 May;173(5):1487-90; discussion 90-1. doi: 10.1097/01.ju.0000154634.17485.7a. PMID: 15821465.L1: X-3

458. Varkarakis I, Rha K, Hernandez F, et al. Laparoscopic specimen extraction: morcellation. BJU Int. 2005 Mar;95 Suppl 2:27-31. PMID: 15759350.L1: X-2, X-3, X-5

459. Baughman SM, Bishoff JT. Novel direct-vision renal morcellation with orthopedic rotary shaver-blade instrumentation. J Endourol. 2005 Jan-Feb;19(1):86-9. doi: 10.1089/end.2005.19.86. PMID: 15735391.L1: X-2, X-3, X-5

460. Roberts WW, Bhayani SB, Allaf ME, et al. Pathological stage does not alter the prognosis for renal lesions determined to be stage T1 by computerized tomography. J Urol. 2005 Mar;173(3):713-5. doi: 10.1097/01.ju.0000153638.15018.58. PMID: 15711249.L1: X-3, X-4, X-5

461. Samson SL, Bentley JR, Fahey TJ, et al. The effect of loop electrosurgical excision procedure on future pregnancy outcome. Obstet Gynecol. 2005 Feb;105(2):325-32. doi: 10.1097/01.AOG.0000151991.09124.bb. PMID: 15684160.L1: X-3, X-4, X-5

462. Gauruder-Burmester A, Kroncke TJ, Vorwerks D, et al. [Current state of uterine artery embolization for treating symptomatic leiomyomas of the uterus]. Zentralbl Gynakol. 2004 Dec;126(6):355-8. doi: 10.1055/s-2004-832375. PMID: 15570549.L1: X-1

463. Seelig MH, Senninger N, Kocher T. [Laparoscopic splenectomy: first experiences with a 3-trocar-technique and the 'hanging-spleen-maneuver']. Zentralbl Chir. 2004 Oct;129(5):387-90. doi: 10.1055/s-2004-820359. PMID: 15486790.L1: X-2, X-3, X-5

464. Valdivia Uria JG, Sanchez Zalabardo JM, Regojo Zapata O, et al. [Laparoscopic nephroureterectomy for upper urinary tract urothelial tumors]. Arch Esp Urol. 2004 Apr;57(3):319-24. PMID: 15176373.L1: X-3, X-5

465. Sadler L, Saftlas A, Wang W, et al. Treatment for cervical intraepithelial neoplasia and risk of preterm delivery. Jama. 2004 May 5;291(17):2100-6. doi: 10.1001/jama.291.17.2100. PMID: 15126438.L1: X-3, X-4, X-5

466. Morrison JE, Jr., Jacobs VR. Replacement of expensive, disposable instruments with old-fashioned surgical techniques for improved cost-effectiveness in laparoscopic hysterectomy. Jsls. 2004 Apr-Jun;8(2):201-6. PMID: 15119671.L1: X-5

467. Indman PD. Factors affecting capacitive current diversion with a uterine resectoscope: an in vitro study. J Am Assoc Gynecol Laparosc. 2004 Feb;11(1):128; author reply -9. PMID: 15104850.L1: X-2, X-4, X-5

468. Sinha RY, Hegde A, Warty N, et al. Laparoscopic devascularization of uterine myomata followed by enucleation of the myomas by direct morcellation. J Am Assoc Gynecol Laparosc. 2004 Feb;11(1):99-102. PMID: 15104844.L1: X-3, X-5

469. Li Z, Leng J, Lang J, et al. Vaginal hysterectomy for patients with moderately enlarged uterus of benign lesions. Chin Med Sci J. 2004 Mar;19(1):60-3. PMID: 15104228.L1: X-2, X-5

470. Varkarakis JM, McAllister M, Ong AM, et al. Evaluation of water jet morcellation as an alternative to hand morcellation of renal tissue ablation during laparoscopic nephrectomy: an in vitro study. Urology. 2004 Apr;63(4):796-9. doi: 10.1016/j.urology.2003.10.067. PMID: 15072914.L1: X-2, X-3

471. Decenzo JA. Iatrogenic endometriosis caused by uterine morcellation during a supracervical hysterectomy. Obstet Gynecol. 2004 Mar;103(3):583; author reply -4. PMID: 15024758.L1: X-1

472. Vavassori I, Hurle R, Vismara A, et al. Holmium laser enucleation of the prostate combined with mechanical morcellation: two years of experience with 196 patients. J Endourol. 2004 Feb;18(1):109-12. doi: 10.1089/089277904322836767. PMID: 15006063.L1: X-2, X-3

473. Brown RL. Iatrogenic endometriosis caused by uterine morcellation during a supracervical hysterectomy. Obstet Gynecol. 2004 Mar;103(3):583; author reply -4. PMID: 14990425.L1: X-1

474. Duan H, Liang YJ, Li L, et al. [Research on repairing patterns and factors causing subsequent surgery after trancervical resection of endometrium]. Zhonghua Fu Chan Ke Za Zhi. 2003 Dec;38(12):741-4. PMID: 14728845.L1: X-2, X-3, X-4, X-5

475. Taylor SM, Romero AA, Kammerer-Doak DN, et al. Abdominal hysterectomy for the enlarged myomatous uterus compared with vaginal hysterectomy with morcellation. Am J Obstet Gynecol. 2003 Dec;189(6):1579-82; discussion 82-3. PMID: 14710071.INCLUDE X-5

476. Bornstein J, Harroch J, Morad E. Traction suture of the cervix: a novel procedure with loop electrosurgical excision. Obstet Gynecol. 2003 Nov;102(5 Pt 1):1063-5. PMID: 14672488.L1: X-2, X-3, X-4, X-5

477. Crane JM. Pregnancy outcome after loop electrosurgical excision procedure: a systematic review. Obstet Gynecol. 2003 Nov;102(5 Pt 1):1058-62. PMID: 14672487.L1: X-1, X-3

478. Nazah I, Robin F, Jais JP, et al. Comparison between bisection/morcellation and myometrial coring for reducing large uteri during vaginal hysterectomy or laparoscopically assisted vaginal hysterectomy: results of a randomized prospective study. Acta Obstet Gynecol Scand. 2003 Nov;82(11):1037-42. PMID: 14616278.L1: X-5

479. Sepilian V, Della Badia C. Iatrogenic endometriosis caused by uterine morcellation during a supracervical hysterectomy. Obstet Gynecol. 2003 Nov;102(5 Pt 2):1125-7. PMID: 14607029.L1: X-3, X-5

480. Darwish A. Modified hysteroscopic myomectomy of large submucous fibroids. Gynecol Obstet Invest. 2003;56(4):192-6. doi: 74451. PMID: 14576470.L1: X-5

481. Milad MP, Sokol E. Laparoscopic morcellator-related injuries. J Am Assoc Gynecol Laparosc. 2003 Aug;10(3):383-5. PMID: 14567817.L1: X-1

482. Blanc B. [Uterine morcellation during vaginal hysterectomy: apropos of a series of 216 prospective cases. B. Deval et al. Gynecol Obtet Fertil 2002; 30:850-5]. Gynecol Obstet Fertil. 2003 May;31(5):491-2. PMID: 14567133.L1: X-1

483. Landman J, Venkatesh R, Kibel A, et al. Modified renal morcellation for renal cell carcinoma: laboratory experience and early clinical application. Urology. 2003 Oct;62(4):632-4; discussion 5. PMID: 14550431.L1: X-2, X-3, X-5

484. Seki N, Mochida O, Kinukawa N, et al. Holmium laser enucleation for prostatic adenoma: analysis of learning curve over the course of 70 consecutive cases. J Urol. 2003 Nov;170(5):1847-50. doi: 10.1097/01.ju.0000092035.16351.9d. PMID: 14532790.L1: X-2, X-3

485. Tan AH, Gilling PJ, Kennett KM, et al. A randomized trial comparing holmium laser enucleation of the prostate with transurethral resection of the prostate for the treatment of bladder outlet obstruction secondary to benign prostatic hyperplasia in large glands (40 to 200 grams). J Urol. 2003 Oct;170(4 Pt 1):1270-4. doi: 10.1097/01.ju.0000086948.55973.00. PMID: 14501739.L1: X-2, X-3

486. Xia SJ, Zhu J, Lu J, et al. [The treatment of benign prostatic hyperplasia by means of transurethral holmium laser enucleation]. Zhonghua Nan Ke Xue. 2003;9(4):257-9. PMID: 12931364.L1: X-2, X-3

487. Bartmann CP, Stief B, Schoon HA. [Thermal injury and wound healing of the endometrium subsequent to minimally invasive transendoscopic use of Nd:YAG-laser-and electrosurgery in horses]. Dtsch Tierarztl Wochenschr. 2003 Jul;110(7):271-80. PMID: 12910864.L1: X-1, X-2, X-3, X-4, X-5

488. Xia EL, Duan H, Zhang J, et al. [Analysis of 16 cases of uterine perforation during hysteroscopic electro-surgeries]. Zhonghua Fu Chan Ke Za Zhi. 2003 May;38(5):280-3. PMID: 12895311.L1: X-2, X-5

489. Takeuchi H, Kuwatsuru R. The indications, surgical techniques, and limitations of laparoscopic myomectomy. Jsls. 2003 Apr-Jun;7(2):89-95. PMID: 12856836.L1: X-5

490. Deval B, Rafii A, Soriano D, et al. Morbidity of vaginal hysterectomy for benign tumors as a function of uterine weight. J Reprod Med. 2003 Jun;48(6):435-40. PMID: 12856514.L1: X-5

491. Hernandez F, Rha KH, Pinto PA, et al. Laparoscopic nephrectomy: assessment of morcellation versus intact specimen extraction on postoperative status. J Urol. 2003 Aug;170(2 Pt 1):412-5. doi: 10.1097/01.ju.0000076667.70020.82. PMID: 12853788.L1: X-3

492. Kuo RL, Paterson RF, Siqueira TM, Jr., et al. Holmium laser enucleation of the prostate: morbidity in a series of 206 patients. Urology. 2003 Jul;62(1):59-63. PMID: 12837423.L1: X-2, X-3

493. Kuo RL, Paterson RF, Kim SC, et al. Holmium Laser Enucleation of the Prostate (HoLEP): A Technical Update. World J Surg Oncol. 2003 Jun 6;1(1):6. doi: 10.1186/1477-7819-1-6. PMID: 12818001.L1: X-1, X-2, X-3

494. Meng MV, Koppie TM, Stoller ML. Pathologic sampling of laparoscopically morcellated kidneys: a mathematical model. J Endourol. 2003 May;17(4):229-33. doi: 10.1089/089277903765444366. PMID: 12816586.L1: X-1, X-3

495. Cai Y, Jacobson A, Marcovich R, et al. Electrical prostate morcellator: an alternative to manual morcellation for laparoscopic nephrectomy specimens? An in vitro study. Urology. 2003 Jun;61(6):1113-7; discussion 7. PMID: 12809874.L1: X-1, X-2, X-3

496. Kuo RL, Kim SC, Lingeman JE, et al. Holmium laser enucleation of prostate (HoLEP): the Methodist Hospital experience with greater than 75 gram enucleations. J Urol. 2003 Jul;170(1):149-52. doi: 10.1097/01.ju.0000070686.56806.a1. PMID: 12796668.L1: X-2, X-3

497. User HM, Nadler RB. Novel technique of renal entrapment for morcellation. J Urol. 2003 Jun;169(6):2287-8. doi: 10.1097/01.ju.0000062544.91372.90. PMID: 12771772.L1: X-2, X-3

498. Walsh RM, Chand B, Brodsky J, et al. Determination of intact splenic weight based on morcellated weight. Surg Endosc. 2003 Aug;17(8):1266-8. doi: 10.1007/s00464-001-8223-6. PMID: 12748847.L1: X-2, X-3

499. McCausland VM, McCausland AM. Previous tubal ligation is a risk factor for hysterectomy after rollerball endometrial ablation. Obstet Gynecol. 2003 Apr;101(4):818-9; author reply 9. PMID: 12681901.L1: X-1, X-3, X-4

500. Tuma J, Krafka K, Kopecna L. [Laparoscopic surgery of the spleen in children]. Rozhl Chir. 2002 Dec;81(12):641-4. PMID: 12666480.L1: X-2, X-3, X-5

501. Signorile PG. Laparoscopic-ultraminilaparotomic myomectomy (LUM)-laparoscopic-ultraminilaparotomic embolized myomectomy (LUEM). Surgical techniques. Clin Exp Obstet Gynecol. 2002;29(4):277-80. PMID: 12635745.L1: X-5

502. Borrazzo EC, Daly JM, Morrisey KP, et al. Hand-assisted laparoscopic splenectomy for giant spleens. Surg Endosc. 2003 Jun;17(6):918-20. doi: 10.1007/s00464-002-8946-z. PMID: 12632136.L1: X-2, X-3, X-5

503. Tsivian A, Sidi AA. Port site metastases in urological laparoscopic surgery. J Urol. 2003 Apr;169(4):1213-8. doi: 10.1097/01.ju.0000035910.75480.4b. PMID: 12629331.L1: X-1, X-2

504. League DD. Endometrial ablation as an alternative to hysterectomy. Aorn j. 2003 Feb;77(2):322-4, 7-38; quiz 41, 43-4. PMID: 12619849.L1: X-1

505. Nannapaneni P, Naik R, de Barros Lopes A, et al. Intra-abdominal bleed following LLETZ. J Obstet Gynaecol. 2002 Jan;22(1):99-100. PMID: 12521750.L1: X-2, X-3, X-4, X-5

506. Dronov AF, Poddubnyi VI, Smirnov AN, et al. [Laparoscopic splenectomy in congenital hemolytic anemia in children]. Khirurgiia (Mosk). 2002(11):14-8. PMID: 12501457.L1: X-2, X-3, X-5

507. Benassi L, Rossi T, Kaihura CT, et al. Abdominal or vaginal hysterectomy for enlarged uteri: a randomized clinical trial. Am J Obstet Gynecol. 2002 Dec;187(6):1561-5. PMID: 12501064.L1: X-5

508. Meng MV, Miller TR, Cha I, et al. Cytology of morcellated renal specimens: significance in diagnosis and dissemination. J Urol. 2003 Jan;169(1):45-8. doi: 10.1097/01.ju.0000035542.89566.a8. PMID: 12478099.L1: X-2, X-3, X-5

509. Deval B, Rafii A, Samain E, et al. [Uterine morcellation during vaginal hysterectomy: apropos of a series of 216 prospective cases]. Gynecol Obstet Fertil. 2002 Nov;30(11):850-5. PMID: 12476689.L1: X-5

510. Rosen M, Brody F, Walsh RM, et al. Hand-assisted laparoscopic splenectomy vs conventional laparoscopic splenectomy in cases of splenomegaly. Arch Surg. 2002 Dec;137(12):1348-52. PMID: 12470097.L1: X-2, X-3, X-5

511. Ou CS, Harper A, Liu YH, et al. Laparoscopic myomectomy technique. Use of colpotomy and the harmonic scalpel. J Reprod Med. 2002 Oct;47(10):849-53. PMID: 12418070.L1: X-5

512. Brun JL, Youbi A, Hocke C. [Complications, sequellae and outcome of cervical conizations: evaluation of three surgical technics]. J Gynecol Obstet Biol Reprod (Paris). 2002 Oct;31(6):558-64. PMID: 12407327.L1: X-2, X-3, X-4, X-5

513. Hochreiter WW, Thalmann GN, Burkhard FC, et al. Holmium laser enucleation of the prostate combined with electrocautery resection: the mushroom technique. J Urol. 2002 Oct;168(4 Pt 1):1470-4. doi: 10.1097/01.ju.0000025336.31206.25. PMID: 12352420.L1: X-2, X-3

514. Hurle R, Vavassori I, Piccinelli A, et al. Holmium laser enucleation of the prostate combined with mechanical morcellation in 155 patients with benign prostatic hyperplasia. Urology. 2002 Sep;60(3):449-53. PMID: 12350482.L1: X-2, X-3

515. Tagaya N, Rokkaku K, Kubota K. Splenectomy using a completely needlescopic procedure: report of three cases. J Laparoendosc Adv Surg Tech A. 2002 Jun;12(3):213-6. doi: 10.1089/10926420260188137. PMID: 12184909.L1: X-2, X-3

516. Tan AH, Gilling PJ. Holmium laser prostatectomy: current techniques. Urology. 2002 Jul;60(1):152-6. PMID: 12100945.L1: X-1, X-2, X-3

517. Matin SF, Gill IS. Laparoscopic radical nephrectomy: retroperitoneal versus transperitoneal approach. Curr Urol Rep. 2002 Apr;3(2):164-71. PMID: 12084210.L1: X-1

518. Hettiarachchi JA, Samadi AA, Konno S, et al. Holmium laser enucleation for large (greater than 100 mL) prostate glands. Int J Urol. 2002 May;9(5):233-6. PMID: 12060433.L1: X-2, X-3

519. Paraskevaidis E, Davidson EJ, Koliopoulos G, et al. Bleeding after loop electrosurgical excision procedure performed in either the follicular or luteal phase of the menstrual cycle: a randomized trial. Obstet Gynecol. 2002 Jun;99(6):997-1000. PMID: 12052589.L1: X-2, X-3, X-4, X-5

520. Nadu A, Hoznek A, Salomon L, et al. Laparoscopic retroperitoneal nephrectomy for Aspergillus-infected polycystic kidney. J Endourol. 2002 May;16(4):237-40. doi: 10.1089/089277902753752205. PMID: 12042107.L1: X-2, X-3

521. Pautler SE, Hewitt SM, Linehan WM, et al. Specimen morcellation after laparoscopic radical nephrectomy: confirmation of histologic diagnosis using needle biopsy. J Endourol. 2002 Mar;16(2):89-92. doi: 10.1089/089277902753619573. PMID: 11962561.L1: X-3

522. Wattiez A, Soriano D, Fiaccavento A, et al. Total laparoscopic hysterectomy for very enlarged uteri. J Am Assoc Gynecol Laparosc. 2002 May;9(2):125-30. PMID: 11960035.L1: X-5

523. Nelson CP, Wolf JS, Jr. Comparison of hand assisted versus standard laparoscopic radical nephrectomy for suspected renal cell carcinoma. J Urol. 2002 May;167(5):1989-94. PMID: 11956425.L1: X-3

524. Pautler SE, Harrington FS, McWilliams GW, et al. A novel laparoscopic specimen entrapment device to facilitate morcellation of large renal tumors. Urology. 2002 Apr;59(4):591-3. PMID: 11927323.L1: X-2, X-3, X-5

525. Kercher KW, Matthews BD, Walsh RM, et al. Laparoscopic splenectomy for massive splenomegaly. Am J Surg. 2002 Feb;183(2):192-6. PMID: 11918887.L1: X-2, X-3, X-5

526. Gettman MT, Napper C, Corwin TS, et al. Laparoscopic radical nephrectomy: prospective assessment of impact of intact versus fragmented specimen removal on postoperative quality of life. J Endourol. 2002 Feb;16(1):23-6. doi: 10.1089/089277902753483673. PMID: 11890445.L1: X-3

527. Sundaram CP, Ono Y, Landman J, et al. Hydrophilic guide wire technique to facilitate organ entrapment using a laparoscopic sack during laparoscopy. J Urol. 2002 Mar;167(3):1376-7. PMID: 11832736.L1: X-2, X-3

528. Dietrich CS, 3rd, Yancey MK, Miyazawa K, et al. Risk factors for early cytologic abnormalities after loop electrosurgical excision procedure. Obstet Gynecol. 2002 Feb;99(2):188-92. PMID: 11814494.L1: X-2, X-3, X-4, X-5

529. Canis M, Mage G, Botchorishvili R, et al. [Laparoscopy and gynecologic cancer: is it still necessary to debate or only convince the incredulous?]. Gynecol Obstet Fertil. 2001 Dec;29(12):913-8. PMID: 11802556.L1: X-1

530. Seidman DS, Nezhat CH, Nezhat F, et al. The role of laparoscopic-assisted myomectomy (LAM). Jsls. 2001 Oct-Dec;5(4):299-303. PMID: 11719974.L1: X-1, X-5

531. Meng MV, Koppie TM, Duh QY, et al. Novel method of assessing surgical margin status in laparoscopic specimens. Urology. 2001 Nov;58(5):677-81. PMID: 11711335.L1: X-2, X-3, X-5

532. Shekarriz B, Meng MV, Lu HF, et al. Laparoscopic nephrectomy for inflammatory renal conditions. J Urol. 2001 Dec;166(6):2091-4. PMID: 11696713.L1: X-3

533. Rabban JT, Meng MV, Yeh B, et al. Kidney morcellation in laparoscopic nephrectomy for tumor: recommendations for specimen sampling and pathologic tumor staging. Am J Surg Pathol. 2001 Sep;25(9):1158-66. PMID: 11688575.L1: X-3

534. Gouin F, Bertrand-Vasseur A, Collet T, et al. [Subfascial lipomatous tumors: management in a series of 37 consecutive cases]. Rev Chir Orthop Reparatrice Appar Mot. 2001 Oct;87(6):585-95. PMID: 11685150.L1: X-2, X-3, X-5

535. Greene AK, Hodin RA. Laparoscopic splenectomy for massive splenomegaly using a Lahey bag. Am J Surg. 2001 Jun;181(6):543-6. PMID: 11513782.L1: X-3, X-5

536. Kanaoka Y, Hirai K, Ishiko O, et al. An intranodal morcellation technique employing loop electrosurgical excision procedure for large prolapsed pedunculated myomas. Oncol Rep. 2001 Sep-Oct;8(5):1149-51. PMID: 11496333.L1: X-3, X-5

537. Miller CE. Methods of tissue extraction in advanced laparoscopy. Curr Opin Obstet Gynecol. 2001 Aug;13(4):399-405. PMID: 11452202.L1: X-1

538. Doucette RC, Sharp HT, Alder SC. Challenging generally accepted contraindications to vaginal hysterectomy. Am J Obstet Gynecol. 2001 Jun;184(7):1386-9; discussion 90-1. PMID: 11408857.L1: X-5

539. Yang Y, Tan X, Li P. [Clinical observation of hysteroscopic electric resection: an analysis of 36 patients with abnormal uterine bleeding]. Zhonghua Fu Chan Ke Za Zhi. 1999 Aug;34(8):482-4. PMID: 11360600.L1: X-4, X-5

540. Duan H, Xia E, Liang Y. [Study on the electrothermal tissue effects during transcervical resection of endometrium]. Zhonghua Fu Chan Ke Za Zhi. 1999 Aug;34(8):479-81. PMID: 11360599.L1: X-2, X-3, X-4, X-5

541. Liu Z, Lang J, Sun D. [Vaginal hysterectomy for large uterus]. Zhonghua Fu Chan Ke Za Zhi. 1999 Aug;34(8):456-8. PMID: 11360591.L1: X-5

542. Lu Y, Zhang S, Liu X. [Clinical study on transvaginal hysterectomy for moderate enlarged uterus]. Zhonghua Fu Chan Ke Za Zhi. 1999 Aug;34(8):453-5. PMID: 11360590.L1: X-5

543. Heniford BT, Matthews BD, Answini GA, et al. Laparoscopic splenectomy for malignant diseases. Semin Laparosc Surg. 2000 Jun;7(2):93-100. PMID: 11320480.L1: X-1, X-2, X-3, X-5

544. Jarrett TW, Chan DY, Cadeddu JA, et al. Laparoscopic nephroureterectomy for the treatment of transitional cell carcinoma of the upper urinary tract. Urology. 2001 Mar;57(3):448-53. PMID: 11248618.L1: X-2, X-3

545. Walsh RM, Heniford BT, Brody F, et al. The ascendance of laparoscopic splenectomy. Am Surg. 2001 Jan;67(1):48-53. PMID: 11206897.L1: X-2, X-3, X-5

546. Shubina TA, Lyutova LV, Karabasova MA, et al. Coagulation and fibrinolysis in rats after surgery with monopolar electrical scalpel. Bull Exp Biol Med. 2000 Sep;130(9):917-20. PMID: 11177281.L1: X-2, X-3, X-4, X-5

547. Moody JA, Lingeman JE. Holmium laser enucleation for prostate adenoma greater than 100 gm.: comparison to open prostatectomy. J Urol. 2001 Feb;165(2):459-62. doi: 10.1097/00005392-200102000-00025. PMID: 11176396.L1: X-2, X-3

548. van Wijngaarden WJ, Filshie GM. Laparoscopic supracervical hysterectomy with Filshie clips. J Am Assoc Gynecol Laparosc. 2001 Feb;8(1):137-42. PMID: 11172129.L1: X-3, X-5

549. Althuisius SM, Schornagel IJ, Dekker GA, et al. Loop electrosurgical excision procedure of the cervix and time of delivery in subsequent pregnancy. Int J Gynaecol Obstet. 2001 Jan;72(1):31-4. PMID: 11146074.L1: X-2, X-3, X-4, X-5

550. Gill IS. Laparoscopic radical nephrectomy for cancer. Urol Clin North Am. 2000 Nov;27(4):707-19. PMID: 11098769.L1: X-3

551. Hirai K, Kanaoka Y, Ishiko O, et al. A novel technique for myomectomy. Intranodal surgery with an electromechanical tissue borer. J Reprod Med. 2000 Oct;45(10):813-6. PMID: 11077629.L1: X-5

552. Landman J, Lento P, Hassen W, et al. Feasibility of pathological evaluation of morcellated kidneys after radical nephrectomy. J Urol. 2000 Dec;164(6):2086-9. PMID: 11061932.L1: X-2, X-3

553. Suh-Burgmann EJ, Whall-Strojwas D, Chang Y, et al. Risk factors for cervical stenosis after loop electrocautery excision procedure. Obstet Gynecol. 2000 Nov;96(5 Pt 1):657-60. PMID: 11042296.L1: X-2, X-3, X-4, X-5

554. Hasson HM, Rotman C, Rana N. The morcellator knife: a new laparoscopic instrument for supracervical hysterectomy and morcellation. Obstet Gynecol. 2000 Oct;96(4):644. PMID: 11041771.L1: X-1

555. Landman J, Collyer WC, Olweny E, et al. Laparoscopic renal ablation: an in vitro comparison of currently available electrical tissue morcellators. Urology. 2000 Oct 1;56(4):677-81. PMID: 11018638.L1: X-2, X-3

556. Grosdemouge I, Bleret-Mattart V, von Theobald P, et al. [Complications of vaginal hysterectomy on non-prolapsed uterus]. J Gynecol Obstet Biol Reprod (Paris). 2000 Sep;29(5):478-84. PMID: 11011277.L1: X-5

557. Dunn MD, Portis AJ, Shalhav AL, et al. Laparoscopic versus open radical nephrectomy: a 9-year experience. J Urol. 2000 Oct;164(4):1153-9. PMID: 10992356.L1: X-3

558. Fentie DD, Barrett PH, Taranger LA. Metastatic renal cell cancer after laparoscopic radical nephrectomy: long-term follow-up. J Endourol. 2000 Jun;14(5):407-11. PMID: 10958561.L1: X-3

559. Gilling PJ, Kennett KM, Fraundorfer MR. Holmium laser enucleation of the prostate for glands larger than 100 g: an endourologic alternative to open prostatectomy. J Endourol. 2000 Aug;14(6):529-31. PMID: 10954311.L1: X-2, X-3

560. De Grandi P, Chardonnens E, Gerber S. The morcellator knife: a new laparoscopic instrument for supracervical hysterectomy and morcellation. Obstet Gynecol. 2000 May;95(5):777-8. PMID: 10841695.L1: X-5

561. Kresch A. Clinical outcomes of OPERA, out-patient endometrial resection/ablation. Prim Care Update Ob Gyns. 1998 Jul 1;5(4):205. PMID: 10838390.L1: X-5

562. Caprotti R, Franciosi C, Romano F, et al. Combined laparoscopic splenectomy and cholecystectomy for the treatment of hereditary spherocytosis: is it safe and effective? Surg Laparosc Endosc Percutan Tech. 1999 Jun;9(3):203-6. PMID: 10804001.L1: X-2, X-3

563. Hillemanns P, Kimmig R, Dannecker C, et al. [LEEP versus cold knife conization for treatment of cervical intraepithelial neoplasias]. Zentralbl Gynakol. 2000;122(1):35-42. PMID: 10785949.L1: X-3, X-4

564. Moody JA, Lingeman JE. Holmium laser enucleation of the prostate with tissue morcellation: initial United States experience. J Endourol. 2000 Mar;14(2):219-23. PMID: 10772518.L1: X-2, X-3

565. Parekh AR, Moran ME, Newkirk RE, et al. Tissue removal utilizing Steiner Morcellator within a LapSac: effects of a fluid-filled environment. J Endourol. 2000 Mar;14(2):185-9. PMID: 10772513.L1: X-2, X-3, X-5

566. Dunn MD, Portis AJ, Elbahnasy AM, et al. Laparoscopic nephrectomy in patients with end-stage renal disease and autosomal dominant polycystic kidney disease. Am J Kidney Dis. 2000 Apr;35(4):720-5. PMID: 10739795.L1: X-3

567. Mizoguchi H, Ohno H, Emoto A, et al. [Laparoscopic radical nephrectomy for renal cell carcinoma--transperitoneal anterior approach]. Nihon Hinyokika Gakkai Zasshi. 1999 Dec;90(12):906-10. PMID: 10658462.L1: X-3

568. Raders JL. Dispersive pad injuries associated with hysteroscopic surgery. J Am Assoc Gynecol Laparosc. 1999 Aug;6(3):363-7. PMID: 10610207.L1: X-3, X-4, X-5

569. Dodson MK, Sharp HT. Uses and abuses of the loop electrosurgical excision procedure (LEEP). Clin Obstet Gynecol. 1999 Dec;42(4):916-21. PMID: 10572704.L1: X-3, X-4, X-5

570. Colgan TJ, Shah R, Leyland N. Post-hysteroscopic ablation reaction: a histopathologic study of the effects of electrosurgical ablation. Int J Gynecol Pathol. 1999 Oct;18(4):325-31. PMID: 10542940.L1: X-2, X-3, X-4, X-5

571. Tsin DA, Colombero LT. Laparoscopic leash: a simple technique to prevent specimen loss during operative laparoscopy. Obstet Gynecol. 1999 Oct;94(4):628-9. PMID: 10511371.L1: X-5

572. Kuzel D, Fucikova Z, Cibula D, et al. [Rational laparoscopic intervention in laparoscopically-assisted vaginal hysterectomy (LAVH): prospective study]. Ceska Gynekol. 1999 Apr;64(2):96-9. PMID: 10510549.L1: X-5

573. Figueiredo O, Figueiredo EG, Figueiredo PG, et al. Vaginal removal of the benign nonprolapsed uterus: experience with 300 consecutive operations. Obstet Gynecol. 1999 Sep;94(3):348-51. PMID: 10472857.L1: X-5

574. Pawel Siekierski B, Tyminska A, Sikora S, et al. [LEEP in gynecologic practice]. Przegl Lek. 1999;56(1):68-71. PMID: 10375931.L1: X-1, X-3

575. Hashizume M, Tanoue K, Akahoshi T, et al. Laparoscopic splenectomy: the latest modern technique. Hepatogastroenterology. 1999 Mar-Apr;46(26):820-4. PMID: 10370620.L1: X-2, X-3, X-5

576. Unger JB. Vaginal hysterectomy for the woman with a moderately enlarged uterus weighing 200 to 700 grams. Am J Obstet Gynecol. 1999 Jun;180(6 Pt 1):1337-44. PMID: 10368468.L1: X-5

577. Hemal AK, Gupta NP, Wadhwa SN. Modified minimal cost retroperitoneoscopic nephrectomy, nephrectomy with isthumusectomy and nephroureterectomy in children: a pilot study. BJU Int. 1999 May;83(7):823-7. PMID: 10368206.L1: X-3

578. Das A, Fraundorfer M, Gilling P. The holmium laser for the treatment of benign prostatic hyperplasia: a brief review. Lasers Med Sci. 1999 Jun;14(2):86-90. doi: 10.1007/s101030050027. PMID: 24519161.L1: X-1, X-2, X-3

579. Walther MM, Lyne JC, Libutti SK, et al. Laparoscopic cytoreductive nephrectomy as preparation for administration of systemic interleukin-2 in the treatment of metastatic renal cell carcinoma: a pilot study. Urology. 1999 Mar;53(3):496-501. PMID: 10096373.L1: X-3

580. Walsh RM, Heniford BT. Laparoscopic splenectomy for non-Hodgkin lymphoma. J Surg Oncol. 1999 Feb;70(2):116-21. PMID: 10084655.L1: X-2, X-3, X-5

581. Shwayder JM. Laparoscopically assisted vaginal hysterectomy. Obstet Gynecol Clin North Am. 1999 Mar;26(1):169-87. PMID: 10083937.L1: X-1

582. Wood C, Maher P. Endoscopic treatment of uterine fibroids. Baillieres Clin Obstet Gynaecol. 1998 Jun;12(2):289-316. PMID: 10023423.L1: X-1

583. Le Duc A, Gilling PJ. Holmium laser resection of the prostate. Eur Urol. 1999 Feb;35(2):155-60. doi: 19836. PMID: 9933809.L1: X-2, X-3

584. Switala I, Cosson M, Lanvin D, et al. [Is vaginal hysterectomy important for large uterus of more than 500 g? Comparison with laparotomy]. J Gynecol Obstet Biol Reprod (Paris). 1998 Oct;27(6):585-92. PMID: 9854221.L1: X-5

585. Gilling PJ, Kennett K, Das AK, et al. Holmium laser enucleation of the prostate (HoLEP) combined with transurethral tissue morcellation: an update on the early clinical experience. J Endourol. 1998 Oct;12(5):457-9. PMID: 9847070.L1: X-2, X-3

586. Hebra A, Walker JD, Tagge EP, et al. A new technique for laparoscopic splenectomy with massively enlarged spleens. Am Surg. 1998 Dec;64(12):1161-4. PMID: 9843336.L1: X-2, X-3

587. Mitchell MF, Tortolero-Luna G, Cook E, et al. A randomized clinical trial of cryotherapy, laser vaporization, and loop electrosurgical excision for treatment of squamous intraepithelial lesions of the cervix. Obstet Gynecol. 1998 Nov;92(5):737-44. PMID: 9794661.L1: X-2, X-3, X-5

588. Bojahr B, Romer T, Straube W. Laparoscopic removal of a 5-cm subserous pedunculated myoma with small instruments. J Am Assoc Gynecol Laparosc. 1998 Nov;5(4):435-8. PMID: 9782152.L1: X-3, X-5

589. Kresch AJ, Longacre T, Feste JR, et al. Initial experience with a physiologic morcellating resectoscope. J Am Assoc Gynecol Laparosc. 1998 Nov;5(4):419-21. PMID: 9782148.L1: X-2, X-5

590. Barrett PH, Fentie DD, Taranger LA. Laparoscopic radical nephrectomy with morcellation for renal cell carcinoma: the Saskatoon experience. Urology. 1998 Jul;52(1):23-8. PMID: 9671864.L1: X-3

591. Hutchins FL, Jr., Reinoehl EM. Retained myoma after laparoscopic supracervical hysterectomy with morcellation. J Am Assoc Gynecol Laparosc. 1998 Aug;5(3):293-5. PMID: 9668153.L1: X-3, X-5

592. Shalhav AL, Leibovitch I, Lev R, et al. Is laparoscopic radical nephrectomy with specimen morcellation acceptable cancer surgery? J Endourol. 1998 Jun;12(3):255-7. PMID: 9658297.L1: X-1, X-3

593. Hashizume M, Migo S, Tsugawa K, et al. Laparoscopic splenectomy with the newly devised morcellator. Hepatogastroenterology. 1998 Mar-Apr;45(20):554-7. PMID: 9638450.L1: X-2, X-3, X-5

594. Pelosi MA, Pelosi MA, 3rd. Should uterine size alone require laparoscopic assistance? Vaginal hysterectomy for a 2003-g uterus. J Laparoendosc Adv Surg Tech A. 1998 Apr;8(2):99-103. PMID: 9617971.L1: X-3, X-5

595. Kresch AJ, Lyons TL, Westland AB, et al. Laparoscopic supracervical hysterectomy with a new disposable morcellator. J Am Assoc Gynecol Laparosc. 1998 May;5(2):203-6. PMID: 9564073.L1: X-5

596. Bannenberg JJ, Garibiyan H, Vijverberg P, et al. Initial experiences with the retroperitoneal approach for endoscopic nephrectomy with the patient in the prone position. J Laparoendosc Adv Surg Tech A. 1998 Feb;8(1):25-32. PMID: 9533803.L1: X-1, X-3

597. Pandya S, Sanders LE. Use of a Foley catheter in the removal of a substernal goiter. Am J Surg. 1998 Feb;175(2):155-7. doi: 10.1016/s0002-9610(97)00267-5. PMID: 9515535.L1: X-2, X-3, X-4, X-5

598. Doss BJ, Jacques SM, Qureshi F, et al. Extratubal secondary trophoblastic implants: clinicopathologic correlation and review of the literature. Hum Pathol. 1998 Feb;29(2):184-7. PMID: 9490280.L1: X-2, X-3, X-5

599. Fraundorfer MR, Gilling PJ. Holmium:YAG laser enucleation of the prostate combined with mechanical morcellation: preliminary results. Eur Urol. 1998;33(1):69-72. PMID: 9471043.L1: X-2, X-3

600. Nageli J, Lange J. [Indications, technique and outcome of laparoscopic splenectomy]. Ther Umsch. 1997 Sep;54(9):510-4. PMID: 9411842.L1: X-1, X-2, X-3

601. Pelosi MA, 3rd, Pelosi MA. The Pryor technique of uterine morcellation. Int J Gynaecol Obstet. 1997 Sep;58(3):299-303. PMID: 9286864.L1: X-5

602. Schneider A. Recurrence of unclassifiable uterine cancer after modified laparoscopic hysterectomy with morcellation. Am J Obstet Gynecol. 1997 Aug;177(2):478-9. PMID: 9290479.L1: X-3, X-5

603. Elashry OM, Giusti G, Nadler RB, et al. Incisional hernia after laparoscopic nephrectomy with intact specimen removal: caveat emptor. J Urol. 1997 Aug;158(2):363-9. PMID: 9224304.L1: X-3

604. Pelosi MA, 3rd, Pelosi MA. The suprapubic cruciate incision for laparoscopic-assisted microceliotomy. Jsls. 1997 Jul-Sep;1(3):269-72. PMID: 9876686.L1: X-5

605. Carter JE, McCarus SD. Laparoscopic myomectomy. Time and cost analysis of power vs. manual morcellation. J Reprod Med. 1997 Jul;42(7):383-8. PMID: 9252927.L1: X-5

606. Luque Mialdea R, Martin-Crespo Izquierdo R, Navascues del Rio JA, et al. [Retroperitoneal laparoscopic nephrectomy in children]. Actas Urol Esp. 1997 Jun;21(6):637-9. PMID: 9412202.L1: X-1, X-3

607. Newkirk GR. Office procedures. Electrosurgical loop excision of the cervix. Prim Care. 1997 Jun;24(2):281-302. PMID: 9174040.L1: X-2, X-3, X-5

608. Amy JJ. Vaginal hysterectomy. Natl Med J India. 1997 May-Jun;10(3):126-7. PMID: 9230602.L1: X-5

609. Pelosi MA, 3rd, Pelosi MA. Transvaginal uterine morcellation with unsuspected adenocarcinoma of the endometrium. Int J Gynaecol Obstet. 1997 May;57(2):207-8. PMID: 9184967.L1: X-3, X-5

610. Canis M, Pouly JL, Wattiez A, et al. Laparoscopic management of adnexal masses suspicious at ultrasound. Obstet Gynecol. 1997 May;89(5 Pt 1):679-83. PMID: 9166300.L1: X-2, X-3, X-5

611. Suzuki K, Fujita K. [Laparoscopic surgery for renal carcinomas]. Gan To Kagaku Ryoho. 1997 Mar;24(5):544-50. PMID: 9087285.L1: X-1, X-3

612. Baldauf JJ, Dreyfus M, Wertz JP, et al. [Consequences and treatment of cervical stenoses after laser conization or loop electrosurgical excision]. J Gynecol Obstet Biol Reprod (Paris). 1997;26(1):64-70. PMID: 9091546.L1: X-2, X-3, X-5

613. Baldauf JJ, Dreyfus M, Ritter J, et al. Risk of cervical stenosis after large loop excision or laser conization. Obstet Gynecol. 1996 Dec;88(6):933-8. doi: 10.1016/s0029-7844(96)00331-6. PMID: 8942830.L1: X-2, X-3, X-5

614. Machac J, Hegerova I. [Personal experience with laparoscopic hysterectomy]. Ceska Gynekol. 1996 Oct;61(5):287-90. PMID: 9004973.L1: X-5

615. Kammerer-Doak D, Mao J. Vaginal hysterectomy with and without morcellation: the University of New Mexico hospital's experience. Obstet Gynecol. 1996 Oct;88(4 Pt 1):560-3. PMID: 8841218.L1: X-5

616. Whittaker MD, Garry R. Patient Satisfaction with Laparoscopic-Assisted Removal of Large Myomas. J Am Assoc Gynecol Laparosc. 1996 Aug;3(4, Supplement):S55. PMID: 9074265.L1: X-5

617. Carter JE, McCarus S, Baginiski L, et al. Laparoscopic Outpatient Treatment of Large Myomas. J Am Assoc Gynecol Laparosc. 1996 Aug;3(4, Supplement):S6. PMID: 9074091.L1: X-5

618. Carter JE, McCarus S. Time Savings Using the Steiner Morcellator in Laparoscopic Myomectomy. J Am Assoc Gynecol Laparosc. 1996 Aug;3(4, Supplement):S6. PMID: 9074090.L1: X-5

619. Adamian LV, Kulakov VV, Kiselev SI, et al. Laparoscopic Myomectomy in Treatment of Large Myomas. J Am Assoc Gynecol Laparosc. 1996 Aug;3(4, Supplement):S1. PMID: 9074071.L1: X-5

620. Fitzgerald PG, Langer JC, Cameron BH, et al. Pediatric laparoscopic splenectomy using the lateral approach. Surg Endosc. 1996 Aug;10(8):859-61. PMID: 8694957.L1: X-2, X-3, X-5

621. Andrei B. Myomectomy by pelvicoscopy. Int Surg. 1996 Jul-Sep;81(3):271-5. PMID: 9028988.L1: X-5

622. Thomas PA, Zaleski MS, Ohlhausen WW, et al. Cytomorphologic characteristics of thermal injury related to endocervical brushing following loop electrosurgical excision procedure (LEEP). Diagn Cytopathol. 1996 May;14(3):212-5. doi: 10.1002/(sici)1097-0339(199604)14:3<212::aid-dc3>3.0.co;2-j. PMID: 8829894.L1: X-3, X-4

623. Terrosu G, Donini A, Silvestri F, et al. Laparoscopic splenectomy in the management of hematological diseases. Surgical technique and outcome of 17 patients. Surg Endosc. 1996 Apr;10(4):441-4. PMID: 8661800.L1: X-2, X-3, X-5

624. Chiu WT, Chen SY, Lin JW, et al. Color-Doppler Ultrasound-assisted endoscopic neurosurgery for intracerebral hemorrhage. Zhonghua Yi Xue Za Zhi (Taipei). 1996 Mar;57(3):198-203. PMID: 8935226.L1: X-2, X-3, X-4, X-5

625. Valla JS, Guilloneau B, Montupet P, et al. Retroperitoneal laparoscopic nephrectomy in children: preliminary report of six cases. J Laparoendosc Surg. 1996 Mar;6 Suppl 1:S55-9. PMID: 8832929.L1: X-1, X-3

626. Dubuisson JB, Chapron C. Uterine fibroids: place and modalities of laparoscopic treatment. Eur J Obstet Gynecol Reprod Biol. 1996 Mar;65(1):91-4. PMID: 8706965.L1: X-5

627. Ferris DG, Hainer BL, Pfenninger JL, et al. 'See and treat' electrosurgical loop excision of the cervical transformation zone. J Fam Pract. 1996 Mar;42(3):253-7. PMID: 8636676.L1: X-2, X-3, X-4, X-5

628. Magos A, Bournas N, Sinha R, et al. Vaginal hysterectomy for the large uterus. Br J Obstet Gynaecol. 1996 Mar;103(3):246-51. PMID: 8630309.L1: X-5

629. Wood C, Maher P. New strategies for treating myomas. Diagn Ther Endosc. 1996;2(3):129-34. doi: 10.1155/dte.2.129. PMID: 18493393.L1: X-5

630. Semm K. Tissue morcellation in endoscopic surgery. Surg Technol Int. 1996;5:175-8. PMID: 15858737.L1: X-1

631. Kinukawa T, Hattori R, Ono Y, et al. [Laparoscopic radical nephrectomy. Analysis of 10 cases and preliminary report of retroperitoneal approach]. Nihon Hinyokika Gakkai Zasshi. 1995 Nov;86(11):1625-30. PMID: 8551704.L1: X-3

632. Suzuki K, Masuda H, Ushiyama T, et al. Gasless laparoscopy-assisted nephrectomy without tissue morcellation for renal carcinoma. J Urol. 1995 Nov;154(5):1685-7. PMID: 7563322.L1: X-3

633. Ferris DG, Hainer BL, Pfenninger JL, et al. Electrosurgical loop excision of the cervical transformation zone: the experience of family physicians. J Fam Pract. 1995 Oct;41(4):337-44. PMID: 7561706.L1: X-2, X-3, X-4, X-5

634. Prendiville W. Large loop excision of the transformation zone. Clin Obstet Gynecol. 1995 Sep;38(3):622-39. PMID: 8612372.L1: X-2, X-3, X-4, X-5

635. Goldrath MH. Hysteroscopic endometrial ablation. Obstet Gynecol Clin North Am. 1995 Sep;22(3):559-72. PMID: 8524537.L1: X-4, X-5

636. Lang JF, Childers JM, Surwit EA. Laparoscopic hysterectomy for persistent gestational trophoblastic neoplasia. J Am Assoc Gynecol Laparosc. 1995 Aug;2(4):475-7. PMID: 9050606.L1: X-2, X-3, X-4, X-5

637. Emmermann A, Zornig C, Peiper M, et al. Laparoscopic splenectomy. Technique and results in a series of 27 cases. Surg Endosc. 1995 Aug;9(8):924-7. PMID: 8525451.L1: X-2, X-3, X-5

638. Mazdisnian F, Kurzel RB, Coe S, et al. Vaginal hysterectomy by uterine morcellation: an efficient, non-morbid procedure. Obstet Gynecol. 1995 Jul;86(1):60-4. doi: 10.1016/0029-7844(95)00086-7. PMID: 7784024.L1: X-5

639. Bratschi HU, Heiz B. [Total pelviscopic removal of ovarian tumors in a bag bag posterior colpotomy]. Geburtshilfe Frauenheilkd. 1995 Jul;55(7):383-6. doi: 10.1055/s-2007-1022806. PMID: 7557204.L1: X-1, X-2, X-3, X-5

640. Mecke H, Wallas F, Brocker A, et al. [Pelviscopic myoma enucleation: technique, limits, complications]. Geburtshilfe Frauenheilkd. 1995 Jul;55(7):374-9. doi: 10.1055/s-2007-1022804. PMID: 7557202.L1: X-5

641. Herzog TJ, Williams S, Adler LM, et al. Potential of cervical electrosurgical excision procedure for diagnosis and treatment of cervical intraepithelial neoplasia. Gynecol Oncol. 1995 Jun;57(3):286-93. doi: 10.1006/gyno.1995.1144. PMID: 7774831.L1: X-2, X-3, X-4, X-5

642. Machac J, Hegerova I, Mosler P. [Use of a morcellator in supracervical laparotomy extirpation of the uterus]. Ceska Gynekol. 1995 Jun;60(3):158-9. PMID: 7670709.L1: X-1, X-5

643. Redwine DB. Laparoscopic hysterectomy compared with abdominal and vaginal hysterectomy in a community hospital. J Am Assoc Gynecol Laparosc. 1995 May;2(3):305-10. PMID: 9050574.L1: X-4, X-5

644. Munro MG, Fu YS. Loop electrosurgical excision with a laparoscopic electrode and carbon dioxide laser vaporization: comparison of thermal injury characteristics in the rat uterine horn. Am J Obstet Gynecol. 1995 Apr;172(4 Pt 1):1257-62. PMID: 7726266.L1: X-2, X-3, X-5

645. Ferenczy A, Choukroun D, Falcone T, et al. The effect of cervical loop electrosurgical excision on subsequent pregnancy outcome: North American experience. Am J Obstet Gynecol. 1995 Apr;172(4 Pt 1):1246-50. PMID: 7726264.L1: X-2, X-3, X-4, X-5

646. Mettler L, Semm K, Lehmann-Willenbrock L, et al. Comparative evaluation of classical intrafascial-supracervical hysterectomy (CISH) with transuterine mucosal resection as performed by pelviscopy and laparotomy--our first 200 cases. Surg Endosc. 1995 Apr;9(4):418-23. PMID: 7660267.L1: X-5

647. Phillips DR, Nathanson HG, Meltzer SM, et al. Transcervical electrosurgical resection of submucous leiomyomas for chronic menorrhagia. J Am Assoc Gynecol Laparosc. 1995 Feb;2(2):147-53. PMID: 9050549.L1: X-5

648. Wright TC, Jr., Richart RM. Loop excision of the uterine cervix. Curr Opin Obstet Gynecol. 1995 Feb;7(1):30-4. PMID: 7742512.L1: X-1, X-3

649. Lehmann-Willenbrock E, Semm K, Luttges J, et al. Sonographic and Histological Morphometry of the Uterine Cervix-An Assessment of Laparoscopic and Other lntrafascial Hysterectomy Techniques. Diagn Ther Endosc. 1995;2(2):71-7. doi: 10.1155/dte.2.71. PMID: 18493385.L1: X-2, X-3, X-5

650. Semm K, Lehmann-Willenbrock E, Mettler L. Laparoscopic and other intrafascial hysterectomy techniques or mucosal ablation-a choice for maximum organ conservation. Diagn Ther Endosc. 1995;2(2):61-70. doi: 10.1155/dte.2.61. PMID: 18493384.L1: X-2, X-5

651. Mettler L, Alvarez-Rodas E, Semm K. Hormonal treatment and pelviscopic myomectomy. Diagn Ther Endosc. 1995;1(4):217-21. doi: 10.1155/dte.1.217. PMID: 18493368.L1: X-5

652. Mettler L, Alvarez-Rodas E, Lehmann-Willenbrock E, et al. Intrafascial supracervical hysterectomy without colpotomy and transuterine mucosal resection by pelviscopy and laparotomy. Diagn Ther Endosc. 1995;1(4):201-7. doi: 10.1155/dte.1.201. PMID: 18493366.L1: INCLUDE L2: X-5

653. Rullo S, Boni T, Silvestrini I, et al. How safe is hysteroscopic surgery? Our experience in the first 78 cases. Clin Exp Obstet Gynecol. 1995;22(4):285-8. PMID: 8777780.L1: X-2, X-5

654. Kolmorgen K. [Laparoscopic myomectomy]. Zentralbl Gynakol. 1995;117(12):659-62. PMID: 8585361.L1: INCLUDE L2: X-5

655. Resnick DK, Pollack IF, Albright AL. Surgical management of the cloverleaf skull deformity. Pediatr Neurosurg. 1995;22(1):29-37; discussion 238. PMID: 7888390.L1: X-2, X-3, X-5

656. Grunberger W. [Laparoscopic interventions in gynecology]. Wien Klin Wochenschr. 1995;107(2):77-82. PMID: 7879398.L1: X-1

657. Montagna S, Zacche G. [Endometrial ablation with the resectoscope. The authors' experience]. Minerva Ginecol. 1995 Jan-Feb;47(1-2):17-21. PMID: 7770144.L1: X-2, X-3, X-4, X-5

658. Lewis PL, Lashgari M. A comparison of cold knife, CO2 laser, and electrosurgical loop conization in the treatment of cervical intraepithelial neoplasia. J Gynecol Surg. 1994 Winter;10(4):229-34. PMID: 10150434.L1: X-2, X-3, X-4, X-5

659. Girardi F, Heydarfadai M, Koroschetz F, et al. Cold-knife conization versus loop excision: histopathologic and clinical results of a randomized trial. Gynecol Oncol. 1994 Dec;55(3 Pt 1):368-70. doi: 10.1006/gyno.1994.1308. PMID: 7835776.L1: X-2, X-3, X-4, X-5

660. Rosales Delgado JA, Gonzalez-Sicilia Cotter E, Gonzalez Vergara R, et al. [Morcellation laparoscopic hysterectomy of the CASH (Classical, Abdominal, Semm, Hysterectomy) type]. Ginecol Obstet Mex. 1994 Dec;62:378-80. PMID: 7835735.L1: X-5

661. Eddy GL, Spiegel GW, Creasman WT. Adverse effect of electrosurgical loop excision on assignment of FIGO stage in cervical cancer: report of two cases. Gynecol Oncol. 1994 Nov;55(2):313-7. doi: 10.1006/gyno.1994.1296. PMID: 7959301.L1: X-2, X-3, X-4, X-5

662. Katoh N, Ono Y, Yamada S, et al. Laparoscopic radical nephrectomy for renal cell carcinoma: early experience. J Endourol. 1994 Oct;8(5):357-9. PMID: 7858623.L1: X-3

663. Cuschieri A, Frank T. Slicer and tissue retrieval system for excisional endoscopic surgery. Surg Endosc. 1994 Oct;8(10):1246-9. PMID: 7809817.L1: X-2, X-3, X-4, X-5

664. Hoffman MS, DeCesare S, Kalter C. Abdominal hysterectomy versus transvaginal morcellation for the removal of enlarged uteri. Am J Obstet Gynecol. 1994 Aug;171(2):309-13; discussion 13-5. PMID: 8059807.L1: X-5

665. Schwartz RO. Laparoscopic hysterectomy. Supracervical vs. assisted vaginal. J Reprod Med. 1994 Aug;39(8):625-30. PMID: 7996527.L1: X-5

666. Smith BM, Schropp KP, Lobe TE, et al. Laparoscopic splenectomy in childhood. J Pediatr Surg. 1994 Aug;29(8):975-7. PMID: 7965532.L1: X-2, X-3, X-5

667. Ferenczy A. Electroconization of the cervix with a fine-needle electrode. Obstet Gynecol. 1994 Jul;84(1):152-9. PMID: 8008313.L1: X-2, X-3, X-4, X-5

668. McLucas B. Premalignant lesions of the cervix. J Reprod Med. 1994 Jul;39(7):514-5. PMID: 7966040.L1: X-1, X-2

669. Chantilis SJ, McQuitty DA, Preminger GM, et al. Laparoscopic removal of gonads containing on occult seminoma in a woman with complete androgen resistance. J Am Assoc Gynecol Laparosc. 1994 May;1(3):277-82. PMID: 9050501.L1: X-2, X-3, X-4, X-5

670. Schlinkert RT, Braich TA. Laparoscopic assisted splenectomy for treatment of presumed immune thrombocytopenic purpura: initial results. Mayo Clin Proc. 1994 May;69(5):422-4. PMID: 8170191.L1: X-2, X-3, X-5

671. McLucas B, McGill J. Pure cutting current for loop excision of squamous intraepithelial lesions. J Reprod Med. 1994 May;39(5):373-6. PMID: 8064704.L1: X-2, X-3, X-4, X-5

672. Lobe TE, Schropp KP, Joyner R, et al. The suitability of automatic tissue morcellation for the endoscopic removal of large specimens in pediatric surgery. J Pediatr Surg. 1994 Feb;29(2):232-4. PMID: 8176598.L1: X-2, X-3, X-5

673. Vietz PF, Ahn TS. A new approach to hysterectomy without colpotomy: pelviscopic intrafascial hysterectomy. Am J Obstet Gynecol. 1994 Feb;170(2):609-13. PMID: 8116722.L1: X-5

674. Suzuki K, Ihara H, Kurita Y, et al. Laparoscopy-assisted radical nephrectomy without pneumoperitoneum. Eur Urol. 1994;25(3):237-41. PMID: 8200407.L1: X-3

675. Nezhat C, Nezhat F, Bess O, et al. Laparoscopically assisted myomectomy: a report of a new technique in 57 cases. Int J Fertil Menopausal Stud. 1994 Jan-Feb;39(1):39-44. PMID: 8167679.L1: X-5

676. Goff BA, Rice LW, Fleischhacker DS, et al. Large loop excision of the transformation zone in patients with exocervical squamous intraepithelial lesions. Eur J Gynaecol Oncol. 1994;15(4):257-62. PMID: 7957331.L1: X-2, X-3, X-4, X-5

677. Kerbl K, Clayman RV, McDougall EM, et al. Laparoscopic nephrectomy. Bmj. 1993 Dec 4;307(6917):1488-9. PMID: 8281096.L1: X-1, X-3

678. Urban DA, Kerbl K, McDougall EM, et al. Organ entrapment and renal morcellation: permeability studies. J Urol. 1993 Dec;150(6):1792-4. PMID: 8230506.L1: X-2, X-3, X-5

679. Semm K. [Intrafascial vaginal hysterectomy (IVH) with or without pelviscopic assistance]. Geburtshilfe Frauenheilkd. 1993 Dec;53(12):873-8. doi: 10.1055/s-2007-1023743. PMID: 8119572.L1: X-1

680. Ono Y, Sahashi M, Yamada S, et al. Laparoscopic nephrectomy without morcellation for renal cell carcinoma: report of initial 2 cases. J Urol. 1993 Oct;150(4):1222-4. PMID: 8371397.L1: X-1, X-3

681. Montagna S, Zacche G. [Endometrial ablation. A review of the technics and results]. Minerva Ginecol. 1993 Sep;45(9):409-17. PMID: 8255501.L1: X-1

682. Michael A. Endometrial ablation and air embolism. Anaesth Intensive Care. 1993 Aug;21(4):475. PMID: 8155120.L1: X-1, X-4, X-5

683. Rosen DJ, Margolin ML, Menashe Y, et al. Toxic shock syndrome after loop electrosurgical excision procedure. Am J Obstet Gynecol. 1993 Jul;169(1):202-4. PMID: 8392792.L1: X-2, X-3, X-4, X-5

684. Oyesanya OA, Amerasinghe C, Manning EA. A comparison between loop diathermy conization and cold-knife conization for management of cervical dysplasia associated with unsatisfactory colposcopy. Gynecol Oncol. 1993 Jul;50(1):84-8. doi: 10.1006/gyno.1993.1168. PMID: 8349168.L1: X-2, X-3, X-4, X-5

685. Pisani E, Zanetti G, Trinchieri A, et al. [Laparoscopic nephrectomy]. Arch Ital Urol Androl. 1993 Jun;65(3):229-30. PMID: 8334441.L1: X-1, X-3

686. Chandhoke PS, Clayman RV, Kerbl K, et al. Laparoscopic ureterectomy: initial clinical experience. J Urol. 1993 May;149(5):992-7. PMID: 8483252.L1: X-2, X-3, X-5

687. Steiner RA, Wight E, Tadir Y, et al. Electrical cutting device for laparoscopic removal of tissue from the abdominal cavity. Obstet Gynecol. 1993 Mar;81(3):471-4. PMID: 8437807.L1: X-5

688. Volz J, Koster S, Potempa D, et al. [Pelviscopic ovarian surgery: a new method of safe organ preserving surgery]. Geburtshilfe Frauenheilkd. 1993 Feb;53(2):132-4. doi: 10.1055/s-2007-1023651. PMID: 8462830.L1: X-2, X-3, X-5

689. Mayeaux EJ, Jr., Harper MB. Loop electrosurgical excisional procedure. J Fam Pract. 1993 Feb;36(2):214-9. PMID: 8426142.L1: X-2, X-3, X-4, X-5

690. Soper NJ, Brunt LM, Fleshman J, Jr., et al. Laparoscopic small bowel resection and anastomosis. Surg Laparosc Endosc. 1993 Feb;3(1):6-12. PMID: 8258075.L1: X-2, X-3

691. Rassweiler JJ, Henkel TO, Potempa DM, et al. The technique of transperitoneal laparoscopic nephrectomy, adrenalectomy and nephroureterectomy. Eur Urol. 1993;23(4):425-30. PMID: 8335045.L1: X-1, X-3

692. Luciano AA, Frishman GN, Maier DB. A comparative analysis of adhesion reduction, tissue effects, and incising characteristics of electrosurgery, CO2 laser, and Nd:YAG laser at operative laparoscopy: an animal study. J Laparoendosc Surg. 1992 Dec;2(6):287-92. PMID: 1489993.L1: X-1, X-2, X-3, X-4, X-5

693. Hasson HM, Rotman C, Rana N, et al. Laparoscopic myomectomy. Obstet Gynecol. 1992 Nov;80(5):884-8. PMID: 1407934.L1: X-5

694. Sullivan B, Kenney P, Seibel M. Hysteroscopic resection of fibroid with thermal injury to sigmoid. Obstet Gynecol. 1992 Sep;80(3 Pt 2):546-7. PMID: 1495733.L1: X-3, X-4, X-5

695. Kopitnik TA, Jr., Kaufman HH. The future. Prospects of innovative treatment of intracerebral hemorrhage. Neurosurg Clin N Am. 1992 Jul;3(3):703-7. PMID: 1633490.L1: X-1, X-2, X-3, X-5

696. Dudley BS. Treatment of cervical intraepithelial neoplasia using the loop electrosurgical excision procedure. Obstet Gynecol. 1992 Jul;80(1):157-8. PMID: 1603489.L1: X-1, X-3

697. Brooks PG. Complications of operative hysteroscopy: how safe is it? Clin Obstet Gynecol. 1992 Jun;35(2):256-61. PMID: 1638818.L1: X-1

698. Higashihara E, Kameyama S, Tanaka Y, et al. [Laparoscopic nephrectomy. Animal experiment and clinical application]. Nihon Hinyokika Gakkai Zasshi. 1992 Mar;83(3):395-400. PMID: 1532999.L1: X-1, X-2, X-3

699. Clayman RV, Kavoussi LR, McDougall EM, et al. Laparoscopic nephrectomy: a review of 16 cases. Surg Laparosc Endosc. 1992 Mar;2(1):29-34. PMID: 1341497.L1: X-3

700. Wright TC, Jr., Richart RM, Ferenczy A, et al. Comparison of specimens removed by CO2 laser conization and the loop electrosurgical excision procedure. Obstet Gynecol. 1992 Jan;79(1):147-53. PMID: 1727574.L1: X-2, X-3, X-4, X-5

701. Reiter RC, Wagner PL, Gambone JC. Routine hysterectomy for large asymptomatic uterine leiomyomata: a reappraisal. Obstet Gynecol 1992 Apr;79(4):481-4. PMID: 1553162. X-5

702. Semm K. [Hysterectomy via laparotomy or pelviscopy. A new CASH method without colpotomy]. Geburtshilfe Frauenheilkd. 1991 Dec;51(12):996-1003. doi: 10.1055/s-2008-1026252. PMID: 1838998.L1: X-1, X-2, X-3, X-4, X-5

703. Clayman RV, Kavoussi LR, Figenshau RS, et al. Laparoscopic nephroureterectomy: initial clinical case report. J Laparoendosc Surg. 1991 Dec;1(6):343-9. PMID: 1838941.L1: X-2, X-3

704. Semm K. [Morcellement and suturing using pelviscopy--not a problem any more]. Geburtshilfe Frauenheilkd. 1991 Oct;51(10):843-6. doi: 10.1055/s-2008-1026221. PMID: 1837003.L1: X-1, X-2, X-5

705. Duffy S, Reid PC, Smith JH, et al. In vitro studies of uterine electrosurgery. Obstet Gynecol. 1991 Aug;78(2):213-20. PMID: 2067765.L1: X-2

706. Clayman RV, Kavoussi LR, Soper NJ, et al. Laparoscopic nephrectomy: initial case report. J Urol. 1991 Aug;146(2):278-82. PMID: 1830346.L1: X-3

707. Hoffman HJ, Reddy KV. Progressive cranial suture stenosis in craniosynostosis. Neurosurg Clin N Am. 1991 Jul;2(3):555-64. PMID: 1821303.L1: X-1, X-2, X-3

708. Gillespie A. Endometrial ablation: a conservative alternative to hysterectomy for menorrhagia? Med J Aust. 1991 Jun 17;154(12):791-2. PMID: 2041502.L1: X-1

709. Brooks PG, Serden SP, Davos I. Hormonal inhibition of the endometrium for resectoscopic endometrial ablation. Am J Obstet Gynecol. 1991 Jun;164(6 Pt 1):1601-6; discussion 6-8. PMID: 1904683.L1: X-2, X-4, X-5

710. Rohatgi M. Cloverleaf skull--a severe form of Crouzon's syndrome: a new concept in aetiology. Acta Neurochir (Wien). 1991;108(1-2):45-52. PMID: 2058426.L1: X-2, X-3, X-4, X-5

711. Hassler W, Zentner J. Radical osteoclastic craniectomy in sagittal synostosis. Neurosurgery. 1990 Oct;27(4):539-43. PMID: 2234355.L1: X-2, X-3

712. Eysler D, Soper R. A modification of operative laparoscopic technique to permit removal of an ectopic pregnancy without morcellation. Am J Obstet Gynecol. 1990 May;162(5):1348. PMID: 2140242.L1: X-2, X-3

713. Matejicek M, Dungl P, Slavik M, et al. [Sprengel's deformity]. Acta Chir Orthop Traumatol Cech. 1990 Feb;57(1):3-14. PMID: 2336905.L1: X-1, X-2, X-3

714. Leibsohn S, d'Ablaing G, Mishell DR, Jr., et al. Leiomyosarcoma in a series of hysterectomies performed for presumed uterine leiomyomas. Am J Obstet Gynecol 1990 Apr;162(4):968-74; discussion 74-6. PMID: 2327466. X-5

715. Prendiville W, Cullimore J, Norman S. Large loop excision of the transformation zone (LLETZ). A new method of management for women with cervical intraepithelial neoplasia. Br J Obstet Gynaecol. 1989 Sep;96(9):1054-60. PMID: 2804007.L1: X-2, X-3, X-5

716. Henderson SR. Ectopic tubal pregnancy treated by operative laparoscopy. Am J Obstet Gynecol. 1989 Jun;160(6):1462-6; discussion 6-9. PMID: 2525338.L1: X-2, X-3, X-4, X-5

717. Shimada H, Nihmoto S, Matsuba A, et al. Primary cholesterol hepatolithiasis. Gastroenterol Jpn. 1989 Apr;24(2):170-6. PMID: 2744333.L1: X-2, X-3, X-5

718. Ortega Moreno J, Uson Gargallo J. [Experimental study of the effects of electromicrosurgical section versus microscissor section in the uterus of rats]. Rev Quir Esp. 1988 Sep-Oct;15(5):242-7. PMID: 3153404.L1: X-2, X-3, X-4, X-5

719. Greene CS, Jr., Winston KR. Treatment of scaphocephaly with sagittal craniectomy and biparietal morcellation. Neurosurgery. 1988 Aug;23(2):196-202. PMID: 3185879.L1: X-2, X-3

720. Hohlweg-Majert P, Kirn R, Mechela A. [Clinical aspects of vaginal hysterectomy]. Geburtshilfe Frauenheilkd. 1987 Dec;47(12):864-7. doi: 10.1055/s-2008-1036063. PMID: 3436509.L1: X-5

721. Siegler AM. Therapeutic hysteroscopy. Acta Eur Fertil. 1986 Nov-Dec;17(6):467-71. PMID: 3630558.L1: X-1

722. Draca P. Vaginal hysterectomy by means of morcellation. Eur J Obstet Gynecol Reprod Biol. 1986 Aug;22(4):237-42. PMID: 3743862.L1: X-5

723. Epstein N, Epstein F, Newman G. Total vertex craniectomy for the treatment of scaphocephaly. Childs Brain. 1982 Sep-Oct;9(5):309-16. PMID: 7128245.L1: X-2, X-3

724. Semm K. Tissue-puncher and loop-ligation--new aids for surgical-therapeutic pelviscopy (laparoscopy) = endoscopic intraabdominal surgery. Endoscopy. 1978 May;10(2):119-24. doi: 10.1055/s-0028-1098278. PMID: 149004.L1: X-1, X-2

725. Mohr G, Hoffman HJ, Munro IR, et al. Surgical management of unilateral and bilateral coronal craniosynostosis: 21 years of experience. Neurosurgery. 1978 Mar-Apr;2(2):83-92. PMID: 366447.L1: X-2, X-3

726. Laskowski A. [Active therapy in cases of cervix erosion following electrosurgery]. Ginekol Pol. 1977 Oct;48(10):875-9. PMID: 924214.L1: X-2, X-3

727. Laskowski A. [Implant endometriosis following electrosurgery of uterine cervix]. Wiad Lek. 1977 Jun 1;30(11):849-52. PMID: 883297.L1: X-2, X-3, X-4, X-5

728. Laskowski A. [Complications following electrosurgical procedures on the cervix uteri]. Pol Tyg Lek. 1976 May 19;31(16):667-9. PMID: 1272963.L1: X-2, X-3, X-4, X-5

729. Higier J, Zielinski J. [Progestagens in the prevention of inoculation endometriosis in the uterine cervix following electrosurgery]. Ginekol Pol. 1973 Mar;44(3):277-81. PMID: 4697775.L1: X-2, X-3, X-4, X-5

730. Pratt JH, Gunnlaugsson GH. Vaginal hysterectomy by morcellation. Mayo Clin Proc. 1970 May;45(5):374-87. PMID: 5443234. L2: X-1, X-5

731. Gauss CJ. [Three new instruments for morcellation of the fetus]. Munch Med Wochenschr. 1951 Mar 9;93(10):472-7. PMID: 14833304.L1: X-2

732. Allen E. Vaginal removal of the uterus by morcellation. Am J Obstet Gynecol. 1949 Apr;57(4):692-700. PMID: 18113698. L2: X-10

733. Benjamin HB, Ahrenberger HW, Fairless CJ. The Submucosal Morcellation of Hemorrhoids. Ann Surg. 1945 Feb;121(2):239-44. PMID: 17858566.L1: X-2, X-3, X-5

734. Durand-Reville M, Dufour P, Vinatier D, et al. [Uterine leiomyosarcomas: a surprising pathology. Review of the literature. Six case reports]. J Gynecol Obstet Biol Reprod (Paris). 1996;25(7):710-5. PMID: 8991905.L1: L2: X-11

735. Mahnert N, Morgan D, Campbell D, et al. Unexpected gynecologic malignancy diagnosed after hysterectomy performed for benign indications. Obstet Gynecol. 2015 Feb;125(2):397-405. doi: 10.1097/aog.0000000000000642. PMID: 25569001. X-5

736. Society of Gynecologic Oncology. SGO Position Statement: Morcellation. December 2013. https://www.sgo.org/newsroom/position-statements-2/morcellation/

737. . Patient safety must be a priority in all aspects of care. Lancet Oncol. 2014 Feb;15(2):123. doi: 10.1016/s1470-2045(14)70042-7. PMID: 24480553.L1: X-1

738. Tirumani SH, Deaver P, Shinagare AB, et al. Metastatic pattern of uterine leiomyosarcoma: retrospective analysis of the predictors and outcome in 113 patients. J Gynecol Oncol. 2014 Oct;25(4):306-12. doi: 10.3802/jgo.2014.25.4.306. PMID: 25142630.L1: X-4, X-5

739. Serrano C, Nucci MR, Tirumani SH, et al. Hormone dependency in metastatic low-grade leiomyosarcoma following uterine smooth muscle tumour of uncertain malignant potential. BMJ Case Rep. 2014;2014doi: 10.1136/bcr-2013-202107. PMID: 24675802.L1: X-2, X-3, X-4, X-5

740. Rauh-Hain JA, Oduyebo T, Diver EJ, et al. Uterine leiomyosarcoma: an updated series. Int J Gynecol Cancer. 2013 Jul;23(6):1036-43. doi: 10.1097/IGC.0b013e31829590dc. PMID: 23714705.L1: INCLUDE L2: X-3, X-3e

741. Rauh-Hain JA, Hinchcliff EM, Oduyebo T, et al. Clinical outcomes of women with recurrent or persistent uterine leiomyosarcoma. Int J Gynecol Cancer. 2014 Oct;24(8):1434-40. doi: 10.1097/igc.0000000000000221. PMID: 25248114.L1: X-2, X-4, X-5

742. Oduyebo T, Hinchcliff E, Meserve EE, et al. Risk Factors for Occult Uterine Sarcoma Among Women Undergoing Minimally Invasive Gynecologic Surgery. J Minim Invasive Gynecol. 2015 Aug 4doi: 10.1016/j.jmig.2015.07.017. PMID: 26253281.L1: INCLUDE L2: X-5

743. Rutstein SE, Siedhoff MT, Geller EJ, et al. Cost-effectiveness of laparoscopic hysterectomy with morcellation compared to abdominal hysterectomy for presumed fibroids. J Minim Invasive Gynecol. 2015 Oct 13doi: 10.1016/j.jmig.2015.09.025. PMID: 26475764.L1: X-1, X-5

744. Mandato VD, Torricelli F, Pirillo D, et al. Impact of the Food and Drug Administration safety communication on the use of power morcellator in daily clinical practice. An Italian survey. J Minim Invasive Gynecol. 2015 Oct 7doi: 10.1016/j.jmig.2015.09.021. PMID: 26454195.L1: X-2

745. Mutch DG. Premature Judgment of Uterine Morcellation: Look at the Data Before You Leap. J Natl Cancer Inst. 2015 Nov;107(11)doi: 10.1093/jnci/djv283. PMID: 26449387.L1: X-1

746. Wright JD, Cui RR, Wang A, et al. Economic and Survival Implications of Use of Electric Power Morcellation for Hysterectomy for Presumed Benign Gynecologic Disease. J Natl Cancer Inst. 2015 Nov;107(11)doi: 10.1093/jnci/djv251. PMID: 26449386.L1: INCLUDE L2: X-1, X-3

747. van den Haak L, Arkenbout EA, Sandberg EM, et al. Power Morcellator Features Affecting Tissue Spill in Gynecological Laparoscopy: An in vitro study. J Minim Invasive Gynecol. 2015 Sep 29doi: 10.1016/j.jmig.2015.09.014. PMID: 26432710.L1: X-2

748. Choo KJ, Lee HJ, Lee TS, et al. Intrapelvic dissemination of early low-grade endometrioid stromal sarcoma due to electronic morcellation. Obstet Gynecol Sci. 2015 Sep;58(5):414-7. doi: 10.5468/ogs.2015.58.5.414. PMID: 26430669.L1: X-3

749. Elshal AM, Mekkawy R, Laymon M, et al. Towards optimizing prostate tissue retrieval following holmium laser enucleation of the prostate (HoLEP): Assessment of two morcellators and review of literature. Can Urol Assoc J. 2015 Sep-Oct;9(9-10):E618-25. doi: 10.5489/cuaj.3035. PMID: 26425224.L1: X-2, X-3

750. Erenel H, Temizkan O, Mathyk BA, et al. Parasitic myoma after laparoscopic surgery: a mini-review. J Turk Ger Gynecol Assoc. 2015;16(3):181-6. doi: 10.5152/jtgga.2015.15242. PMID: 26401114.L1: X-1, X-5

751. Moawad GN, Abi Khal IE, Opoku-Anane J, et al. Comparison of methods of morcellation: manual versus power. Acta Obstet Gynecol Scand. 2015 Sep 24doi: 10.1111/aogs.12783. PMID: 26400045.L1: X-5

752. Cooper NA, Robinson LL, Clark TJ. Ambulatory hysteroscopy and its role in the management of abnormal uterine bleeding. J Fam Plann Reprod Health Care. 2015 Oct;41(4):284-91. doi: 10.1136/jfprhc-2014-100872. PMID: 26399587.L1: X-1

753. Cheung VY, Pun TC. Contained Morcellation for Laparoscopic Myomectomy Within a Specially Designed Bag. J Minim Invasive Gynecol. 2015 Sep 25doi: 10.1016/j.jmig.2015.08.889. PMID: 26391058.L1: X-1

754. Paul PG, Thomas M, Das T, et al. Reply to Letter: Contained Morcellation for Laparoscopic Myomectomy Within a Specially Designed Bag. J Minim Invasive Gynecol. 2015 Sep 21doi: 10.1016/j.jmig.2015.09.007. PMID: 26391056.L1: X-1

755. Hall T, Lee SI, Boruta DM, et al. Medical Device Safety and Surgical Dissemination of Unrecognized Uterine Malignancy: Morcellation in Minimally Invasive Gynecologic Surgery. Oncologist. 2015 Sep 17doi: 10.1634/theoncologist.2015-0061. PMID: 26382742.L1: X-1

756. Cohen SL, Morris SN, Brown DN, et al. Contained Tissue Extraction using Power Morcellation: Prospective Evaluation of Leakage Parameters. Am J Obstet Gynecol. 2015 Sep 5doi: 10.1016/j.ajog.2015.08.076. PMID: 26348384.L1: INCLUDE L2: X-5

757. Winner B, Porter A, Velloze S, et al. Uncontained Compared With Contained Power Morcellation in Total Laparoscopic Hysterectomy. Obstet Gynecol. 2015 Oct;126(4):834-8. doi: 10.1097/aog.0000000000001039. PMID: 26348168.L1: INCLUDE L2: X-5

758. Picerno TM, Wasson MN, Gonzalez Rios AR, et al. Morcellation and the Incidence of Occult Uterine Malignancy: A Dual-Institution Review. Int J Gynecol Cancer. 2015 Sep 1doi: 10.1097/igc.0000000000000558. PMID: 26332395.INCLUDE X-5

759. Gajewska M, Wielgos M, Panek G. Critical analysis of cases of endometrial carcinoma of the uterine corpus incidentally diagnosed after incomplete surgery for other indications. Three case reports and a review of the literature. Prz Menopauzalny. 2014 Oct;13(5):305-9. doi: 10.5114/pm.2014.46469. PMID: 26327871.L1: X-2, X-3, X-5

760. Harris JA, Swenson CW, Uppal S, et al. Practice Patterns and Postoperative Complications Before and After Food and Drug Administration Safety Communication on Power Morcellation. Am J Obstet Gynecol. 2015 Aug 24doi: 10.1016/j.ajog.2015.08.047. PMID: 26314519.L1: X-2, X-5

761. El Tayeb MM, Borofsky MS, Paonessa JE, et al. Wolf Piranha Versus Lumenis Versacut Prostate Morcellation Devices: A Prospective Randomized Trial. J Urol. 2015 Aug 22doi: 10.1016/j.juro.2015.08.078. PMID: 26307163.L1: X-2, X-3

762. Gargiulo AR, Lewis EI, Kaser DJ, et al. Robotic single-site myomectomy: a step-by-step tutorial. Fertil Steril. 2015 Aug 20doi: 10.1016/j.fertnstert.2015.07.1159. PMID: 26300020.L1: X-5

763. Barboza LE, Malafaia O, Slongo LE, et al. Holmium Laser enucleation of the prostate (HoLEP) versus Transurethral Resection of the Prostate (TURP). Rev Col Bras Cir. 2015 Jun;42(3):165-70. doi: 10.1590/0100-69912015003007. PMID: 26291257.L1: X-2, X-3

764. Akintobi AO, Bello O, Asaolu OA, et al. Laparoscopic supracervical hysterectomy and uterine morcellation: A case report from Asokoro District Hospital, Abuja, Nigeria. Niger J Clin Pract. 2015 Nov-Dec;18(6):824-7. doi: 10.4103/1119-3077.163280. PMID: 26289526.L1: X-3, X-5

765. Ramirez-Sanchez LR, Alanis-Fuentes J, Morales-Dominguez L. [Intrauterine synechiae after use of monopolar resectoscope]. Ginecol Obstet Mex. 2015 Jun;83(6):340-9. PMID: 26285485.L1: X-4, X-5

766. Montella F, Cosma S, Riboni F, et al. A Safe and Simple Laparoscopic Cold Knife Section Technique for Bulky Uterus Removal. J Laparoendosc Adv Surg Tech A. 2015 Sep;25(9):755-9. doi: 10.1089/lap.2014.0640. PMID: 26275047.L1: X-5

767. Munro MG. Hysteroscopic Myomectomy of FIGO Type 2 Leiomyomas Under Local Anesthesia: Bipolar Radiofrequency Needle-Based Release Followed by Electromechanical Morcellation. J Minim Invasive Gynecol. 2015 Aug 8doi: 10.1016/j.jmig.2015.08.002. PMID: 26260303.L1: X-3, X-5

768. Turgal M, Ozgu-Erdinc AS, Beksac K, et al. Myomectomy during cesarean section and adhesion formation as a long-term postoperative complication. Ginekol Pol. 2015 Jun;86(6):457-60. PMID: 26255455.L1: X-4, X-5

769. Brunckhorst O, Ahmed K, Nehikhare O, et al. Evaluation of the Learning Curve for Holmium Laser Enucleation of the Prostate Using Multiple Outcome Measures. Urology. 2015 Oct;86(4):824-9. doi: 10.1016/j.urology.2015.07.021. PMID: 26254171.L1: X-2, X-3

770. Brito LG, Rosa e Silva JC, Nogueira AA. [Reflections about the impact caused by the Food and Drug Administration (FDA) warning against uterine and/or fibroid power morcellation]. Rev Bras Ginecol Obstet. 2015 Jul;37(7):299-301. doi: 10.1590/s0100-720320150005428. PMID: 26247248.L1: X-1

771. Taylor DK, Holthouser K, Segars JH, et al. Recent scientific advances in leiomyoma (uterine fibroids) research facilitates better understanding and management. F1000Res. 2015;4(F1000 Faculty Rev):183. doi: 10.12688/f1000research.6189.1. PMID: 26236472.L1: X-1

772. Van der Meulen JF, Pijnenborg J, Boomsma CM, et al. Parasitic myoma after laparoscopic morcellation: a systematic review of the literature. Bjog. 2015 Jul 29doi: 10.1111/1471-0528.13541. PMID: 26234998.L1: X-1

773. Obajimi GO, Oranye BC. Retained surgical needle post myomectomy, an uncommon mishap. Afr J Med Med Sci. 2014 Dec;43(4):365-7. PMID: 26234126.L1: X-2, X-3, X-4, X-5

774. Chan JK, Gardner AB, Thompson CA, et al. The use of clinical characteristics to help prevent morcellation of leiomyosarcoma: An analysis of 491 cases. Am J Obstet Gynecol. 2015 Jul 29doi: 10.1016/j.ajog.2015.07.040. PMID: 26226552.L1: INCLUDE L2: X-3, X-5

775. Choi CH, Kim JJ, Kim WY, et al. A rare case of post-hysterectomy vault site iatrogenic endometriosis. Obstet Gynecol Sci. 2015 Jul;58(4):319-22. doi: 10.5468/ogs.2015.58.4.319. PMID: 26217604.L1: X-2, X-3, X-4, X-5

776. Chung YH, Lee SW, Shin SY, et al. Single-port laparoscopic debulking surgery of variant benign metastatic leiomyomatosis with simultaneous lymphatic spreading and intraperitoneal seeding. Obstet Gynecol Sci. 2015 Jul;58(4):314-8. doi: 10.5468/ogs.2015.58.4.314. PMID: 26217603.L1: X-2, X-3, X-5

777. Melendez J, Yoong W. Re: Laparoscopic morcellation: an acceptable risk or an Achilles heel? Are there safer alternatives to morcellation? Bjog. 2015 Aug;122(9):1275. doi: 10.1111/1471-0528.13492. PMID: 26212744.L1: X-1

778. Solima E, Scagnelli G, Austoni V, et al. Vaginal Uterine Morcellation Within a Specimen Containment System: A Study of Bag Integrity. J Minim Invasive Gynecol. 2015 Jul 20doi: 10.1016/j.jmig.2015.07.007. PMID: 26205578.L1: X-5

779. Hamerlynck TW, Schoot BC, van Vliet HA, et al. Removal of Endometrial Polyps: Hysteroscopic Morcellation versus Bipolar Resectoscopy, A Randomized Trial. J Minim Invasive Gynecol. 2015 Jul 17doi: 10.1016/j.jmig.2015.07.006. PMID: 26192235.L1: X-2, X-3, X-5

780. Monn MF, El Tayeb M, Bhojani N, et al. Predictors of Enucleation and Morcellation Time During Holmium Laser Enucleation of the Prostate. Urology. 2015 Aug;86(2):338-42. doi: 10.1016/j.urology.2015.04.028. PMID: 26189134.L1: X-2, X-3

781. . Incorrect and Incomplete Table Headings. Use of Electric Power Morcellation and Prevalence of Underlying Cancer in Women Who Undergo Myomectomy. JAMA Oncol. 2015 Apr;1(1):110. doi: 10.1001/jamaoncol.2015.0803. PMID: 26182314.L1: X-1

782. Nezhat C. The Dilemma of Myomectomy, Morcellation, and the Demand for Reliable Metrics on Surgical Quality. JAMA Oncol. 2015 Apr;1(1):78-9. doi: 10.1001/jamaoncol.2014.184. PMID: 26182308.L1: X-1

783. Wright JD, Tergas AI, Cui R, et al. Use of Electric Power Morcellation and Prevalence of Underlying Cancer in Women Who Undergo Myomectomy. JAMA Oncol. 2015 Apr;1(1):69-77. doi: 10.1001/jamaoncol.2014.206. PMID: 26182307.L1: INCLUDE L2: X-5

784. Chen I, Hopkins L, Firth B, et al. Incidence of Tissue Morcellation During Surgery for Uterine Sarcoma at a Canadian Academic Centre. J Obstet Gynaecol Can. 2015 May;37(5):421-5. PMID: 26168102.L1: X-5

785. Singh SS, Bougie O, Arendas K, et al. Morcellation in Canada: Perspectives on Current Practices and Future Implications. J Minim Invasive Gynecol. 2015 Jul 10doi: 10.1016/j.jmig.2015.07.001. PMID: 26166320.L1: X-1

786. Minagawa S, Okada S, Sakamoto H, et al. En-Bloc Technique With Anteroposterior Dissection Holmium Laser Enucleation of the Prostate Allows a Short Operative Time and Acceptable Outcomes. Urology. 2015 Sep;86(3):628-33. doi: 10.1016/j.urology.2015.06.009. PMID: 26126696.L1: X-2, X-3

787. Piao S, Choo MS, Wang Y, et al. Clinical and Pathological Characteristics of Hard Nodules Resistant to Morcellation During Holmium Laser Enucleation of the Prostate. Int Neurourol J. 2015 Jun;19(2):90-8. doi: 10.5213/inj.2015.19.2.90. PMID: 26126438.L1: X-2, X-3

788. Olive DL. The dangers of junk science in obstetrics and gynecology: lessons from the power morcellation controversy. Curr Opin Obstet Gynecol. 2015 Aug;27(4):249-52. doi: 10.1097/gco.0000000000000191. PMID: 26107785.L1: X-1

789. Ciszak T, Mittal PK, Sullivan P, et al. Case report: MR imaging features of disseminated uterine leiomyosarcoma presenting after hysterectomy with morcellation. Abdom Imaging. 2015 Oct;40(7):2600-5. doi: 10.1007/s00261-015-0486-9. PMID: 26093623.L1: X-3

790. Rimbach S, Holzknecht A, Nemes C, et al. A new in-bag system to reduce the risk of tissue morcellation: development and experimental evaluation during laparoscopic hysterectomy. Arch Gynecol Obstet. 2015 Dec;292(6):1311-20. doi: 10.1007/s00404-015-3788-9. PMID: 26093523.L1: X-2, X-3, X-5

791. Dioun SM, Soliman PT. Laparoscopic hysterectomy with morcellation for a suspected uterine fibroid resulting in dissemination of cervical adenocarcinoma: A case report. Gynecol Oncol Rep. 2015 Apr;12:5-6. doi: 10.1016/j.gore.2014.12.001. PMID: 26076147.L1: X-3, X-5

792. Inoue K, Tsubamoto H, Oku H, et al. Complete remission achieved by oophorectomy for recurrent endometrial stromal sarcoma after laparoscopic morcellation. Gynecol Oncol Rep. 2015 Jan;11:1-3. doi: 10.1016/j.gore.2014.10.003. PMID: 26076082.L1: X-3

793. Cusido M, Fargas F, Baulies S, et al. Impact of Surgery on the Evolution of Uterine Sarcomas. J Minim Invasive Gynecol. 2015 Sep-Oct;22(6):1068-74. doi: 10.1016/j.jmig.2015.05.024. PMID: 26070730.L1: INCLUDE L2: X-3

794. Chong GO, Lee YH, Hong DG, et al. Robotic hysterectomy or myomectomy without power morcellation: A single-port assisted three-incision technique with manual morcellation. Int J Med Robot. 2015 Jun 8doi: 10.1002/rcs.1668. PMID: 26058845.L1: X-5

795. Santos-Lopez A, Gorbea-Chavez V, Rodriguez-Colorado S, et al. [Vaginal hysterectomy for the enlarged non-prolapse uterus using morcellation techniques and/or Deschamps needle: a retrospective cohort study]. Ginecol Obstet Mex. 2015 Mar;83(3):148-54. PMID: 26058167.L1: X-5

796. Saredi G, Pirola GM, Pacchetti A, et al. Evaluation of the learning curve for thulium laser enucleation of the prostate with the aid of a simulator tool but without tutoring: comparison of two surgeons with different levels of endoscopic experience. BMC Urol. 2015;15:49. doi: 10.1186/s12894-015-0045-2. PMID: 26055885.L1: X-2, X-3

797. Clark Donat L, Clark M, Tower AM, et al. Transvaginal morcellation. Jsls. 2015 Apr-Jun;19(2)doi: 10.4293/jsls.2014.00255. PMID: 26005318.L1: INCLUDE L2: X-5

798. Dessie SG, Park M, Rosenblatt PL. Laparoscopic supracervical hysterectomy with transcervical morcellation and sacrocervicopexy for the treatment of uterine prolapse. Int Urogynecol J. 2015 May 20doi: 10.1007/s00192-015-2732-7. PMID: 25990208.L1: X-2, X-3, X-5

799. Naumann RW, Brown J. Complications of Electromechanical Morcellation Reported in the Manufacturer and User Facility Device Experience (MAUDE) Database. J Minim Invasive Gynecol. 2015 Sep-Oct;22(6):1018-21. doi: 10.1016/j.jmig.2015.05.008. PMID: 25987522.L1: INCLUDE L2: X-3, X-3d

800. Connor M. New technologies and innovations in hysteroscopy. Best Pract Res Clin Obstet Gynaecol. 2015 Apr 1doi: 10.1016/j.bpobgyn.2015.03.012. PMID: 25958129.L1: X-1

801. Chang WC, Chu LH, Huang PS, et al. Comparison of Laparoscopic Myomectomy in Large Myomas With and Without Leuprolide Acetate. J Minim Invasive Gynecol. 2015 Sep-Oct;22(6):992-6. doi: 10.1016/j.jmig.2015.04.026. PMID: 25958038.L1: X-5

802. Sakes A, Arkenbout EA, Jelinek F, et al. Design of an endovascular morcellator for the surgical treatment of equine Cushing's disease. Vet Q. 2015;35(3):165-9. doi: 10.1080/01652176.2015.1047676. PMID: 25946649.L1: X-2, X-3, X-5

803. Li S, Li M, Xu W, et al. Single-Incision Laparoscopic Splenectomy Using the Suture Suspension Technique for Splenomegaly in Children with Hereditary Spherocytosis. J Laparoendosc Adv Surg Tech A. 2015 Sep;25(9):770-4. doi: 10.1089/lap.2014.0375. PMID: 25946642.L1: X-2, X-3, X-5

804. Closon F, Tulandi T. Future research and developments in hysteroscopy. Best Pract Res Clin Obstet Gynaecol. 2015 Mar 31doi: 10.1016/j.bpobgyn.2015.03.008. PMID: 25943903.L1: X-1

805. McGurgan PM, McIlwaine P. Complications of hysteroscopy and how to avoid them. Best Pract Res Clin Obstet Gynaecol. 2015 Apr 1doi: 10.1016/j.bpobgyn.2015.03.009. PMID: 25937555.L1: X-1

806. Emanuel MH. Hysteroscopy and the treatment of uterine fibroids. Best Pract Res Clin Obstet Gynaecol. 2015 Apr 1doi: 10.1016/j.bpobgyn.2015.03.014. PMID: 25937553.L1: X-1

807. Akdemir A, Taylan E, Zeybek B, et al. Innovative technique for enclosed morcellation using a surgical glove. Obstet Gynecol. 2015 May;125(5):1145-9. doi: 10.1097/aog.0000000000000823. PMID: 25932842.L1: X-5

808. Favero G, Miglino G, Kohler C, et al. Vaginal Morcellation Inside Protective Pouch: A Safe Strategy for Uterine Extration in Cases of Bulky Endometrial Cancers: Operative and Oncological Safety of the Method. J Minim Invasive Gynecol. 2015 Sep-Oct;22(6):938-43. doi: 10.1016/j.jmig.2015.04.015. PMID: 25917277.L1: X-2, X-3, X-5

809. Princi D, Rolli R, Galli PA. Compliance and complications of culdotomy. Minerva Ginecol. 2015 Apr 22 PMID: 25900769.L1: X-5

810. Franchini M, Zolfanelli F, Gallorini M, et al. Hysteroscopic polypectomy in an office setting: specimen quality assessment for histopathological evaluation. Eur J Obstet Gynecol Reprod Biol. 2015 Jun;189:64-7. doi: 10.1016/j.ejogrb.2015.03.011. PMID: 25879991.L1: X-2, X-3, X-5

811. Noventa M, Ancona E, Quaranta M, et al. Intrauterine Morcellator Devices: The Icon of Hysteroscopic Future or Merely a Marketing Image? A Systematic Review Regarding Safety, Efficacy, Advantages, and Contraindications. Reprod Sci. 2015 Oct;22(10):1289-96. doi: 10.1177/1933719115578929. PMID: 25878200.L1: X-1

812. Suh DH, Lee KH, Kim K, et al. Major clinical research advances in gynecologic cancer in 2014. J Gynecol Oncol. 2015 Apr;26(2):156-67. doi: 10.3802/jgo.2015.26.2.156. PMID: 25872896.L1: X-1

813. Carmignani L, Macchi A, Ratti D, et al. Are Histological Findings of Thulium Laser Vapo-Enucleation Versus Transurethral Resection of the Prostate Comparable? Pathol Oncol Res. 2015 Sep;21(4):1071-5. doi: 10.1007/s12253-015-9931-x. PMID: 25862670.L1: X-1, X-2, X-3

814. Leanza V, Gulino FA, Leanza G, et al. Surgical removal of multiple mesenteric fibroids (Kg 4,500) by abdominal spread of previous laparoscopic uterine myomectomy. G Chir. 2015 Jan-Feb;36(1):32-5. PMID: 25827668.L1: X-2, X-3, X-5

815. Bortoletto P, Einerson BD, Miller ES, et al. Cost-Effectiveness Analysis of Morcellation Hysterectomy for Myomas. J Minim Invasive Gynecol. 2015 Jul-Aug;22(5):820-6. doi: 10.1016/j.jmig.2015.03.015. PMID: 25827327.L1: X-1, X-2, X-3, X-4, X-5

816. Siedhoff MT, Wheeler SB, Rutstein SE, et al. Laparoscopic hysterectomy with morcellation vs abdominal hysterectomy for presumed fibroid tumors in premenopausal women: a decision analysis. Am J Obstet Gynecol. 2015 May;212(5):591.e1-8. doi: 10.1016/j.ajog.2015.03.006. PMID: 25817518.L1: X-1

817. Robert G, Cornu JN, Fourmarier M, et al. Multicentre prospective evaluation of the learning curve of holmium laser enucleation of the prostate (HoLEP). BJU Int. 2015 Mar 17doi: 10.1111/bju.13124. PMID: 25781490.L1: X-2, X-3

818. Kaser DJ, Melamed A, Bormann CL, et al. Cryopreserved embryo transfer is an independent risk factor for placenta accreta. Fertil Steril. 2015 May;103(5):1176-84.e2. doi: 10.1016/j.fertnstert.2015.01.021. PMID: 25747133.L1: X-3, X-4, X-5

819. Ubaldi FM, Vaiarelli A, Rienzi L. Loop electrosurgical excision procedure: a risk for spontaneous abortion? Fertil Steril. 2015 Apr;103(4):904-5. doi: 10.1016/j.fertnstert.2015.01.016. PMID: 25660645.L1: X-1

820. Ciavattini A, Clemente N, Delli Carpini G, et al. Loop electrosurgical excision procedure and risk of miscarriage. Fertil Steril. 2015 Apr;103(4):1043-8. doi: 10.1016/j.fertnstert.2014.12.112. PMID: 25624192.L1: X-2, X-3, X-4, X-5

821. Lieng M, Berner E, Busund B. Reply: To PMID 25460521. J Minim Invasive Gynecol. 2015 May-Jun;22(4):697. doi: 10.1016/j.jmig.2015.01.016. PMID: 25623372.L1: X-1

822. Api M, Boza A, Cikman MS, et al. Comparison of barbed and conventional sutures in adhesion formation and histological features in a rat myomectomy model: randomized single blind controlled trial. Eur J Obstet Gynecol Reprod Biol. 2015 Feb;185:121-5. doi: 10.1016/j.ejogrb.2014.11.032. PMID: 25562637.L1: X-2, X-3, X-4, X-5

823. Martyn FM, McAuliffe FM, Beggan C, et al. Excisional treatments of the cervix and effect on subsequent fertility: a retrospective cohort study. Eur J Obstet Gynecol Reprod Biol. 2015 Feb;185:114-20. doi: 10.1016/j.ejogrb.2014.12.004. PMID: 25557866.L1: X-2, X-3, X-4, X-5

824. Stout MJ, Frey HA, Tuuli MG, et al. Loop electrosurgical excision procedure and risk of vaginal infections during pregnancy: an observational study. Bjog. 2015 Mar;122(4):545-51. doi: 10.1111/1471-0528.13252. PMID: 25515321.L1: X-2, X-3, X-4, X-5

825. Abu-Elhasan AM, Abdellah MS, Hamed HO. Safety and efficacy of postoperative continuous intra-peritoneal wash with lactated Ringer's for minimizing post-myomectomy pelvic adhesions: a pilot clinical trial. Eur J Obstet Gynecol Reprod Biol. 2014 Dec;183:78-82. doi: 10.1016/j.ejogrb.2014.09.002. PMID: 25461357.L1: X-2, X-4, X-5

826. Wortman M, Cholkeri A, McCausland AM, et al. Late-onset endometrial ablation failure--etiology, treatment, and prevention. J Minim Invasive Gynecol. 2015 Mar-Apr;22(3):323-31. doi: 10.1016/j.jmig.2014.10.020. PMID: 25446549.L1: X-1

827. McPherson K, Manyonda I, Lumsden MA, et al. A randomised trial of treating fibroids with either embolisation or myomectomy to measure the effect on quality of life among women wishing to avoid hysterectomy (the FEMME study): study protocol for a randomised controlled trial. Trials. 2014;15:468. doi: 10.1186/1745-6215-15-468. PMID: 25432688.L1: X-1, X-4, X-5

828. Takeda A, Koike W, Imoto S, et al. Conservative management of uterine artery pseudoaneurysm after laparoscopic-assisted myomectomy and subsequent pregnancy outcome: case series and review of the literature. Eur J Obstet Gynecol Reprod Biol. 2014 Nov;182:146-53. doi: 10.1016/j.ejogrb.2014.09.020. PMID: 25277771.L1: X-3, X-4, X-5

829. Shen Q, Chen M, Wang Y, et al. Effects of laparoscopic versus minilaparotomic myomectomy on uterine leiomyoma: a meta-analysis. J Minim Invasive Gynecol. 2015 Feb;22(2):177-84. doi: 10.1016/j.jmig.2014.09.007. PMID: 25265886.L1: X-1, X-4

830. Conforti A, Krishnamurthy GB, Dragamestianos C, et al. Intrauterine adhesions after open myomectomy: an audit. Eur J Obstet Gynecol Reprod Biol. 2014 Aug;179:42-5. doi: 10.1016/j.ejogrb.2014.04.034. PMID: 24965978.L1: X-4, X-5

831. Kofoed K, Norrbom C, Forslund O, et al. Low prevalence of oral and nasal human papillomavirus in employees performing CO2-laser evaporation of genital warts or loop electrode excision procedure of cervical dysplasia. Acta Derm Venereol. 2015 Feb;95(2):173-6. doi: 10.2340/00015555-1912. PMID: 24941064.L1: X-2, X-3, X-4, X-5

832. Maclaran K, Agarwal N, Odejinmi F. Co-existence of uterine myomas and endometriosis in women undergoing laparoscopic myomectomy: risk factors and surgical implications. J Minim Invasive Gynecol. 2014 Nov-Dec;21(6):1086-90. doi: 10.1016/j.jmig.2014.05.013. PMID: 24905479.L1: X-4, X-5

833. Fokom-Domgue J, Vassilakos P, Petignat P. Is screen-and-treat approach suited for screening and management of precancerous cervical lesions in Sub-Saharan Africa? Prev Med. 2014 Aug;65:138-40. doi: 10.1016/j.ypmed.2014.05.014. PMID: 24879892.L1: X-1, X-3

834. Bailey AP, Lancerotto L, Gridley C, et al. Greater surgical precision of a flexible carbon dioxide laser fiber compared to monopolar electrosurgery in porcine myometrium. J Minim Invasive Gynecol. 2014 Nov-Dec;21(6):1103-9. doi: 10.1016/j.jmig.2014.05.004. PMID: 24858988.L1: X-2

835. Manoucheri E, Fuchs-Weizman N, Cohen SL, et al. MAUDE: analysis of robotic-assisted gynecologic surgery. J Minim Invasive Gynecol. 2014 Jul-Aug;21(4):592-5. doi: 10.1016/j.jmig.2013.12.122. PMID: 24486535.L1: X-1, X-4, X-5

836. Ardovino M, Castaldi MA, Fraternali F, et al. Bidirectional barbed suture in laparoscopic myomectomy: clinical features. J Laparoendosc Adv Surg Tech A. 2013 Dec;23(12):1006-10. doi: 10.1089/lap.2013.0103. PMID: 24320206.L1: X-4, X-5

837. Pluchino N, Litta P, Freschi L, et al. Comparison of the initial surgical experience with robotic and laparoscopic myomectomy. Int J Med Robot. 2014 Jun;10(2):208-12. doi: 10.1002/rcs.1542. PMID: 24123629.L1: X-5

838. Ciavattini A, Stortoni P, Mancioli F, et al. The impact of loop electrosurgical excision procedure (LEEP) for CIN 2,3 on spontaneous preterm delivery in twin pregnancies by assisted reproductive technique: preliminary data. J Matern Fetal Neonatal Med. 2014 Jul;27(11):1169-71. doi: 10.3109/14767058.2013.850483. PMID: 24090057.L1: X-3, X-4

839. Ehsanipoor RM, Jolley JA, Goldshore MA, et al. The relationship between previous treatment for cervical dysplasia and preterm delivery in twin gestations. J Matern Fetal Neonatal Med. 2014 May;27(8):821-4. doi: 10.3109/14767058.2013.836178. PMID: 23962130.L1: X-2, X-3, X-4, X-5

840. Gizzo S, Saccardi C, Patrelli TS, et al. Magnetic resonance-guided focused ultrasound myomectomy: safety, efficacy, subsequent fertility and quality-of-life improvements, a systematic review. Reprod Sci. 2014 Apr;21(4):465-76. doi: 10.1177/1933719113497289. PMID: 23868442.L1: X-1

841. Berman JM, Guido RS, Garza Leal JG, et al. Three-year outcome of the Halt trial: a prospective analysis of radiofrequency volumetric thermal ablation of myomas. J Minim Invasive Gynecol. 2014 Sep-Oct;21(5):767-74. doi: 10.1016/j.jmig.2014.02.015. PMID: 24613404.L1: X-4, X-5

842. Hampton T. Critics of fibroid removal procedure question risks it may pose for women with undetected uterine cancer. Jama. 2014 Mar 5;311(9):891-3. doi: 10.1001/jama.2014.27. PMID: 24504342.L1: X-1

843. Song H, Lu D, Navaratnam K, et al. Aromatase inhibitors for uterine fibroids. Cochrane Database Syst Rev. 2013;10:Cd009505. doi: 10.1002/14651858.CD009505.pub2. PMID: 24151065.L1: X-1

844. Andrews RT, Spies JB, Sacks D, et al. Patient care and uterine artery embolization for leiomyomata. J Vasc Interv Radiol. 2009 Jul;20(7 Suppl):S307-11. doi: 10.1016/j.jvir.2009.04.002. PMID: 19560015.L1: X-1, X-4

845. Sesti F, Ruggeri V, Pietropolli A, et al. Laparoscopically assisted vaginal hysterectomy versus vaginal hysterectomy for enlarged uterus. Jsls. 2008 Jul-Sep;12(3):246-51. PMID: 18765046.L1: X-5

846. Tan J, Sun Y, Dai H, et al. A randomized trial of laparoscopic versus laparoscopic-assisted minilaparotomy myomectomy for removal of large uterine myoma: short-term outcomes. J Minim Invasive Gynecol. 2008 Jul-Aug;15(4):402-9. doi: 10.1016/j.jmig.2008.03.010. PMID: 18602045.L1: X-4, X-5

847. Sesti F, Capobianco F, Capozzolo T, et al. Isobaric gasless laparoscopy versus minilaparotomy in uterine myomectomy: a randomized trial. Surg Endosc. 2008 Apr;22(4):917-23. doi: 10.1007/s00464-007-9516-1. PMID: 17705083.L1: X-5

848. Lethaby A, Vollenhoven B. Fibroids (uterine myomatosis, leiomyomas). Clin Evid. 2002 Jun(7):1666-78. PMID: 12230780.L1: X-1

849. Seracchioli R, Venturoli S, Vianello F, et al. Total laparoscopic hysterectomy compared with abdominal hysterectomy in the presence of a large uterus. J Am Assoc Gynecol Laparosc. 2002 Aug;9(3):333-8. PMID: 12101331.L1: X-5

850. Yen YK, Liu WM, Yuan CC, et al. Comparison of two procedures for laparoscopic-assisted vaginal hysterectomy of large myomatous uteri. J Am Assoc Gynecol Laparosc. 2002 Feb;9(1):63-9. PMID: 11821608.L1: X-5

851. Darai E, Soriano D, Kimata P, et al. Vaginal hysterectomy for enlarged uteri, with or without laparoscopic assistance: randomized study. Obstet Gynecol. 2001 May;97(5 Pt 1):712-6. PMID: 11339921.L1: X-2, X-5

852. Soriano D, Goldstein A, Lecuru F, et al. Recovery from vaginal hysterectomy compared with laparoscopy-assisted vaginal hysterectomy: a prospective, randomized, multicenter study. Acta Obstet Gynecol Scand. 2001 Apr;80(4):337-41. PMID: 11264609.L1: X-5

853. Ferrari MM, Berlanda N, Mezzopane R, et al. Identifying the indications for laparoscopically assisted vaginal hysterectomy: a prospective, randomised comparison with abdominal hysterectomy in patients with symptomatic uterine fibroids. Bjog. 2000 May;107(5):620-5. PMID: 10826576.L1: X-5

854. Kroncke T, David M. Uterine Artery Embolization (UAE) for Fibroid Treatment - Results of the 5th Radiological Gynecological Expert Meeting. Rofo. 2015 Apr 22doi: 10.1055/s-0034-1399345. PMID: 25901539.L1: X-1

855. Venkatesan AM, Partanen A, Pulanic TK, et al. Magnetic resonance imaging-guided volumetric ablation of symptomatic leiomyomata: correlation of imaging with histology. J Vasc Interv Radiol. 2012 Jun;23(6):786-94.e4. doi: 10.1016/j.jvir.2012.02.015. PMID: 22626269.INCLUDE X-2, X-5

856. Radosa MP, Owsianowski Z, Mothes A, et al. Long-term risk of fibroid recurrence after laparoscopic myomectomy. Eur J Obstet Gynecol Reprod Biol. 2014 Sep;180:35-9. doi: 10.1016/j.ejogrb.2014.05.029. PMID: 25016181.INCLUDE X-2, X-5

857. Agrawal P, Agrawal R, Chandrakar J. To Assess the Safety of Morcellation for Removing Uterine Specimen During Laparoscopic and Vaginal Hysterectomies for Leiomyomas. J Obstet Gynaecol India. 2016 Oct;66(Suppl 1):567-72. doi: 10.1007/s13224-016-0900-4. PMID: 27651662.X-5

858. Sekulic M, Moench L, Movahedi-Lankarani S. Disseminated peritoneal leiomyomatosis postmorcellated resection of uterine leiomyomatous tissue. Apmis. 2016 Sep 20doi: 10.1111/apm.12601. PMID: 27649643.X-5

859. Nezhat C, Li A, Abed S, et al. Strong Association Between Endometriosis and Symptomatic Leiomyomas. Jsls. 2016 Jul-Sep;20(3)doi: 10.4293/jsls.2016.00053. PMID: 27647977.X-5

860. Baron M, Nouhaud FX, Delcourt C, et al. [HoLEP learning curve: Toward a standardised formation and a team strategy]. Prog Urol. 2016 Sep;26(9):492-9. doi: 10.1016/j.purol.2016.08.002. PMID: 27614386.X-2, X-3, X-5

861. Meulenbroeks D, Hamerlynck TW, Saglam-Kara S, et al. Hysteroscopic tissue removal systems: a randomized in vitro comparison. J Minim Invasive Gynecol. 2016 Sep 2doi: 10.1016/j.jmig.2016.08.829. PMID: 27597661.X-2, X-5

862. Hamerlynck TW, van Vliet HA, Beerens AS, et al. Hysteroscopic morcellation versus loop resection for removal of placental remnants: a randomized trial. J Minim Invasive Gynecol. 2016 Aug 30doi: 10.1016/j.jmig.2016.08.828. PMID: 27590568.X-2, X-3, X-5

863. Xu AB, Luo F, Zou ZH, et al. [Application of morcellator in transurethral bipolar plasmakinetic anatomical enucleation of the prostate]. Nan Fang Yi Ke Da Xue Xue Bao. 2016 Aug 20;36(8):1100-4. PMID: 27578580.X-2, X-3, X-5

864. Pearce SM, Pariser JJ, Malik RD, et al. Outcomes following Thulium vapoenucleation of large prostates. Int Braz J Urol. 2016 Jul-Aug;42(4):757-65. doi: 10.1590/s1677-5538.ibju.2015.0424. PMID: 27564287.X-2, X-3, X-5

865. Wright JD, Chen L, Burke WM, et al. Trends in Use and Outcomes of Women Undergoing Hysterectomy With Electric Power Morcellation. Jama. 2016 Aug 23-30;316(8):877-8. doi: 10.1001/jama.2016.9432. PMID: 27552622.INCLUDE X-5

866. Salari BW, Bhagavath B, Galloway ML, et al. The hysteroscopic morcellator to overcome cervical stenosis. Fertil Steril. 2016 Aug 16doi: 10.1016/j.fertnstert.2016.07.1091. PMID: 27542706.X-2, X-3, X-5

867. Barker MA. Current Issues with Hysterectomy. Obstet Gynecol Clin North Am. 2016 Sep;43(3):591-601. doi: 10.1016/j.ogc.2016.04.012. PMID: 27521886.X-1

868. Bechev B, Magunska N, Kovachev E, et al. [LAPAROSCOPIC TREATMENT OF INTRALIGAMENTAL LEIOMYOMA PER MAGNA]. Akush Ginekol (Sofiia). 2016;55(1):66-8. PMID: 27514135.X-2, X-3, X-5

869. Gincheva D, Nikolova M. [DISSEMINATED PERITONEAL LEYOMYOMATOSIS--PRACTICAL APPROACH TO DIAGNOSIS]. Akush Ginekol (Sofiia). 2016;55(2):45-8. PMID: 27509658.X-1, X-2, X-3, X-5

870. Shaker H. Prostate tissue retrieval after holmium laser enucleation of the prostate; assessment of non-morcellation approaches. Arab J Urol. 2016 Jun;14(2):156. doi: 10.1016/j.aju.2016.03.001. PMID: 27489743.X-1, X-2, X-3, X-5

871. Gutman RE. Does the uterus need to be removed to correct uterovaginal prolapse? Curr Opin Obstet Gynecol. 2016 Oct;28(5):435-40. doi: 10.1097/gco.0000000000000307. PMID: 27467823.X-1

872. Piao S, Choo MS, Kim M, et al. Holmium Laser Enucleation of the Prostate is Safe for Patients Above 80 Years: A Prospective Study. Int Neurourol J. 2016 Jun;20(2):143-50. doi: 10.5213/inj.1630478.239. PMID: 27377947.X-2, X-3, X-5

873. Kerbage Y, Azais H, Estevez JP, et al. [Current controversies regarding power morcellation and future directions]. Gynecol Obstet Fertil. 2016 Jul-Aug;44(7-8):417-23. doi: 10.1016/j.gyobfe.2016.05.006. PMID: 27363612.X-1

874. Chaichian S, Mehdizadehkashi A, Tahermanesh K, et al. Leiomyosarcoma of the Broad Ligament With Fever Presentation: A Case Report and Review of Literature. Iran Red Crescent Med J. 2016 Apr;18(4):e33892. doi: 10.5812/ircmj.33892. PMID: 27330834.X-3, X-5

875. . Medical Devices; Obstetrical and Gynecological Devices; Classification of the Gynecologic Laparoscopic Power Morcellation Containment System. Final order. Fed Regist. 2016 Jun 21;81(119):40181-3. PMID: 27328463.X-1

876. Moawad GN, Samuel D, Khalil ED. Abdominal Approaches to Tissue Containment and Extraction in Minimally Invasive Gynecologic Surgery. J Minim Invasive Gynecol. 2016 Jun 12doi: 10.1016/j.jmig.2016.05.014. PMID: 27306150.X-1, X-2, X-3, X-5

877. Wu C, Zhang X, Tao X, et al. Leiomyomatosis peritonealis disseminata: A case report and review of the literature. Mol Clin Oncol. 2016 Jun;4(6):957-8. doi: 10.3892/mco.2016.848. PMID: 27284430.X-2, X-3, X-5

878. Nappi L, Sorrentino F, Angioni S, et al. Leiomyomatosis Peritonealis Disseminata (LPD) ten years after laparoscopic myomectomy associated with ascites and lymph nodes enlargement: a case report. Int J Surg Case Rep. 2016;25:1-3. doi: 10.1016/j.ijscr.2016.05.017. PMID: 27280492.X-3, X-5

879. Anapolski M, Panayotopoulos D, Alkatout I, et al. Power morcellation inside a secure endobag: a pilot study. Minim Invasive Ther Allied Technol. 2016 Aug;25(4):203-9. doi: 10.1080/13645706.2016.1176932. PMID: 27192613.X-5

880. Ackenbom MF, Giugale LE, Wang Y, et al. Incidence of Occult Uterine Pathology in Women Undergoing Hysterectomy With Pelvic Organ Prolapse Repair. Female Pelvic Med Reconstr Surg. 2016 Sep-Oct;22(5):332-5. doi: 10.1097/spv.0000000000000283. PMID: 27171317.X-2, X-3, X-4, X-5

881. Shazly SA, Laughlin-Tommaso SK, Breitkopf DM, et al. Hysteroscopic Morcellation Versus Resection for the Treatment of Uterine Cavitary Lesions: A Systematic Review and Meta-analysis. J Minim Invasive Gynecol. 2016 Sep-Oct;23(6):867-77. doi: 10.1016/j.jmig.2016.04.013. PMID: 27164165.X-1

882. Walter JR, Hayman E, Tsai S, et al. Medical Device Approvals Through the Premarket Approval Pathway in Obstetrics and Gynecology From 2000 to 2015: Process and Problems. Obstet Gynecol. 2016 Jun;127(6):1110-7. doi: 10.1097/aog.0000000000001430. PMID: 27159747.X-1

883. Campagna G, Morciano A, Rossitto C, et al. A new approach to supracervical hysterectomy during laparoscopic sacral colpopexy for pelvic organ prolapse: A randomized clinical trial. Neurourol Urodyn. 2016 Apr 29doi: 10.1002/nau.23030. PMID: 27128776.X-2, X-3, X-5

884. Aoki Y, Matsuura M, Matsuno T, et al. Single-site in-bag morcellation achieved via direct puncture of the pneumoperitoneum cap, a cordless electric morcellator, and a 5-mm flexible scope. Eur J Obstet Gynecol Reprod Biol. 2016 Jun;201:126-30. doi: 10.1016/j.ejogrb.2016.04.012. PMID: 27107329.X-5

885. Parker WH, Kaunitz AM, Pritts EA, et al. In Reply. Obstet Gynecol. 2016 May;127(5):966-7. doi: 10.1097/aog.0000000000001416. PMID: 27101114.X-1

886. Baggish M. U.S. Food and Drug Administration's Guidance Regarding Morcellation of Leiomyomas: Well-Intentioned, But Is It Harmful for Women? Obstet Gynecol. 2016 May;127(5):965-6. doi: 10.1097/aog.0000000000001415. PMID: 27101113.X-1

887. Dietl A, Farthmann J, Gitsch G. Complications after power morcellation: renewal of vaginal hysterectomy? Am J Obstet Gynecol. 2016 Aug;215(2):250. doi: 10.1016/j.ajog.2016.04.004. PMID: 27085514.X-1

888. Ikhena DE, Paintal A, Milad MP. Feasibility of Washings at the Time of Laparoscopic Power Morcellation: A Pilot Study. J Minim Invasive Gynecol. 2016 Jul-Aug;23(5):793-7. doi: 10.1016/j.jmig.2016.03.024. PMID: 27068277.X-5

889. Kim SH, Son HJ, Kim JW, et al. Severe postoperative dyspnea caused by neglected massive intraperitoneal fluid collection during laser enucleation and morcellation of the prostate: a case report. Korean J Anesthesiol. 2016 Apr;69(2):185-8. doi: 10.4097/kjae.2016.69.2.185. PMID: 27066210.X-2, X-3, X-5

890. El Tayeb MM, Jacob JM, Bhojani N, et al. Holmium Laser Enucleation of the Prostate in Patients Requiring Anticoagulation. J Endourol. 2016 Jul;30(7):805-9. doi: 10.1089/end.2016.0070. PMID: 27065437.X-2, X-3, X-5

891. Aitchison LP, Cui CK, Arnold A, et al. The ergonomics of laparoscopic surgery: a quantitative study of the time and motion of laparoscopic surgeons in live surgical environments. Surg Endosc. 2016 Apr 8doi: 10.1007/s00464-016-4855-4. PMID: 27059965.X-2, X-3, X-5

892. Ruan JY, Chen HQ, Gong YH, et al. Laparoscopic subtotal hysterectomy due to giant uterine fibroids: a case report. Clin Exp Obstet Gynecol. 2016;43(1):134-6. PMID: 27048036.X-3, X-5

893. Djakovic I, Rudman SS, Kosec V. UTERINE RUPTURE FOLLOWING MYOMECTOMY IN THIRD TRIMESTER. Acta Clin Croat. 2015 Dec;54(4):521-4. PMID: 27017729.X-2, X-3, X-4, X-5

894. Froyman W, Landolfo C, Amant F, et al. Morcellation and risk of malignancy in presumed ovarian fibromas/fibrothecomas. Lancet Oncol. 2016 Mar;17(3):273-4. doi: 10.1016/s1470-2045(16)00022-x. PMID: 26972853.X-2, X-3, X-5

895. Wasson M, Butler K, Magtibay P, et al. Prognostic Factors for Morcellation During Vaginal Hysterectomy. Obstet Gynecol. 2016 Apr;127(4):752-7. doi: 10.1097/aog.0000000000001346. PMID: 26959209.X-5

896. Tracy EE, Bortoletto P. The Role of Social Networks, Medical-Legal Climate, and Patient Advocacy on Surgical Options: A New Era. Obstet Gynecol. 2016 Apr;127(4):758-62. doi: 10.1097/aog.0000000000001335. PMID: 26959205.X-1

897. Takeda A, Watanabe K, Hayashi S, et al. In-Bag Manual Extraction of Excised Myomas by Surgical Scalpel through Suprapubic Mini-Laparotomic Incision in Laparoscopic-Assisted Myomectomy. J Minim Invasive Gynecol. 2016 Jul-Aug;23(5):731-8. doi: 10.1016/j.jmig.2016.02.020. PMID: 26946277.X-5

898. Winner B, Porter A, Biest S. In Reply. Obstet Gynecol. 2016 Feb;127(2):403-4. doi: 10.1097/aog.0000000000001283. PMID: 26942375.X-1

899. Lakhi NA, Serur E. Uncontained Compared With Contained Power Morcellation in Total Laparoscopic Hysterectomy. Obstet Gynecol. 2016 Feb;127(2):403. doi: 10.1097/aog.0000000000001282. PMID: 26942374. X-1

900. Centini G, Troia L, Lazzeri L, et al. Modern operative hysteroscopy. Minerva Ginecol. 2016 Apr;68(2):126-32. PMID: 26930389.X-1

901. Angioni S, Pontis A, Multinu A, et al. Safe endobag morcellation in a single-port laparoscopy subtotal hysterectomy. Minim Invasive Ther Allied Technol. 2016;25(2):113-6. doi: 10.3109/13645706.2015.1109521. PMID: 26902985.X-1, X-5

902. Nyilas A, Paszt A, Simonka Z, et al. [Laparoscopic removal of large spleens: Pfannenstiel incision as an alternative specimen extraction method]. Magy Seb. 2016 Mar;69(1):14-9. doi: 10.1556/1046.69.2016.1.3. PMID: 26901690.X-2, X-3, X-5

903. Po L, Lee PE. The Unintended Consequences of an FDA Warning: The Case of Power Morcellation in Myoma Surgery. J Minim Invasive Gynecol. 2016 May-Jun;23(4):597-602. doi: 10.1016/j.jmig.2016.02.004. PMID: 26898893.X-3, X-4, X-5

904. Lee EJ, Kim DH. Vaginal morcellation through the posterior cul-de-sac using an electromechanical morcellator after laparoscopic myomectomy or subtotal hysterectomy: a retrospective, case-control study. Surg Endosc. 2016 Feb 19doi: 10.1007/s00464-016-4821-1. PMID: 26895917.INCLUDE X-5

905. Ketan PV, Prashant HS. Thulium laser enucleation of the prostate is a safe and a highly effective modality for the treatment of benign prostatic hyperplasia - Our experience of 236 patients. Urol Ann. 2016 Jan-Mar;8(1):76-80. doi: 10.4103/0974-7796.171494. PMID: 26834407.X-2, X-3, X-4, X-5

906. Ripamonti U. Redefining the induction of periodontal tissue regeneration in primates by the osteogenic proteins of the transforming growth factor-beta supergene family. J Periodontal Res. 2016 Feb 2doi: 10.1111/jre.12356. PMID: 26833268.X-1, X-2, X-3, X-5

907. Lum DA, Sokol ER, Berek JS, et al. Impact of the 2014 Food and Drug Administration Warnings Against Power Morcellation. J Minim Invasive Gynecol. 2016 May-Jun;23(4):548-56. doi: 10.1016/j.jmig.2016.01.019. PMID: 26827905.X-2, X-3, X-5

908. Arnold A, Ketheeswaran A, Bhatti M, et al. A Prospective Analysis of Hysteroscopic Morcellation in the Management of Intrauterine Pathologies. J Minim Invasive Gynecol. 2016 Mar-Apr;23(3):435-41. doi: 10.1016/j.jmig.2016.01.013. PMID: 26803919.X-5

909. Venturella R, Rocca ML, Lico D, et al. In-bag manual versus uncontained power morcellation for laparoscopic myomectomy: randomized controlled trial. Fertil Steril. 2016 May;105(5):1369-76. doi: 10.1016/j.fertnstert.2015.12.133. PMID: 26801067.X-5

910. Rechberger T, Miotla P, Futyma K, et al. Power morcellation for women undergoing laparoscopic supracervical hysterectomy - safety of procedure and clinical experience from 426 cases. Ginekol Pol 2016;87(8):546-51. PMID: 27629127. X-5

911. Zhang J, Li T, Zhang J, et al. Clinical Characteristics and Prognosis of Unexpected Uterine Sarcoma After Hysterectomy for Presumed Myoma With and Without Transvaginal Scalpel Morcellation. Int J Gynecol Cancer 2016 Jan 20PMID: 26807642. X-5

912. Balgobin S, Maldonado PA, Chin K, et al. Safety Of Manual Morcellation Following Vaginal Or Laparoscopic-Assisted Vaginal Hysterectomy. J Minim Invasive Gynecol 2016 Jan 20PMID: 26802908. X-5

913. Picerno TM, Wasson MN, Gonzalez Rios AR, et al. Morcellation and the Incidence of Occult Uterine Malignancy: A Dual-Institution Review. Int J Gynecol Cancer 2016 Jan;26(1):149-55. PMID: 26332395. X-5

914. Rodriguez AM, Asoglu MR, Sak ME, et al. Incidence of occult leiomyosarcoma in presumed morcellation cases: a database study. Eur J Obstet Gynecol Reprod Biol 2015 Nov 28;197:31-5. PMID: 26699101. X-5

915. Zhao WC, Bi FF, Li D, et al. Incidence and clinical characteristics of unexpected uterine sarcoma after hysterectomy and myomectomy for uterine fibroids: a retrospective study of 10,248 cases. Onco Targets Ther 2015;8:2943-8. PMID: 26508879. X-5

916. Song T, Kim TJ, Lee SH, et al. Laparoendoscopic single-site myomectomy compared with conventional laparoscopic myomectomy: a multicenter, randomized, controlled trial. Fertil Steril 2015 Nov;104(5):1325-31. PMID: 26263079. X-5

917. Martin L, Scheib SA, Goldberg J. Complications Following Extended Freeze Endometrial Cryoablation in Uteri with Previous Uterine Incisions: A Case Report. J Reprod Med. 2015 Nov-Dec;60(11-12):540-2. PMID: 26775464.X-2, X-3, X-4, X-5

918. Lee MM, Matsuzono T. Hysteroscopic intrauterine morcellation of submucosal fibroids: preliminary results in Hong Kong and comparisons with conventional hysteroscopic monopolar loop resection. Hong Kong Med J. 2016 Feb;22(1):56-61. doi: 10.12809/hkmj154600. PMID: 26744122.X-5

919. Palermo M, Blanco L, Acquafresca P, et al. REDUCE PORT LAPAROSCOPIC SPLENECTOMY FOR GIANT EPITELIAL CYST. Arq Bras Cir Dig. 2015 Nov-Dec;28(4):282-5. doi: 10.1590/s0102-6720201500040016. PMID: 26734802.X-2, X-3, X-5

920. Narasimhulu DM, Eugene E, Sumit S. Torsion of an iatrogenic parasitic fibroid related to power morcellation for specimen retrieval. J Turk Ger Gynecol Assoc. 2015;16(4):259-62. doi: 10.5152/jtgga.2015.15093. PMID: 26692779.X-3, X-5

921. Rimbach S, Holzknecht A, Schmedler C, et al. First clinical experiences using a new in-bag morcellation system during laparoscopic hysterectomy. Arch Gynecol Obstet. 2016 Jul;294(1):83-93. doi: 10.1007/s00404-015-3986-5. PMID: 26690354.X-5

922. Sparic R, Guido M, Tinelli A. Cesarean myomectomy and possible risk factors for admission to intensive care unit - a retrospective study. Ginekol Pol. 2015 Oct;86(10):731-6. PMID: 26677581.X-4, X-5

923. Tulandi T, Closon F, Czuzoj-Shulman N, et al. Adhesion Barrier Use After Myomectomy and Hysterectomy: Rates and Immediate Postoperative Complications. Obstet Gynecol. 2016 Jan;127(1):23-8. doi: 10.1097/aog.0000000000001186. PMID: 26646123.X-4, X-5

924. Denschlag D, Thiel FC, Ackermann S, et al. Sarcoma of the Uterus. Guideline of the DGGG (S2k-Level, AWMF Registry No. 015/074, August 2015). Geburtshilfe Frauenheilkd. 2015 Oct;75(10):1028-42. doi: 10.1055/s-0035-1558120. PMID: 26640293.X-1

925. Martin L, Shelton J, Goldberg J. The current controversy regarding power morcellation in gynecologic surgery. Womens Health (Lond). 2015 Nov;11(6):793-5. doi: 10.2217/whe.15.65. PMID: 26618791.X-1

926. Pinto A, Barletta JA. Adrenal Tumors in Adults. Surg Pathol Clin. 2015 Dec;8(4):725-49. doi: 10.1016/j.path.2015.07.005. PMID: 26612224.X-1

927. Barron KI, Richard T, Robinson PS, et al. Association of the U.S. Food and Drug Administration Morcellation Warning With Rates of Minimally Invasive Hysterectomy and Myomectomy. Obstet Gynecol. 2015 Dec;126(6):1174-80. doi: 10.1097/aog.0000000000001111. PMID: 26595561.X-2, X-5

928. Kim YJ, Lee YH, Kwon JB, et al. A novel one lobe technique of thulium laser enucleation of the prostate: 'All-in-One' technique. Korean J Urol. 2015 Nov;56(11):769-74. doi: 10.4111/kju.2015.56.11.769. PMID: 26568795.X-2, X-3, X-5

929. Sandberg EM, Cohen SL, Jansen FW, et al. Analysis of Risk Factors for Intraoperative Conversion of Laparoscopic Myomectomy. J Minim Invasive Gynecol. 2016 Mar-Apr;23(3):352-7. doi: 10.1016/j.jmig.2015.10.017. PMID: 26546180.X-4, X-5

930. Lukes AS, Roy KH, Presthus JB, et al. Randomized comparative trial of cervical block protocols for pain management during hysteroscopic removal of polyps and myomas. Int J Womens Health. 2015;7:833-9. doi: 10.2147/ijwh.s50101. PMID: 26543383.X-5

931. Brown RH, Chang DK, Siy R, et al. Trends in the Surgical Correction of Gynecomastia. Semin Plast Surg. 2015 May;29(2):122-30. doi: 10.1055/s-0035-1549053. PMID: 26528088.X-1, X-2, X-3, X-5

932. Hur HC, King LP, Klebanoff MJ, et al. Fibroid morcellation: a shared clinical decision tool for mode of hysterectomy. Eur J Obstet Gynecol Reprod Biol. 2015 Dec;195:122-7. doi: 10.1016/j.ejogrb.2015.09.044. PMID: 26520875.X-3

933. Bhagavath B, Benjamin A. Minimally Invasive Gynecologic Surgery for Benign Conditions: Progress and Challenges. Obstet Gynecol Surv. 2015 Oct;70(10):656-66. doi: 10.1097/ogx.0000000000000237. PMID: 26490165.X-1

934. Kim JJ, Kim WY, Lee DH, et al. Efficacy of TachoSil((R)) in preventing hemorrhage after loop electrosurgical excision procedure. Eur J Obstet Gynecol Reprod Biol. 2015 Nov;194:245-8. doi: 10.1016/j.ejogrb.2015.09.005. PMID: 26476696.X-2, X-3, X-4, X-5

935. Rutstein SE, Siedhoff MT, Geller EJ, et al. Cost-Effectiveness of Laparoscopic Hysterectomy With Morcellation Compared With Abdominal Hysterectomy for Presumed Myomas. J Minim Invasive Gynecol. 2016 Feb 1;23(2):223-33. doi: 10.1016/j.jmig.2015.09.025. PMID: 26475764.X-1, X-5

936. Munro MG, Christianson LA. Complications of Hysteroscopic and Uterine Resectoscopic Surgery. Clin Obstet Gynecol. 2015 Dec;58(4):765-97. doi: 10.1097/grf.0000000000000146. PMID: 26457853.X-1

937. Moawad GN, Abi Khal IE, Opoku-Anane J, et al. Comparison of methods of morcellation: manual versus power. Acta Obstet Gynecol Scand. 2016 Jan;95(1):52-4. doi: 10.1111/aogs.12783. PMID: 26400045.X-5

938. Cohen SL, Morris SN, Brown DN, et al. Contained tissue extraction using power morcellation: prospective evaluation of leakage parameters. Am J Obstet Gynecol. 2016 Feb;214(2):257.e1-6. doi: 10.1016/j.ajog.2015.08.076. PMID: 26348384.X-5

939. Parker W. Parasitic myomas may be more common than we think. Bjog. 2016 Jan;123(1):76. doi: 10.1111/1471-0528.13573. PMID: 26335152.X-1

940. Harris JA, Swenson CW, Uppal S, et al. Practice patterns and postoperative complications before and after US Food and Drug Administration safety communication on power morcellation. Am J Obstet Gynecol. 2016 Jan;214(1):98.e1-.e13. doi: 10.1016/j.ajog.2015.08.047. PMID: 26314519.X-2, X-5

941. El Tayeb MM, Borofsky MS, Paonessa JE, et al. Wolf Piranha Versus Lumenis VersaCut Prostate Morcellation Devices: A Prospective Randomized Trial. J Urol. 2016 Feb;195(2):413-7. doi: 10.1016/j.juro.2015.08.078. PMID: 26307163.X-2, X-3, X-5

942. Munro MG. Hysteroscopic Myomectomy of FIGO Type 2 Leiomyomas Under Local Anesthesia: Bipolar Radiofrequency Needle-Based Release Followed By Electromechanical Morcellation. J Minim Invasive Gynecol. 2016 Jan;23(1):12-3. doi: 10.1016/j.jmig.2015.08.002. PMID: 26260303.X-1, X-5

943. Paul PG, Thomas M, Das T, et al. Contained Morcellation for Laparoscopic Myomectomy Within a Specially Designed Bag. J Minim Invasive Gynecol. 2016 Feb 1;23(2):257-60. doi: 10.1016/j.jmig.2015.08.004. PMID: 26260302.X-5

944. Hamerlynck TW, Schoot BC, van Vliet HA, et al. Removal of Endometrial Polyps: Hysteroscopic Morcellation versus Bipolar Resectoscopy, A Randomized Trial. J Minim Invasive Gynecol. 2015 Nov-Dec;22(7):1237-43. doi: 10.1016/j.jmig.2015.07.006. PMID: 26192235.X-2, X-3, X-5

945. Palomba S, La Sala GB. Response: Another consideration in minilaparotomy for myomectomy. Reprod Biomed Online. 2015 Sep;31(3):444. doi: 10.1016/j.rbmo.2015.05.012. PMID: 26184848.X-1

946. Kim TH, Lee HH, Kim JM, et al. Another consideration in minilaparotomy for myomectomy. Reprod Biomed Online. 2015 Sep;31(3):443. doi: 10.1016/j.rbmo.2015.05.013. PMID: 26184847.INCLUDE X-1

947. Ting WH, Lin HH, Wu MP, et al. Safety and efficacy of manual syringe infusion of distending media for hysteroscopic procedures: a case-control study. Eur J Obstet Gynecol Reprod Biol. 2015 Aug;191:112-5. doi: 10.1016/j.ejogrb.2015.06.003. PMID: 26115055.X-2, X-4, X-5

948. Chong GO, Lee YH, Hong DG, et al. Robotic hysterectomy or myomectomy without power morcellation: A single-port assisted three-incision technique with manual morcellation. Int J Med Robot. 2016 Sep;12(3):483-9. doi: 10.1002/rcs.1668. PMID: 26058845.X-5

949. Topcu HO, Iskender CT, Timur H, et al. Outcomes after cesarean myomectomy versus cesarean alone among pregnant women with uterine leiomyomas. Int J Gynaecol Obstet. 2015 Sep;130(3):244-6. doi: 10.1016/j.ijgo.2015.03.035. PMID: 26021769.X-4, X-5

950. Schwarz TM, Kolben T, Gallwas J, et al. Comparison of two surgical methods for the treatment of CIN: classical LLETZ (large-loop excision of the transformation zone) versus isolated resection of the colposcopic apparent lesion - study protocol for a randomized controlled trial. Trials. 2015;16:225. doi: 10.1186/s13063-015-0736-8. PMID: 26002493.X-1, X-2

951. Dessie SG, Park M, Rosenblatt PL. Laparoscopic supracervical hysterectomy with transcervical morcellation and sacrocervicopexy for the treatment of uterine prolapse. Int Urogynecol J. 2016 Jan;27(1):151-3. doi: 10.1007/s00192-015-2732-7. PMID: 25990208.X-2, X-3, X-5

952. Connor M. New technologies and innovations in hysteroscopy. Best Pract Res Clin Obstet Gynaecol. 2015 Oct;29(7):951-65. doi: 10.1016/j.bpobgyn.2015.03.012. PMID: 25958129.X-1

953. Closon F, Tulandi T. Future research and developments in hysteroscopy. Best Pract Res Clin Obstet Gynaecol. 2015 Oct;29(7):994-1000. doi: 10.1016/j.bpobgyn.2015.03.008. PMID: 25943903.X-1

954. McGurgan PM, McIlwaine P. Complications of hysteroscopy and how to avoid them. Best Pract Res Clin Obstet Gynaecol. 2015 Oct;29(7):982-93. doi: 10.1016/j.bpobgyn.2015.03.009. PMID: 25937555.X-1

955. Emanuel MH. Hysteroscopy and the treatment of uterine fibroids. Best Pract Res Clin Obstet Gynaecol. 2015 Oct;29(7):920-9. doi: 10.1016/j.bpobgyn.2015.03.014. PMID: 25937553.X-1, X-5

956. Princi D, Rolli R, Galli PA. Compliance and complications of culdotomy. Minerva Ginecol. 2016 Aug;68(4):418-22. PMID: 25900769.X-4, X-5

957. DeStephano CC, Jernigan AM, Szymanski LM. Iatrogenic Uterine Diverticulum in Pregnancy After Robotic-assisted Myomectomy. J Minim Invasive Gynecol. 2015 Jul-Aug;22(5):902-5. doi: 10.1016/j.jmig.2015.03.016. PMID: 25827328.X-2, X-3, X-4, X-5

958. Robert G, Cornu JN, Fourmarier M, et al. Multicentre prospective evaluation of the learning curve of holmium laser enucleation of the prostate (HoLEP). BJU Int. 2016 Mar;117(3):495-9. doi: 10.1111/bju.13124. PMID: 25781490.X-2, X-3, X-5

959. Palomba S, Fornaciari E, Falbo A, et al. Safety and efficacy of the minilaparotomy for myomectomy: a systematic review and meta-analysis of randomized and non-randomized controlled trials. Reprod Biomed Online. 2015 May;30(5):462-81. doi: 10.1016/j.rbmo.2015.01.013. PMID: 25769930.X-1

960. Desai VB, Guo XM, Xu X. Alterations in surgical technique after FDA statement on power morcellation. Am J Obstet Gynecol. 2015 May;212(5):685-7. doi: 10.1016/j.ajog.2015.02.027. PMID: 25735888.X-1, X-2

961. Farina-Perez LA. To morcellate, morcellator, morcellation. Actas Urol Esp. 2015 Jul-Aug;39(6):396-7. doi: 10.1016/j.acuro.2015.01.001. PMID: 25676526.X-1

962. Aitchison LP, Flint J, Nesbitt-Hawes E, et al. A feasibility study determining surgical ergonomics in a live surgical setting. J Minim Invasive Gynecol. 2015 May-Jun;22(4):626-30. doi: 10.1016/j.jmig.2015.01.022. PMID: 25638044.X-2, X-3, X-5

963. Parker W, Pritts E, Olive D. Risk of morcellation of uterine leiomyosarcomas in laparoscopic supracervical hysterectomy and laparoscopic myomectomy, a retrospective trial including 4791 women. J Minim Invasive Gynecol. 2015 May-Jun;22(4):696-7. doi: 10.1016/j.jmig.2015.01.015. PMID: 25623370.INCLUDE X-1

964. Bai DS, Chen P, Qian JJ, et al. Modified laparoscopic hepatectomy for hepatic hemangioma. Surg Endosc. 2015 Nov;29(11):3414-21. doi: 10.1007/s00464-014-4048-y. PMID: 25552235.X-2, X-3, X-5

965. Shokeir T. Safe vaginal uterine morcellation following total laparoscopic hysterectomy. Am J Obstet Gynecol. 2015 May;212(5):689. doi: 10.1016/j.ajog.2014.12.024. PMID: 25530593.INCLUDE X-1

966. Bhave Chittawar P, Franik S, Pouwer AW, et al. Minimally invasive surgical techniques versus open myomectomy for uterine fibroids. Cochrane Database Syst Rev. 2014(10):Cd004638. doi: 10.1002/14651858.CD004638.pub3. PMID: 25331441.X-1

967. Hamidouche A, Vincienne M, Thubert T, et al. [Operative hysteroscopy for myoma removal: Morcellation versus bipolar loop resection]. J Gynecol Obstet Biol Reprod (Paris). 2015 Sep;44(7):658-64. doi: 10.1016/j.jgyn.2014.09.006. PMID: 25287109.X-5

968. Bogani G, Serati M, Cromi A, et al. Risk of undiagnosed uterine malignancies at the time of robotic supracervical hysterectomy and sacrocolpopexy. Eur Urol. 2015 Feb;67(2):352. doi: 10.1016/j.eururo.2014.08.058. PMID: 25192969.INCLUDE X-5

969. Walters Haygood CL, Fauci JM, Huddleston-Colburn MK, et al. Outcomes of gynecologic oncology patients undergoing robotic-assisted laparoscopic procedures in a university setting. J Robot Surg. 2014 Sep;8(3):207-11. doi: 10.1007/s11701-014-0452-5. PMID: 27637679.X-2, X-3, X-5

970. Kongnyuy EJ, Wiysonge CS. Interventions to reduce haemorrhage during myomectomy for fibroids. Cochrane Database Syst Rev. 2014(8):Cd005355. doi: 10.1002/14651858.CD005355.pub5. PMID: 25125317.X-1

971. Gomez Sancha F, Rivera VC, Georgiev G, et al. Common trend: move to enucleation-Is there a case for GreenLight enucleation? Development and description of the technique. World J Urol. 2015 Apr;33(4):539-47. doi: 10.1007/s00345-014-1339-9. PMID: 24929643.X-2, X-3, X-5

972. Jiang G, Qian J, Yao J, et al. A new technique for laparoscopic splenectomy and azygoportal disconnection. Surg Innov. 2014 Jun;21(3):256-62. doi: 10.1177/1553350613492587. PMID: 23804998.X-2, X-3, X-5

973. Sparic R, Berisavac M, Buzadzic S, et al. Complications during cesarean delivery in a patient with two previous myomectomies. Acta Chir Iugosl. 2013;60(1):99-100. PMID: 24669572.X-3, X-4, X-5

974. Stitely ML, Bakri YN. Dilation of the vaginal cuff using the Bakri Postpartum Balloon to extract the large uterus at the time of robotic hysterectomy for endometrial carcinoma. J Robot Surg. 2011 Sep;5(3):215-6. doi: 10.1007/s11701-011-0260-0. PMID: 27637710.X-2, X-3, X-4, X-5

975. Jain N, Sahni P. Multiple Layer Closure of Myoma Bed in Laparoscopic Myomectomy. J Gynecol Endosc Surg. 2011 Jul-Dec;2(2):85-90. doi: 10.4103/0974-1216.114079. PMID: 26085750.X-5

976. Rebeles SA, Muntz HG, Wieneke-Broghammer C, et al. Robot-assisted total laparoscopic hysterectomy in obese and morbidly obese women. J Robot Surg. 2009 Oct;3(3):141. doi: 10.1007/s11701-009-0149-3. PMID: 27638370.X-2, X-4, X-5

977. Kongnyuy EJ, Wiysonge CS. Interventions to reduce haemorrhage during myomectomy for fibroids. Cochrane Database Syst Rev. 2009(3):Cd005355. doi: 10.1002/14651858.CD005355.pub3. PMID: 19588371.X-1, X-5

978. Duarte RJ, Denes FT, Cristofani LM, et al. Laparoscopic nephrectomy for wilms tumor after chemotherapy: initial experience. J Urol. 2004 Oct;172(4 Pt 1):1438-40. PMID: 15371863.X-2, X-3, X-4, X-5

979. Valla JS, Guilloneau B, Montupet P, et al. Retroperitoneal laparoscopic nephrectomy in children. Preliminary report of 18 cases. Eur Urol. 1996;30(4):490-3. PMID: 8977073.X-2, X-3, X-4, X-5

Appendix E. Risk of Bias Form and Summary

Table E-1. Risk of bias assessment form: KQ1 studies

Domain-Specific Question	Response
Selection Bias (SB)	
SB1. Was the allocation sequence generated adequately (e.g., random number table, computer generated randomization)? Inadequate methods of allocation include non-random assignment (e.g., by participant last name, day of the week).	Yes. The authors report an acceptable method of assigning participants to an intervention or control group.
	No. The authors report an inadequate method of assignment to intervention or control group.
	Not reported. The authors do not describe how participants were allocated to the intervention and control groups.
SB2. Was allocation adequately concealed (e.g., pharmacy-controlled, sealed envelopes)?	Yes. The authors used an adequate method of allocation was concealed.
	No. The authors did not use a method to conceal the allocation of participants to study arms or the allocation concealment was inadequate.
	Not reported. Concealment is not described in the methods or mentioned by the publication authors.
SB3. Were the intervention and comparison groups comparable at baseline? Note: If randomization and allocation concealment approaches were successful, the groups should be similar.	Yes. Baseline characteristics such as age, severity, and fibroid characteristics were similar between groups or differences between groups at baseline were minimal and likely due to chance.
	No. There were differences between groups that may be a potential source of bias.
Overall assessment of selection bias:	High
	Medium
	Low
Comments on sources of selection bias:	
Performance Bias (PB)	
PB1. Did authors describe allowable concurrent interventions or assess participants for use of concomitant interventions?	Yes
	No
	Not reported
PB2. Did authors assess adherence (i.e., fidelity) to the intended treatment (e.g., collected pill counts, supplied and reviewed a medication diary), surgical, or procedural protocol?	Yes
	No
	Not applicable
Overall assessment of performance bias:	High
	Medium
	Low
Comments on sources of performance bias:	
Reporting Bias	
RB1. Were the outcomes specified a priori?	Yes. Authors describe the outcomes and harms that would be assessed and reported.
	No. Authors do not describe prespecified outcomes.
RB2. Were all prespecified outcomes reported in the findings/results?	Yes. All prespecified outcomes were reported in the study publication.

Table E-1. Risk of bias assessment form: KQ1 studies, continued

Domain-Specific Question	Response
	No. One or more of the prespecified outcomes were not reported in the publication.
Overall assessment of reporting bias:	High
	Medium
	Low
Comments on sources of reporting bias:	
Attrition Bias (AB)	
AB1. Did authors adequately report the disposition of all randomized participants? Mark "yes" if there was no attrition (i.e., the number randomized equals the number reported in followup).	Yes. The authors described the number of participants who were analyzed and accounted for participants who were lost to follow-up and/or dropped out.
	No. The authors did not account for participants who did not complete the study.
Intervention LTF rate:	
Control LTF rate:	
Study LTF rate:	
AB2. Were characteristics of the lost-to-followup / drop-out group evaluated for differences with the study group?	Yes. Authors compare the loss-to-followup / drop-outs group to the whole group.
	No. Authors do not comment on the characteristics of the group lost to followup compared with the overall study population.
	Not applicable. Attrition was minimal or none.
AB3. Did authors use an intention-to-treat approach in analysis of outcomes?	Yes
	No
	Not reported
AB4. Were incomplete outcome data adequately addressed?	Yes. Authors used an appropriate method for missing data (e.g., imputation), the missing data was minimal and reasons were similar between groups, or there was no missing data.
	No. Authors did not address missing data, a substantial proportion of patients withdrew, or missing outcome data could have biased observed effect size.
	Not sure.
How did authors handle missing data?	
Overall assessment of attrition bias:	High
	Medium
	Low
Comments on sources of attrition bias:	
Detection Bias (DB)	
DB1. Was the intervention fully described?	Yes. The authors reported sufficient detail to allow replication of the intervention or the authors reference a treatment manual.
	No. The authors did not report sufficient detail to replicate the intervention.
DB2. Was the length of followup similar for all study groups for primary outcomes?	Yes
	No
	Not reported

Table E-1. Risk of bias assessment form: KQ1 studies, continued

Domain-Specific Question	Response
DB3. Were the primary outcomes coded by individuals blinded to the intervention status of the participants?	Yes. The outcome assessors were unaware of an individual participant's group assignment.
	No. The outcome assessors knew which group participants were assigned to.
	Not reported
DB4. Did authors use reliable and valid measures/tools to assess primary outcomes?	Yes. Outcomes were assesses using previously validated measure(s) or the authors establish the validity in the current publication.
	No. The outcomes were assessed using measures of uncertain validity and reliability.
	Not sure. There is not enough information to rate this criterion.
Overall assessment of detection bias:	High
	Medium
	Low
Comments on sources of detection bias:	
Other Bias (OB)	
OB1. Was a priori sample size calculation provided for the primary outcome? See http://www.ncbi.nlm.nih.gov/pmc/articles/PMC3409926/ for more information on estimating sample size for clinical studies.	Yes
	No
Overall assessment of other bias:	High
	Medium
	Low
Comments on sources of other bias:	
Risk of Bias for Individual Outcomes	
Risk of bias associated with specific outcome(s) of interest differs from the risk of bias assessments above?	Yes (or likely yes)
	No
	Unsure
Assess risk of bias for harm(s) reported in this study?	Yes
	No
	Unsure

Assessment of Overall Risk of Bias for Individual Studies

The team preselected individual questions to assess the risk of bias in randomized controlled trials from a list of design-specific criteria.[1] The team developed an appraisal form that included 16 questions across six domains:

- Selection Bias *(3 items)*
- Performance bias *(2 items)*
- Reporting bias *(2 items)*
- Attrition bias *(4 items)*
- Detection bias *(4 item)*
- Other bias *(1 item)*

Two team members independently assessed the risk of bias for each domain. Conflicts were reconciled through discussion. We used the cumulative assessments from the six domains to categorize studies as high risk of bias, medium risk of bias, or low risk of bias based on the following:

- Low risk of bias: low risk of bias for all domains OR low risk of bias in all domains except for masking of those conducting imaging when placebo was used or the individual conducting the original intervention was not involved in the imaging.
- Medium risk of bias: medium risk of bias for one or two domains OR unclear risk of bias for one or more domains, together with no known important limitation that could invalidate its results.
- High risk of bias: medium risk of bias for 3 or more domains OR high risk of in any domain

The overall risk of bias for the study was calculated from individual domain assessments:

- Low risk of bias = **Good** quality
- Medium risk of bias = **Fair** quality
- High risk of bias = **Poor** quality

Table E-2. Risk of bias assessment summary: KQ1 RCTs

Citation	Participants	Selection	Performance	Reporting	Attrition	Detection	Other	Low Count	Medium Count	High Count	Overall Low	Overall Medium	Overall High
Alessandri F et al. (2006)[2]	148	L	L	L	H	M	M	3	2	1			●
Ardovino M et al. (2013)[3]	170	M	H	L	M	M	M	1	4	1			●
Benassi L et al. (2002)[4]	119	L	L	L	L	M	L	5	1	0	●		
Bilhim T et al. (2011)[5]	160	M	M	M	M	M	H	0	5	1			●
Broekmans FJ et al. (1996)[6]	27	H	H	L	H	M	H	1	1	4			●
Brucker SY et al. (2014)[7]	51	M	L	H	M	M	M	1	4	1			●
Carbonell Esteve JL et al. (2008)[8]	100	M	M	L	L	L	L	4	2	0		●	
Carbonell JL et al. (2013)[9]	220	M	L	L	H	M	L	3	2	1			●
Carbonell JL et al. (2013)[10]	70	L	L	L	M	L	L	5	1	0		●	
Carr BR et al. (1993)[11]	16	H	H	L	L	L	H	3	0	3			●
Casini ML et al. (2006)[12]	181	H	H	L	M	M	H	1	2	3			●
Chwalisz K et al. (2007)[13]	129	L	L	L	L	M	L	5	1	0	●		
Cicinelli E et al. (2009)[14]	80	M	M	L	L	M	H	2	3	1			●
Costantini S et al. (1990)[15]	42	H	H	L	L	L	H	3	0	3			●
Cunningham E et al. (2008)[16]	16	L	L	L	H	L	M	4	1	1			●
Donnez J et al. (2012)[17]	307	L	L	L	L	L	L	6	0	0	●		

Table E-2. Risk of bias assessment summary: KQ1 RCTs, continued

Citation	Participants	Selection	Performance	Reporting	Attrition	Detection	Other	Low Count	Medium Count	High Count	Overall Low	Overall Medium	Overall High
Donnez J et al. (2012)[18]	242	L	L	L	L	L	L	6	0	0	●		
Donnez J et al. (2015)[19]	451	L	M	L	L	L	L	5	1	0		●	
Edwards RD et al. (2007)[20]	157	L	L	L	L	L	L	6	0	0	●		
Eisinger SH et al. (2003)[21]	40	L	M	L	L	M	L	4	2	0		●	
Esteve JL et al. (2012)[22]	176	L	L	L	M	L	L	5	1	0		●	
Esteve JL et al. (2013)[23]	124	M	M	L	H	L	L	3	2	1			●
Fedele L et al. (1991)[24]	42	M	M	L	M	M	M	1	5	0			●
Fedele L et al. (2000)[25]	38	M	M	L	L	M	M	2	4	0			●
Ferrari MM et al. (2000)[26]	62	L	L	L	L	L	M	5	1	0		●	
Fiscella K et al. (2006)[27]	42	M	L	L	L	L	L	5	1	0		●	
Friedman AJ et al. (1988)[28]	16	H	M	L	L	M	M	2	3	1			●
Friedman AJ et al. (1989)[29]	38	M	L	L	L	L	M	4	2	0		●	
Friedman AJ et al. (1991)[30]	128	M	L	L	H	M	M	2	3	1			●
Friedman AJ et al. (1993)[31]	51	H	H	L	H	M	H	1	1	4			●
Gregoriou O et al. (1997)[32]	40	H	H	L	L	M	H	2	1	3			●
Hald K et al. (2007)[33]	66	L	L	L	M	L	L	5	1	0		●	
Hazlina N et al. (2005)[34]	35	M	M	L	M	L	L	3	3	0			●
Hehenkamp WJ et al. (2005)[35]	177	L	L	L	L	L	L	6	0	0	●		
Hwang JL et al. (2002)[36]	90	L	L	L	L	M	L	5	1	0	●		
Jacoby VL et al. (2016)	20	L	L	L	L	L	M	5	1	0		●	
Jiang N et al. (2014)[37]	80	H	M	L	L	M	H	2	2	2			●
Jirecek S et al. (2004)[38]	25	M	M	L	M	M	M	1	5	0			●
Jun F et al. (2012)[39]	127	M	L	L	L	M	M	3	3	0			●
Levens E et al. (2008)[40]	22	L	M	L	M	L	H	3	2	1			●
Liu M et al. (2011)[41]	359	M	M	L	M	L	L	3	3	0			●
Macnaught G et al. (2016)	20	H	L	L	L	L	M	4	1	1			●
Mais V et al. (1996)[42]	40	L	L	L	L	M	M	4	2	0		●	
Manyonda IT et al. (2012)[43]	163	L	L	L	M	L	L	5	1	0		●	
Mara M et al. (2006)[44]	63	L	L	L	L	M	M	4	2	0		●	
Melli MS et al. (2007)[45]	50	M	M	L	M	H	M	1	4	1			●
Meng X et al. (2010)[46]	100	H	M	L	M	M	H	1	3	2			●
Morris EP et al. (2008)[47]	75	M	M	L	M	L	L	3	3	0			●

Table E-2. Risk of bias assessment summary: KQ1 RCTs, continued

Citation	Participants	Selection	Performance	Reporting	Attrition	Detection	Other	Low Count	Medium Count	High Count	Overall Low	Overall Medium	Overall High
Nieman LK et al. (2011)[48]	42	L	M	L	L	L	H	4	1	1			●
Orsi F et al. (2015)[49]	33	M	M	L	M	M	H	1	4	1			●
Palomba S et al. (1998)[50]	50	M	M	L	L	L	L	4	2	0		●	
Palomba S et al. (2001)[51]	70	L	M	L	M	L	L	4	2	0		●	
Palomba S et al. (2002)[52]	100	L	L	L	L	M	L	5	1	0	●		
Palomba S et al. (2002)[53]	90	L	L	L	M	L	L	5	1	0		●	
Palomba S et al. (2007)[54]	136	L	L	L	L	L	M	5	1	0		●	
Palomba S et al. (2008)[55]	110	L	M	L	L	M	H	3	2	1			●
Parazzini F et al. (1999)[56]	72	H	M	L	H	M	M	1	3	2			●
Parsanezhad ME et al. (2010)[57]	70	M	M	L	M	L	H	2	3	1			●
Pinto I et al. (2003)[58]	57	M	L	L	M	L	L	4	2	0		●	
Rossetti A et al. (2001)[59]	81	L	L	L	L	L	M	5	1	0		●	
Ruuskanen A et al. (2010)[60]	57	M	L	L	L	M	H	3	2	1			●
Sadan O et al. (2001)[61]	20	M	M	L	L	M	M	2	4	0			●
Sayyah-Melli M et al. (2009)[62]	60	M	M	L	H	M	H	1	3	2			●
Scialli AR et al. (1995)[63]	41	M	M	L	M	H	M	1	4	1			●
Seracchioli R et al. (2000)[64]	131	L	L	L	M	M	L	4	2	0		●	
Seracchioli R et al. (2002)[65]	122	L	L	L	L	M	H	4	1	1			●
Sesti F et al. (2008)[66]	80	L	L	L	L	L	L	6	0	0	●		
Sesti F et al. (2008)[67]	100	L	L	L	L	L	L	6	0	0	●		
Sesti F et al. (2014)[68]	108	L	L	L	L	L	L	6	0	0	●		
Shlansky-Goldberg RD et al. (2014)[69]	60	L	L	L	L	L	L	6	0	0	●		
Silva-Filho AL et al. (2006)[70]	60	M	M	L	L	L	H	3	2	1			●
Simsek T et al. (2002)[71]	46	H	M	H	H	M	H	0	2	4			●
Siskin GP et al. (2008)[72]	53	L	L	L	L	L	L	6	0	0	●		
Song YG et al. (2013)[73]	60	M	L	L	L	M	L	4	2	0		●	
Soriano D et al. (2001)[74]	80	M	L	L	L	L	M	4	2	0		●	
Soysal ME et al. (2001)[75]	96	L	L	L	L	L	M	5	1	0		●	
Spies JB et al. (2004)[76]	100	L	L	L	M	M	L	4	2	0		●	
Spies JB et al. (2005)[77]	36	L	L	L	L	L	L	6	0	0	●		
Takeuchi H, Kobori H, Kikuchi I, et al. (2000)[78]	67	H	L	L	H	M	H	2	1	3			●

Table E-2. Risk of bias assessment summary: KQ1 RCTs, continued

Citation	Participants	Selection	Performance	Reporting	Attrition	Detection	Other	Low Count	Medium Count	High Count	Overall Low	Overall Medium	Overall High
Tan J et al. (2008)[79]	52	L	L	L	L	M	L	5	1	0	●		
Tan J et al. (2009)[80]	80	L	L	L	L	L	L	6	0	0	●		
Tosun AK et al. (2014)[81]	60	H	H	M	H	M	H	0	2	4			●
Vercellino G et al. (2012)[82]	166	L	H	L	M	M	L	3	2	1			●
Vilos GA et al. (2006)[83]	26	L	L	L	H	L	H	4	0	2			●
Wang JJ et al. (2011)[84]	384	L	L	L	L	L	L	6	0	0	●		
Wang X et al. (2013)[85]	110	M	L	L	M	L	M	3	3	0			●
Wang X et al. (2015)	130	M	H	L	L	M	M	2	3	1			●
Watanabe Y et al. (1992)[86]	41	M	M	L	M	M	H	1	4	1			●
Worthington-Kirsch RL et al. (2011)[87]	46	M	L	L	M	L	L	4	2	0		●	
Yang Z et al. (2014)[88]	40	M	M	L	M	M	L	2	4	0			●
Yen YK et al. (2001)[89]	81	H	L	L	M	M	M	2	3	1			●
Yen YK et al. (2002)[90]	61	H	L	L	M	M	M	2	3	1			●
Yu SC et al. (2011)[91]	60	L	L	L	L	L	L	6	0	0	●		
Yuk JS et al. (2015)	92	M	M	L	M	M	L	2	6	0			●
Zhao F et al. (2011)[92]	105	H	M	L	M	M	M	1	4	1			●

Notes: Does not include related publications. Does not include: Eder S et al. (2013)[93] (pooled analysis). Abbreviations: L=low; M=medium; H=high; N=number of participants.

Table E-3. Overall risk of bias

Overall Risk of Bias	Citation	Selection	Performance	Reporting	Attrition	Detection	Other	Participants
Low (18 Studies; 2,334)	Benassi L et al. (2002)[4]	L	L	L	L	M	L	119
	Chwalisz K et al. (2007)[13]	L	L	L	L	M	L	129
	Donnez J et al. (2012)[17]	L	L	L	L	L	L	307
	Donnez J et al. (2012)[18]	L	L	L	L	L	L	242
	Edwards RD et al. (2007)[20]	L	L	L	M	L	L	157
	Hehenkamp WJ et al. (2005)[35]	L	L	L	L	L	L	177
	Hwang JL et al. (2002)[36]	L	L	L	L	M	L	90
	Palomba S et al. (2002)[52]	L	L	L	L	M	L	100
	Sesti F et al. (2008)[66]	L	L	L	L	L	L	80
	Sesti F et al. (2008)[67]	L	L	L	L	L	L	100

Table E-3. Overall risk of bias, continued

Overall Risk of Bias	Citation	Selection	Performance	Reporting	Attrition	Detection	Other	Participants
	Sesti F et al. (2014)[68]	L	L	L	L	L	L	108
	Shlansky-Goldberg RD et al. (2014)[69]	L	L	L	L	L	L	60
	Siskin GP et al. (2008)[72]	L	L	L	L	L	L	53
	Spies JB et al. (2005)[77]	L	L	L	L	L	L	36
	Tan J et al. (2008)[79]	L	L	L	L	M	L	52
	Tan J et al. (2009)[80]	L	L	L	L	L	L	80
	Wang JJ et al. (2011)[84]	L	L	L	L	L	L	384
	Yu SC et al. (2011)[91]	L	L	L	L	L	L	60
Medium (25 Studies; 2,328)	Carbonell Esteve JL et al. (2008)[8]	M	M	L	L	L	L	100
	Carbonell JL et al. (2013)[10]	L	L	L	M	L	L	70
	Donnez J et al. (2015)[19]	L	M	L	L	L	L	451
	Eisinger SH et al. (2003)[21]	L	M	L	L	M	L	40
	Esteve JL et al. (2012)[22]	L	L	L	M	L	L	176
	Ferrari MM et al. (2000)[26]	L	L	L	L	L	M	62
	Fiscella K et al. (2006)[27]	M	L	L	L	L	L	42
	Friedman AJ et al. (1989)[29]	M	L	L	L	L	M	38
	Hald K et al. (2007)[33]	L	L	L	M	L	L	66
	Jacoby VL et al. (2016)	L	L	L	L	L	M	20
	Mais V et al. (1996)[42]	L	L	L	L	M	M	40
	Manyonda IT et al. (2012)[43]	L	L	L	M	L	L	163
	Mara M et al. (2006)[44]	L	L	L	L	M	M	63
	Palomba S et al. (1998)[50]	M	M	L	L	L	L	50
	Palomba S et al. (2001)[51]	L	M	L	M	L	L	70
	Palomba S et al. (2002)[53]	L	L	L	M	L	L	90
	Palomba S et al. (2007)[54]	L	L	L	L	L	M	136
	Pinto I et al. (2003)[58]	M	L	L	M	L	L	57
	Rossetti A et al. (2001)[59]	L	L	L	L	L	M	81
	Seracchioli R et al. (2000)[64]	L	L	L	M	M	L	131
	Song YG et al. (2013)[73]	M	L	L	L	M	L	60
	Soriano D et al. (2001)[74]	M	L	L	L	L	M	80
	Soysal ME et al. (2001)[75]	L	L	L	L	L	M	96
	Spies JB et al. (2004)[76]	L	L	L	M	M	L	100
	Worthington-Kirsch RL et al. (2011)[87]	M	L	L	M	L	L	46
High (52 Studies, 4,155)	Alessandri F et al. (2006)[2]	L	L	L	H	M	M	148
	Ardovino M et al. (2013)[3]	M	H	L	M	M	M	170
	Bilhim T et al. (2011)[5]	M	M	M	M	M	H	160
	Broekmans FJ et al. (1996)[6]	H	H	L	H	M	H	27
	Brucker SY et al. (2014)[7]	M	L	H	M	M	M	51
	Carbonell JL et al. (2013)[9]	M	L	L	H	M	L	220

Overall Risk of Bias	Citation	Selection	Performance	Reporting	Attrition	Detection	Other	Participants
	Carr BR et al. (1993)[11]	H	H	L	L	L	H	16

Table E-3. Overall risk of bias, continued

Overall Risk of Bias	Citation	Selection	Performance	Reporting	Attrition	Detection	Other	Participants
	Casini ML et al. (2006)[12]	H	H	L	M	M	H	181
	Cicinelli E et al. (2009)[14]	M	M	L	L	M	H	80
	Costantini S et al. (1990)[15]	H	H	L	L	L	H	42
	Cunningham E et al. (2008)[16]	L	L	L	H	L	M	16
	Esteve JL et al. (2013)[23]	M	M	L	H	L	L	124
	Fedele L et al. (1991)[24]	M	M	L	M	M	M	42
	Fedele L et al. (2000)[25]	M	M	L	L	M	M	38
	Friedman AJ et al. (1988)[28]	H	M	L	L	M	M	16
	Friedman AJ et al. (1991)[30]	M	L	L	H	M	M	128
	Friedman AJ et al. (1993)[31]	H	H	L	H	M	H	51
	Gregoriou O et al. (1997)[32]	H	H	L	L	M	H	40
	Hazlina N et al. (2005)[34]	M	M	L	M	L	L	35
	Jiang N et al. (2014)[37]	H	M	L	L	M	H	80
	Jirecek S et al. (2004)[38]	M	M	L	M	M	M	25
	Jun F et al. (2012)[39]	M	L	L	L	M	M	127
	Levens E et al. (2008)[40]	L	M	L	M	L	H	22
	Liu M et al. (2011)[41]	M	M	L	M	L	L	359
	Macnaught G et al. (2016)	H	L	L	L	L	M	20
	Melli MS et al. (2007)[45]	M	M	L	M	H	M	50
	Meng X et al. (2010)[46]	H	M	L	M	M	H	100
	Morris EP et al. (2008)[47]	M	M	L	M	L	L	75
	Nieman LK et al. (2011)[48]	L	M	L	L	L	H	42
	Orsi F et al. (2015)[49]	M	M	L	M	M	H	33
	Palomba S et al. (2008)[55]	L	M	L	L	M	H	110
	Parazzini F et al. (1999)[56]	H	M	L	H	M	M	72
	Parsanezhad ME et al. (2010)[57]	M	M	L	M	L	H	70
	Ruuskanen A et al. (2010)[60]	M	L	L	L	M	H	57
	Sadan O et al. (2001)[61]	M	M	L	L	M	M	20
	Sayyah-Melli M et al. (2009)[62]	M	M	L	H	M	H	60
	Scialli AR et al. (1995)[63]	M	M	L	M	H	M	41
	Seracchioli R et al. (2002)[65]	L	L	L	L	M	H	122
	Silva-Filho AL et al. (2006)[70]	M	M	L	L	L	H	60

Overall Risk of Bias	Citation	Selection	Performance	Reporting	Attrition	Detection	Other	Participants
	Simsek T et al. (2002)[71]	H	M	H	H	M	H	46
	Takeuchi H, Kobori H, Kikuchi I, et al. (2000)[78]	H	L	L	H	M	H	67
	Tosun AK et al. (2014)[81]	H	H	M	H	M	H	60
	Vercellino G et al. (2012)[82]	L	H	L	M	M	L	166
	Vilos GA et al. (2006)[83]	L	L	L	H	L	H	26
	Wang X et al. (2013)[85]	M	L	L	M	L	M	110
	Wang X et al. (2015)	M	H	L	L	M	M	130
	Watanabe Y et al. (1992)[86]	M	M	L	M	M	H	41

Table E-3. Overall risk of bias, continued

Overall Risk of Bias	Citation	Selection	Performance	Reporting	Attrition	Detection	Other	Participants
	Yang Z et al. (2014)[88]	M	M	L	M	M	L	40
	Yen YK et al. (2001)[89]	H	L	L	M	M	M	81
	Yen YK et al. (2002)[90]	H	L	L	M	M	M	61
	Yuk JS et al. (2015)	M	M	L	M	M	L	92
	Zhao F et al. (2011)[92]	H	M	L	M	M	M	105

References

1. Viswanathan M, Ansari MT, Berkman ND, et al. Assessing the Risk of Bias of Individual Studies in Systematic Reviews of Health Care Interventions. AHRQ Publication No. 12-EHC047-EF. Rockville MD: Agency for Healthcare Research and Quality; March 2012. www.effectivehealthcare.ahrq.gov/
2. Alessandri F, Lijoi D, Mistrangelo E, et al. Randomized study of laparoscopic versus minilaparotomic myomectomy for uterine myomas. J Minim Invasive Gynecol. 2006 Mar-Apr;13(2):92-7. doi: 10.1016/j.jmig.2005.11.008. PMID: 16527709.
3. Ardovino M, Ardovino I, Castaldi MA, et al. Minilaparoscopic myomectomy: a mini-invasive technical variant. J Laparoendosc Adv Surg Tech A. 2013 Oct;23(10):871-5. doi: 10.1089/lap.2013.0037. PMID: 23992206.
4. Benassi L, Rossi T, Kaihura CT, et al. Abdominal or vaginal hysterectomy for enlarged uteri: a randomized clinical trial. Am J Obstet Gynecol. 2002 Dec;187(6):1561-5. PMID: 12501064.
5. Bilhim T, Pisco JM, Duarte M, et al. Polyvinyl alcohol particle size for uterine artery embolization: a prospective randomized study of initial use of 350-500 mum particles versus initial use of 500-700 mum particles. J Vasc Interv Radiol. 2011 Jan;22(1):21-7. doi: 10.1016/j.jvir.2010.09.018. PMID: 21106390.
6. Broekmans FJ, Hompes PG, Heitbrink MA, et al. Two-step gonadotropin-releasing hormone agonist treatment of uterine leiomyomas: standard-dose therapy followed by reduced-dose therapy. Am J Obstet Gynecol. 1996 Nov;175(5):1208-16. PMID: 8942490.
7. Brucker SY, Hahn M, Kraemer D, et al. Laparoscopic radiofrequency volumetric thermal ablation of fibroids versus laparoscopic myomectomy. Int J Gynaecol Obstet. 2014 Jun;125(3):261-5. doi: 10.1016/j.ijgo.2013.11.012. PMID: 24698202.
8. Carbonell Esteve JL, Acosta R, Heredia B, et al. Mifepristone for the treatment of uterine leiomyomas: a randomized controlled trial. Obstet Gynecol. 2008 Nov;112(5):1029-36. doi: 10.1097/AOG.0b013e31818aa930. PMID: 18978102.
9. Carbonell JL, Acosta R, Perez Y, et al. Treatment of Uterine Myoma with 2.5 or 5 mg Mifepristone Daily during 3 Months with 9 Months Posttreatment Followup: Randomized Clinical Trial. ISRN Obstet Gynecol. 2013;2013:649030. doi: 10.1155/2013/649030. PMID: 23984082.
10. Carbonell JL, Acosta R, Perez Y, et al. Safety and effectiveness of different dosage of mifepristone for the treatment of uterine fibroids: a double-blind randomized clinical trial. Int J Womens Health. 2013;5:115-24. doi: 10.2147/ijwh.s33125. PMID: 23658500.
11. Carr BR, Marshburn PB, Weatherall PT, et al. An evaluation of the effect of gonadotropin-releasing hormone analogs and medroxyprogesterone acetate on uterine leiomyomata volume by magnetic resonance imaging: a prospective, randomized, double blind, placebo-controlled, crossover trial. J Clin Endocrinol Metab. 1993 May;76(5):1217-23. doi: 10.1210/jcem.76.5.8496313. PMID: 8496313.
12. Casini ML, Rossi F, Agostini R, et al. Effects of the position of fibroids on fertility. Gynecol Endocrinol. 2006 Feb;22(2):106-9. doi: 10.1080/09513590600604673. PMID: 16603437.

13. Chwalisz K, Larsen L, Mattia-Goldberg C, et al. A randomized, controlled trial of asoprisnil, a novel selective progesterone receptor modulator, in women with uterine leiomyomata. Fertil Steril. 2007 Jun;87(6):1399-412. doi: 10.1016/j.fertnstert.2006.11.094. PMID: 17307170.

14. Cicinelli E, Tinelli R, Colafiglio G, et al. Laparoscopy vs minilaparotomy in women with symptomatic uterine myomas: a prospective randomized study. J Minim Invasive Gynecol. 2009 Jul-Aug;16(4):422-6. doi: 10.1016/j.jmig.2009.03.011. PMID: 19573818.

15. Costantini S, Anserini P, Valenzano M, et al. Luteinizing hormone-releasing hormone analog therapy of uterine fibroid: analysis of results obtained with buserelin administered intranasally and goserelin administered subcutaneously as a monthly depot. Eur J Obstet Gynecol Reprod Biol. 1990 Oct;37(1):63-9. PMID: 2142921.

16. Cunningham E, Barreda L, Ngo M, et al. Uterine artery embolization versus occlusion for uterine leiomyomas: a pilot randomized clinical trial. J Minim Invasive Gynecol. 2008 May-Jun;15(3):301-7. doi: 10.1016/j.jmig.2008.01.011. PMID: 18439501.

17. Donnez J, Tomaszewski J, Vazquez F, et al. Ulipristal acetate versus leuprolide acetate for uterine fibroids. N Engl J Med. 2012 Feb 2;366(5):421-32. doi: 10.1056/NEJMoa1103180. PMID: 22296076.

18. Donnez J, Tatarchuk TF, Bouchard P, et al. Ulipristal acetate versus placebo for fibroid treatment before surgery. N Engl J Med. 2012 Feb 2;366(5):409-20. doi: 10.1056/NEJMoa1103182. PMID: 22296075.

19. Donnez J, Hudecek R, Donnez O, et al. Efficacy and safety of repeated use of ulipristal acetate in uterine fibroids. Fertil Steril. 2015 Feb;103(2):519-27.e3. doi: 10.1016/j.fertnstert.2014.10.038. PMID: 25542821.

20. Edwards RD, Moss JG, Lumsden MA, et al. Uterine-artery embolization versus surgery for symptomatic uterine fibroids. N Engl J Med. 2007 Jan 25;356(4):360-70. doi: 10.1056/NEJMoa062003. PMID: 17251532.

21. Eisinger SH, Meldrum S, Fiscella K, et al. Low-dose mifepristone for uterine leiomyomata. Obstet Gynecol. 2003 Feb;101(2):243-50. PMID: 12576246.

22. Esteve JL, Acosta R, Perez Y, et al. Treatment of uterine myoma with 5 or 10mg mifepristone daily during 6 months, post-treatment evolution over 12 months: double-blind randomised clinical trial. Eur J Obstet Gynecol Reprod Biol. 2012 Apr;161(2):202-8. doi: 10.1016/j.ejogrb.2011.12.018. PMID: 22269473.

23. Esteve JL, Acosta R, Perez Y, et al. Mifepristone versus placebo to treat uterine myoma: a double-blind, randomized clinical trial. Int J Womens Health. 2013;5:361-9. doi: 10.2147/ijwh.s42770. PMID: 23843709.

24. Fedele L, Bianchi S, Baglioni A, et al. Intranasal buserelin versus surgery in the treatment of uterine leiomyomata: long-term follow-up. Eur J Obstet Gynecol Reprod Biol. 1991 Jan 4;38(1):53-7. PMID: 1899079.

25. Fedele L, Bianchi S, Raffaelli R, et al. A randomized study of the effects of tibolone and transdermal estrogen replacement therapy in postmenopausal women with uterine myomas. Eur J Obstet Gynecol Reprod Biol. 2000 Jan;88(1):91-4. PMID: 10659924.

26. Ferrari MM, Berlanda N, Mezzopane R, et al. Identifying the indications for laparoscopically assisted vaginal hysterectomy: a prospective, randomised comparison with abdominal hysterectomy in patients with symptomatic uterine fibroids. Bjog. 2000 May;107(5):620-5. PMID: 10826576.

27. Fiscella K, Eisinger SH, Meldrum S, et al. Effect of mifepristone for symptomatic leiomyomata on quality of life and uterine size: a randomized controlled trial. Obstet Gynecol. 2006 Dec;108(6):1381-7. doi: 10.1097/01.AOG.0000243776.23391.7b. PMID: 17138770.

28. Friedman AJ, Barbieri RL, Doubilet PM, et al. A randomized, double-blind trial of a gonadotropin releasing-hormone agonist (leuprolide) with or without medroxyprogesterone acetate in the treatment of leiomyomata uteri. Fertil Steril. 1988 Mar;49(3):404-9. PMID: 2963759.

29. Friedman AJ, Harrison-Atlas D, Barbieri RL, et al. A randomized, placebo-controlled, double-blind study evaluating the efficacy of leuprolide acetate depot in the treatment of uterine leiomyomata. Fertil Steril. 1989 Feb;51(2):251-6. PMID: 2492232.

30. Friedman AJ, Hoffman DI, Comite F, et al. Treatment of leiomyomata uteri with leuprolide acetate depot: a double-blind, placebo-controlled, multicenter study. The Leuprolide Study Group. Obstet Gynecol. 1991 May;77(5):720-5. PMID: 1901638.

31. Friedman AJ, Daly M, Juneau-Norcross M, et al. A prospective, randomized trial of gonadotropin-releasing hormone agonist plus estrogen-progestin or progestin "add-back" regimens for women with leiomyomata uteri. J Clin Endocrinol Metab. 1993 Jun;76(6):1439-45. doi: 10.1210/jcem.76.6.8501148. PMID: 8501148.

32. Gregoriou O, Vitoratos N, Papadias C, et al. Effect of tibolone on postmenopausal women with myomas. Maturitas. 1997 Jun;27(2):187-91. PMID: 9255754.

33. Hald K, Klow NE, Qvigstad E, et al. Laparoscopic occlusion compared with embolization of uterine vessels: a randomized controlled trial. Obstet Gynecol. 2007 Jan;109(1):20-7. doi: 10.1097/01.aog.0000249602.39339.31. PMID: 17197583.

34. Nik Hazlina NH, I MP, Nor Aliza AG, et al. Clinical study to compare the efficacy and adverse effects of Nona Roguy herbal formulation and gonadotrophin releasing hormone agonist (GnRH) in the treatment of uterine fibroids. International Medical Journal. 2005 December;12(4):295-302. PMID: 2006015151.

35. Hehenkamp WJ, Volkers NA, Donderwinkel PF, et al. Uterine artery embolization versus hysterectomy in the treatment of symptomatic uterine fibroids (EMMY trial): peri- and postprocedural results from a randomized controlled trial. Am J Obstet Gynecol. 2005 Nov;193(5):1618-29. doi: 10.1016/j.ajog.2005.05.017. PMID: 16260201.

36. Hwang JL, Seow KM, Tsai YL, et al. Comparative study of vaginal, laparoscopically assisted vaginal and abdominal hysterectomies for uterine myoma larger than 6 cm in diameter or uterus weighing at least 450 g: a prospective randomized study. Acta Obstet Gynecol Scand. 2002 Dec;81(12):1132-8. PMID: 12519109.

37. Jiang N, Xie B, Zhang X, et al. Enhancing ablation effects of a microbubble-enhancing contrast agent ("SonoVue") in the treatment of uterine fibroids with high-intensity focused ultrasound: a randomized controlled trial. Cardiovasc Intervent Radiol. 2014 Oct;37(5):1321-8. doi: 10.1007/s00270-013-0803-z. PMID: 24549267.

38. Jirecek S, Lee A, Pavo I, et al. Raloxifene prevents the growth of uterine leiomyomas in premenopausal women. Fertil Steril. 2004 Jan;81(1):132-6. PMID: 14711556.

39. Jun F, Yamin L, Xinli X, et al. Uterine artery embolization versus surgery for symptomatic uterine fibroids: a randomized controlled trial and a meta-analysis of the literature. Arch Gynecol Obstet. 2012 May;285(5):1407-13. doi: 10.1007/s00404-011-2065-9. PMID: 22048783.

40. Levens ED, Potlog-Nahari C, Armstrong AY, et al. CDB-2914 for uterine leiomyomata treatment: a randomized controlled trial. Obstet Gynecol. 2008 May;111(5):1129-36. doi: 10.1097/AOG.0b013e3181705d0e. PMID: 18448745.

41. Liu M, Cheng Z, Zhu Y, et al. Prospective comparison of laparoscopic uterine artery occlusion plus myomectomy with classic intrafascial supracervical hysterectomy for symptomatic fibroid treatment: differences in post-operative quality-of-life measures. Eur J Obstet Gynecol Reprod Biol. 2011 Mar;155(1):79-84. doi: 10.1016/j.ejogrb.2010.10.022. PMID: 21216518.

42. Mais V, Ajossa S, Guerriero S, et al. Laparoscopic versus abdominal myomectomy: a prospective, randomized trial to evaluate benefits in early outcome. Am J Obstet Gynecol. 1996 Feb;174(2):654-8. PMID: 8623802.

43. Manyonda IT, Bratby M, Horst JS, et al. Uterine artery embolization versus myomectomy: impact on quality of life--results of the FUME (Fibroids of the Uterus: Myomectomy versus Embolization) Trial. Cardiovasc Intervent Radiol. 2012 Jun;35(3):530-6. doi: 10.1007/s00270-011-0228-5. PMID: 21773858.

44. Mara M, Fucikova Z, Maskova J, et al. Uterine fibroid embolization versus myomectomy in women wishing to preserve fertility: preliminary results of a randomized controlled trial. Eur J Obstet Gynecol Reprod Biol. 2006 Jun 1;126(2):226-33. doi: 10.1016/j.ejogrb.2005.10.008. PMID: 16293363.

45. Melli MS, Farzadi L, Madarek EO. Comparison of the effect of gonadotropin-releasing hormone analog (Diphereline) and Cabergoline (Dostinex) treatment on uterine myoma regression. Saudi Med J. 2007 Mar;28(3):445-50. PMID: 17334477.

46. Meng X, He G, Zhang J, et al. A comparative study of fibroid ablation rates using radio frequency or high-intensity focused ultrasound. Cardiovasc Intervent Radiol. 2010 Aug;33(4):794-9. doi: 10.1007/s00270-010-9909-8. PMID: 20544227.

47. Morris EP, Rymer J, Robinson J, et al. Efficacy of tibolone as "add-back therapy" in conjunction with a gonadotropin-releasing hormone analogue in the treatment of uterine fibroids. Fertil Steril. 2008 Feb;89(2):421-8. doi: 10.1016/j.fertnstert.2007.02.064. PMID: 17572410.

48. Nieman LK, Blocker W, Nansel T, et al. Efficacy and tolerability of CDB-2914 treatment for symptomatic uterine fibroids: a randomized, double-blind, placebo-controlled, phase IIb study. Fertil Steril. 2011 Feb;95(2):767-72.e1-2. doi: 10.1016/j.fertnstert.2010.09.059. PMID: 21055739.

49. Orsi F, Monfardini L, Bonomo G, et al. Ultrasound guided high intensity focused ultrasound (USgHIFU) ablation for uterine fibroids: Do we need the microbubbles? Int J Hyperthermia. 2015 Mar 11:1-7. doi: 10.3109/02656736.2015.1004134. PMID: 25758436.

50. Palomba S, Affinito P, Tommaselli GA, et al. A clinical trial of the effects of tibolone administered with gonadotropin-releasing hormone analogues for the treatment of uterine leiomyomata. Fertil Steril. 1998 Jul;70(1):111-8. PMID: 9660431.

51. Palomba S, Sammartino A, Di Carlo C, et al. Effects of raloxifene treatment on uterine leiomyomas in postmenopausal women. Fertil Steril. 2001 Jul;76(1):38-43. PMID: 11438317.

52. Palomba S, Russo T, Orio F, Jr., et al. Effectiveness of combined GnRH analogue plus raloxifene administration in the treatment of uterine leiomyomas: a prospective, randomized, single-blind, placebo-controlled clinical trial. Hum Reprod. 2002 Dec;17(12):3213-9. PMID: 12456626.

53. Palomba S, Orio F, Jr., Morelli M, et al. Raloxifene administration in premenopausal women with uterine leiomyomas: a pilot study. J Clin Endocrinol Metab. 2002 Aug;87(8):3603-8. doi: 10.1210/jcem.87.8.8747. PMID: 12161482.

54. Palomba S, Zupi E, Falbo A, et al. A multicenter randomized, controlled study comparing laparoscopic versus minilaparotomic myomectomy: reproductive outcomes. Fertil Steril. 2007 Oct;88(4):933-41. doi: 10.1016/j.fertnstert.2006.12.047. PMID: 17434505.

55. Palomba S, Orio F, Jr., Falbo A, et al. Tibolone reverses the cognitive effects caused by leuprolide acetate administration, improving mood and quality of life in patients with symptomatic uterine leiomyomas. Fertil Steril. 2008 Jul;90(1):165-73. doi: 10.1016/j.fertnstert.2007.05.061. PMID: 18001721.

56. Parazzini F, Bortolotti A, Chiantera V, et al. Goserelin acetate to avoid hysterectomy in pre-menopausal women with fibroids requiring surgery. Eur J Obstet Gynecol Reprod Biol. 1999 Nov;87(1):31-3. PMID: 10579613.

57. Parsanezhad ME, Azmoon M, Alborzi S, et al. A randomized, controlled clinical trial comparing the effects of aromatase inhibitor (letrozole) and gonadotropin-releasing hormone agonist (triptorelin) on uterine leiomyoma volume and hormonal status. Fertil Steril. 2010 Jan;93(1):192-8. doi: 10.1016/j.fertnstert.2008.09.064. PMID: 19135657.

58. Pinto I, Chimeno P, Romo A, et al. Uterine fibroids: uterine artery embolization versus abdominal hysterectomy for treatment--a prospective, randomized, and controlled clinical trial. Radiology. 2003 Feb;226(2):425-31. doi: 10.1148/radiol.2262011716. PMID: 12563136.

59. Rossetti A, Sizzi O, Soranna L, et al. Long-term results of laparoscopic myomectomy: recurrence rate in comparison with abdominal myomectomy. Hum Reprod. 2001 Apr;16(4):770-4. PMID: 11278231.

60. Ruuskanen A, Hippelainen M, Sipola P, et al. Uterine artery embolisation versus hysterectomy for leiomyomas: primary and 2-year follow-up results of a randomised prospective clinical trial. Eur Radiol. 2010 Oct;20(10):2524-32. doi: 10.1007/s00330-010-1829-0. PMID: 20526776.

61. Sadan O, Ginath S, Sofer D, et al. The role of tamoxifen in the treatment of symptomatic uterine leiomyomata -- a pilot study. Eur J Obstet Gynecol Reprod Biol. 2001 Jun;96(2):183-6. PMID: 11384804.

62. Sayyah-Melli M, Tehrani-Gadim S, Dastranj-Tabrizi A, et al. Comparison of the effect of gonadotropin-releasing hormone agonist and dopamine receptor agonist on uterine myoma growth. Histologic, sonographic, and intra-operative changes. Saudi Med J. 2009 Aug;30(8):1024-33. PMID: 19668882.

63. Scialli AR, Jestila KJ. Sustained benefits of leuprolide acetate with or without subsequent medroxyprogesterone acetate in the nonsurgical management of leiomyomata uteri. Fertil Steril. 1995 Aug;64(2):313-20. PMID: 7615109.

64. Seracchioli R, Rossi S, Govoni F, et al. Fertility and obstetric outcome after laparoscopic myomectomy of large myomata: a randomized comparison with abdominal myomectomy. Hum Reprod. 2000 Dec;15(12):2663-8. PMID: 11098042.

65. Seracchioli R, Venturoli S, Vianello F, et al. Total laparoscopic hysterectomy compared with abdominal hysterectomy in the presence of a large uterus. J Am Assoc Gynecol Laparosc. 2002 Aug;9(3):333-8. PMID: 12101331.

66. Sesti F, Ruggeri V, Pietropolli A, et al. Laparoscopically assisted vaginal hysterectomy versus vaginal hysterectomy for enlarged uterus. Jsls. 2008 Jul-Sep;12(3):246-51. PMID: 18765046.

67. Sesti F, Capobianco F, Capozzolo T, et al. Isobaric gasless laparoscopy versus minilaparotomy in uterine myomectomy: a randomized trial. Surg Endosc. 2008 Apr;22(4):917-23. doi: 10.1007/s00464-007-9516-1. PMID: 17705083.

68. Sesti F, Cosi V, Calonzi F, et al. Randomized comparison of total laparoscopic, laparoscopically assisted vaginal and vaginal hysterectomies for myomatous uteri. Arch Gynecol Obstet. 2014 Sep;290(3):485-91. doi: 10.1007/s00404-014-3228-2. PMID: 24710800.

69. Shlansky-Goldberg RD, Rosen MA, Mondschein JI, et al. Comparison of polyvinyl alcohol microspheres and tris-acryl gelatin microspheres for uterine fibroid embolization: results of a single-center randomized study. J Vasc Interv Radiol. 2014 Jun;25(6):823-32. doi: 10.1016/j.jvir.2014.03.009. PMID: 24788209.

70. Silva-Filho AL, Werneck RA, de Magalhaes RS, et al. Abdominal vs vaginal hysterectomy: a comparative study of the postoperative quality of life and satisfaction. Arch Gynecol Obstet. 2006 Apr;274(1):21-4. doi: 10.1007/s00404-005-0118-7. PMID: 16408185.

71. Simsek T, Karakus C, Trak B. Impact of different hormone replacement therapy regimens on the size of myoma uteri in postmenopausal period: tibolone versus transdermal hormonal replacement system. Maturitas. 2002 Jul 25;42(3):243-6. PMID: 12161049.

72. Siskin GP, Beck A, Schuster M, et al. Leiomyoma infarction after uterine artery embolization: a prospective randomized study comparing tris-acryl gelatin microspheres versus polyvinyl alcohol microspheres. J Vasc Interv Radiol. 2008 Jan;19(1):58-65. doi: 10.1016/j.jvir.2007.08.034. PMID: 18192468.

73. Song YG, Jang H, Park KD, et al. Non spherical polyvinyl alcohol versus gelatin sponge particles for uterine artery embolization for symptomatic fibroids. Minim Invasive Ther Allied Technol. 2013 Dec;22(6):364-71. doi: 10.3109/13645706.2013.826674. PMID: 23992381.

74. Soriano D, Goldstein A, Lecuru F, et al. Recovery from vaginal hysterectomy compared with laparoscopy-assisted vaginal hysterectomy: a prospective, randomized, multicenter study. Acta Obstet Gynecol Scand. 2001 Apr;80(4):337-41. PMID: 11264609.

75. Soysal ME, Soysal SK, Vicdan K. Thermal balloon ablation in myoma-induced menorrhagia under local anesthesia. Gynecol Obstet Invest. 2001;51(2):128-33. doi: 52908. PMID: 11223708.

76. Spies JB, Allison S, Flick P, et al. Polyvinyl alcohol particles and tris-acryl gelatin microspheres for uterine artery embolization for leiomyomas: results of a randomized comparative study. J Vasc Interv Radiol. 2004 Aug;15(8):793-800. doi: 10.1097/01.rvi.0000136982.42548.5d. PMID: 15297582.

77. Spies JB, Allison S, Flick P, et al. Spherical polyvinyl alcohol versus tris-acryl gelatin microspheres for uterine artery embolization for leiomyomas: results of a limited randomized comparative study. J Vasc Interv Radiol. 2005 Nov;16(11):1431-7. doi: 10.1097/01.rvi.0000179793.69590.1a. PMID: 16319148.

78. Takeuchi H, Kobori H, Kikuchi I, et al. A prospective randomized study comparing endocrinological and clinical effects of two types of GnRH agonists in cases of uterine leiomyomas or endometriosis. J Obstet Gynaecol Res. 2000 Oct;26(5):325-31. PMID: 11147718.

79. Tan J, Sun Y, Dai H, et al. A randomized trial of laparoscopic versus laparoscopic-assisted minilaparotomy myomectomy for removal of large uterine myoma: short-term outcomes. J Minim Invasive Gynecol. 2008 Jul-Aug;15(4):402-9. doi: 10.1016/j.jmig.2008.03.010. PMID: 18602045.

80. Tan J, Sun Y, Zhong B, et al. A randomized, controlled study comparing minilaparotomy versus isobaric gasless laparoscopic assisted minilaparotomy myomectomy for removal of large uterine myomas: short-term outcomes. Eur J Obstet Gynecol Reprod Biol. 2009 Jul;145(1):104-8. doi: 10.1016/j.ejogrb.2009.04.015. PMID: 19427094.

81. Tosun AK, Tosun I, Suer N. Comparison of levonorgestrel-releasing intrauterine device with oral progestins in heavy menstrual bleeding (HMB) cases with uterine leiomyoma (LNG-IUD and oral progestin usage in myoma uteri). Pak J Med Sci. 2014 Jul;30(4):834-9. PMID: 25097527.

82. Vercellino G, Erdemoglu E, Joe A, et al. Laparoscopic temporary clipping of uterine artery during laparoscopic myomectomy. Arch Gynecol Obstet. 2012 Nov;286(5):1181-6. doi: 10.1007/s00404-012-2419-y. PMID: 22714065.

83. Vilos GA, Vilos AG, Abu-Rafea B, et al. Administration of goserelin acetate after uterine artery embolization does not change the reduction rate and volume of uterine myomas. Fertil Steril. 2006 May;85(5):1478-83. doi: 10.1016/j.fertnstert.2005.10.039. PMID: 16579996.

84. Wang JJ, Yang F, Gao T, et al. Gasless laparoscopy versus conventional laparoscopy in uterine myomectomy: a single-centre randomized trial. J Int Med Res. 2011;39(1):172-8. PMID: 21672319.

85. Wang X, Qin J, Wang L, et al. Effect of high-intensity focused ultrasound on sexual function in the treatment of uterine fibroids: comparison to conventional myomectomy. Arch Gynecol Obstet. 2013 Oct;288(4):851-8. doi: 10.1007/s00404-013-2775-2. PMID: 23564052.

86. Watanabe Y, Nakamura G, Matsuguchi H, et al. Efficacy of a low-dose leuprolide acetate depot in the treatment of uterine leiomyomata in Japanese women. Fertil Steril. 1992 Jul;58(1):66-71. PMID: 1624025.

87. Worthington-Kirsch RL, Siskin GP, Hegener P, et al. Comparison of the efficacy of the embolic agents acrylamido polyvinyl alcohol microspheres and tris-acryl gelatin microspheres for uterine artery embolization for leiomyomas: a prospective randomized controlled trial. Cardiovasc Intervent Radiol. 2011 Jun;34(3):493-501. doi: 10.1007/s00270-010-0049-y. PMID: 21127866.

88. Yang Z, Zhang Y, Zhang R, et al. A case-control study of high-intensity focused ultrasound combined with sonographically guided intratumoral ethanol injection in the treatment of uterine fibroids. J Ultrasound Med. 2014 Apr;33(4):657-65. doi: 10.7863/ultra.33.4.657. PMID: 24658945.

89. Yen YK, Liu WM, Yuan CC, et al. Addition of laparoscopic uterine nerve ablation to laparoscopic bipolar coagulation of uterine vessels for women with uterine myomas and dysmenorrhea. J Am Assoc Gynecol Laparosc. 2001 Nov;8(4):573-8. PMID: 11677339.

90. Yen YK, Liu WM, Yuan CC, et al. Comparison of two procedures for laparoscopic-assisted vaginal hysterectomy of large myomatous uteri. J Am Assoc Gynecol Laparosc. 2002 Feb;9(1):63-9. PMID: 11821608.

91. Yu SC, Lok I, Ho SS, et al. Comparison of clinical outcomes of tris-acryl microspheres versus polyvinyl alcohol microspheres for uterine artery embolization for leiomyomas: results of a randomized trial. J Vasc Interv Radiol. 2011 Sep;22(9):1229-35. doi: 10.1016/j.jvir.2011.05.011. PMID: 21802314.

92. Zhao F, Jiao Y, Guo Z, et al. Evaluation of loop ligation of larger myoma pseudocapsule combined with vasopressin on laparoscopic myomectomy. Fertil Steril. 2011 Feb;95(2):762-6. doi: 10.1016/j.fertnstert.2010.08.059. PMID: 20883988.

93. Eder S, Baker J, Gersten J, et al. Efficacy and safety of oral tranexamic acid in women with heavy menstrual bleeding and fibroids. Womens Health (Lond Engl). 2013 Jul;9(4):397-403. doi: 10.2217/whe.13.28. PMID: 23656203.

Appendix F. Registered Study Protocols

Table F-1. Registered protocols from studies included in Key Question 1

Study Name NCT (Related Publication)	Intervention(s)	Sponsor Funding Type	Start Date; Completion Date Study Status	Estimated Enrollment
PGL4001 Efficacy Assessment in Reduction of Symptoms Due to Uterine Leiomyomata NCT01629563 (See Ref ID: 95)	**Drug**: PGL4001 5 mg **Drug**: PGL4001 10 mg	PregLem SA Industry	6/1/2012; 1/1/2015 Completed, No Results Available	551
A Study to Evaluate the Safety and Effectiveness of Asoprisnil in the Treatment of Uterine Fibroids NCT00160459 (See Ref ID: 3324)	**Drug**: Asoprisnil	Abbott Industry	5/1/2000; 7/1/2001 Completed, No Results Available	129
Mifepristone to Treat Uterine Fibroids NCT01786226 (See Ref ID: 629)	**Drug**: Oral administration of mifepristone 2.5 mg daily for three months **Drug**: Oral administration of mifepristone 5 mg daily for three months	Mediterranea Medica S. L. Other	3/1/2010; 3/1/2012 Terminated, No Results Available	220
PGL4001 Efficacy Assessment in Reduction of Symptoms Due to Uterine Leiomyomata NCT01156857 (See Ref ID: 414)	**Drug**: PGL4001, placebo **Drug**: PGL4001, progestin	PregLem SA Industry	7/1/2010; 2/1/2012 Completed, No Results Available	209
PGL4001 Efficacy Assessment in Reduction of Symptoms Due to Uterine Leiomyomata (PEARLIII-extension Study) NCT01252069 (See Ref ID: 414)	**Drug**: PGL4001, placebo, **Drug** free period **Drug**: PGL4001, progestin, **Drug** free period	PregLem SA Industry	1/1/2011; 1/1/2014 Completed, No Results Available	200
Mifepristone 10 or 5 mg for 6 Months to Treat Uterine Fibroids NCT00886873 (See Ref ID: 2635)	**Drug**: Mifepristone	Mediterranea Medica S. L. Other	5/1/2008; 5/1/2009 Completed, No Results Available	100
Treatment of Uterine Fibroids With the Selective Progesterone Receptor Modulator CDB-2914 NCT00290251 (See Ref ID: 1849)	**Drug**: Ulipristal acetate **Drug**: Ulipristal acetate **Drug**: Placebo	Eunice Kennedy Shriver National Institute of Child Health and Human Development (NICHD) HRA Pharma National Institutes of Health Clinical Center (CC) NIH, Industry	2/1/2006; 8/1/2010 Completed, Has Results	72

Table F-1. Registered protocols from studies included in Key Question 1, continued

Study Name NCT (Related Publication)	Intervention(s)	Sponsor Funding Type	Start Date; Completion Date Study Status	Estimated Enrollment
Trial of Mifepristone for Fibroids NCT00133705 (See Ref ID: 3407)	**Drug**: Mifepristone	University of Rochester Eunice Kennedy Shriver National Institute of Child Health and Human Development (NICHD) Other, NIH	7/1/2003; 6/1/2010 Completed, Has Results	70
High Intensity Focused Ultrasound Ablation Virus Myomectomy to Treat Uterine Fibroids NCT01239641 (See Ref ID: 793; 804)	**Procedure**: High intensity focused ultrasound	Chongqing Medical University Other	9/1/2010; 7/1/2013 Recruiting, No Results Available	220
Emmy Trial: Uterine Artery Embolization (UAE) Versus Hysterectomy for Uterine Fibroids NCT00100191 (See Ref ID: 815; 1986; 2759; 2971; 3120; 3175; 3192; 3678; 3721; 3819)	**Procedure**: Embolization **Procedure**: Hysterectomy	The Netherlands Organisation for Health Research and Development Boston Scientific Corporation Other, Industry	2/1/2002; 4/1/2006 Completed, No Results Available	120
A Prospective Study Comparing Contour SE™ Microspheres to Embosphere® Microspheres for Treating Symptomatic Uterine Fibroids With Uterine Fibroid Embolization (UFE) NCT00628901 (See Ref ID: 347)	**Procedure**: Embolization **Device**: Contour SE™ Microspheres **Device**: Embosphere® Microspheres	Boston Scientific Corporation Industry	1/1/2006; 1/1/2011 Completed, Has Results	60
Laparoscopic Uterine Sparing Techniques Outcomes and Reinterventions NCT01750008 (See Ref ID: 392)	**Procedure**: Global Fibroid Ablation **Procedure**: Myomectomy	Halt Medical, Inc. Industry	11/1/2012; 9/1/2018 Active, Not Recruiting, No Results Available	50
Comparison Study in the Treatment of Uterine Fibroids Uterine Fibroid Embolization Using BeadBlock™ Embolic Agent NCT00361036 (See Ref ID: 1806)	**Device**: Uterine fibroid embolization BeadBlock™ **Device**: Uterine fibroid embolization Embosphere®	Worthington-Kirsch, Robert L., M.D. Terumo Medical Corporation Biocompatibles UK Ltd Other, Industry	8/1/2006; 3/1/2010 Completed, No Results Available	44

Table F-1. Registered protocols from studies included in Key Question 1, continued

Study Name NCT (Related Publication)	Intervention(s)	Sponsor Funding Type	Start Date; Completion Date Study Status	Estimated Enrollment
Laparoscopic Occlusion of Uterine Vessels Compared to Uterine Fibroid Embolization for Treatment of Uterine Fibroids NCT00277680 (See Ref ID: 2303; 3382)	**Procedure**: Laparoscopic bilateral occlusion of uterine artery **Procedure**: Radiological embolization (UFE)	Ullevaal University Hospital Oslo University Hospital Other	12/1/2000; 4/1/2010 Active, Not Recruiting, No Results Available	60
Temporary Clipping of the Uterine Arteries During Laparoscopic Myomectomy NCT01530802 (See Ref ID: 1108)	**Procedure**: Clipping of uterine arteries during laparoscopic myomectomy	Charite University, Berlin, Germany Other	1/1/2007; 12/1/2009 Completed, No Results Available	166
Multicentre randomised controlled trial comparing uterine artery embolisation with surgical treatment for uterine fibroids ISRCTN23023665 (See Ref ID: 3365)	**Procedure**: Embolisation **Procedure**: Surgery	Greater Glasgow Health Board (North Glasgow University Hospitals Division) (UK) Government	1/11/2000; 1/09/2010 Completed, No Results Available	200
Magnetic Resonance-Guided Focused Ultrasound to Treat Uterine Fibroids: A Pilot Randomized, Placebo-Controlled Trial NCT01377519 (See Ref ID: 11180)	**Procedure**: MR Guided Focused Ultrasound **Procedure**: Placebo MR Guided Focused Ultrasound	University of California, San Francisco Other	6/1/2011; 12/1/2012 Completed, No Results Available	20
A Phase III, Randomized, Parallel Group, Double-blind, Double-dummy, Active Comparator-controlled, Multicenter Study to Assess the Efficacy and Safety of PGL4001 vs GnRH-agonist for Pre-operative Ttt of Symptomatic Uterine Myomas NCT00740831 (See Ref ID: 1278)	**Drug**: Ulipristal acetate (PGL4001) **Drug**: Leuprorelin	PregLem SA Industry	8/1/2008; 6/1/2010 Completed, Has Results	301
A Phase III, Randomized, Parallel Group, Double-Blind, Placebo-Controlled, Multi-Center Study to Assess the Efficacy and Safety of PGL4001 (Ulipristal) Versus Placebo for Pre-Operative Treatment of Symptomatic Uterine Myomas NCT00755755 (See Ref ID: 1279)	**Drug**: Ulipristal acetate (PGL4001) **Drug**: Placebo	PregLem SA Industry	10/1/2008; 8/1/2010 Completed, Has Results	241

Table F-2. Registered protocols for ongoing studies of interventions for uterine fibroids

Study Name NCT (Related Publication)	Intervention(s)	Sponsor Funding Type	Start Date; Completion Date Study Status	Estimated Enrollment
Evaluation of a Hysteroscopic Morcellator in Hysteroscopic Treatment of Submucosal Fibroids NCT02406898	**Device**: Morcellator uterine system (MH) Karl Storz, Tuttligen-Germany	Assistance Publique Hopitaux De Marseille Other	4/1/2015; 3/1/2018 Not Yet Recruiting, No Results Available	60
Safety and Efficacy in Premenopausal Women With Heavy Menstrual Bleeding (HMB) Associated With Uterine Fibroids (UF) NCT01817530	**Drug**: Elagolix, elagolix sodium	AbbVie Industry	1/1/2013; 12/1/2015 Active, Not Recruiting, No Results Available	520
A Study of the Safety and Efficacy of Intermittent Ulipristal Treatment of Abnormal Uterine Bleeding Associated With Leiomyomas NCT02147158	**Drug**: Ulipristal acetate (UPA) 5 mg **Drug**: Ulipristal acetate (UPA) 10 mg **Drug**: Placebo	Watson Pharmaceuticals Industry	1/1/2014; 12/1/2015 Recruiting, No Results Available	400
Bay1002670, Fibroids, Safety and Efficacy NCT02131662	**Drug**: BAY1002670	Bayer Industry	5/1/2014; 3/1/2016 Recruiting, No Results Available	300
Ulipristal Acetate 10 mg and Assisted Reproduction NCT02425878	**Drug**: Ulipristal Acetate **Drug**: Placebo	Instituto Valenciano de Infertilidad, IVI VALENCIA Other	5/1/2015; Null Not Yet Recruiting, No Results Available	282
Safety and Efficacy Pre-Menopausal Women With Heavy Uterine Bleeding and Uterine Fibroids NCT01441635	**Drug**: Elagolix, elagolix sodium	AbbVie Industry	9/1/2011; 2/1/2014 Completed, No Results Available	271
A Study of the Efficacy and Safety of a Single Ulipristal Treatment Course for the Treatment of Abnormal Uterine Bleeding Associated With Leiomyomas NCT02147197	**Drug**: Ulipristal acetate 5 mg **Drug**: Ulipristal acetate 10 mg **Drug**: Placebo	Watson Pharmaceuticals Industry	4/1/2014; 3/1/2015 Recruiting, No Results Available	150
Ulipristal Acetate Versus GnRH Analogue Treatment Before Hysteroscopic Resection of Uterine Leiomyoma NCT02361879	**Drug**: Ulipristal acetate **Drug**: Leuprolide acetate	University Magna Graecia Other	2/1/2015; 9/1/2017 Recruiting, No Results Available	146
Ulipristal Acetate Versus GnRH Analogue and Myometrial Preservation	**Drug**: Ulipristal acetate **Drug**: Leuprolide acetate	University Magna Graecia Other	2/1/2015; 9/1/2017 Recruiting, No Results Available	110

Study Name NCT (Related Publication)	Intervention(s)	Sponsor Funding Type	Start Date; Completion Date Study Status	Estimated Enrollment
NCT02357563				

Table F-2. Registered protocols for ongoing studies of interventions for uterine fibroids, continued

Study Name NCT (Related Publication)	Intervention(s)	Sponsor Funding Type	Start Date; Completion Date Study Status	Estimated Enrollment
Ulipristal vs. GnRHa Prior to Laparoscopic Myomectomy NCT02288130	**Drug**: GnRHa **Drug**: Ulipristal	VU University Medical Center Other	12/1/2014; 9/1/2016 Recruiting, No Results Available	100
PGL4001 Efficacy Assessment in Reduction of Symptoms Due to Uterine Leiomyomata NCT01642472	**Drug**: Ulipristal acetate - open label	PregLem SA Industry	7/1/2012; 11/1/2014 Active, Not Recruiting, No Results Available	90
Study of Tumor-shrinking Decoction (TSD) to Treat Symptomatic Uterine Fibroids NCT02189083	**Drug**: TSD	The University of Hong Kong Other	5/1/2014; 2/1/2016 Recruiting, No Results Available	78
The Effect of Ulipristal Acetate (UPA) on Women Ovarian Reserve NCT02361892	**Drug**: Ulipristal acetate	University Magna Graecia Other	2/1/2015; 9/1/2017 Recruiting, No Results Available	73
Study of the Efficacy of Dienogest in the Treatment of Uterine Leiomyomas When Compared to Desogestrel and Goserelin NCT01738724	**Drug**: Dienogest **Drug**: Goserelin **Drug**: Desogestrel	University of Sao Paulo Other	1/1/2013; 12/1/2013 Not Yet Recruiting, No Results Available	63
GnRH Agonist Pretreatment in Hysteroscopic Myomectomy NCT01873378	**Drug**: Triptorelin 3.75 mg	Azienda Ospedaliera S. Maria della Misericordia Other	1/1/2013; Null Recruiting, No Results Available	60
Intra-arterial Lidocaine for Pain Control Post Uterine Fibroid Embolization NCT02293447	**Drug**: Lidocaine per-embolization **Drug**: Lidocaine post-embolization	University Health Network, Toronto Other	11/1/2014; 4/1/2016 Recruiting, No Results Available	60
Vasopressin Versus Epinephrine in Myomectomy NCT01861015	**Drug**: Epinephrine **Drug**: Vasopressin	CHA University Other	5/1/2013; 4/1/2016 Recruiting, No Results Available	60
Misoprostol for Reduction of Blood Loss During Fibroid Surgery NCT02209545	**Drug**: Misoprostol **Drug**: Placebo	Northwestern University Other	10/1/2014; 5/1/2018 Recruiting, No Results Available	50

Table F-2. Registered protocols for ongoing studies of interventions for uterine fibroids, continued

Study Name NCT (Related Publication)	Intervention(s)	Sponsor Funding Type	Start Date; Completion Date Study Status	Estimated Enrollment
A Multi-Center, Parallel Design, Randomized, Double-Blind Study to Evaluate the Safety and Efficacy of 6 and 12 mg ProellexÂ® (Telapristone Acetate) Administered Orally in the Treatment of Premenopausal Women With Confirmed Symptomatic Uterine Fibroids NCT02301897	**Drug**: Telapristone Acetate **Drug**: Placebo	Repros Therapeutics Inc. Industry	12/1/2014; 12/1/2016 Recruiting, No Results Available	45
A Phase 2, Study to Evaluate the Safety and Efficacy ProellexÂ® (Telapristone Acetate) Administered Vaginally in the Treatment of Uterine Fibroids NCT02323646	**Drug**: Telapristone Acetate (ProellexÂ®)	Repros Therapeutics Inc. Industry	12/1/2014; 12/1/2016 Recruiting, No Results Available	45
Ulipristal Acetate for the Preoperative Management of Hypoechoic Cellular Leiomyomas NCT02361905	**Drug**: Ulipristal acetate **Drug**: Leuprolide acetate	University Magna Graecia Other	2/1/2015; 9/1/2017 Recruiting, No Results Available	42
Clinical Trial of Uterine Artery Embolization for Uterine Leiomyoma NCT00821275	**Procedure**: Interventional radiological or surgical management	Sun Yat-sen University Other	1/1/2008; 12/1/2018 Enrolling By Invitation, No Results Available	900
Post Market TRUST - U.S.A. Study NCT02163525	**Procedure**: Global Fibroid Ablation (GFA) **Procedure**: Abdominal or Laparoscopic Myomectomy **Procedure**: Uterine Artery Embolization (UAE)	Halt Medical, Inc. Industry	6/1/2014; 12/1/2021 Recruiting, No Results Available	300
Post Market TRUST Study NCT01563783	**Procedure**: Global Fibroid Ablation (GFA) **Procedure**: Abdominal or Laparoscopic Myomectomy **Procedure**: Uterine Artery Embolization	Halt Medical, Inc. Industry	12/1/2012; 12/1/2019 Recruiting, No Results Available	260

Study Name NCT (Related Publication)	Intervention(s)	Sponsor Funding Type	Start Date; Completion Date Study Status	Estimated Enrollment
	(UAE)			

Table F-2. Registered protocols for ongoing studies of interventions for uterine fibroids, continued

Study Name NCT (Related Publication)	Intervention(s)	Sponsor Funding Type	Start Date; Completion Date Study Status	Estimated Enrollment
Sonalleve Fibroid Ablation Pivotal Clinical Trial for MR-HIFU of Uterine Fibroids NCT01504308	**Device**: MRgHIFU system	Philips Healthcare Industry	5/1/2012; 4/1/2019 Active, Not Recruiting, No Results Available	224
High Intensity Focused Ultrasound Ablation Virus Myomectomy to Treat Uterine Fibroids NCT01239641 (See Ref ID: 793; 804)	**Procedure**: High intensity focused ultrasound	Chongqing Medical University Other	9/1/2010; 7/1/2013 Recruiting, No Results Available	220
Uterine Artery Embolization (UAE) Versus High-Intensity-Focused-Ultrasound (HIFU) for Treatment of Uterine Fibroids NCT01834703	**Procedure**: Embolization **Procedure**: HIFU	Chinese University of Hong Kong Prince of Wales Hospital, Shatin, Hong Kong Other	5/1/2009; Null Recruiting, No Results Available	200
The FIRSTT: Comparing MRgFUS (MR-guided Focused Ultrasound) Versus UAE (Uterine Artery Embolization) for Uterine Fibroids NCT00995878	**Procedure**: Focused ultrasound (MRgFUS) **Procedure**: Uterine artery embolization (UAE)	Mayo Clinic Eunice Kennedy Shriver National Institute of Child Health and Human Development (NICHD) Other, NIH	10/1/2009; 12/1/2015 Active, Not Recruiting, No Results Available	180
Sonography Guided Transcervical Ablation of Uterine Fibroids NCT02228174	**Device**: Intrauterine Ultrasound-Guided Radiofrequency Ablation System	Gynesonics Industry	10/1/2014; 4/1/2019 Recruiting, No Results Available	147
Laparoscopic Radiofrequency Ablation (RFA) of Symptomatic Uterine Fibroids NCT00874029	**Device**: Halt **Procedure**	Halt Medical, Inc Industry	3/1/2009; 3/1/2014 Completed, Has Results	137
China Clinical Trial for Therapeutic MR-HIFU Ablation of Uterine Fibroids NCT01588899	**Device**: MRgHIFU system	Philips Healthcare Industry	5/1/2012; 6/1/2015 Active, Not Recruiting, No Results Available	110
ExAblate UF V2 System for the Treatment of Symptomatic Uterine Fibroids	**Device**: ExAblate Treatment UF V2	InSightec Industry	5/1/2012; 4/1/2015 Recruiting, No	106

Study Name NCT (Related Publication)	Intervention(s)	Sponsor Funding Type	Start Date; Completion Date Study Status	Estimated Enrollment
NCT01285960			Results Available	

Table F-2. Registered protocols for ongoing studies of interventions for uterine fibroids, continued

Study Name NCT (Related Publication)	Intervention(s)	Sponsor Funding Type	Start Date; Completion Date Study Status	Estimated Enrollment
Diffusion -and Perfusion Weighted MRI for Response Prediction of Symptomatic Leiomyomas Following Uterine Artery Embolization NCT01514617	**Procedure**: Diffusion - and perfusion weighted MRI including IV contrast agent injection	Universitaire Ziekenhuizen Leuven Other	1/1/2012; 12/1/2016 Recruiting, No Results Available	100
Uterine Leiomyoma Treatment With Radiofrequency Ablation NCT01840124	**Procedure**: Radiofrequency ablation	University of California Other	7/1/2013; Null Recruiting, No Results Available	100
Clinical Study of the Mirabilis High-Intensity Focused Ultrasound System for Non-Invasive Treatment of Uterine Fibroids NCT01946178	**Device**: Mirabilis High-Intensity Focused Ultrasound Treatment System	Mirabilis Medica, Inc. Industry	1/1/2011; Null Active, Not Recruiting, No Results Available	80
Uterine Fibroid Embolization-Long Term Follow up and Technical Perspectives NCT01852734	**Procedure**: Embolization	Odense University Hospital Other	11/1/2013; 11/1/2015 Recruiting, No Results Available	60
Laparoscopic Uterine Sparing Techniques Outcomes and Reinterventions NCT01750008 (See Ref ID: 392)	**Procedure**: Global Fibroid Ablation **Procedure**: Myomectomy	Halt Medical, Inc. Industry	11/1/2012; 9/1/2018 Active, Not Recruiting, No Results Available	50
Post Market Evaluation of Acessa With TAG NCT01842789	**Device**: Acessa **Procedure**	Halt Medical, Inc. Industry	4/1/2013; 12/1/2015 Recruiting, No Results Available	50
Factors Influencing Volumetric MR-HIFU Ablation of Uterine Fibroids NCT02386137	**Device**: Contrast-enhancement ultrasound with Sonovue	University Hospital, Bordeaux Other	3/1/2015; 3/1/2017 Not Yet Recruiting, No Results Available	40
Laparoscopic Cryoablation of Uterine Fibroids NCT01735812	**Device**: IceSense3 system	IceCure Medical Ltd. Industry	12/1/2012; Null Recruiting, No Results Available	30
Clinical Test of the MRgHIFU System on Uterine Fibroids NCT02283502	**Device**: MRgHIFU system	Chin-Jung Wang National Health Research	9/1/2014; 5/1/2015 Recruiting, No Results Available	20

Study Name NCT (Related Publication)	Intervention(s)	Sponsor Funding Type	Start Date; Completion Date Study Status	Estimated Enrollment
		Institutes, Taiwan Chang Gung Memorial Hospital Other		

Table F-2. Registered protocols for ongoing studies of interventions for uterine fibroids, continued

Study Name NCT (Related Publication)	Intervention(s)	Sponsor Funding Type	Start Date; Completion Date Study Status	Estimated Enrollment
Safety and Effectiveness of OCL 503 in the Treatment of Women With Leiomyomata NCT02410018	**Device**: OCL 503 (uterine artery embolization)	IMBiotechnologies Ltd. Industry	4/1/2015; 9/1/2015 Recruiting, No Results Available	10
Far Infrared Radiation Treatment for Uterine Fibroids NCT00574418	**Procedure**: Far Infrared Radiation (5Î¼m to 20Î¼m wavelength)	GAAD Medical Research Institute Inc. Other	1/1/2006; 9/1/2008 Active, Not Recruiting, No Results Available	2
Hysteroscopic Monopolar and Bipolar Resection NCT00323999	**Procedure**: Hysteroscopic resection of fibroids, polyps and endometrium	Ullevaal University Hospital Other	12/1/2004; 12/1/2007 Recruiting, No Results Available	Null
MyoSure Hysteroscopic Tissue Removal System Registry Study NCT01369758	**Device**: MyoSure Tissue Removal System	Hologic, Inc. Industry	11/1/2010; 11/1/2013 Active, not recruiting	600
Study of Conventional Laparoscopic Hysterectomy Versus Robot-Assisted Laparoscopic Hysterectomy at a Teaching Institution NCT01581905	**Procedure**: Conventional Laparoscopic Hysterectomy (LH) **Procedure**: Robot Assisted Hysterectomy	Milton S. Hershey Medical Center Other	3/1/2012; 6/1/2013 Recruiting, No Results Available	400
Single Incision Laparoscopic Surgery (SILS) Versus Conventional Laparoscopic Hysterectomy NCT01483417	**Procedure**: Single incision Laparoscopic hysterectomy **Procedure**: Conventional laparoscopic hysterectomy	Samsung Medical Center Other	12/1/2011; 3/1/2013 Recruiting, No Results Available	240
Minimally Invasive Benign Hysterectomy NCT01865929	**Procedure**: Vaginal or laparoscopic hysterectomy	Region Skane Other	1/1/2010; 12/1/2015 Recruiting, No Results Available	200
Single-port Access Laparoscopic-assisted Vaginal Hysterectomy	**Procedure**: Single-port LAVH	Taipei Veterans General Hospital, Taiwan	10/1/2009; 10/1/2010 Recruiting, No	100

Study Name NCT (Related Publication)	Intervention(s)	Sponsor Funding Type	Start Date; Completion Date Study Status	Estimated Enrollment
NCT01048931		National Yang Ming University Other	Results Available	

Table F-2. Registered protocols for ongoing studies of interventions for uterine fibroids, continued

Study Name NCT (Related Publication)	Intervention(s)	Sponsor Funding Type	Start Date; Completion Date Study Status	Estimated Enrollment
Vaginal vs. Laparoscopic Hysterectomy NCT02059954	**Procedure**: Hysterectomy	Medical University of Graz Austrian Urogynecology Working Group (AUWG) Other	1/1/2014; 7/1/2015 Recruiting, No Results Available	100
HOME Study: Hysteroscopic Office Myomectomy Evaluation NCT01152112	**Device**: Myomectomy	Hologic, Inc. Industry	6/1/2010; 3/1/2013 Active, Not Recruiting, No Results Available	86
Barbed Suture in Single-port Laparoscopic Myomectomy NCT01984632	**Procedure**: Single-port laparoscopic myomectomy **Procedure**: Multi-port laparoscopic myomectomy	CHA University Other	11/1/2013; 11/1/2015 Recruiting, No Results Available	80
Barbed Suture Versus Traditional Suture Material for Laparoscopic Myomectomy NCT01347385	**Procedure**: Laparoscopic myomectomy with unidirectional barbed suture **Procedure**: Traditional suture material	Sunnybrook Health Sciences Centre Other	1/1/2012; Null Not Yet Recruiting, No Results Available	80
Surgical Success After Laparoscopic vs Abdominal Hysterectomy NCT01793584	**Procedure**: Laparoscopic hysterectomy **Procedure**: Abdominal hysterectomy	University of Texas Southwestern Medical Center Other	2/1/2013; 6/1/2016 Recruiting, No Results Available	75
Laparoscopic Occlusion of Uterine Vessels Compared to Uterine Fibroid Embolization for Treatment of Uterine Fibroids NCT00277680 (See Ref ID: 2303; 3382)	**Procedure**: Laparoscopic bilateral occlusion of uterine artery **Procedure**: Radiological embolization (UFE)	Ullevaal University Hospital Oslo University Hospital Other	12/1/2000; 4/1/2010 Active, Not Recruiting, No Results Available	60
Single or Triple Uterine	**Procedure**: Single	RagÄ±p Atakan Al	3/1/2015; 5/1/2017	60

Study Name NCT (Related Publication)	Intervention(s)	Sponsor Funding Type	Start Date; Completion Date Study Status	Estimated Enrollment
Tourniquet at Myomectomy NCT02392585	tourniquet **Procedure**: Triple tourniquet	Ataturk University Other	Recruiting, No Results Available	
Use of v Care in Abdominal Hysterectomy NCT02371811	**Device**: Uterine manipulator (v care)	Ain Shams Maternity Hospital Other	2/1/2015; 8/1/2015 Recruiting, No Results Available	60

Table F-2. Registered protocols for ongoing studies of interventions for uterine fibroids, continued

Study Name NCT (Related Publication)	Intervention(s)	Sponsor Funding Type	Start Date; Completion Date Study Status	Estimated Enrollment
Laparoscopic Myomectomy Using Barbed or Conventional Sutures NCT02166411	**Procedure**: Myomectomy using barbed sutures **Procedure**: Myomectomy using conventional sutures	Cairo University Other	12/1/2013; 12/1/2015 Recruiting, No Results Available	54
Influence of Aromatase Inhibitors and GnRH Analogs to Treat Uterine Leiomyoma by Vaginal Hysterectomy NCT01280045	**Procedure**: Vaginal hysterectomy	University of Sao Paulo Other	1/1/2011; 1/1/2015 Recruiting, No Results Available	50
Assessment of the Manageability and Safety of ADBLOCK Adhesion Barrier System in Laparoscopic Gynaecological Surgery NCT01745432	**Device**: ADBLOCK	Terumo Europe N.V. Industry	8/1/2012; 11/1/2014 Active, Not Recruiting, No Results Available	30

Appendix G. Study Outcome Data

Outcome Data for Key Question 1 and Key Question 2

We extracted intermediate and final health outcomes from all studies included for KQ 1. We recorded data on 414 discreet outcome measures representing 19 prespecified outcome categories: symptom status; desired fertility status; pregnancy outcomes; sexual function; fibroid characteristics; fibroid recurrence; subsequent treatment for fibroids; satisfaction with outcomes; transfusion; unplanned hysterectomy; perforation of organs; cancer dissemination; other serious adverse events; technical success; conversion to another procedure; estimated intraoperative blood loss; length of stay; readmission / reoperation; return to usual activities. We report additional data on effectiveness outcomes and harms not represented in the main report

All data are publicly available in the Systematic Review Data Repository (SRDR).

Effectiveness Outcomes Data

Table G-1. Change in uterine volume following uterine artery embolization

Author, Year	Embolic Agent	N (Imaging)	Followup, months	Baseline; Followup cm^3	Change cm^3 mean ± SD or Percent
Macnaught G et al. (2015)[1]	Embospheres	10 (MRI)	6	NR NR	↓396.5 p=<0.01
Macnaught G et al. (2015)[1]	Gelfoam	10 (MRI)	6	NR NR	↓117.1 p=NS
Wang X et al. (2015)[2]	200 µm PVA particles	65 (US)	6	290.78 ± 14.88 168.24 ± 12.87	↓122.54 p<0.05
Wang X et al. (2015)[2]	500 µm PVA particles	65 (US)	6	291.73 ± 16.44 123.76 ± 13.99	↓167.97 p<0.05
Shlansky-Goldberg R et al. (2014)[3]	TAG microspheres	28 (MRI)	3	NR 909.1 ± 610.8	↓557.8 ± 1101.1 p=NR
Shlansky-Goldberg R et al. (2014)[3]	PVA particles	28 (MRI)	3	NR 1058.0 ± 613.4	↓436.4 ± 352.1 p=NR
Song Y et al. (2013)[4]	Gelatin sponge particles	30 (MRI)	3	960.27 ± 548.1 498.61 ± 301.74	NR
Song Y et al. (2013)[4]	PVA particles	30 (MRI)	3	934.47 ± 320.78 534.12 ± 193.67	NR
Yu S et al. (2011)[5]	PVA	30 (NA)	NA	NR NR	NR
Yu S et al. (2011)[5]	TAG microspheres	30 (NA)	NA	NR NR	NR
Worthington-Kirsch R et al. (2011)[6]	TAG microspheres	24 (MRI)	6	650.0 ± 180.0 NR	NR[a]
Worthington-Kirsch R et al. (2011)[6]	PVA	22 (MRI)	6	540.0 ± 90.0 NR	NR[a]
Bilhim T et al. (2011)[7]	PVA particles, large	76 (MRI)	6	482.0 ± NR 266.0 ± NR	↓44.8% p=NR
Bilhim T et al. (2011)[7]	PVA particles, small	77 (MRI)	6	515.0 ± NR 314.0 ± NR	↓39.0% p=NR
Siskin G et al. (2008)[8]	PVA microspheres	27 (MRI)	1	564.0 ± NR 470.7 ± NR	↓16.5% p=NR
Siskin G et al.	TAG	26	1	611.6 ± NR	↓12.6%

Author, Year	Embolic Agent	N (Imaging)	Followup, months	Baseline; Followup cm^3	Change cm^3 mean ± SD or Percent
(2008)[8]	microspheres	(MRI)		534.3 ± NR	p=NR
Vilos G et al. (2006)[9]	PVA particles	10 (US)	12	476.6 ± 279.3 200.6 ± 74.1	↓58.0% p=NR
Vilos G et al. (2006)[9]	PVA plus goserelin	12 (US)	12	556.4 ± 271.8 305.1 ± 141.3	↓45.0% p=NR
Spies J et al. (2005)[10]	PVA particles	17 (MRI)	3	510.5 ± 314.8 NR	↓16.4 ± 23.5% p=NR
Spies J et al. (2005)[10]	TAG microspheres	19 (MRI)	3	618.9 ± 305.1 NR	↓27.4 ± 22.4% p=NR
Spies J et al. (2004)[11]	PVA particles	46 (MRI)	3	603.9 ± 343.3 NR	↓30.2 ± 17.3% p=NR
Spies J et al. (2004)[11]	TAG microspheres	54 (MRI)	3	648.7 ± 326.7 NR	↓35.1 ± 16.7% p=NR
Pinto I et al. (2003)[12]	PVA particles	38 (NA)	NA	NR NR	NR
Volkers N et al. (2007)[13]	PVA particles	87 (US)	1.5	471.9 ± 450 268.0 ± 209.0†	↓20.9% p<0.001
Volkers N et al. (2007)[13]	PVA particles	66 (US)	6	NR 235.3 ± 204.0	↓30.9% p<0.001
Volkers N et al. (2007)[13]	PVA particles	62 (US)	12	NR 201.2 ±198.0	↓44.3% p<0.001
Volkers N et al. (2007)[13]	PVA particles	62 (US)	24	NR 170.2 ± 135.0	↓48.2% p<0.001
Ananthakrishnan G et al. (2013)[14]	NR	85 (MRI)	6	670.0 ± 503.0 422.0 ± 353.0*	↓34.0% p=NR
Ananthakrishnan G et al. (2013)[14]	NR	68 (MRI)	60	NR 292.0 ± 287.0	↓53.0% p=NR

Notes: Uterine volume not reported in the following: Yu SC et al. (2011);5 Mara M et al. (2008);15 Pinto I et al. (2003);12
*n=84; †n=69; Abbreviations: MRI= magnetic resonance imaging; nPVA= non spherical polyvinyl alcohol; NR= not reported; PVA= polyvinyl alcohol; SPVA= spherical polyvinyl alcohol; TAG= tris-acryl gelatin; TAGM= tris-acryl gelatin microspheres; UAE= uterine artery embolization; US= ultrasound

Table G-2. Change in bleeding characteristics and hemoglobin with ulipristal acetate

Author, Year	Dose, mg	N	Treatment Months	Last Followup Months	Bleeding Measure	Baseline Followup	Change
Donnez J et al. (2015)[16, 17] PEARL IV	5	228	5.5	14	Amenorrhea at end of both treatment cycles	NR 122/197 (62%)	NR
Donnez J et al. (2015)[16, 17] PEARL IV	5	228	11	14	Amenorrhea at end of four treatment cycles	NR 94/150 (63%)	NR
Donnez J et al. (2015)[16, 17] PEARL IV	10	223	5.5	14	Amenorrhea at end of both treatment cycles	NR 136/187 (73%)	NR
Donnez J et al. (2015)[16, 17] PEARL IV	10	223	11	14	Amenorrhea at end of four treatment cycles	NR 106/147 (72%)	NR
Donnez J et al. (2015)[16, 17] PEARL IV	5	218	11	14	PBAC score Median (IQR)	224 (148, 357) After	After cycle 1 ↓87 (↓167, ↑13)

Author, Year	Dose, mg	N	Treatment Months	Last Followup Months	Bleeding Measure	Baseline Followup	Change
						cycle 1 123 (45, 313) After cycle 2 92 (44, 253) After cycle 4 77.5 (NR)	After cycle 2 ↓95 (↓216, ↑9)
Donnez J et al. (2015)[16, 17] PEARL IV	10	214	11	14	PBAC score Median (IQR)	215 (151, 373) After cycle 1 129 (56, 285) After cycle 2 99 (37, 202) After cycle 4 76 (NR)	After cycle 1 ↓85 (↓209, ↓12) After cycle 2 ↓110 (↓236, ↓50)
Donnez J et al. (2014)[18] PEARL III	10	199	2.5	5.5	Hemoglobin (g/dl)	12.5 ± 1.8 NR	NR
Donnez J et al. (2014)[18] PEARL III	10	201	2.5	5.5	PBAC score Median (IQR)	216 (126, 376) 31 (11,100)	↓120 (↓255,↓45)
Donnez J et al. (2012)[19] PEARL I	5 + iron supplementation	95	3	3	Hemoglobin (g/dl)	9.3 ± 1.5 13.5 ± 1.3	↑4.25 ± 1.9 p<0.001
Donnez J et al. (2012)[19]	5 + iron supplementation	95	3	3	PBAC score Median (IQR)	386 (235, 627) 0 (0, 5)	↓329 (↓571,↓205)
Donnez J et al. (2012)[19]	5 + iron supplementation	50[a]	8.7	8.7	PBAC score Median (IQR)	321 (219, 536) 234 (102, 450)	↓81 (↓195, ↑27)
Donnez J et al. (2012)[19]	5 + iron supplementation	95	3	3	PBAC score <75	NR 86/94 (91%)	NR
Donnez J et al. (2012)[19]	5 + iron supplementation	95	3	3	PBAC score ≤ 2 (amenorrhea)	NR 69/94 (73%)	NR
Donnez J et al. (2012)[19]	10 + iron supplementation	94	3	3	Hemoglobin (g/dl)	9.5 ± 1.6 13.6 ± 1.2	↑4.2 ± 1.8 p<0.001
Donnez J et al. (2012)[19]	10 + iron supplementation	94	3	3	PBAC score Median (IQR)	330 (235, 537) 0 (0, 0)	↓326 (↓527,↓226)
Donnez J et al. (2012)[19]	10 + iron supplementation	41[a]	8.7	8.7	PBAC score Median (IQR)	272 (212, 433) 174 (46, 321)	↓161 (↓256,↓↑13)

Author, Year	Dose, mg	N	Treatment Months	Last Followup Months	Bleeding Measure	Baseline Followup	Change
Donnez J et al. (2012)[19]	10 + iron supplementation	94	3	3	PBAC score <75	NR 86/93 (92%)	NR
Donnez J et al. (2012)[19]	10 + iron supplementation	94	3	3	PBAC score ≤ 2 (amenorrhea)	NR 76/93 (82%)	NR
Donnez J et al. (2012)[20] PEARL II	5	93	3	3	Hemoglobin (g/dl)	12.4 ± 1.6 12.8 ± 1.4	↑0.4 p=NR
Donnez J et al. (2012)[20]	5	93	3	3	PBAC score Median (IQR)	286 (190, 457) 0 (0, 2)	↓268 (↓412,↓172)
Donnez J et al. (2012)[20]	5	43[b]	8.7	8.7	PBAC score Median (IQR)	299 (213, 391) 236 (143, 387)	↓73 (↓242, ↑65)
Donnez J et al. (2012)[20]	5	93	3	3	PBAC score < 75	NR 84/93 (90%)	NR
Donnez J et al. (2012)[20]	5	93	3	3	PBAC score ≤ 2 (amenorrhea)	NR 70/93 (75%)	NR
Donnez J et al. (2012)[20]	10	95	3	3	Hemoglobin (g/dl)	12.4 ± 1.6 12.9 ± 1.2	↑0.5 p=NR
Donnez J et al. (2012)[20]	10	95	3	3	PBAC score Median (IQR)	271 (183, 392) 0 (0, 0)	↓268 (↓387,↓179)
Donnez J et al. (2012)[20]	10	45[b]	8.7	8.7	PBAC score Median (IQR)	244 (173, 351) 141 (103, 311)	↓96 (↓155,↓62)
Donnez J et al. (2012)[20]	10	95	3	3	PBAC score < 75	NR 93/95 (98%)	NR
Donnez J et al. (2012)[20]	10	95	3	3	PBAC score ≤ 2 (amenorrhea	NR 85/95 (89%)	NR
Levens ED et al. (2008)[21]	10 or 20	12	3	3	Hemoglobin (g/dl)	NR NR	↓0.3 p=NS

Notes: A Subset from PEARL I study who did not have surgery following initial 3 months of treatment b Subset from PEARL II study who did not have surgery following initial 3 months of treatment; Abbreviations: g/dl= Grams per deciliter; IQR= interquartile; mg= milligrams; n= number; NR= not reported; NS= not significant; PBAC= pictorial blood loss assessment chart

Harms and Serious Adverse Event Data

We extracted the incidence of harms and serious adverse events reported in the studies included in KQ 1. We limited presentation of harms in the tables below to a prespecified list (transfusion; unplanned hysterectomy; organ perforation; cancer dissemination; ovarian failure; misdirected embolization; and other serious AE including death, life-threatening complication, deep vein thrombosis, pulmonary embolism, cardiovascular complication, pulmonary complication, uterine artery dissection) and recorded the frequency, including “0”, during or after the intervention and at last followup. We recorded the rate as the count of patients with the

event per the number of patients available for analysis and treated per protocol unless study authors indicated that intention to treat was used to calculate the incidence of harms. If the count of harms was reported during or after treatment and at last followup and was cumulative, we recorded the count only in the interval in which the event occurred. We organized the tables by intervention category (i.e., medical interventions, procedural interventions, and surgical interventions). We report these data by arm and do not include comparative rates of harms within studies as studies were not designed to capture harms adequately (i.e., studies were not powered to detect differences in harms or did not include sufficient duration of followup). For this same reason, we did not assess the quality of harms reporting within these studies. We report the incidence of transfusion separately from other harms, as transfusion is a common risk of surgical or procedural removal of fibroids (or the uterus) and is of clinical significance in a population at increased risk of anemia due to excessive uterine bleeding caused by leiomyoma. See SRDR for all harms extracted.

Medical Interventions

Table G-3. Harms reported at the end of medical treatment for uterine fibroids

Author, Year	Intervention	Harm	EOT Incidence	%
Donnez J et al. (2012)[22]	ulipristal acetate, 5 mg	uterine hemorrhage	0/95	0
	ulipristal acetate, 10 mg	uterine hemorrhage	1/98	1
	ulipristal acetate, 5 mg	ovarian hemorrhage	1/95	1
	ulipristal acetate, 10 mg	ovarian hemorrhage	0/98	0
Donnez J et al. (2015)[16]	ulipristal, 10mg	fibroid expulsion, partial[a]	1/205	0.5
		arteriospasm, coronary	1/205	0.5
		obstruction, small intestine	1/205	0.5
	ulipristal, 5mg	fibroid expulsion, partial	0/215	0
		arteriospasm, coronary	0/215	0
		obstruction, small intestine	0/215	0
Eder S et al. (2013)[23]	tranexamic acid, 3.9mg	adverse event, treatment emergent	4/232	1.7
Fedele L et al. (1991)[24]	buserelin, intranasal	transfusion	0/15	0
Jirecek S et al. (2004)[25]	raloxifene, 180mg	adverse event, serious (not defined)	0/13	0
Palomba S et al. (2002)[22]	leuprolide plus placebo	adverse event, serious[b]	0/50	0
	leuprolide plus raloxifene	adverse event, serious[b]	0/50	0

Notes: [a] assessed as possibly related to intervention by study investigators; [b] death, overdose, diagnosis of cancer, or any life-threatening, permanently disabling or requiring hospitalization.

Procedural Interventions

Table G-4. Harms reported during or after procedural intervention for uterine fibroids

Author, Year	Intervention	Harm	EOT Incidence	%	LFU Incidence	%
Bilhim T et al. (2011)[7]	UAE with PVA particles, large	complication, major	1/80	ND	ND	ND
	UAE with PVA particles, small	complication, major	2/80	ND	ND	ND
	uterine artery occlusion, laparoscopic	claudication, buttock	1/29	3.5	ND	ND
		embolism, pulmonary	1/29	3.5	ND	ND
	UAE	fibroid expulsion	5/29	17.2	ND	ND

Author, Year	Intervention	Harm	EOT Incidence	%	LFU Incidence	%
		claudication, buttock	0/29	0	ND	ND
		embolism, pulmonary	0/29	0	ND	ND
Hehenkamp WJ et al. (2005)[26]	UAE	sepsis	0/81	0	1/81	1.2
		embolism, pulmonary	1/81	1.2	0/81	0
Jacoby VL et al. (2016)	MrgFUS	adverse event, serious	0/13	0	ND	ND
Jiang N et al. (2014)[27]	HIFU plus CEUS	complication, major	0/40	0	ND	ND
Jun F et al. (2012)[28]	UAE	complication, major	ND	ND	0/62	0
Manyonda IT et al. (2012)[29]	UAE	sepsis, pelvic requiring IV antibiotics	ND	ND	1/67	1.5
Mara M et al. (2006)[30]	UAE	complication, life threatening	ND	ND	0/30	0
		complication, serious	ND	ND	3/30	10
		dissection, uterine artery	1/30	3.3	ND	ND
Meng X et al. (2010)[31]	HIFU	complication, major	0/50	0	0/50	0
Orsi F et al. (2015)[32]	HIFU	complication, major	0/16	0	ND	ND
	HIFU plus CEUS	complication, major	0/17	0	ND	ND
Pinto I et al. (2003)[12]	UAE	abscess, intraabdominal	ND	ND	0/40	0
		abscess, surgical wound	ND	ND	0/40	0
		dissection, uterine artery	2/40	5.0	ND	ND
		perforation, gluteal artery	2/40	5.0	ND	ND
		thrombosis, deep vein	ND	ND	1/40	2.0
Song YG et al. (2013)[4]	UAE with gelatin sponge particles	complication, major	ND	ND	0/30	0
	UAE with PVA	complication, major	ND	ND	0/30	0
Spies JB et al. (2004)[11]	UAE with PVA	embolism, pulmonary	0/46	ND	0/46	0
	UAE with TAG microspheres	embolism, pulmonary	1/54	ND	1/54	1.9
Wang X et al. (2013)[33]	HIFU	death	0/48	0	ND	ND
		complication, severe	0/48	0	ND	ND
Wang X et al. (2015)	PVA	bleeding	1/65	1.5	ND	ND
Yang Z et al. (2014)[34]	HIFU	complication, major SIR Class C-F	0/20	0	ND	ND
	HIFU plus ultrasound guided intramural ethanol injection	complication, major SIR Class C-F	0/20	0	ND	ND
Yu SC et al. (2011)[5]	UAE with PVA	complication, major SIR Class D	ND	ND	2/30	6.6
		ovarian failure, premature	ND	ND	3/29	11.0
	UAE with TAG microspheres	complication, major SIR Class D	ND	ND	0/30	0
		ovarian failure, premature	ND	ND	2/27	7.0

Abbreviations: CEUS=contrast enhanced ultrasound; EOT=end of treatment; LFU=last followup; UAE=uterine artery embolization; PVA=polyvinyl alcohol particles; TAG=tris-acryl gelatin particles; nPVA= ; HIFU=high intensity focused ultrasound; SIR=Society of Interventional Radiology

Surgical Interventions

Table G-5. Organ injury or perforation rates of surgical interventions for uterine fibroids

Author, Year	Intervention	Harm	Incidence*	%
Brucker SY et al. (2014)[35]	ablation, radiofrequency volumetric thermal	injury, bladder, ureter, bowel or vessels	0/25	0
	myomectomy	injury, bladder, ureter, bowel or vessels	0/25	0
Hahn M et al. (2015)	radiofrequency volumetric thermal ablation	uterine perforation, unplanned hysterectomy	1/26	3.8
Hwang JL et al. (2002)[36]	hysterectomy, abdominal	injury, major organ or vessel	0/30	0
	hysterectomy, laparoscopic assisted vaginal	injury, major organ or vessel	0/30	0
	hysterectomy, vaginal	injury, major organ or vessel	0/30	0
Kramer B et al. (2016)	radiofrequency volumetric thermal ablation	uterine perforation, unplanned pregnancy	ND	ND
Mara M et al. (2006)[30]	myomectomy	dissection, uterine artery	0/33	0
Pinto I et al. (2003)[12]	hysterectomy, abdominal	dissection, uterine artery	0/30	0
		perforation, gluteal artery	0/20	0
Seracchioli R et al. (2002)[37]	hysterectomy, abdominal	injury, bowel	0/62	0
	hysterectomy, total laparoscopic	injury, bowel	1/60	1.7
Silva-Filho AL et al. (2006)[38]	hysterectomy, total abdominal + hysterectomy, vaginal	laceration, bladder	1/60	1.7
Soysal ME et al. (2001)[39]	ablation, endometrial roller ball	injury, cervical	1/28	2.1
	ablation, endometrial thermal balloon	injury, cervical	0/45	0
Yen YK et al. (2002)[40]	hysterectomy, laparoscopic assisted vaginal	injury, urinary tract	0/32	0
	hysterectomy, laparoscopic assisted vaginal with bipolar coagulation of uterine vessels	injury, urinary tract	0/29	0

Notes:*Intraoperative or postoperative

Other Interventions

Table G-6. Harms reported at the end of other treatment for uterine fibroids

Author, Year	Intervention	Harm	EOT Incidence	%	LFU Incidence	%
Nik Hazlina N et al. (2005)[7]	Herbal treatment	adverse event, serious	0/18	0	ND	ND
	GnRH agonist	adverse event, serious	0/17	0	ND	ND

Table G-7. Incidence of other serious harms reported during or after surgical intervention for uterine fibroids

Author, Year	Intervention	Harm	EOT Incidence	%	LFU Incidence	%
Alessandri F et al. (2006)[41]	myomectomy, laparoscopic	peritonitis, acute diffuse	1/74	ND	ND	ND
Benassi L et al.	hysterectomy,					

Author, Year	Intervention	Harm	EOT Incidence	%	LFU Incidence	%
(2002)[42]	abdominal	embolism, pulmonary	0/60	0	ND	ND
	hysterectomy, vaginal	embolism, pulmonary	0/60	0	ND	ND
Ferrari MM et al. (2000)[43]	hysterectomy, laparoscopic assisted vaginal	complication, major	0/31	0	ND	ND
	hysterectomy, vaginal	complication, major	0/31	0	ND	ND
Hehenkamp WJ et al. (2005)[26]	hysterectomy	sepsis	0/75	0	0/75	0
		embolism, pulmonary	1/75	1.3	0/75	0
Jun F et al. (2012)[28]	hysterectomy or myomectomy	complication, major	ND	ND	4/62	6.0
Manyonda IT et al. (2012)[29]	myomectomy	embolism, pulmonary	ND	ND	1/73	1.4
		sepsis, e. coli	ND	ND	1/73	1.4
Mara M et al. (2006)[30]	myomectomy	complication, life threatening	ND	ND	0/33	0
		complication, serious	ND	ND	1/33	3.0
Meng X et al. (2010)[31]	ablation, radiofrequency	complication, major	0/50	0	0/50	0
Pinto I et al. (2003)[12]	hysterectomy, abdominal	abscess, intraabdominal	ND	ND	1/20	5.0
		abscess, surgical wound	ND	ND	3/20	15.0
		thrombosis, deep vein	ND	ND	1/20	5.0
Rossetti A et al. (2001)[44]	myomectomy, abdominal	complication, major or late	0/40	0	ND	ND
	myomectomy, laparoscopic	complication, major or late	0/41	0	ND	ND
Seracchioli R et al. (2002)[37]	hysterectomy, abdominal	wound infection	6/62	9.7	ND	ND
	hysterectomy, total laparoscopic	wound infection	0/60	0	ND	ND
Sesti F et al. (2008)[45]	myomectomy, isobaric gasless laparoscopy	complication, major	0/50	0	ND	ND
	myomectomy, minilaparotomy	complication, major	0/50	0	ND	ND
Tan J et al. (2008)[46]	myomectomy, isobaric gasless laparoscopic assisted minilaparotomy	complication, intraoperative	0/26	0	ND	ND
	myomectomy, isobaric gasless laparoscopy	complication, intraoperative	0/26	0	ND	ND
Tan J et al. (2009)[47]	myomectomy, laparoscopic assisted minilaparotomy	complication, intraoperative	0/40	0	ND	ND
	myomectomy, minilaparotomy	complication, intraoperative	0/40	0	ND	ND
Vercellino G et al. (2012)[48]	myomectomy	hydronephrosis	1/86	1.2	ND	ND
		cardiac arrhythmia	1/86	1.2	ND	ND
		embolism, pulmonary	1/86	1.2	ND	ND
	myomectomy plus uterine artery clipping	hydronephrosis	1/80	1.3	ND	ND
		sepsis due to pyelonephritis	1/80	1.3	ND	ND
		hernia, trocar site	1/80	1.3	ND	ND

Author, Year	Intervention	Harm	EOT Incidence	%	LFU Incidence	%
		thrombosis, sinus venous	1/80	1.3	ND	ND
Wang X et al. (2013)[33]	myomectomy	death	0/52	0	ND	ND
		complication, severe	0/52	0	ND	ND

Abbreviations: EOT=end of treatment; LFU=last followup; ND=no data

Transfusion Rates

Table G-8. Transfusion rates during or following myomectomy

Author, Year	Myomectomy Approach	Incidence	%
Alessandri F et al. (2006)[41]	minilaparotomy	0/74	0
Alessandri F et al. (2006)[41]	laparoscopic	0/74	0
Ardovino M et al. (2013)[49]	laparoscopic standard	0/72	0
Ardovino M et al. (2013)[49]	laparoscopic mini-invasive	0/98	0
Table Cicinelli E et al. (2009)[50]	minilaparotomy	0/40	0
Cicinelli E et al. (2009)[50]	laparoscopic assisted minilaparotomy	0/40	0
Mara M et al. (2006)[30]	open or laparoscopic	2/33	6.1
Rossetti A et al. (2001)[44]	laparoscopic	0/41	0
Rossetti A et al. (2001)[44]	abdominal	0/40	0
Seracchioli R et al. (2000)[51]	laparoscopic	0/66	0
Seracchioli R et al. (2000)[51]	abdominal	3/65	4.6
Sesti F et al. (2008)[45]	minilaparotomy	0/50	0
Sesti F et al. (2008)[45]	isobaric gasless laparoscopy	0/50	0
Vercellino G et al. (2012)[48]	myomectomy plus uterine artery clipping	0/80	0
Vercellino G et al. (2012)[48]	laparoscopic	0/86	0
Wang JJ et al. (2011)[52]	gasless laparoscopic	0/194	0
Wang JJ et al. (2011)[52]	conventional laparoscopic	6/190	3.2
Wang X et al. (2013)[33]	myomectomy	1/52	1.9
Zhao F et al. (2011)[53]	loop ligation with vasopressin	0/35	0
Zhao F et al. (2011)[53]	myomectomy with vasopressin	1/35	2.8
Zhao F et al. (2011)[53]	myomectomy	5/35	14.3

N is the number analyzed. The number analyzed was equal to the number randomized in all arms. Transfusion counts are intraoperative or postoperative. Eight studies did not report whether transfusion was required[29, 35, 46, 47, 54-57]

Table G-9. Transfusion rates during or following hysterectomy

Author, Year	Hysterectomy Approach	Incidence	%
Benassi L et al. (2002)[42]	abdominal	4/59	6.8
Benassi L et al. (2002)[42]	vaginal	2/60	3.3
Ferrari MM et al. (2000)[43]	laparoscopic assisted vaginal	0/31	0
Ferrari MM et al. (2000)[43]	vaginal	1/31	3
Hehenkamp WJ et al. (2005)[26]	hysterectomy	10/89	13.3
Hwang JL et al. (2002)[36]	abdominal	1/30	3.3
Hwang JL et al. (2002)[36]	laparoscopic assisted vaginal	5/30	16.7
Hwang JL et al. (2002)[36]	vaginal	1/30	3.3
Pinto I et al. (2003)[12]	abdominal	4/20	20
Seracchioli R et al. (2002)[37]	abdominal	1/62	1.6
Seracchioli R et al. (2002)[37]	total laparoscopic	0/60	0
Sesti F et al. (2008)[58]	laparoscopic assisted vaginal	0/40	0
Sesti F et al. (2008)[58]	vaginal	0/40	0
Sesti F et al. (2014)[59]	laparoscopic assisted vaginal	2/36	5.6
Sesti F et al. (2014)[59]	total laparoscopic	0/36	0

Author, Year	Hysterectomy Approach	Incidence	%
Sesti F et al. (2014)[59]	vaginal	0/36	0
Silva-Filho AL et al. (2006)[38]	total abdominal + hysterectomy, vaginal*	1/60	1.7
Soriano D et al. (2001)[60]	laparoscopic assisted vaginal	1/40	2.7
Soriano D et al. (2001)[60]	vaginal	1/40	2.5
Yen YK et al. (2002)[40]	laparoscopic assisted vaginal	2/32	6.3

Table G-9. Transfusion rates during or following hysterectomy, continued

Author, Year	Hysterectomy Approach	Incidence	%
Yen YK et al. (2002)[40]	laparoscopic assisted vaginal with bipolar coagulation of uterine vessels	1/29	3.4

N is the number analyzed. The number analyzed was equal to the number randomized in all arms. *One study reported transfusion counts for both groups. Transfusion counts are intraoperative or postoperative. Three studies did not report if transfusion was required[55, 61,, 62]

Table G-10. Transfusion rates during or following uterine artery embolism, occlusion, or HIFU (5 studies)

Author, Year	UAE/ UAO	Incidence	%
Hehenkamp WJ et al. (2005)[26]	UAE	0/81	0
Mara M et al. (2006)[30]	UAE	0/30	0
Mara M et al. (2008)[15]	UAE	0/58	0
Pinto I et al. (2003)[12]	UAE	0/40	0
Wang X et al. (2013)[33]	HIFU	0/48	0

Abbreviations: UAE=uterine artery embolization; HIFU=high intensity focused ultrasound

Data for Key Questions 3 and 4

Table G-11. Data extracted for Key Question 3

Citation	Design	N	Age, Mean	Age, SD	LMS	LMS Rate
Adelusola KA, Ogunniyi SO (2001)[63]	Retrospective	177	NR	NR	0	0/177
Ahmed AA, Stachurski J, Aziz EA, et al. (2002)[64]	Prospective	10	NR	NR	0	0/10
Angle HS, Cohen SM, Hidlebaugh D (1995)[65]	Retrospective	41	41	NR	0	0/41
Balgobin S, Maldonado PA, Chin K, et al. (2016)[66]	Retrospective	1629	46	11.3	0	0/435
Banaczek Z, Sikora K, Lewandowska-Andruszuk I (2004)[67]	Retrospective	309	44.5	NR	0	0/309
Barbieri RL, Dilena M, Chumas J, et al. (1993)[68]	RCT	20	33.7	NR	0	0/15
Begum S, Khan S (2004)[69]	Prospective	91	NR	NR	0	0/91
Bernard JP, Rizk E, Camatte S, et al. (2001)[70]	Prospective	75	NR	NR	0	0/75
Betjes HE, Hanstede MM, Emanuel MH, et al. (2009)[71]	Retrospective	539	44.3	NR	0	0/539
Birsan A, Deval B, Detchev R, et al. (2003)[72]	Prospective	24	NR	NR	0	0/24
Bojahr B, De Wilde RL, Tchartchian G (2015)[73]	Retrospective	10731	NR	NR	2	2/8720
Brohl AS, Li L, Andikyan V, et al. (2015)[74]	Retrospective	2075	38.3	6.1	2	2/2075
Bronz L, Suter T, Rusca T (1997)[75]	Prospective	25	NR	NR	0	0/25
Brown J, Taylor K, Ramirez PT, et al. (2015)[76]	Retrospective	808	NR	NR	1	1/400
Butt JL, Jeffery ST, Van der Spuy ZM (2012)[77]	Retrospective	106	NR	NR	0	0/106

Citation	Design	N	Age, Mean	Age, SD	LMS	LMS Rate
Campo S, Campo V, Gambadauro P (2005)[78]	Prospective	80	NR	NR	0	0/80
Chen SY, Chang DY, Sheu BC, et al. (2008)[79]	Prospective	136	NR	NR	0	0/136
Cicinelli E, Romano F, Anastasio PS, et al. (1995)[80]	Prospective	11	NR	NR	0	0/11
Clark Donat L, Clark M, Tower AM, et al. (2015)[81]	Retrospective	64	48.5	7.87	0	0/64
Colgan TJ, Pendergast S, LeBlanc M (1993)[82]	Retrospective	77	36.9	NR	0	0/77
Cormio G, Loizzi V, Ceci O, et al. (2015)[83]	Retrospective	588	NR	NR	3	3/588
Corson SL, Brooks PG (1991)[84]	Retrospective	92	40.1	NR	2	2/92
Crescini C (1993)[85]	Prospective	25	NR	NR	0	0/25
Cusidó M, Fargas F, Baulies S,et al. (2015)[86]	Retrospective	4014	46	NR	12	12/4014
Bushaqer NJ (2014)[87]	Retrospective	137	36	NR	0	0/137
De Falco M, Staibano S, Mascolo M, et al. (2009)[88]	RCT	62	37.3	NR	0	0/62
Deligdisch L, Hirschmann S, Altchek A (1997)[89]	Retrospective	60	NR	NR	0	0/60
Di Lieto A, De Falco M, Mansueto G, et al. (2005)[90]	RCT	70	36.8	NR	0	0/70
Dijkhuizen FP, De Vries LD, Mol BW, et al. (2000)[91]	Prospective	9	NR	NR	0	0/9
Dundr P, Mara M, Maskova J, et al. (2006)[92]	Retrospective	20	NR	NR	0	0/20
El-Mowafi D, Madkour W, Lall C, et al. (2004)[93]	Retrospective	165	45.8	NR	0	0/165
Emanuel MH, Wamsteker K (2005)[94]	Retrospective	28	NR	NR	0	0/28
Emanuel MH, Wamsteker K, Hart AA, et al. (1999)[95]	Retrospective	285	NR	NR	1	1/285
Fanfani F, Fagotti A, Bifulco G, et al. (2005)[96]	Prospective	213	NR	NR	0	0/213
Fedele L, Bianchi S, Dorta M, et al. (1991)[97]	Prospective	71	NR	NR	0	0/71
Ferrari MM, Berlanda N, Mezzopane R, et al. (2000)[98]	RCT	62	NR	NR	0	0/62
Fukuda M, Shimizu T, Fukuda K, et al. (1993)[99]	Retrospective	20	NR	NR	0	0/20
Gao Z, Li L, Meng Y. A .(2016)[100]	Retrospective	3986	47.9	NR	17	17/3986
Garcia CR, Tureck RW (1984)[101]	Prospective	17	NR	NR	0	0/17
Gavai M, Hupuczi P, Papp Z (2006)[102]	Retrospective	504	33	NR	0	0/504
Gaym A (2004)[103]	Retrospective	588	38.5	NR	0	0/588
Geethamala K, Murthy VS, Vani BR, Rao S (2016)[104]	Retrospective	820	NR	NR	1	1/820
Goldrath MH (1990)[105]	Retrospective	151	NR	NR	1	1/151
Gowri M, Mala G, Murthy S, et al. (2013)[106]	Retrospective	259	NR	NR	0	0/259
Grigoriadis C, Papaconstantinou E, Mellou A, et al. (2012)[107]	Retrospective	10	38.2	NR	0	0/10
Gurung G, Pradhan N, Rana SRA (2015)[108]	Retrospective	40	NR	NR	0	0/40
Hallez JP (1995)[109]	Retrospective	284	NR	NR	0	0/284
Hanafi M (2005)[110]	Retrospective	145	NR	NR	0	0/145
Hanafi M (2013)[111]	Retrospective	134	43.7	NR	0	0/134

Citation	Design	N	Age, Mean	Age, SD	LMS	LMS Rate
Harmanli OH, Bevilacqua SA, Dandolu V, et al. (2005)[112]	Retrospective	333	44.2	NR	0	0/333
Hasson HM, Rotman C, Rana N, et al. (1992)[113]	Retrospective	56	37.2	NR	0	0/56
Hasson HM, Rotman C, Rana N, et al. (1993)[114]	Retrospective	22	40.4	NR	0	0/22
Hoffman MS, DeCesare S, Kalter C (1994)[115]	Prospective	47	41.9	NR	0	0/47
Huang JQ, Lathi RB, Lemyre M, et al. (2010)[116]	Retrospective	131	41	NR	0	0/131
Huang PS, Sheu BC, Huang SC, Chang WC (2016)[117]	Retrospective	83	41.1	7.5	0	0/83
Jansen FW, de Kroon CD, van Dongen H, et al. (2006)[118]	Prospective	89	43.8	NR	0	0/89
Jha R, Pant AD, Jha A, et al. (2006)[119]	Retrospective	55	37.6	NR	0	0/55
Johns DA, Diamond MP (1994)[120]	Retrospective	11	39.2	NR	0	0/11
Kafy S, Huang JY, Al-Sunaidi M, et al. (2006)[121]	Retrospective	934	59.6	NR	0	0/934
Kalogiannidis I, Prapas N, Xiromeritis P, et al. (2010)[122]	Prospective	75	34.8	4.5	0	0/75
Kamikabeya TS, Etchebehere RM, Nomelini RS, et al. (2010)[123]	Retrospective	1364	NR	NR	1	1/1364
Kiltz RJ, Rutgers J, Phillips J, et al. (1994)[124]	Prospective	28	31	1.8	0	0/28
Kinay T, Basarir ZO, Tuncer SF et al. (2016)[125]	Retrospective	947	47.1	NR	2	2/947
Klimentova DV, Braila AD, Simionescu C, et al. (2012)[126]	Retrospective	959	NR	NR	0	0/959
Kohama T, Hashimoto S, Ueno H, et al. (1997)[127]	Prospective	25	NR	NR	0	0/25
Kuzel D, Toth D, Fucikova Z, et al. (1999)[128]	Prospective	45	NR	NR	0	0/45
Landi S, Zaccoletti R, Ferrari L, et al. (2001)[129]	Prospective	368	NR	NR	0	0/368
Laughead MK, Stones LM (1997)[130]	Prospective	8	NR	NR	0	0/8
Leibsohn S, d'Ablaing G, Mishell DR, Jr., et al. (1990)[131]	Retrospective	1429	NR	NR	7	7/1429
Leung F, Terzibachian JJ, Gay C, et al. (2009)[132]	Retrospective	1297	48	NR	3	3/1297
Levens ED, Wesley R, Premkumar A, et al. (2009)[133]	RCT	18	NR	NR	0	0/18
Lieng M, Berner E, Busund B (2015)[134,]	Retrospective	4771	61.2	12.3	6	6/4771
Lim SS, Sockalingam JK, Tan PC (2008)[136]	RCT	66	46.5	NR	0	0/64
Litta P, Fantinato S, Calonaci F, et al. (2010)[137]	RCT	160	37.34	NR	0	0/160
Liu L, Li Y, Xu H, et al. (2011)[138]	Prospective	167	NR	NR	0	0/167
Liu WM, Tzeng CR, Yi-Jen C, et al. (2004)[139]	Prospective	486	NR	NR	0	0/486
Lyons TL, Adolph AJ, Winer WK (2004)[140]	Retrospective	54	47.3	NR	0	0/54
MacKenzie IZ, Naish C, Rees M, et al. (2004)[141]	Retrospective	118	47.5	NR	0	0/118
Mais V, Ajossa S, Guerriero S, et al. (1996)[142]	RCT	40	NR	NR	0	0/40
Mansour FW, Kives S, Urbach DR, et al. (2012)[143]	Retrospective	59	34.7	NR	0	0/59

Citation	Design	N	Age, Mean	Age, SD	LMS	LMS Rate
Mara M, Fucikova Z, Kuzel D, et al. (2006)[144]	Prospective	80	33.5	NR	0	0/80
Marana R, Busacca M, Zupi E, et al. (1999)[145]	RCT	55	NR	NR	0	0/55
Mecke H, Wallas F, Brocker A, et al. (1995)[146]	Retrospective	215	36	NR	0	0/215
Mettler L, Alvarez-Rodas E, Semm K (1995)[147]	Retrospective	500	43.2	NR	1	1/500
Milad MP, Morrison K, Sokol A, et al. (2001)[148]	Prospective	69	43.9	NR	0	0/69
Miskry T, Magos A (2003)[149]	RCT	36	NR	NR	0	0/9
Moghadam R, Lathi RB, Shahmohamady B, et al. (2006)[150]	Retrospective	144	41	NR	0	0/144
Muhammad Z, Ibrahaim S, Agu O (2009)[151]	Retrospective	78	46.6	NR	0	0/75
Munoz JL, Jimenez JS, Hernandez C, et al. (2003)[152]	Retrospective	120	44.8	NR	0	0/120
Nemec W, Inwald EC, Buchholz S, et al. (2016)[153]	Retrospective	984	53.8	NR	5	5/984
Nezhat F, Nezhat CH, Admon D, et al. (1995)[154]	Retrospective	28	NR	NR	0	0/28
Obed JY, Bako B, Usman JD, et al. (2011)[155]	Prospective	331	30.1	NR	0	0/331
O'Hanlan KA, Dibble SL, Garnier AC, et al. (2007)[156]	Retrospective	258	50	NR	0	0/258
Okezie O, Ezegwui HU (2006)[157]	Retrospective	190	NR	NR	0	0/190
Ouldamer L, Rossard L, Arbion F, et al. (2014)[158]	Retrospective	709	49.5	NR	0	0/709
Palomba S, Orio F, Jr., Russo T, et al. (2005)[159]	RCT	40	53.4	NR	0	0/40
Palomba S, Zupi E, Falbo A, et al. (2010)[160]	Prospective	30	30.2	NR	0	0/30
Palomba S, Zupi E, Russo T, et al. (2007)[161]	RCT	136	NR	NR	0	0/136
Parker WH, Fu YS, Berek JS (1994)[162]	Retrospective	1332	NR	NR	1	1/1332
Paul GP, Naik SA, Madhu KN, et al. (2010)[163]	Retrospective	1001	32.6	NR	1	1/1001
Perveen S, Tayyab S (2008)[164]	Retrospective	20	NR	NR	0	0/20
Phillips DR, Nathanson HG, Milim SJ, et al. (1995)[165]	Prospective	38	NR	NR	0	0/38
Picerno TM, Wasson MN, Gonzalez Rios AR, et al. (2016)[166]	Retrospective	1004	45.7	NR	0	0/258
Polena V, Mergui JL, Perrot N, et al. (2007)[167]	Retrospective	235	47.9	NR	0	0/235
Pron G, Mocarski E, Cohen M, et al. (2003)[168]	Prospective	8	NR	NR	0	0/8
Radosa MP, Owsianowski Z, Mothes A, et al. (2014)[169]	Retrospective	224	37.9	NR	0	0/224
Raine-Bennett T, Tucker LY, Zaritsky E, et al. (2016)[170]	Pop based cohort	34728	NR	NR	172	81/34728
Raspagliesi , F. (2016)[171]	Retrospective	4000	47.2	NR	91	91/4000
Rechberger, T .(2016)[172]	Retrospective	334	NR	NR	0	0/334
Rein MS, Friedman AJ, Stuart JM, et al. (1990)[55]	RCT	20	NR	NR	0	0/20
Reiter RC, Wagner PL, Gambone JC	Retrospective	104	41.5	NR	0	0/104

Citation	Design	N	Age, Mean	Age, SD	LMS	LMS Rate
(1992)[173]						
Rodriguez AM, Asoglu MR, Sak ME, et al. (2015)[174]	Retrospective	13964	40.9	7	19	19/13964
Rosenblatt P, Makai G, DiSciullo A (2010)[175]	Retrospective	24	50.2	NR	0	0/24
Rovio PH, Helin R, Heinonen PK (2009)[176]	Retrospective	53	44.7	NR	0	0/53
Rutgers JL, Spong CY, Sinow R, et al. (1995)[177]	RCT	46	38	NR	0	0/46
Sahagun Quevedo JA, Perez Ruiz JC, Cherem B, et al. (1994)[178]	Retrospective	594	NR	NR	0	0/594
Samaila M, Adesiyun AG, Agunbiade OS, et al. (2009)[179]	Retrospective	196	44.6	NR	0	0/196
Sandberg EM, van den Haak L, Bosse T, et al. (2016)[180]	Prospective	5	34.6	NR	0	0/5
Sayyah-Melli M, Tehrani-Gadim S, Dastranj-Tabrizi A, et al. (2009)[181]	RCT	23	39.67	NR	0	0/23
Schutz K, Possover M, Merker A, et al. (2002)[182]	RCT	48	NR	NR	0	0/48
Seidman MA, Oduyebo T, Muto MG, et al. (2012)[183]	Retrospective	1091	NR	NR	1	1/1091
Seki K, Hoshihara T, Nagata I (1992)[184]	Retrospective	1886	45.5	NR	7	7/1886
Seracchioli R, Venturoli S, Vianello F, et al. (2002)[185]	RCT	122	46.3	NR	0	0/122
Serur E, Zambrano N, Brown K, et al. (2016)[186]	Retrospective	117	NR	NR	1	1/88
Shen CC, Wu MP, Kung FT, et al. (2003)[187]	Retrospective	1521	45.5	NR	0	0/1521
Shergill SK, Shergill HK, Gupta M, et al. (2002)[188]	RCT	34	NR	NR	0	0/34
Sikora-Szczęśniak DL, Sikora W, Szczęśniak G (2013) [189]	Retrospective	294	45.6	NR	0	0/39
Silva BA, Falcone T, Bradley L, et al. (2000)[190]	Prospective	39	37	NR	0	0/37
Silva BA, Falcone T, Bradley L, et al. (2000)[190]	Retrospective	37	37	NR	0	0/37
Sinha R, Hegde A, Mahajan C, et al. (2008)[191]	Prospective	505	34.44	NR	2	2/505
Smits R, De Kruif J, Van Heteren C (2016)[192]	Retrospective	358	44.5	NR	0	0/171
Song T, Kim TJ, Lee SH, et al. (2015)[193]	RCT	100	39.3	5.7	0	0/100
Takamizawa S, Minakami H, Usui R, et al. (1999)[194]	Retrospective	923	44.5	NR	1	1/923
Tan J, Sun Y, Dai H, et al. (2008)[195]	RCT	52	NR	NR	0	0/52
Tan J, Sun Y, Zhong B, et al. (2009)[196]	RCT	80	36.3	NR	0	0/80
Theben JU, Schellong AR, Altgassen C, et al. (2013)[197]	Retrospective	1132	45.9	NR	2	2/1132
Tinelli A, Hurst BS, Hudelist G, et al. (2012)[198]	Prospective	235	NR	NR	0	0/235
Toubia T, Moulder JK, Schiff LD, et al. (2016)[199]	Prospective	20	NR	NR	0	0/20
Uccella S, Cromi A, Serati M, et al. (2014)[200]	Retrospective	71	48	NR	0	0/71
Ueki M, Okamoto Y, Tsurunaga T, et al. (1995)[201]	Retrospective	230	42.5	NR	0	0/230
van Dongen H, Emanuel MH, Wolterbeek R, et al. (2008)[202]	RCT	22	48.2	NR	0	0/22

Citation	Design	N	Age, Mean	Age, SD	LMS	LMS Rate
Varma R, Soneja H, Clark TJ, et al. (2009)[203]	Prospective	92	NR	NR	1	1/92
Venkatesan AM, Partanen A, Pulanic TK, et al. (2012)[204]	Prospective	9	NR	NR	0	0/9
Vercellini P, Cribiù FM, Bosari S, et al. (2016)[205]	Retrospective	2356	39	6	1	1/2356
Walid MS, Heaton RL (2010)[206]	Retrospective	41	NR	NR	0	0/41
Wamsteker K, Emanuel MH, de Kruif JH (1993)[207]	Prospective	51	NR	NR	0	0/51
Wang CJ, Soong YK, Lee CL (2007)[208]	Prospective	18	NR	NR	0	0/18
West S, Ruiz R, Parker WH (2006)[209]	Retrospective	91	40	NR	0	0/91
Widrich T, Bradley LD, Mitchinson AR, et al. (1996)[210]	Prospective	13	NR	NR	0	0/13
Williams AR, Critchley HO, Osei J, et al. (2007)[211]	RCT	33	NR	NR	0	0/33
Williams CD, Marshburn PB (1998)[212]	Prospective	5	38.5	NR	0	0/5
Wortman M, Dagget A (1995)[213]	Retrospective	75	43.2	NR	0	0/75
Yen YK, Liu WM, Yuan CC, et al. (2002)[214]	RCT	64	NR	NR	0	0/61
Ylikorkala O, Tiitinen A, Hulkko S, et al. (1995)[215]	RCT	101	43	NR	0	0/101
Yoo EH, Lee PI, Huh CY, et al. (2007)[216]	Retrospective	512	33	NR	0	0/512
Yoon HJ, Kyung MS, Jung US, et al. (2007)[217]	Retrospective	51	34.9	NR	0	0/51
Zhang J, Li T, Zhang J, et al. (2016)[218]	Retrospective	3021	47.88	6.2	5	5/3021
Zhang J, Zhang J, Dai Y, et al. (2015)[219]	Retrospective	4248	NR	NR	1	1/4248
Zhao WC, Bi FF, Li D, et al. (2015)[220]	Retrospective	10248	48.2	7.64	13	13/10248
Zhu L, Lang JH, Liu CY, et al. (2009)[221]	RCT	101	NR	NR	0	0/101
Zullo F, Palomba S, Corea D, et al. (2004)[222]	RCT	60	28.2	NR	0	0/60

Table G-12. Patient data extracted from studies for Key Question 4

Author (LMS Total)	Preoperative	Initial Surgery	Morcellation	Power	Cancer Stage (First)	Upstaged	Months followup	Outcome	Age	Menopausal Status	Notes
Einstein MH et al., 2008[223] (5)	Benign	LSC SCH	Yes	Yes	I	No	30	NED	NR	NR	
	Benign	LMYOM	Yes	Yes	I	Yes	61	NED	NR	NR	
	Benign	SCH	Yes	No	I	Yes	31	AWD	NR	NR	
	Benign	SCH BSO	No	No	I	No	37	NED	NR	NR	
	Benign	SCH BSO	No	No	I	Yes	6	AWD	NR	NR	
Kamikabeya TS et al., 2010[123] (1)	Benign	TAH BSO	No	No	NR	No	2	Dead	58	Post	
Takamiza	Benign	TAH	No	No	NR	NR	132	NED	44	NR	Received

Author (LMS Total)	Preoperative	Initial Surgery	Morcellation	Power	Cancer Stage (First)	Upstaged	Months followup	Outcome	Age	Menopausal Status	Notes
wa S et al., 1999[224] (1)											chemo as treatment
Oduyebo T et al., 2014[225] (14)	Benign	LSC SCH	Yes	Yes	I	No	27	NED	NR	NR	
	Benign	LSC SCH	Yes	Yes	I	No	38	NED	NR	NR	
	Benign	LMYO M	Yes	Yes	I	No	48.7	NED	NR	NR	
	Benign	LSC SCH	Yes	Yes	IV	NA	3	Dead	NR	NR	
	Benign	LAVH	Yes	No	NR	NA	72	AWD	NR	NR	
	Benign	LMYO M	Yes	Yes	I	Yes	37.5	Dead	NR	NR	
	Benign	LSC SCH	Yes	Yes	III	Yes	5.1	Dead	NR	NR	
	Benign	LSC SCH	Yes	Yes	NR	NA	48	Dead	NR	NR	
	Benign	LSC SCH	Yes	Yes	I	No	20.2	NED	NR	NR	
	Benign	TVH	Yes	No	I	NA	26	NED	NR	NR	
	Benign	TVH	Yes	No	I	NA	1.8	NED	NR	NR	
	Benign	Robotic TLH	Yes	Yes	I	NA	15.3	NED	NR	NR	
	Benign	LSC HYST	Yes	No	NR	NA	30.4	Dead	NR	NR	
	Benign	LAVH	Yes	No	I	No	4.5	NED	NR	NR	
Graebe K et al., 2015[226] (2)	Benign	MIS HYST	Yes	Yes	I	Yes	8	AWD	NR	Pre	Mass staging years later
	Benign	MIS HYST	Yes	Yes	I	Yes	13	AWD	NR	Pre	
Tan-Kim J et al., 2014[227] (5)	Benign	LSC HYST	Yes	Yes	NR	no	31	NED	51	Post	
	Benign	LSC HYST	Yes	Yes	NR	Yes	51	NED	41	Pre	
	Benign	LSC HYST	Yes	Yes	NR	Yes	36	Dead	48	Pre	
	Benign	TAH+BSO	no	no	NR	no	37	Alive	66	post	
	Benign	TAH+BSO	no	no	NR	yes	23	Dead	54	post	
Sinha R et al., 2008[228] (2)	Benign	LSC MYOM	Yes	Yes	NR	NR	42	Alive	NR	Pre	
	Benign	LSC MYOM	Yes	Yes	NR	NR	42	Alive	NR	Pre	
Tan A et al., 2015[229] (2)	Benign	LSC MYOM	Yes	Yes	NR	NR	34	Dead	48	Pre	
	Benign	VAG HYST	Yes	No	NR	NR	21	AWD	38	Pre	
Seidman MA et al., 2012[230] (7)	Benign	Varied	Yes	Yes	I	No	38	NED	43	NR	
	Benign	Varied	Yes	Yes	I	No	9	NED	48	NR	
	Benign	Varied	Yes	Yes	I	No	42	Alive	42	NR	
	Benign	Varied	Yes	Yes	I	Yes (late)	27	Dead	58	Post	

Author (LMS Total)	Preoperative	Initial Surgery	Morcellation	Power	Cancer Stage (First)	Upstaged	Months followup	Outcome	Age	Menopausal Status	Notes
	Benign	Varied	Yes	Yes	I	Yes	17	Dead	47	NR	
	Benign	Varied	Yes	Yes	I	Yes	39	Alive	49	NR	
	Benign	Varied	Yes	Yes	I	Yes	29	Dead	68	Post	
Zhang J et al., 2015[231] (1)	Benign	ABD MYOM	Yes	No	NR	No	58	NED	35	Pre	
Bojah B et al., 2015[232] (2)	Benign	LSC SCH	Yes	Yes	I	No	137	NED	49	NR	
	Benign	LSC SCH	Yes	Yes	I	Yes (late)	13	Dead	49	NR	
Theben JU et al., 2013[233] (2)	Benign	LSC SCH	Yes	No	pT1b, pNx, cM0	No	52	NED	43	NR	
	Benign	LSC SCH	Yes	Yes	pT1c, pNx,cM0	No	36	NED	49	NR	
Serur E et al., 2016[186] (1)	Benign	LSC HYST	Yes	No	NR	NR	28	NED	56	post	
Vercellini P et al., 2016[205] (1)	Benign	LSC MYOM	Yes	Yes	NR	NR	4	Dead	39	NR	
Cusido M et al., 2015[86] (8)	Benign	HYST	Yes	Yes	NR	NR	36	AWD	50	NR	
	Benign	HYST	Yes	No	NR	NR	33	Dead	48	NR	
	Benign	MYOM	Yes	Yes	NR	NR	27	Dead	56	NR	
	Benign	HYST	Yes	No	NR	NR	22	AWD	46	NR	
	Benign	HYST	No	No	NR	NR	14	AWD	47	NR	
	Benign	HYST	No	No	NR	NR	90	AWD	52	NR	
	Benign	HYST	No	No	NR	NR	16	AWD	51	NR	
	Benign	HYST	No	No	NR	NR	12	AWD	63	NR	
Nemec W et al., 2016[153] (64)	Benign	HYST	Yes	No	I	NR	28	Alive	53.8	NR	
	Benign	HYST	Yes	No	I	NR	31	Alive	53.8	NR	
	Benign	HYST	Yes	No	I	NR	39	Alive	53.8	NR	
	Benign	HYST	Yes	No	I	NR	41	Alive	53.8	NR	
	Benign	HYST	Yes	No	I	NR	52	Alive	53.8	NR	
	Benign	HYST	Yes	No	I	NR	66	Alive	53.8	NR	
	Benign	HYST	Yes	No	I	NR	67	Alive	53.8	NR	
	Benign	HYST	Yes	No	I	NR	93	Alive	53.8	NR	
	Benign	HYST	Yes	No	I	NR	104	Alive	53.8	NR	
	Benign	HYST	Yes	No	I	NR	113	Alive	53.8	NR	
	Benign	HYST	Yes	No	II to IV	NR	127	Alive	53.8	NR	
	Benign	HYST	Yes	No	II to IV	NR	23	Dead	53.8	NR	
	Benign	HYST	Yes	No	II to IV	NR	34	Dead	53.8	NR	
	Benign	HYST	Yes	No	NR	NR	41	Dead	53.8	NR	
	Benign	HYST	Yes	No	NR	NR	127	Dead	53.8	NR	
	Benign	HYST	No	No	I	NR	17	Alive	53.8	NR	
	Benign	HYST	No	No	I	NR	18	Alive	53.8	NR	
	Benign	HYST	No	No	I	NR	20	Alive	53.8	NR	
	Benign	HYST	No	No	I	NR	26	Alive	53.8	NR	

Author (LMS Total)	Preoperative	Initial Surgery	Morcellation	Power	Cancer Stage (First)	Upstaged	Months followup	Outcome	Age	Menopausal Status	Notes
	Benign	HYST	No	No	I	NR	31	Alive	53.8	NR	
	Benign	HYST	No	No	I	NR	34	Alive	53.8	NR	
	Benign	HYST	No	No	I	NR	36	Alive	53.8	NR	
	Benign	HYST	No	No	I	NR	40	Alive	53.8	NR	
	Benign	HYST	No	No	I	NR	42	Alive	53.8	NR	
	Benign	HYST	No	No	I	NR	43	Alive	53.8	NR	
	Benign	HYST	No	No	I	NR	43	Alive	53.8	NR	
	Benign	HYST	No	No	I	NR	44	Alive	53.8	NR	
	Benign	HYST	No	No	I	NR	45	Alive	53.8	NR	
	Benign	HYST	No	No	I	NR	53	Alive	53.8	NR	
	Benign	HYST	No	No	I	NR	55	Alive	53.8	NR	
	Benign	HYST	No	No	I	NR	64	Alive	53.8	NR	
	Benign	HYST	No	No	I	NR	68	Alive	53.8	NR	
	Benign	HYST	No	No	I	NR	72	Alive	53.8	NR	
	Benign	HYST	No	No	I	NR	92	Alive	53.8	NR	
	Benign	HYST	No	No	I	NR	94	Alive	53.8	NR	
	Benign	HYST	No	No	I	NR	95	Alive	53.8	NR	
	Benign	HYST	No	No	II to IV	NR	96	Alive	53.8	NR	
	Benign	HYST	No	No	II to IV	NR	101	Alive	53.8	NR	
	Benign	HYST	No	No	II to IV	NR	101	Alive	53.8	NR	
	Benign	HYST	No	No	II to IV	NR	116	Alive	53.8	NR	
	Benign	HYST	No	No	II to IV	NR	125	Alive	53.8	NR	
	Benign	HYST	No	No	II to IV	NR	128	Alive	53.8	NR	
	Benign	HYST	No	No	II to IV	NR	1	Dead	53.8	NR	
	Benign	HYST	No	No	II to IV	NR	2	Dead	53.8	NR	
	Benign	HYST	No	No	II to IV	NR	4	Dead	53.8	NR	
	Benign	HYST	No	No	II to IV	NR	4	Dead	53.8	NR	
	Benign	HYST	No	No	II to IV	NR	5	Dead	53.8	NR	
	Benign	HYST	No	No	II to IV	NR	9	Dead	53.8	NR	
	Benign	HYST	No	No	II to IV	NR	12	Dead	53.8	NR	
	Benign	HYST	No	No	II to IV	NR	13	Dead	53.8	NR	
	Benign	HYST	No	No	II to IV	NR	15	Dead	53.8	NR	
	Benign	HYST	No	No	II to IV	NR	15	Dead	53.8	NR	
	Benign	HYST	No	No	II to IV	NR	16	Dead	53.8	NR	
	Benign	HYST	No	No	II to IV	NR	18	Dead	53.8	NR	
	Benign	HYST	No	No	II to IV	NR	19	Dead	53.8	NR	

Author (LMS Total)	Preoperative	Initial Surgery	Morcellation	Power	Cancer Stage (First)	Upstaged	Months followup	Outcome	Age	Menopausal Status	Notes
	Benign	HYST	No	No	II to IV	NR	21	Dead	53.8	NR	
	Benign	HYST	No	No	II to IV	NR	25	Dead	53.8	NR	
	Benign	HYST	No	No	II to IV	NR	29	Dead	53.8	NR	
	Benign	HYST	No	No	II to IV	NR	33	Dead	53.8	NR	
	Benign	HYST	No	No	II to IV	NR	34	Dead	53.8	NR	
	Benign	HYST	No	No	II to IV	NR	43	Dead	53.8	NR	
	Benign	HYST	No	No	II to IV	NR	53	Dead	53.8	NR	
	Benign	HYST	No	No	II to IV	NR	77	Dead	53.8	NR	
	Benign	HYST	No	No	NR	NR	78	Dead	53.8	NR	
Raspagliesi F et al., 2016[171] (91)	Benign	varied	No	No	I	No	5	Alive	NR	NR	
	Benign	varied	No	No	I	No	7	Alive	NR	NR	
	Benign	varied	No	No	I	No	8	Alive	NR	NR	
	Benign	varied	No	No	I	No	11	Alive	NR	NR	
	Benign	varied	No	No	I	No	12	Alive	NR	NR	
	Benign	varied	No	No	I	No	15	Alive	NR	NR	
	Benign	varied	No	No	I	No	16	Alive	NR	NR	
	Benign	varied	No	No	I	No	22	Alive	NR	NR	
	Benign	varied	No	No	I	No	24	Alive	NR	NR	
	Benign	varied	No	No	I	No	8	Dead	NR	NR	
	Benign	varied	No	No	I	No	11	Dead	NR	NR	
	Benign	varied	No	No	I	No	13	Dead	NR	NR	
	Benign	varied	No	No	I	No	13	Dead	NR	NR	
	Benign	varied	No	No	I	No	13	Dead	NR	NR	
	Benign	varied	No	No	I	No	15	Dead	NR	NR	
	Benign	varied	No	No	I	No	15	Dead	NR	NR	
	Benign	varied	No	No	I	No	18	Dead	NR	NR	
	Benign	varied	No	No	I	No	19	Dead	NR	NR	
	Benign	varied	No	No	I	No	24	Alive	NR	NR	
	Benign	varied	No	No	I	No	24	Alive	NR	NR	
	Benign	varied	No	No	I	No	24	Alive	NR	NR	
	Benign	varied	No	No	I	No	24	Alive	NR	NR	
	Benign	varied	No	No	I	No	24	Alive	NR	NR	
	Benign	varied	No	No	I	No	24	Alive	NR	NR	
	Benign	varied	No	No	I	No	24	Alive	NR	NR	
	Benign	varied	No	No	I	No	24	Alive	NR	NR	
	Benign	varied	No	No	I	No	24	Alive	NR	NR	
	Benign	varied	No	No	I	No	24	Alive	NR	NR	
	Benign	varied	No	No	I	No	24	Alive	NR	NR	
	Benign	varied	No	No	I	No	24	Alive	NR	NR	
	Benign	varied	No	No	I	No	24	Alive	NR	NR	
	Benign	varied	No	No	I	No	24	Alive	NR	NR	
	Benign	varied	No	No	I	No	24	Alive	NR	NR	
	Benign	varied	No	No	I	No	24	Alive	NR	NR	
	Benign	varied	No	No	I	No	24	Alive	NR	NR	
	Benign	varied	No	No	I	No	24	Alive	NR	NR	
	Benign	varied	No	No	I	No	24	Alive	NR	NR	

Author (LMS Total)	Preoperative	Initial Surgery	Morcellation	Power	Cancer Stage (First)	Upstaged	Months followup	Outcome	Age	Menopausal Status	Notes
	Benign	varied	No	No	I	No	24	Alive	NR	NR	
	Benign	varied	No	No	I	No	24	Alive	NR	NR	
	Benign	varied	No	No	I	No	24	Alive	NR	NR	
	Benign	varied	No	No	I	No	24	Alive	NR	NR	
	Benign	varied	No	No	I	No	24	Alive	NR	NR	
	Benign	varied	No	No	I	No	24	Alive	NR	NR	
	Benign	varied	No	No	I	No	24	Alive	NR	NR	
	Benign	varied	No	No	I	No	24	Alive	NR	NR	
	Benign	varied	No	No	I	No	24	Alive	NR	NR	
	Benign	varied	No	No	I	No	24	Alive	NR	NR	
	Benign	varied	No	No	I	No	24	Alive	NR	NR	
	Benign	varied	No	No	I	No	24	Alive	NR	NR	
	Benign	varied	No	No	I	No	24	Alive	NR	NR	
	Benign	varied	No	No	I	No	24	Alive	NR	NR	
	Benign	varied	No	No	I	No	24	Alive	NR	NR	
	Benign	varied	No	No	I	No	24	Alive	NR	NR	
	Benign	varied	No	No	I	No	24	Alive	NR	NR	
	Benign	varied	No	No	I	No	24	Alive	NR	NR	
	Benign	varied	No	No	I	No	24	Alive	NR	NR	
	Benign	varied	No	No	I	No	24	Alive	NR	NR	
	Benign	varied	yes	yes	I	No	10	Dead	NR	NR	
	Benign	varied	yes	yes	I	No	10	Dead	NR	NR	
	Benign	varied	yes	yes	I	No	10	Dead	NR	NR	
	Benign	varied	yes	yes	I	No	10	Dead	NR	NR	
	Benign	varied	yes	yes	I	No	10	Dead	NR	NR	
	Benign	varied	yes	yes	I	No	11	Dead	NR	NR	
	Benign	varied	yes	yes	I	No	15	Dead	NR	NR	
	Benign	varied	yes	yes	I	No	18	Dead	NR	NR	
	Benign	varied	yes	yes	I	No	20	Dead	NR	NR	
	Benign	varied	yes	yes	I	No	23	Dead	NR	NR	
	Benign	varied	yes	yes	I	No	23	Dead	NR	NR	
	Benign	varied	yes	yes	I	No	23	Dead	NR	NR	
	Benign	varied	yes	yes	I	No	24	Dead	NR	NR	
	Benign	varied	yes	yes	I	No	24	Dead	NR	NR	
	Benign	varied	yes	yes	I	No	6	Alive	NR	NR	
	Benign	varied	yes	yes	I	No	10	Alive	NR	NR	
	Benign	varied	yes	yes	I	No	12	Alive	NR	NR	
	Benign	varied	yes	yes	I	No	14	Alive	NR	NR	
	Benign	varied	yes	yes	I	No	15	Alive	NR	NR	
	Benign	varied	yes	yes	I	No	19	Alive	NR	NR	
	Benign	varied	yes	yes	I	No	24	Alive	NR	NR	
	Benign	varied	yes	No	I	No	24	Alive	NR	NR	
	Benign	varied	yes	No	I	No	24	Alive	NR	NR	
	Benign	varied	yes	No	I	No	24	Alive	NR	NR	
	Benign	varied	yes	No	I	No	24	Alive	NR	NR	
	Benign	varied	yes	No	I	No	24	Alive	NR	NR	
	Benign	varied	yes	No	I	No	24	Alive	NR	NR	
	Benign	varied	yes	No	I	No	24	Alive	NR	NR	
	Benign	varied	yes	No	I	No	24	Alive	NR	NR	
	Benign	varied	yes	No	I	No	24	Alive	NR	NR	
	Benign	varied	yes	No	I	No	24	Alive	NR	NR	
	Benign	varied	yes	No	I	No	24	Alive	NR	NR	
	Benign	varied	yes	No	I	No	24	Alive	NR	NR	
	Benign	varied	yes	No	I	No	24	Alive	NR	NR	

Author (LMS Total)	Preoperative	Initial Surgery	Morcellation	Power	Cancer Stage (First)	Upstaged	Months followup	Outcome	Age	Menopausal Status	Notes
Brown J et al., 2015[234] (1)	Benign	LSC SCH (converted to TAH)	no	no	NR	no	54.3	Dead	60	post	
Brohl A et al., 2015[235] (1)	Benign	H'SCOPE MYO	no	no	NR	yes	14	NED	49	pre	
Zhang J et al., 2016[236] (2)	Benign	TLH + BSO	yes	no	NR	NR	54	NED	56	post	
	Benign	TAH	no	no	NR	no	17	NED	43	post	
Cormio G et al.[237] (3)	Benign	LAP MYOM	yes	no	NR	no	24	NED	NR	NR	
	Benign	LAP MYOM	yes	no	NR	no	22	NED	NR	NR	
	Benign	LAP MYOM	yes	no	NR	NR	64	Dead	NR	NR	
Lin KH et al., 2015[238] (20)	Benign	TAH	No	No	I	No	20	Dead	52.7	NR	
	Benign	TAH	No	No	I	NR	25	Dead	52.7	NR	
	Benign	TAH	No	No	I	NR	26	Dead	52.7	NR	
	Benign	TAH	No	No	I	NR	43	Dead	52.7	NR	
	Benign	TAH	No	No	I	NR	43	Dead	52.7	NR	
	Benign	TAH	No	No	I	NR	43	Dead	52.7	NR	
	Benign	TAH	No	No	I	NR	43	Dead	52.7	NR	
	Benign	TAH	No	No	I	NR	57	Dead	52.7	NR	
	Benign	TAH	No	No	I	NR	57	Dead	52.7	NR	
	Benign	TAH	No	No	I	NR	248	Alive	52.7	NR	
	Benign	TAH	No	No	I	NR	248	Alive	52.7	NR	
	Benign	TAH	No	No	I	NR	248	Alive	52.7	NR	
	Benign	TAH	No	No	I	NR	248	Alive	52.7	NR	
	Benign	TAH	No	No	I	NR	248	Alive	52.7	NR	
	Benign	TAH	No	No	I	NR	248	Alive	52.7	NR	
	Benign	TAH	No	No	I	NR	248	Alive	52.7	NR	
	Benign	TAH	No	No	I	NR	248	Alive	52.7	NR	
	Benign	TAH	No	No	I	NR	248	Alive	52.7	NR	
	Benign	TAH	No	No	I	NR	248	Alive	52.7	NR	
Perri T et al., 2009[239] (37)	NR	TAH	No	No	I	NR	6	Dead	48	Post	
	NR	TAH	No	No	I	NR	10	Dead	48	Post	
	NR	TAH	No	No	I	NR	14	Dead	48	Post	
	NR	TAH	No	No	I	NR	14	Dead	48	Post	
	NR	TAH	No	No	I	NR	15	Dead	48	Post	
	NR	TAH	No	No	I	NR	17	Dead	48	Post	
	NR	TAH	No	No	I	NR	49	Dead	48	Post	
	NR	TAH	No	No	I	NR	56	Dead	48	Pre	
	NR	TAH	No	No	I	NR	78	Dead	48	Pre	
	NR	TAH	No	No	I	NR	11	Alive	48	Pre	
	NR	TAH	No	No	I	NR	43	Alive	48	Pre	
	NR	TAH	No	No	I	NR	62	Alive	48	Pre	
	NR	TAH	No	No	I	NR	72	Alive	48	Pre	
	NR	TAH	No	No	I	NR	140	Alive	48	Pre	
	NR	TAH	No	No	I	NR	149	Alive	48	Pre	
	NR	TAH	No	No	I	NR	180	Alive	48	Pre	

Author (LMS Total)	Preoperative	Initial Surgery	Morcellation	Power	Cancer Stage (First)	Upstaged	Months followup	Outcome	Age	Menopausal Status	Notes
	NR	TAH	No	No	I	NR	203	Alive	48	Pre	
	NR	TAH	No	No	I	NR	211	Alive	48	Pre	
	NR	TAH	No	No	I	NR	265	Alive	48	Pre	
	NR	TAH	No	No	I	NR	265	Alive	48	Pre	
	NR	TAH	No	No	I	NR	265	Alive	48	Pre	
	NR	ABD MYOM	Yes	No	I	NR	3	Dead	52	Post	
	NR	ABD MYOM	Yes	No	I	NR	4	Dead	52	Pre	
	NR	ABD MYOM	Yes	No	I	NR	7	Dead	52	Pre	
	NR	ABD MYOM	Yes	No	I	NR	7	Dead	52	Pre	
	NR	H'SCO PE MYO	Yes	No	I	NR	11	Dead	52	Post	
	NR	H'SCO PE MYO	Yes	No	I	NR	16	Dead	52	Pre	
	NR	H'SCO PE MYO	Yes	No	I	NR	16	Dead	52	Pre	
	NR	H'SCO PE MYO	Yes	No	I	NR	16	Dead	52	Pre	
	NR	LSC HYST	Yes	No	I	NR	23	Dead	52	Post	
	NR	LSC HYST	Yes	No	I	NR	24	Dead	52	Pre	
	NR	SCH	Yes	No	I	NR	24	Dead	52	Pre	
	NR	SCH	Yes	No	I	NR	35	Dead	52	Pre	
	NR	SCH	Yes	No	I	NR	18	Alive	52	Post	
	NR	SCH	Yes	No	I	NR	308	Alive	52	Post	
	NR	TAH UT INJ	Yes	No	I	NR	387	Alive	52	Post	
	NR	TAH UT INJ	Yes	No	I	NR	387	Alive	52	Pre	
Raine-Bennett T et al., 2016[240] (111)	Benign	varied	Yes	No	I	NR	6	Dead	NR	NR	
	Benign	varied	Yes	No	I	NR	6	Dead	NR	NR	
	Benign	varied	Yes	No	I	NR	12	Dead	NR	NR	
	Benign	varied	Yes	No	I	NR	12	Dead	NR	NR	
	Benign	varied	Yes	No	I	NR	18	Dead	NR	NR	
	Benign	varied	Yes	No	I	NR	18	Dead	NR	NR	
	Benign	varied	Yes	No	I	NR	24	Dead	NR	NR	
	Benign	varied	Yes	No	I	NR	30	Dead	NR	NR	
	Benign	varied	Yes	No	I	NR	6	Alive	NR	NR	
	Benign	varied	Yes	No	I	NR	12	Alive	NR	NR	
	Benign	varied	Yes	No	I	NR	30	Alive	NR	NR	
	Benign	varied	Yes	No	I	NR	36	Alive	NR	NR	
	Benign	varied	Yes	No	I	NR	36	Alive	NR	NR	
	Benign	varied	Yes	No	I	NR	36	Alive	NR	NR	
	Benign	varied	Yes	No	I	NR	36	Alive	NR	NR	
	Benign	varied	Yes	No	I	NR	36	Alive	NR	NR	
	Benign	varied	Yes	No	I	NR	36	Alive	NR	NR	
	Benign	varied	Yes	No	I	NR	36	Alive	NR	NR	

Author (LMS Total)	Preoperative	Initial Surgery	Morcellation	Power	Cancer Stage (First)	Upstaged	Months followup	Outcome	Age	Menopausal Status	Notes
	Benign	varied	Yes	No	I	NR	36	Alive	NR	NR	
	Benign	varied	Yes	No	I	NR	36	Alive	NR	NR	
	Benign	varied	Yes	No	I	NR	36	Alive	NR	NR	
	Benign	varied	Yes	No	I	NR	36	Alive	NR	NR	
	Benign	varied	Yes	No	I	NR	36	Alive	NR	NR	
	Benign	varied	Yes	No	I	NR	36	Alive	NR	NR	
	Benign	varied	Yes	No	I	NR	36	Alive	NR	NR	
	Benign	varied	Yes	No	I	NR	36	Alive	NR	NR	
	Benign	varied	Yes	No	I	NR	36	Alive	NR	NR	
	Benign	varied	Yes	Yes	I	NR	12	Dead	NR	NR	
	Benign	varied	Yes	Yes	I	NR	12	Dead	NR	NR	
	Benign	varied	Yes	Yes	I	NR	30	Alive	NR	NR	
	Benign	varied	Yes	Yes	I	NR	36	Alive	NR	NR	
	Benign	varied	Yes	Yes	I	NR	36	Alive	NR	NR	
	Benign	varied	Yes	Yes	I	NR	36	Alive	NR	NR	
	Benign	varied	Yes	Yes	I	NR	36	Alive	NR	NR	
	Benign	varied	Yes	Yes	I	NR	36	Alive	NR	NR	
	Benign	varied	No	No	I	NR	12	Dead	NR	NR	
	Benign	varied	No	No	I	NR	12	Dead	NR	NR	
	Benign	varied	No	No	I	NR	12	Dead	NR	NR	
	Benign	varied	No	No	I	NR	12	Dead	NR	NR	
	Benign	varied	No	No	I	NR	18	Dead	NR	NR	
	Benign	varied	No	No	I	NR	18	Dead	NR	NR	
	Benign	varied	No	No	I	NR	18	Dead	NR	NR	
	Benign	varied	No	No	I	NR	18	Dead	NR	NR	
	Benign	varied	No	No	I	NR	18	Dead	NR	NR	
	Benign	varied	No	No	I	NR	18	Dead	NR	NR	
	Benign	varied	No	No	I	NR	18	Dead	NR	NR	
	Benign	varied	No	No	I	NR	24	Dead	NR	NR	
	Benign	varied	No	No	I	NR	24	Dead	NR	NR	
	Benign	varied	No	No	I	NR	24	Dead	NR	NR	
	Benign	varied	No	No	I	NR	24	Dead	NR	NR	
	Benign	varied	No	No	I	NR	24	Dead	NR	NR	
	Benign	varied	No	No	I	NR	30	Dead	NR	NR	
	Benign	varied	No	No	I	NR	30	Dead	NR	NR	
	Benign	varied	No	No	I	NR	30	Dead	NR	NR	
	Benign	varied	No	No	I	NR	30	Dead	NR	NR	
	Benign	varied	No	No	I	NR	30	Dead	NR	NR	
	Benign	varied	No	No	I	NR	30	Dead	NR	NR	
	Benign	varied	No	No	I	NR	30	Dead	NR	NR	
	Benign	varied	No	No	I	NR	36	Dead	NR	NR	
	Benign	varied	No	No	I	NR	36	Dead	NR	NR	
	Benign	varied	No	No	I	NR	36	Dead	NR	NR	
	Benign	varied	No	No	I	NR	18	Alive	NR	NR	
	Benign	varied	No	No	I	NR	24	Alive	NR	NR	
	Benign	varied	No	No	I	NR	24	Alive	NR	NR	
	Benign	varied	No	No	I	NR	24	Alive	NR	NR	
	Benign	varied	No	No	I	NR	30	Alive	NR	NR	
	Benign	varied	No	No	I	NR	30	Alive	NR	NR	
	Benign	varied	No	No	I	NR	36	Alive	NR	NR	
	Benign	varied	No	No	I	NR	36	Alive	NR	NR	
	Benign	varied	No	No	I	NR	36	Alive	NR	NR	
	Benign	varied	No	No	I	NR	36	Alive	NR	NR	
	Benign	varied	No	No	I	NR	36	Alive	NR	NR	

Author (LMS Total)	Preoperative	Initial Surgery	Morcellation	Power	Cancer Stage (First)	Upstaged	Months followup	Outcome	Age	Menopausal Status	Notes
	Benign	varied	No	No	I	NR	36	Alive	NR	NR	
	Benign	varied	No	No	I	NR	36	Alive	NR	NR	
	Benign	varied	No	No	I	NR	36	Alive	NR	NR	
	Benign	varied	No	No	I	NR	36	Alive	NR	NR	
	Benign	varied	No	No	I	NR	36	Alive	NR	NR	
	Benign	varied	No	No	I	NR	36	Alive	NR	NR	
	Benign	varied	No	No	I	NR	36	Alive	NR	NR	
	Benign	varied	No	No	I	NR	36	Alive	NR	NR	
	Benign	varied	No	No	I	NR	36	Alive	NR	NR	
	Benign	varied	No	No	I	NR	36	Alive	NR	NR	
	Benign	varied	No	No	I	NR	36	Alive	NR	NR	
	Benign	varied	No	No	I	NR	36	Alive	NR	NR	
	Benign	varied	No	No	I	NR	36	Alive	NR	NR	
	Benign	varied	No	No	I	NR	36	Alive	NR	NR	
	Benign	varied	No	No	I	NR	36	Alive	NR	NR	
	Benign	varied	No	No	I	NR	36	Alive	NR	NR	
	Benign	varied	No	No	I	NR	36	Alive	NR	NR	
	Benign	varied	No	No	I	NR	36	Alive	NR	NR	
	Benign	varied	No	No	I	NR	36	Alive	NR	NR	
	Benign	varied	No	No	I	NR	36	Alive	NR	NR	
	Benign	varied	No	No	I	NR	36	Alive	NR	NR	
	Benign	varied	No	No	I	NR	36	Alive	NR	NR	
	Benign	varied	No	No	I	NR	36	Alive	NR	NR	
	Benign	varied	No	No	I	NR	36	Alive	NR	NR	
	Benign	varied	No	No	I	NR	36	Alive	NR	NR	
	Benign	varied	No	No	I	NR	36	Alive	NR	NR	
	Benign	varied	No	No	I	NR	36	Alive	NR	NR	
	Benign	varied	No	No	I	NR	36	Alive	NR	NR	
	Benign	varied	No	No	I	NR	36	Alive	NR	NR	
	Benign	varied	No	No	I	NR	36	Alive	NR	NR	
	Benign	varied	No	No	I	NR	36	Alive	NR	NR	
	Benign	varied	No	No	I	NR	36	Alive	NR	NR	
	Benign	varied	No	No	I	NR	36	Alive	NR	NR	
	Benign	varied	No	No	I	NR	36	Alive	NR	NR	
	Benign	varied	No	No	I	NR	36	Alive	NR	NR	
	Benign	varied	No	No	I	NR	36	Alive	NR	NR	
	Benign	varied	No	No	I	NR	36	Alive	NR	NR	

Notes: Unable to extract data from Morice P., et al. 2003[241] ; authors did not report patient level data; Abbreviations: ABD MYOM = abdominal myomectomy; AWD = alive with disease; BSO = bilateral salpingo-oophorectomy; H'SCOPE MYO = hysteroscopic myomectomy; LAVH = laparoscopic-assisted vaginal hysterectomy; LMYOM = laparoscopic myomectomy with morcellation; LMS = leiomyosarcoma; LSC ASST VH = laparoscopic assisted vaginal hysterectomy; LSC HYST = laparoscopic hysterectomy; LSC MYOM = laparoscopic myomectomy; LSC SCH = Laparoscopic supracervical hysterectomy; malign = malignant; MIS HYST = minimally invasive hysterectomy; MRI = magnetic resonance imaging; NA = not applicable; NED = no evidence of disease; ND = no data; NR = not reported; Onc = oncology; Post = postmenopausal; Poss Malig = possibly malignant; Pre = premenopausal; SAH = supracervical abdominal hysterectomy; SCH = supracervical hysterectomy; TAH = total abdominal hysterectomy; TAH BSO= total abdominal hysterectomy with bilateral salpingo-oophorectomy; TAH UT INJ = total abdominal hysterectomy uterus injured; TLH = total laparoscopic hysterectomy; TVH = total vaginal hysterectomy; VAG HYST = vaginal hysterectomy

References

1. Macnaught G, Ananthakrishnan G, Hinksman L, et al. Can (1)H MR Spectroscopy be Used to Assess the Success of Uterine Artery Embolisation? Cardiovasc Intervent Radiol. 2016 Mar;39(3):376-84. doi: 10.1007/s00270-015-1179-z. PMID: 26183465.

2. Wang X, Zhang Z, Pan J, et al. Effects of embolic agents with different particle sizes on interventional treatment of uterine fibroids. Pak J Med Sci. 2015 Nov-Dec;31(6):1490-5. doi: 10.12669/pjms.316.7955. PMID: 26870122.

3. Shlansky-Goldberg RD, Rosen MA, Mondschein JI, et al. Comparison of polyvinyl alcohol microspheres and tris-acryl gelatin microspheres for uterine fibroid embolization: results of a single-center randomized study. J Vasc Interv Radiol. 2014 Jun;25(6):823-32. doi: 10.1016/j.jvir.2014.03.009. PMID: 24788209.

4. Song YG, Jang H, Park KD, et al. Non spherical polyvinyl alcohol versus gelatin sponge particles for uterine artery embolization for symptomatic fibroids. Minim Invasive Ther Allied Technol. 2013 Dec;22(6):364-71. doi: 10.3109/13645706.2013.826674. PMID: 23992381.

5. Yu SC, Lok I, Ho SS, et al. Comparison of clinical outcomes of tris-acryl microspheres versus polyvinyl alcohol microspheres for uterine artery embolization for leiomyomas: results of a randomized trial. J Vasc Interv Radiol. 2011 Sep;22(9):1229-35. doi: 10.1016/j.jvir.2011.05.011. PMID: 21802314.

6. Worthington-Kirsch RL, Siskin GP, Hegener P, et al. Comparison of the efficacy of the embolic agents acrylamido polyvinyl alcohol microspheres and tris-acryl gelatin microspheres for uterine artery embolization for leiomyomas: a prospective randomized controlled trial. Cardiovasc Intervent Radiol. 2011 Jun;34(3):493-501. doi: 10.1007/s00270-010-0049-y. PMID: 21127866.

7. Bilhim T, Pisco JM, Duarte M, et al. Polyvinyl alcohol particle size for uterine artery embolization: a prospective randomized study of initial use of 350-500 mum particles versus initial use of 500-700 mum particles. J Vasc Interv Radiol. 2011 Jan;22(1):21-7. doi: 10.1016/j.jvir.2010.09.018. PMID: 21106390.

8. Siskin GP, Beck A, Schuster M, et al. Leiomyoma infarction after uterine artery embolization: a prospective randomized study comparing tris-acryl gelatin microspheres versus polyvinyl alcohol microspheres. J Vasc Interv Radiol. 2008 Jan;19(1):58-65. doi: 10.1016/j.jvir.2007.08.034. PMID: 18192468.

9. Vilos GA, Vilos AG, Abu-Rafea B, et al. Administration of goserelin acetate after uterine artery embolization does not change the reduction rate and volume of uterine myomas. Fertil Steril. 2006 May;85(5):1478-83. doi: 10.1016/j.fertnstert.2005.10.039. PMID: 16579996.

10. Spies JB, Allison S, Flick P, et al. Spherical polyvinyl alcohol versus tris-acryl gelatin microspheres for uterine artery embolization for leiomyomas: results of a limited randomized comparative study. J Vasc Interv Radiol. 2005 Nov;16(11):1431-7. doi: 10.1097/01.rvi.0000179793.69590.1a. PMID: 16319148.

11. Spies JB, Allison S, Flick P, et al. Polyvinyl alcohol particles and tris-acryl gelatin microspheres for uterine artery embolization for leiomyomas: results of a randomized comparative study. J Vasc Interv Radiol. 2004 Aug;15(8):793-800. doi: 10.1097/01.rvi.0000136982.42548.5d. PMID: 15297582.

12. Pinto I, Chimeno P, Romo A, et al. Uterine fibroids: uterine artery embolization versus abdominal hysterectomy for treatment--a prospective, randomized, and controlled clinical trial. Radiology. 2003 Feb;226(2):425-31. doi: 10.1148/radiol.2262011716. PMID: 12563136.

13. Volkers NA, Hehenkamp WJ, Birnie E, et al. Uterine artery embolization versus hysterectomy in the treatment of symptomatic uterine fibroids: 2 years' outcome from the randomized EMMY trial. Am J Obstet Gynecol. 2007 Jun;196(6):519.e1-11. doi: 10.1016/j.ajog.2007.02.029. PMID: 17547877.

14. Ananthakrishnan G, Murray L, Ritchie M, et al. Randomized comparison of uterine artery embolization (UAE) with surgical treatment in patients with symptomatic uterine fibroids (REST trial): subanalysis of 5-year MRI findings. Cardiovasc Intervent Radiol. 2013 Jun;36(3):676-81. doi: 10.1007/s00270-012-0485-y. PMID: 23070101.

15. Mara M, Maskova J, Fucikova Z, et al. Midterm clinical and first reproductive results of a randomized controlled trial comparing uterine fibroid embolization and myomectomy. Cardiovasc Intervent Radiol. 2008 Jan-Feb;31(1):73-85. doi: 10.1007/s00270-007-9195-2. PMID: 17943348.

16. Donnez J, Hudecek R, Donnez O, et al. Efficacy and safety of repeated use of ulipristal acetate in uterine fibroids. Fertil Steril. 2015 Feb;103(2):519-27.e3. doi: 10.1016/j.fertnstert.2014.10.038. PMID: 25542821.

17. Donnez J, Donnez O, Matule D, et al. Long-term medical management of uterine fibroids with ulipristal acetate. Fertil Steril. 2016 Jan;105(1):165-73.e4. doi: 10.1016/j.fertnstert.2015.09.032. PMID: 26477496.

18. Donnez J, Vazquez F, Tomaszewski J, et al. Long-term treatment of uterine fibroids with ulipristal acetate. Fertil Steril. 2014 Jun;101(6):1565-73.e1-18. doi: 10.1016/j.fertnstert.2014.02.008. PMID: 24630081.

19. Donnez J, Tatarchuk TF, Bouchard P, et al. Ulipristal acetate versus placebo for fibroid treatment before surgery. N Engl J Med. 2012 Feb 2;366(5):409-20. doi: 10.1056/NEJMoa1103182. PMID: 22296075.

20. Donnez J, Tomaszewski J, Vazquez F, et al. Ulipristal acetate versus leuprolide acetate for uterine fibroids. N Engl J Med. 2012 Feb 2;366(5):421-32. doi: 10.1056/NEJMoa1103180. PMID: 22296076.

21. Levens ED, Potlog-Nahari C, Armstrong AY, et al. CDB-2914 for uterine leiomyomata treatment: a randomized controlled trial. Obstet Gynecol. 2008 May;111(5):1129-36. doi: 10.1097/AOG.0b013e3181705d0e. PMID: 18448745.

22. Palomba S, Russo T, Orio F, Jr., et al. Effectiveness of combined GnRH analogue plus raloxifene administration in the treatment of uterine leiomyomas: a prospective, randomized, single-blind, placebo-controlled clinical trial. Hum Reprod. 2002 Dec;17(12):3213-9. PMID: 12456626.

23. Eder S, Baker J, Gersten J, et al. Efficacy and safety of oral tranexamic acid in women with heavy menstrual bleeding and fibroids. Womens Health (Lond Engl). 2013 Jul;9(4):397-403. doi: 10.2217/whe.13.28. PMID: 23656203.

24. Fedele L, Bianchi S, Baglioni A, et al. Intranasal buserelin versus surgery in the treatment of uterine leiomyomata: long-term follow-up. Eur J Obstet Gynecol Reprod Biol. 1991 Jan 4;38(1):53-7. PMID: 1899079.

25. Jirecek S, Lee A, Pavo I, et al. Raloxifene prevents the growth of uterine leiomyomas in premenopausal women. Fertil Steril. 2004 Jan;81(1):132-6. PMID: 14711556.

26. Hehenkamp WJ, Volkers NA, Donderwinkel PF, et al. Uterine artery embolization versus hysterectomy in the treatment of symptomatic uterine fibroids (EMMY trial): peri- and postprocedural results from a randomized controlled trial. Am J Obstet Gynecol. 2005 Nov;193(5):1618-29. doi: 10.1016/j.ajog.2005.05.017. PMID: 16260201.

27. Jiang N, Xie B, Zhang X, et al. Enhancing ablation effects of a microbubble-enhancing contrast agent ("SonoVue") in the treatment of uterine fibroids with high-intensity focused ultrasound: a randomized controlled trial. Cardiovasc Intervent Radiol. 2014 Oct;37(5):1321-8. doi: 10.1007/s00270-013-0803-z. PMID: 24549267.

28. Jun F, Yamin L, Xinli X, et al. Uterine artery embolization versus surgery for symptomatic uterine fibroids: a randomized controlled trial and a meta-analysis of the literature. Arch Gynecol Obstet. 2012 May;285(5):1407-13. doi: 10.1007/s00404-011-2065-9. PMID: 22048783.

29. Manyonda IT, Bratby M, Horst JS, et al. Uterine artery embolization versus myomectomy: impact on quality of life--results of the FUME (Fibroids of the Uterus: Myomectomy versus Embolization) Trial. Cardiovasc Intervent Radiol. 2012 Jun;35(3):530-6. doi: 10.1007/s00270-011-0228-5. PMID: 21773858.

30. Mara M, Fucikova Z, Maskova J, et al. Uterine fibroid embolization versus myomectomy in women wishing to preserve fertility: preliminary results of a randomized controlled trial. Eur J Obstet Gynecol Reprod Biol. 2006 Jun 1;126(2):226-33. doi: 10.1016/j.ejogrb.2005.10.008. PMID: 16293363.

31. Meng X, He G, Zhang J, et al. A comparative study of fibroid ablation rates using radio frequency or high-intensity focused ultrasound. Cardiovasc Intervent Radiol. 2010 Aug;33(4):794-9. doi: 10.1007/s00270-010-9909-8. PMID: 20544227.

32. Orsi F, Monfardini L, Bonomo G, et al. Ultrasound guided high intensity focused ultrasound (USgHIFU) ablation for uterine fibroids: Do we need the microbubbles? Int J Hyperthermia. 2015 Mar 11:1-7. doi: 10.3109/02656736.2015.1004134. PMID: 25758436.

33. Wang X, Qin J, Wang L, et al. Effect of high-intensity focused ultrasound on sexual function in the treatment of uterine fibroids: comparison to conventional myomectomy. Arch Gynecol Obstet. 2013 Oct;288(4):851-8. doi: 10.1007/s00404-013-2775-2. PMID: 23564052.

34. Yang Z, Zhang Y, Zhang R, et al. A case-control study of high-intensity focused ultrasound combined with sonographically guided intratumoral ethanol injection in the treatment of uterine fibroids. J Ultrasound Med. 2014 Apr;33(4):657-65. doi: 10.7863/ultra.33.4.657. PMID: 24658945.

35. Brucker SY, Hahn M, Kraemer D, et al. Laparoscopic radiofrequency volumetric thermal ablation of fibroids versus laparoscopic myomectomy. Int J Gynaecol Obstet. 2014 Jun;125(3):261-5. doi: 10.1016/j.ijgo.2013.11.012. PMID: 24698202.

36. Hwang JL, Seow KM, Tsai YL, et al. Comparative study of vaginal, laparoscopically assisted vaginal and abdominal hysterectomies for uterine myoma larger than 6 cm in diameter or uterus weighing at least 450 g: a prospective randomized study. Acta Obstet Gynecol Scand. 2002 Dec;81(12):1132-8. PMID: 12519109.

37. Seracchioli R, Venturoli S, Vianello F, et al. Total laparoscopic hysterectomy compared with abdominal hysterectomy in the presence of a large uterus. J Am Assoc Gynecol Laparosc. 2002 Aug;9(3):333-8. PMID: 12101331.

38. Silva-Filho AL, Werneck RA, de Magalhaes RS, et al. Abdominal vs vaginal hysterectomy: a comparative study of the postoperative quality of life and satisfaction. Arch Gynecol Obstet. 2006 Apr;274(1):21-4. doi: 10.1007/s00404-005-0118-7. PMID: 16408185.

39. Soysal ME, Soysal SK, Vicdan K. Thermal balloon ablation in myoma-induced menorrhagia under local anesthesia. Gynecol Obstet Invest. 2001;51(2):128-33. doi: 52908. PMID: 11223708.

40. Yen YK, Liu WM, Yuan CC, et al. Comparison of two procedures for laparoscopic-assisted vaginal hysterectomy of large myomatous uteri. J Am Assoc Gynecol Laparosc. 2002 Feb;9(1):63-9. PMID: 11821608.

41. Alessandri F, Lijoi D, Mistrangelo E, et al. Randomized study of laparoscopic versus minilaparotomic myomectomy for uterine myomas. J Minim Invasive Gynecol. 2006 Mar-Apr;13(2):92-7. doi: 10.1016/j.jmig.2005.11.008. PMID: 16527709.

42. Benassi L, Rossi T, Kaihura CT, et al. Abdominal or vaginal hysterectomy for enlarged uteri: a randomized clinical trial. Am J Obstet Gynecol. 2002 Dec;187(6):1561-5. PMID: 12501064.

43. Ferrari MM, Berlanda N, Mezzopane R, et al. Identifying the indications for laparoscopically assisted vaginal hysterectomy: a prospective, randomised comparison with abdominal hysterectomy in patients with symptomatic uterine fibroids. Bjog. 2000 May;107(5):620-5. PMID: 10826576.

44. Rossetti A, Sizzi O, Soranna L, et al. Long-term results of laparoscopic myomectomy: recurrence rate in comparison with abdominal myomectomy. Hum Reprod. 2001 Apr;16(4):770-4. PMID: 11278231.

45. Sesti F, Capobianco F, Capozzolo T, et al. Isobaric gasless laparoscopy versus minilaparotomy in uterine myomectomy: a randomized trial. Surg Endosc. 2008 Apr;22(4):917-23. doi: 10.1007/s00464-007-9516-1. PMID: 17705083.

46. Tan J, Sun Y, Dai H, et al. A randomized trial of laparoscopic versus laparoscopic-assisted minilaparotomy myomectomy for removal of large uterine myoma: short-term outcomes. J Minim Invasive Gynecol. 2008 Jul-Aug;15(4):402-9. doi: 10.1016/j.jmig.2008.03.010. PMID: 18602045.

47. Tan J, Sun Y, Zhong B, et al. A randomized, controlled study comparing minilaparotomy versus isobaric gasless laparoscopic assisted minilaparotomy myomectomy for removal of large uterine myomas: short-term outcomes. Eur J Obstet Gynecol Reprod Biol. 2009 Jul;145(1):104-8. doi: 10.1016/j.ejogrb.2009.04.015. PMID: 19427094.

48. Vercellino G, Erdemoglu E, Joe A, et al. Laparoscopic temporary clipping of uterine artery during laparoscopic myomectomy. Arch Gynecol Obstet. 2012 Nov;286(5):1181-6. doi: 10.1007/s00404-012-2419-y. PMID: 22714065.

49. Ardovino M, Ardovino I, Castaldi MA, et al. Minilaparoscopic myomectomy: a mini-invasive technical variant. J Laparoendosc Adv Surg Tech A. 2013 Oct;23(10):871-5. doi: 10.1089/lap.2013.0037. PMID: 23992206.

50. Cicinelli E, Tinelli R, Colafiglio G, et al. Laparoscopy vs minilaparotomy in women with symptomatic uterine myomas: a prospective randomized study. J Minim Invasive Gynecol. 2009 Jul-Aug;16(4):422-6. doi: 10.1016/j.jmig.2009.03.011. PMID: 19573818.

51. Seracchioli R, Rossi S, Govoni F, et al. Fertility and obstetric outcome after laparoscopic myomectomy of large myomata: a randomized comparison with abdominal myomectomy. Hum Reprod. 2000 Dec;15(12):2663-8. PMID: 11098042.

52. Wang JJ, Yang F, Gao T, et al. Gasless laparoscopy versus conventional laparoscopy in uterine myomectomy: a single-centre randomized trial. J Int Med Res. 2011;39(1):172-8. PMID: 21672319.

53. Zhao F, Jiao Y, Guo Z, et al. Evaluation of loop ligation of larger myoma pseudocapsule combined with vasopressin on laparoscopic myomectomy. Fertil Steril. 2011 Feb;95(2):762-6. doi: 10.1016/j.fertnstert.2010.08.059. PMID: 20883988.

54. Edwards RD, Moss JG, Lumsden MA, et al. Uterine-artery embolization versus surgery for symptomatic uterine fibroids. N Engl J Med. 2007 Jan 25;356(4):360-70. doi: 10.1056/NEJMoa062003. PMID: 17251532.

55. Liu M, Cheng Z, Zhu Y, et al. Prospective comparison of laparoscopic uterine artery occlusion plus myomectomy with classic intrafascial supracervical hysterectomy for symptomatic fibroid treatment: differences in post-operative quality-of-life measures. Eur J Obstet Gynecol Reprod Biol. 2011 Mar;155(1):79-84. doi: 10.1016/j.ejogrb.2010.10.022. PMID: 21216518.

56. Mais V, Ajossa S, Guerriero S, et al. Laparoscopic versus abdominal myomectomy: a prospective, randomized trial to evaluate benefits in early outcome. Am J Obstet Gynecol. 1996 Feb;174(2):654-8. PMID: 8623802.

57. Palomba S, Zupi E, Falbo A, et al. A multicenter randomized, controlled study comparing laparoscopic versus minilaparotomic myomectomy: reproductive outcomes. Fertil Steril. 2007 Oct;88(4):933-41. doi: 10.1016/j.fertnstert.2006.12.047. PMID: 17434505.

58. Sesti F, Ruggeri V, Pietropolli A, et al. Laparoscopically assisted vaginal hysterectomy versus vaginal hysterectomy for enlarged uterus. Jsls. 2008 Jul-Sep;12(3):246-51. PMID: 18765046.

59. Sesti F, Cosi V, Calonzi F, et al. Randomized comparison of total laparoscopic, laparoscopically assisted vaginal and vaginal hysterectomies for myomatous uteri. Arch Gynecol Obstet. 2014 Sep;290(3):485-91. doi: 10.1007/s00404-014-3228-2. PMID: 24710800.

60. Soriano D, Goldstein A, Lecuru F, et al. Recovery from vaginal hysterectomy compared with laparoscopy-assisted vaginal hysterectomy: a prospective, randomized, multicenter study. Acta Obstet Gynecol Scand. 2001 Apr;80(4):337-41. PMID: 11264609.

61. Parazzini F, Bortolotti A, Chiantera V, et al. Goserelin acetate to avoid hysterectomy in pre-menopausal women with fibroids requiring surgery. Eur J Obstet Gynecol Reprod Biol. 1999 Nov;87(1):31-3. PMID: 10579613.

62. Ruuskanen A, Hippelainen M, Sipola P, et al. Uterine artery embolisation versus hysterectomy for leiomyomas: primary and 2-year follow-up results of a randomised prospective clinical trial. Eur Radiol. 2010 Oct;20(10):2524-32. doi: 10.1007/s00330-010-1829-0. PMID: 20526776.

63. Abdullah B, Subramaniam R, Omar S, et al. Magnetic resonance-guided focused ultrasound surgery (MRgFUS) treatment for uterine fibroids. Biomed Imaging Interv J. 2010 Apr-Jun;6(2):e15. doi: 10.2349/biij.6.2.e15. PMID: 21611036.

64. Kido A, Ascher SM, Kishimoto K, et al. Comparison of uterine peristalsis before and after uterine artery embolization at 3-T MRI. AJR Am J Roentgenol. 2011 Jun;196(6):1431-5. doi: 10.2214/ajr.10.5349. PMID: 21606309.

65. Demir RH, Marchand GJ. Safe laparoscopic removal of a 3200 gram fibroid uterus. Jsls. 2010 Oct-Dec;14(4):600-2. doi: 10.4293/108680810x12924466008169. PMID: 21605532.

66. Ippolito E, Buora A, Belcaro G, et al. Deep vein thrombosis and pulmonary embolism in a patient affected by uterine fibroids: clinical case. Panminerva Med. 2012 Dec;54(1 Suppl 4):97-9. PMID: 23241942.

67. Mizuno M, Nawa A, Nakanishi T, et al. Clinical benefit of endocrine therapy for benign metastasizing leiomyoma. Int J Clin Oncol. 2011 Oct;16(5):587-91. doi: 10.1007/s10147-010-0156-4. PMID: 21161313.

68. Zhou YF. High intensity focused ultrasound in clinical tumor ablation. World J Clin Oncol. 2011 Jan 10;2(1):8-27. doi: 10.5306/wjco.v2.i1.8. PMID: 21603311.

69. Wong WS, Lee TC, Lim CE. A retrospective study of laparoscopic-assisted vaginal hysterectomy (LAVH) in virgins and nulliparae. Eur J Obstet Gynecol Reprod Biol. 2011 Aug;157(2):217-21. doi: 10.1016/j.ejogrb.2011.03.018. PMID: 21507553.

70. DeLonzor R, Spero RK, Williams JJ. The electrical conductivity of in vivo human uterine fibroids. Int J Hyperthermia. 2011;27(3):255-65. doi: 10.3109/02656736.2011.555875. PMID: 21501027.

71. Markowski DN, Helmke BM, Belge G, et al. HMGA2 and p14Arf: major roles in cellular senescence of fibroids and therapeutic implications. Anticancer Res. 2011 Mar;31(3):753-61. PMID: 21498692.

72. De Riu G, Meloni SM, Massarelli O, et al. Management of midcheek masses and tumors of the accessory parotid gland. Oral Surg Oral Med Oral Pathol Oral Radiol Endod. 2011 May;111(5):e5-11. doi: 10.1016/j.tripleo.2011.01.005. PMID: 21497733.

73. Plusquin C, Vandromme J, Fastrez M, et al. Assessing ovarian cancer risk when considering elective oophorectomy at the time of hysterectomy. Obstet Gynecol. 2011 Aug;118(2 Pt 1):359; author reply -60. doi: 10.1097/AOG.0b013e3182263337. PMID: 21775859.

74. Gilden M, Malik M, Britten J, et al. Leiomyoma fibrosis inhibited by liarozole, a retinoic acid metabolic blocking agent. Fertil Steril. 2012 Dec;98(6):1557-62. doi: 10.1016/j.fertnstert.2012.07.1132. PMID: 22925684.

75. Yoshiki N, Okawa T, Kubota T. Single-incision laparoscopic myomectomy with intracorporeal suturing. Fertil Steril. 2011 Jun;95(7):2426-8. doi: 10.1016/j.fertnstert.2011.03.065. PMID: 21497336.

76. Aneiros-Fernandez J, Arias-Santiago S, Espineira-Carmona MJ, et al. Hemangiopericytoma-like dermatofibroma with mast cells. Am J Dermatopathol. 2011 Aug;33(6):e74-6. doi: 10.1097/DAD.0b013e31821e1a47. PMID: 21712684.

77. Rosica G, Santilli G, Bucari D, et al. A case of disseminated peritoneal leiomyomatosis and diffuse uterine leiomyomatosis. Clin Exp Obstet Gynecol. 2011;38(1):84-7. PMID: 21485735.

78. Kalogiannidis I, Xiromeritis P, Prapas N, et al. Intravaginal misoprostol reduces intraoperative blood loss in minimally invasive myomectomy: a randomized clinical trial. Clin Exp Obstet Gynecol. 2011;38(1):46-9. PMID: 21485725.

79. Grigoriadis C, Androutsopoulos G, Zygouris D, et al. Uterine angioleiomyoma causing severe abnormal uterine bleeding. Clin Exp Obstet Gynecol. 2014;41(1):102-4. PMID: 24707699.

80. Zhou XX, Ji F, Xu L, et al. EUS for choosing best endoscopic treatment of mesenchymal tumors of upper gastrointestinal tract. World J Gastroenterol. 2011 Apr 7;17(13):1766-71. doi: 10.3748/wjg.v17.i13.1766. PMID: 21483639.

81. Wang ZB. [To develop technique of ultrasound ablation, to promote minimal invasive surgery]. Zhonghua Fu Chan Ke Za Zhi. 2011 Jun;46(6):401-2. PMID: 21781576.

82. Ou YC, Huang KH, Lin H, et al. Sepsis secondary to cesarean scar diverticulum resembling an infected leiomyoma. Taiwan J Obstet Gynecol. 2011 Mar;50(1):100-2. doi: 10.1016/j.tjog.2011.01.004. PMID: 21482384.

83. Moini A, Kiani K, Ghaffari F, et al. Hysteroscopic findings in patients with a history of two implantation failures following in vitro fertilization. Int J Fertil Steril. 2012 Apr;6(1):27-30. PMID: 25505508.

84. Su H, Han CM, Wang CJ, et al. Comparison of the efficacy of the pulsed bipolar system and conventional electrosurgery in laparoscopic myomectomy - a retrospective matched control study. Taiwan J Obstet Gynecol. 2011 Mar;50(1):25-8. doi: 10.1016/j.tjog.2009.05.002. PMID: 21482370.

85. Liu L, Li Y, Xu H, et al. Laparoscopic transient uterine artery occlusion and myomectomy for symptomatic uterine myoma. Fertil Steril. 2011 Jan;95(1):254-8. doi: 10.1016/j.fertnstert.2010.05.006. PMID: 21168582.

86. Cusido M, Fargas F, Baulies S, et al. Impact of Surgery on the Evolution of Uterine Sarcomas. J Minim Invasive Gynecol. 2015 Sep-Oct;22(6):1068-74. doi: 10.1016/j.jmig.2015.05.024. PMID: 26070730.

87. Dadhwal V, Gupta B, Dasgupta C, et al. Primary umbilical endometriosis: a rare entity. Arch Gynecol Obstet. 2011 Mar;283 Suppl 1:119-20. doi: 10.1007/s00404-010-1809-2. PMID: 21170542.

88. Sieron D, Wiggermann P, Skupinski J, et al. Uterine artery embolisation and magnetic resonance-guided focused ultrasound treatment of uterine fibroids. Pol J Radiol. 2011 Apr;76(2):37-9. PMID: 22802829.

89. Pourmatroud E, Hormozi L, Hemadi M, et al. Intravenous ascorbic acid (vitamin C) administration in myomectomy: a prospective, randomized, clinical trial. Arch Gynecol Obstet. 2012 Jan;285(1):111-5. doi: 10.1007/s00404-011-1897-7. PMID: 21448709.

90. Videan EN, Satterfield WC, Buchl S, et al. Diagnosis and prevalence of uterine leiomyomata in female chimpanzees (Pan troglodytes). Am J Primatol. 2011 Jul;73(7):665-70. doi: 10.1002/ajp.20947. PMID: 21442632.

91. Lipszyc M, Winters E, Engelman E, et al. Remifentanil patient-controlled analgesia effect-site target-controlled infusion compared with morphine patient-controlled analgesia for treatment of acute pain after uterine artery embolization. Br J Anaesth. 2011 May;106(5):724-31. doi: 10.1093/bja/aer041. PMID: 21441549.

92. Liaw JV, Yun CH, Walker TG, et al. Comparison of clinical and MR imaging outcomes after uterine fibroid embolization with Bead Block and Embosphere. Eur J Radiol. 2012 Jun;81(6):1371-5. doi: 10.1016/j.ejrad.2011.03.017. PMID: 21439744.

93. Gargiulo AR, Nezhat C. Robot-assisted laparoscopy, natural orifice transluminal endoscopy, and single-site laparoscopy in reproductive surgery. Semin Reprod Med. 2011 Mar;29(2):155-68. doi: 10.1055/s-0031-1272478. PMID: 21437830.

94. Wu Q, Liu C, Luo X, et al. Primary leiomyoma of the parietal bone. Neurol India. 2013 Nov-Dec;61(6):686-7. doi: 10.4103/0028-3886.125384. PMID: 24441355.

95. Olive DL. The surgical treatment of fibroids for infertility. Semin Reprod Med. 2011 Mar;29(2):113-23. doi: 10.1055/s-0031-1272473. PMID: 21437825.

96. Kuroda K, Kitade M, Kikuchi I, et al. Alterations in endometrial vascular density via hysteroscopy evaluated by vascular analysis software during laparoscopic myomectomy on an infertile woman with submucous myoma. Minim Invasive Ther Allied Technol. 2011 Jan;20(1):58-61. doi: 10.3109/13645706.2010.518678. PMID: 21155634.

97. Bettocchi S, Achilarre MT, Ceci O, et al. Fertility-enhancing hysteroscopic surgery. Semin Reprod Med. 2011 Mar;29(2):75-82. doi: 10.1055/s-0031-1272469. PMID: 21437821.

98. Behnes CL, Schlegel C, Shoukier M, et al. Hereditary papillary renal cell carcinoma primarily diagnosed in a cervical lymph node: a case report of a 30-year-old woman with multiple metastases. BMC Urol. 2013;13:3. doi: 10.1186/1471-2490-13-3. PMID: 23320739.

99. Koo YJ, Song HS, Im KS, et al. Multimedia article. Highly effective method for myoma excision and suturing in laparoscopic myomectomy. Surg Endosc. 2011 Jul;25(7):2362. doi: 10.1007/s00464-010-1519-7. PMID: 21432007.

100. Gao Z, Li L, Meng Y. A Retrospective Analysis of the Impact of Myomectomy on Survival in Uterine Sarcoma. PLoS One. 2016;11(2):e0148050. doi: 10.1371/journal.pone.0148050. PMID: 26828206.

101. Okugawa Y, Mohri Y, Toiyama Y, et al. Multiple solitary leiomyomas in the esophagus: report of a case. Surg Today. 2011 Apr;41(4):563-7. doi: 10.1007/s00595-010-4286-0. PMID: 21431495.

102. Quinlan D, Quinlan DK. Vaginal hysterectomy for the enlarged fibroid uterus: a report of 85 cases. J Obstet Gynaecol Can. 2010 Oct;32(10):980-3. PMID: 21176308.

103. Lehtonen HJ. Hereditary leiomyomatosis and renal cell cancer: update on clinical and molecular characteristics. Fam Cancer. 2011 Jun;10(2):397-411. doi: 10.1007/s10689-011-9428-z. PMID: 21404119.

104. Geethamala K, Murthy VS, Vani BR, et al. Uterine Leiomyomas: An ENIGMA. J Midlife Health. 2016 Jan-Mar;7(1):22-7. doi: 10.4103/0976-7800.179170. PMID: 27134477.

105. Boyd C, McCluggage WG. Unusual morphological features of uterine leiomyomas treated with progestogens. J Clin Pathol. 2011 Jun;64(6):485-9. doi: 10.1136/jcp.2011.089664. PMID: 21398323.

106. Ozdil B, Akkiz H, Kece C, et al. Endoscopic alcohol injection therapy of giant gastric leiomyomas: an alternative method to surgery. Can J Gastroenterol. 2010 Sep;24(9):533-5. PMID: 21152456.

107. Auber M, Darwish B, Lefebure A, et al. Management of nonpuerperal uterine inversion using a combined laparoscopic and vaginal approach. Am J Obstet Gynecol. 2011 Jun;204(6):e7-9. doi: 10.1016/j.ajog.2011.01.024. PMID: 21397207.

108. Torok P, Major T. [Office hysteroscopy: a new examination method in gynecological practice]. Orv Hetil. 2011 Jan 9;152(2):51-4. doi: 10.1556/oh.2011.28997. PMID: 21177231.

109. Wright KN, Laufer MR. Leiomyomas in adolescents. Fertil Steril. 2011 Jun;95(7):2434.e15-7. doi: 10.1016/j.fertnstert.2011.02.025. PMID: 21392748.

110. Kang HS, Jeong D, Kim DI, et al. The use of acupuncture for managing gynaecologic conditions: An overview of systematic reviews. Maturitas. 2011 Apr;68(4):346-54. doi: 10.1016/j.maturitas.2011.02.001. PMID: 21376483.

111. Zaher S, Lyons D, Regan L. Successful in vitro fertilization pregnancy following magnetic resonance-guided focused ultrasound surgery for uterine fibroids. J Obstet Gynaecol Res. 2011 Apr;37(4):370-3. doi: 10.1111/j.1447-0756.2010.01344.x. PMID: 21392163.

112. Learman LA, Nakagawa S, Gregorich SE, et al. Success of uterus-preserving treatments for abnormal uterine bleeding, chronic pelvic pain, and symptomatic fibroids: age and bridges to menopause. Am J Obstet Gynecol. 2011 Mar;204(3):272.e1-7. doi: 10.1016/j.ajog.2010.12.052. PMID: 21376169.

113. Barri-Soldevila PN, Vazquez A. [Current role of conservative surgery]. Med Clin (Barc). 2013 Jul;141 Suppl 1:7-12. doi: 10.1016/s0025-7753(13)70046-0. PMID: 24314561.

114. Carlson RM, Leslie DB. Synchronous esophageal and jejunal leiomyoma presenting as strangulation obstruction. Am Surg. 2010 Nov;76(11):E216-7. PMID: 21375822.

115. Kulshrestha V, Kriplani A, Agarwal N, et al. Low dose mifepristone in medical management of uterine leiomyoma - an experience from a tertiary care hospital from north India. Indian J Med Res. 2013 Jun;137(6):1154-62. PMID: 23852296.

116. van Ooijen P, ter Haar JF, Pijnenborg JM. Extensive cellulitis as the first symptom of ureter lesion after laparoscopic hysterectomy. J Laparoendosc Adv Surg Tech A. 2011 Apr;21(3):249-50. doi: 10.1089/lap.2010.0460. PMID: 21375415.

117. Huang PS, Sheu BC, Huang SC, et al. Intraligamental Myomectomy Strategy Using Laparoscopy. J Minim Invasive Gynecol. 2016 Sep-Oct;23(6):954-61. doi: 10.1016/j.jmig.2016.06.007. PMID: 27327965.

118. Cogendez E, Dolgun ZN, Sanverdi I, et al. Post-abortion hysteroscopy: a method for early diagnosis of congenital and acquired intrauterine causes of abortions. Eur J Obstet Gynecol Reprod Biol. 2011 May;156(1):101-4. doi: 10.1016/j.ejogrb.2010.12.025. PMID: 21371805.

119. Casadio P, Youssef AM, Spagnolo E, et al. Should the myometrial free margin still be considered a limiting factor for hysteroscopic resection of submucous fibroids? A possible answer to an old question. Fertil Steril. 2011 Apr;95(5):1764-8.e1. doi: 10.1016/j.fertnstert.2011.01.033. PMID: 21315334.

120. Yoshino O, Hori M, Osuga Y, et al. Myomectomy reduces endometrial T2 relaxation times. Fertil Steril. 2011 Jun 30;95(8):2781-3. doi: 10.1016/j.fertnstert.2011.01.032. PMID: 21315332.

121. Koplin G, Swierzy M, Menenakos C, et al. Thoracoscopic resection of a combined esophageal leiomyoma and diverticulum: a case report. Surg Laparosc Endosc Percutan Tech. 2011 Feb;21(1):e16-8. doi: 10.1097/SLE.0b013e318200e2b2. PMID: 21304365.

122. Oehler MK, Scopacasa L, Brown M, et al. Intravenous uterine leiomyomatosis extending into the right heart. Aust N Z J Obstet Gynaecol. 2011 Feb;51(1):92-4. doi: 10.1111/j.1479-828X.2010.01249.x. PMID: 21299517.

123. Kamikabeya TS, Etchebehere RM, Nomelini RS, et al. Gynecological malignant neoplasias diagnosed after hysterectomy performed for leiomyoma in a university hospital. Eur J Gynaecol Oncol. 2010;31(6):651-3. PMID: 21319509.

124. Kathiresan AS, Brookfield KF, Gonzalez-Quintero VH, et al. Vasopressin versus a combination of vasopressin and tourniquets: a comparison of blood loss in patients undergoing abdominal myomectomies. Aust N Z J Obstet Gynaecol. 2011 Feb;51(1):79-83. doi: 10.1111/j.1479-828X.2010.01253.x. PMID: 21299514.

125. Kinay T, Basarir ZO, Tuncer SF, et al. Is a history of cesarean section a risk factor for abnormal uterine bleeding in patients with uterine leiomyoma? Saudi Med J. 2016 Aug;37(8):871-6. doi: 10.15537/smj.2016.8.14711. PMID: 27464864.

126. Vaniova Klimentova D, Braila AD, Simionescu C, et al. Clinical and paraclinical study regarding the macro- and microscopic diagnosis of various anatomo-clinical forms of operated uterine fibromyoma. Rom J Morphol Embryol. 2012;53(2):369-73. PMID: 22732808.

127. Halder SK, Goodwin JS, Al-Hendy A. 1,25-Dihydroxyvitamin D3 reduces TGF-beta3-induced fibrosis-related gene expression in human uterine leiomyoma cells. J Clin Endocrinol Metab. 2011 Apr;96(4):E754-62. doi: 10.1210/jc.2010-2131. PMID: 21289245.

128. Livnat G, Best LA, Guralnik L, et al. Pulmonary outcome of Alport syndrome with familial diffuse esophageal leiomyomatosis. Pediatr Pulmonol. 2011 Jun;46(6):614-6. doi: 10.1002/ppul.21413. PMID: 21284097.

129. Son CE, Choi JS, Lee JH, et al. A case of laparoscopic myomectomy performed during pregnancy for subserosal uterine myoma. J Obstet Gynaecol. 2011;31(2):180-1. doi: 10.3109/01443615.2010.538774. PMID: 21281039.

130. Wilson M, Evans F, Mylona E, et al. Microscopic intravenous leiomyomatosis: an incidental finding at myomectomy. J Obstet Gynaecol. 2011;31(1):96-7. doi: 10.3109/01443615.2010.513458. PMID: 21281013.

131. Gonzalez-Benitez C, Zapardiel I, Hernandez-Gutierrez A, et al. [Laparoscopic removal of primary intestinal fibroid]. Ginecol Obstet Mex. 2013 Mar;81(3):163-5. PMID: 23672118.

132. Matytsina-Quinlan L, Matytsina L. Submucosal uterine fibroid prolapsed into vagina in a symptomatic patient with IUS. BMJ Case Rep. 2014;2014doi: 10.1136/bcr-2014-203877. PMID: 24739657.

133. Bingol B, Gunenc Z, Gedikbasi A, et al. Comparison of diagnostic accuracy of saline infusion sonohysterography, transvaginal sonography and hysteroscopy. J Obstet Gynaecol. 2011;31(1):54-8. doi: 10.3109/01443615.2010.532246. PMID: 21280995.

134. Lieng M, Berner E, Busund B. Risk of morcellation of uterine leiomyosarcomas in laparoscopic supracervical hysterectomy and laparoscopic myomectomy, a retrospective trial including 4791 women. J Minim Invasive Gynecol. 2015 Mar-Apr;22(3):410-4. doi: 10.1016/j.jmig.2014.10.022. PMID: 25460521.

135. Numbering error.

136. Hada T, Andou M, Kanao H, et al. Vaginal cuff dehiscence after total laparoscopic hysterectomy: examination on 677 cases. Asian J Endosc Surg. 2011 Feb;4(1):20-5. doi: 10.1111/j.1758-5910.2010.00065.x. PMID: 22776170.

137. Doherty L, Mutlu L, Sinclair D, et al. Uterine fibroids: clinical manifestations and contemporary management. Reprod Sci. 2014 Sep;21(9):1067-92. doi: 10.1177/1933719114533728. PMID: 24819877.

138. Krissi H, Peled Y, Efrat Z, et al. Ultrasound diagnosis and comprehensive surgical treatment of complete non-puerperal uterine inversion. Arch Gynecol Obstet. 2011 Mar;283 Suppl 1:111-4. doi: 10.1007/s00404-010-1792-7. PMID: 21274722.

139. Wen KC, Sung PL, Lee WL, et al. Myomectomy for uterine myomas through ultramini-laparotomy. J Obstet Gynaecol Res. 2011 May;37(5):383-92. doi: 10.1111/j.1447-0756.2010.01359.x. PMID: 21272149.

140. Nasser F, Affonso BB, de Jesus-Silva SG, et al. [Uterine fibroid embolization in women with giant fibroids]. Rev Bras Ginecol Obstet. 2010 Nov;32(11):530-5. PMID: 21271163.

141. Galani P, Kapetanakis S, Papadopoulos C, et al. Hypovolemic shock due to giant uterus leiomyoma detachment. Akush Ginekol (Sofiia). 2010;49(5):68-71. PMID: 21265397.

142. Liu HS, Chen CH. Subserosal pyomyoma in a virgin female: sonographic and computed tomographic imaging features. Ultrasound Obstet Gynecol. 2011 Feb;37(2):247-8. doi: 10.1002/uog.8855. PMID: 21264983.

143. De Angelis C, Carnevale A, Santoro G, et al. Hysteroscopic findings in women with menorrhagia. J Minim Invasive Gynecol. 2013 Mar-Apr;20(2):209-14. doi: 10.1016/j.jmig.2012.10.009. PMID: 23295199.

144. Tinelli A, Malvasi A, Guido M, et al. Adhesion formation after intracapsular myomectomy with or without adhesion barrier. Fertil Steril. 2011 Apr;95(5):1780-5. doi: 10.1016/j.fertnstert.2010.12.049. PMID: 21256483.

145. DeWitt J, Emerson RE, Sherman S, et al. Endoscopic ultrasound-guided Trucut biopsy of gastrointestinal mesenchymal tumor. Surg Endosc. 2011 Jul;25(7):2192-202. doi: 10.1007/s00464-010-1522-z. PMID: 21184105.

146. Wang KH, Kao AP, Chang CC, et al. Bisphenol A at environmentally relevant doses induces cyclooxygenase-2 expression and promotes invasion of human mesenchymal stem cells derived from uterine myoma tissue. Taiwan J Obstet Gynecol. 2013 Jun;52(2):246-52. doi: 10.1016/j.tjog.2013.04.016. PMID: 23915859.

147. Cheung VY. Sonographically guided high-intensity focused ultrasound for the management of uterine fibroids. J Ultrasound Med. 2013 Aug;32(8):1353-8. doi: 10.7863/ultra.32.8.1353. PMID: 23887944.

148. McDonald AG, Dal Cin P, Ganguly A, et al. Liposarcoma arising in uterine lipoleiomyoma: a report of 3 cases and review of the literature. Am J Surg Pathol. 2011 Feb;35(2):221-7. doi: 10.1097/PAS.0b013e31820414f7. PMID: 21263242.

149. Taskin S, Sonmezer M, Kahraman K, et al. Hysteroscopic resection of uterine submucous leiomyoma protruding through hymen in a 16-year-old adolescent. J Pediatr Adolesc Gynecol. 2011 Jun;24(3):e77-8. doi: 10.1016/j.jpag.2010.08.001. PMID: 21256782.

150. Tarnawa E, Sullivan S, Underwood P, et al. Severe hypercalcemia associated with uterine leiomyoma in pregnancy. Obstet Gynecol. 2011 Feb;117(2 Pt 2):473-6. doi: 10.1097/AOG.0b013e3181fd29ae. PMID: 21252794.

151. Won HR, Abbott J. Optimal management of chronic cyclical pelvic pain: an evidence-based and pragmatic approach. Int J Womens Health. 2010;2:263-77. doi: 10.2147/ijwh.s7991. PMID: 21151732.

152. Kill LM, Kapetanakis V, McCullough AE, et al. Progression of pelvic implants to complex atypical endometrial hyperplasia after uterine morcellation. Obstet Gynecol. 2011 Feb;117(2 Pt 2):447-9. doi: 10.1097/AOG.0b013e3181f2e0c6. PMID: 21252784.

153. Nemec W, Inwald EC, Buchholz S, et al. Effects of morcellation on long-term outcomes in patients with uterine leiomyosarcoma. Arch Gynecol Obstet. 2016 Oct;294(4):825-31. doi: 10.1007/s00404-016-4086-x. PMID: 27105972.

154. Laughlin SK, Stewart EA. Uterine leiomyomas: individualizing the approach to a heterogeneous condition. Obstet Gynecol. 2011 Feb;117(2 Pt 1):396-403. doi: 10.1097/AOG.0b013e31820780e3. PMID: 21252757.

155. Kuroda K, Kitade M, Kikuchi I, et al. A new instrument: a flexible hysteroscope with narrow band imaging system: optical quality comparison between a flexible and a rigid hysteroscope. Minim Invasive Ther Allied Technol. 2011 Sep;20(5):263-6. doi: 10.3109/13645706.2010.548935. PMID: 21247254.

156. Mattei A, Cioni R, Bargelli G, et al. Techniques of laparoscopic myomectomy. Reprod Biomed Online. 2011 Jul;23(1):34-9. doi: 10.1016/j.rbmo.2010.09.011. PMID: 21251880.

157. Hackethal A, Westermann A, Tchartchian G, et al. Laparoscopic myomectomy in patients with uterine myomas associated with infertility. Minim Invasive Ther Allied Technol. 2011 Dec;20(6):338-45. doi: 10.3109/13645706.2010.541922. PMID: 21247253.

158. Ghizoni JS, Baroni EM, Baroni EJ, et al. Vascular leiomyoma in the oral cavity. Gen Dent. 2013 Jan-Feb;61(1):e9-e11. PMID: 23302372.

159. Yi YX, Zhang W, Guo WR, et al. Meta-analysis: the comparison of clinical results between vaginal and laparoscopic myomectomy. Arch Gynecol Obstet. 2011 Jun;283(6):1275-89. doi: 10.1007/s00404-011-1836-7. PMID: 21234758.

160. Kucera E, Mandys F, Drahonovsky J, et al. [Reproductive outcome after laparoscopic myomectomy--retrospective analysis 1994-2007]. Ceska Gynekol. 2009 Dec;74(6):431-6. PMID: 21246791.

161. Gong J, Xie Y, Dou F, et al. Correlation of thrombomodulin expression and occlusion of the uterine artery for the treatment of leiomyoma. Eur J Obstet Gynecol Reprod Biol. 2011 Feb;154(2):192-5. doi: 10.1016/j.ejogrb.2010.08.004. PMID: 21239103.

162. Dyer JD. Nontarget embolisation or local effect of infarction? Cardiovasc Intervent Radiol. 2013 Aug;36(4):1172. doi: 10.1007/s00270-013-0637-8. PMID: 23674272.

163. Sakai T, Manabe W, Kamitani T, et al. [Ropivacaine-induced late-onset systemic toxicity after transversus abdominis plane block under general anesthesia: successful reversal with 20% lipid emulsion]. Masui. 2010 Dec;59(12):1502-5. PMID: 21229691.

164. Thomas B, Magos A. Subtotal hysterectomy and myomectomy - vaginally. Best Pract Res Clin Obstet Gynaecol. 2011 Apr;25(2):133-52. doi: 10.1016/j.bpobgyn.2010.11.003. PMID: 21185235.

165. Mijailovic MZ, Lukic SM, Jankovic SM, et al. Arterial embolization of uterine fibroids. J buon. 2010 Oct-Dec;15(4):704-7. PMID: 21229633.

166. Pinto E, Trovao A, Leitao S, et al. Conservative laparoscopic approach to a perforated pyomyoma after uterine artery embolization. J Minim Invasive Gynecol. 2012 Nov-Dec;19(6):775-9. doi: 10.1016/j.jmig.2012.07.001. PMID: 23084686.

167. Okamura H, Yamaguchi A, Kimura N, et al. Partial resection of intravenous leiomyomatosis with cardiac extension. Gen Thorac Cardiovasc Surg. 2011 Jan;59(1):38-41. doi: 10.1007/s11748-010-0620-0. PMID: 21225399.

168. Kim CH, Kim SR, Lee HA, et al. Transvaginal ultrasound-guided radiofrequency myolysis for uterine myomas. Hum Reprod. 2011 Mar;26(3):559-63. doi: 10.1093/humrep/deq366. PMID: 21216788.

169. Anzaku AS, Musa J. Total abdominal hysterectomy for benign gynaecological conditions at a University Teaching Hospital in Nigeria. Niger J Med. 2012 Jul-Sep;21(3):326-30. PMID: 23304930.

170. Kojima T, Taki Y, Fujisawa H, et al. Leiomyoma treatment by uterine artery embolization using gelatin sponge prepared by the pumping method. Exp Ther Med. 2012 Nov;4(5):781-4. doi: 10.3892/etm.2012.688. PMID: 23226725.

171. Raspagliesi F, Maltese G, Bogani G, et al. Morcellation worsens survival outcomes in patients with undiagnosed uterine leiomyosarcomas: A retrospective MITO group study. Gynecologic Oncology. doi: 10.1016/j.ygyno.2016.11.002.

172. Rechberger T, Miotla P, Futyma K, et al. Power morcellation for women undergoing laparoscopic supracervical hysterectomy - safety of procedure and clinical experience from 426 cases. Ginekol Pol. 2016;87(8):546-51. doi: 10.5603/gp.2016.0042. PMID: 27629127.

173. McLucas B, Danzer H, Wambach C, et al. Ovarian reserve following uterine artery embolization in women of reproductive age: a preliminary report. Minim Invasive Ther Allied Technol. 2013 Feb;22(1):45-9. doi: 10.3109/13645706.2012.743918. PMID: 23311507.

174. Okuda S, Oshio K, Asada H, et al. Reduction in the vascular bed volume of uterine fibroids after hormonal treatment: evaluation with dynamic double-echo R(2)* imaging. Magn Reson Med Sci. 2012;11(4):283-9. PMID: 23269015.

175. Brodowska A, Brodowski J, Laszczynska M, et al. Immunoexpression of aromatase cytochrome P450 and 17beta-hydroxysteroid dehydrogenase in women's ovaries after menopause. J Ovarian Res. 2014;7:52. doi: 10.1186/1757-2215-7-52. PMID: 24855493.

176. Lim MC, Song YJ, Seo SS, et al. Embryonic-natural orifice transumbilical endoscopic surgery for myomectomy with traction of multidirectional sutures: a new surgical approach. J Laparoendosc Adv Surg Tech A. 2011 Jan-Feb;21(1):35-7. doi: 10.1089/lap.2010.0268. PMID: 21214489.

177. Yang WW, Zhu BR, Li J, et al. [Analysis of complications of high intensity focused ultrasound in treatment of uterine leiomyoma.]. Zhonghua Fu Chan Ke Za Zhi. 2010 Dec;45(12):913-6. PMID: 21211423.

178. Chen WZ, Tang LD, Yang WW, et al. [Study on the efficacy and safety of ultrasound ablation in treatment of uterine fibroids.]. Zhonghua Fu Chan Ke Za Zhi. 2010 Dec;45(12):909-12. PMID: 21211422.

179. Modupeola S, Adesiyun A, Agunbiade O, et al. Clinico-pathological assessment of hysterectomies in Zaria. European Journal of General Medicine. 2009;6(3).

180. Sandberg EM, van den Haak L, Bosse T, et al. Disseminated leiomyoma cells can be identified following conventional myomectomy. BJOG. 2016 Aug 17doi: 10.1111/1471-0528.14265. PMID: 27533508.

181. Tsili AC, Lentoudi ED, Argyropoulou MI, et al. Fibromatous uterus in a 16-year-old girl: a case report. Case Rep Med. 2010;2010:932762. doi: 10.1155/2010/932762. PMID: 21209811.

182. Malik S, Mahendru R, Rana SS. Vaginal leiomyoma presenting as dysfunctional uterine bleeding. Taiwan J Obstet Gynecol. 2010 Dec;49(4):531-2. doi: 10.1016/s1028-4559(10)60113-1. PMID: 21199763.

183. Croce S, Young RH, Oliva E. Uterine leiomyomas with bizarre nuclei: a clinicopathologic study of 59 cases. Am J Surg Pathol. 2014 Oct;38(10):1330-9. doi: 10.1097/pas.0000000000000249. PMID: 25140893.

184. Lee SL, Huang LW, Chang JZ, et al. Pelvic abscess after laparoscopic myomectomy with vaginal extraction. Taiwan J Obstet Gynecol. 2010 Dec;49(4):528-30. doi: 10.1016/s1028-4559(10)60112-x. PMID: 21199762.

185. Ahn SY, Jeon SW. Endoscopic resection of co-existing severe dysplasia and a small esophageal leiomyoma. World J Gastroenterol. 2013 Jan 7;19(1):137-40. doi: 10.3748/wjg.v19.i1.137. PMID: 23326177.

186. Serur E, Zambrano N, Brown K, et al. Extracorporeal Manual Morcellation of Very Large Uteri Within an Enclosed Endoscopic Bag: Our 5-Year Experience. J Minim Invasive Gynecol. 2016 Sep-Oct;23(6):903-8. doi: 10.1016/j.jmig.2016.03.016. PMID: 27058770.

187. Jackson TR, Einarsson JI. Single-incision laparoscopic myomectomy. J Minim Access Surg. 2011 Jan;7(1):83-6. doi: 10.4103/0972-9941.72391. PMID: 21197249.

188. Kim KA, Yoon SW, Yoon BS, et al. Spontaneous vaginal expulsion of uterine myoma after magnetic resonance-guided focused ultrasound surgery. J Minim Invasive Gynecol. 2011 Jan-Feb;18(1):131-4. doi: 10.1016/j.jmig.2010.09.015. PMID: 21195969.

189. Jiang GQ, Gao YN, Gao M, et al. Benign metastasizing leiomyoma: report of two cases and literature review. Chin Med J (Engl). 2010 Nov;123(22):3367-71. PMID: 21163149.

190. Kuzel D, Mara M, Horak P, et al. Comparative outcomes of hysteroscopic examinations performed after uterine artery embolization or laparoscopic uterine artery occlusion to treat leiomyomas. Fertil Steril. 2011 May;95(6):2143-5. doi: 10.1016/j.fertnstert.2010.12.014. PMID: 21195400.

191. Firouznia K, Ghanaati H, Jalali AH, et al. Uterine artery embolization for treatment of symptomatic fibroids: a review of the evidence. Iran Red Crescent Med J. 2013 Dec;15(12):e16699. doi: 10.5812/ircmj.16699. PMID: 24693405.

192. Smits RM, De Kruif JH, Van Heteren CF. Complication rate of uterine morcellation in laparoscopic supracervical hysterectomy: a retrospective cohort study. Eur J Obstet Gynecol Reprod Biol. 2016 Apr;199:179-82. doi: 10.1016/j.ejogrb.2016.02.022. PMID: 26943477.

193. Song T, Kim TJ, Lee SH, et al. Laparoendoscopic single-site myomectomy compared with conventional laparoscopic myomectomy: a multicenter, randomized, controlled trial. Fertil Steril. 2015 Nov;104(5):1325-31. doi: 10.1016/j.fertnstert.2015.07.1137. PMID: 26263079.

194. Rothmund R, Szyrach M, Reda A, et al. A prospective, randomized clinical comparison between UltraCision and the novel sealing and cutting device BiCision in patients with laparoscopic supracervical hysterectomy. Surg Endosc. 2013 Oct;27(10):3852-9. doi: 10.1007/s00464-013-2994-4. PMID: 23670744.

195. Carta G, Palermo P, Di Ramio R, et al. Leiomyosarcoma after hysteroscopic myomectomy: a case report. Eur J Gynaecol Oncol. 2012;33(6):656-7. PMID: 23327066.

196. Garcia-Donas J, Hernando S, Romero N, et al. Knowledge of hereditary renal cancer syndromes: a pending issue for oncologists. Anticancer Drugs. 2011 Jan;22 Suppl 1:S15-20. doi: 10.1097/01.cad.0000390768.93282.65. PMID: 21173603.

197. Gajewska M, Kosinska-Kaczynska K, Marczewska J, et al. [Huge uterine leiomyoma with degenerative changes mimicking ovarian carcinoma--a case report]. Ginekol Pol. 2013 Feb;84(2):147-50. PMID: 23668063.

198. Diaconescu MR, Diaconescu S. Mesenchymal (non-epithelial) "non-GIST" tumors of the digestive tract. Chirurgia (Bucur). 2012 Nov-Dec;107(6):742-50. PMID: 23294952.

199. Toubia T, Moulder JK, Schiff LD, et al. Peritoneal Washings After Power Morcellation in Laparoscopic Myomectomy: A Pilot Study. J Minim Invasive Gynecol. 2016 May-Jun;23(4):578-81. doi: 10.1016/j.jmig.2016.02.001. PMID: 26867701.

200. Uccella S, Cromi A, Serati M, et al. Laparoscopic hysterectomy in case of uteri weighing >/=1 kilogram: a series of 71 cases and review of the literature. J Minim Invasive Gynecol. 2014 May-Jun;21(3):460-5. doi: 10.1016/j.jmig.2013.08.706. PMID: 24012921.

201. Ahmadi F, Zafarani F, Haghighi H, et al. Application of 3D Ultrasonography in Detection of Uterine Abnormalities. Int J Fertil Steril. 2011 Jan;4(4):144-7. PMID: 24851173.

202. Gandhi AC, Dugad HI, Shah Y. A rare presentation of cervical fibroid in pregnancy. Ann Afr Med. 2014 Apr-Jun;13(2):88-90. doi: 10.4103/1596-3519.129889. PMID: 24705114.

203. Urgesi R, Pastorelli A, Zampaletta C, et al. Obscure-occult bleeding: resolution of unexplained chronic sideropenic anaemia by colonoscopic removal of a colonic leiomyoma. BMJ Case Rep. 2011;2011doi: 10.1136/bcr.11.2009.2455. PMID: 22714624.

204. Diop MM, Diao B, Toure PS, et al. Acute renal failure in the postpartum due to calcified myoma: a case report. West Afr J Med. 2012 Jul-Sep;31(3):204-6. PMID: 23310943.

205. Vercellini P, Cribiu FM, Bosari S, et al. Prevalence of unexpected leiomyosarcoma at myomectomy: a descriptive study. Am J Obstet Gynecol. 2016 Feb;214(2):292-4. doi: 10.1016/j.ajog.2015.09.092. PMID: 26450408.

206. Kim da H, Kim ML, Song T, et al. Is myomectomy in women aged 45 years and older an effective option? Eur J Obstet Gynecol Reprod Biol. 2014 Jun;177:57-60. doi: 10.1016/j.ejogrb.2014.04.006. PMID: 24768231.

207. Saxena R, Shah T, Thirumalappa S, et al. Technique of abdominal hysterectomy for non-puerperal uterine inversion. BMJ Case Rep. 2011;2011doi: 10.1136/bcr.01.2011.3729. PMID: 22700070.

208. Bullock R, Mayhew R, Gibson T, et al. Leiomyoma: an unusual bladder neoplasm. BMJ Case Rep. 2011;2011doi: 10.1136/bcr.01.2011.3739. PMID: 22688470.

209. Ghosh B, McKeown B, Gumma A. Lipoleiomyoma. BMJ Case Rep. 2011;2011doi: 10.1136/bcr.08.2011.4577. PMID: 22679054.

210. Pushpalatha K, Kumar S, Dinda AK, et al. Symplastic leiomyoma of uterus--a clinico-pathological dilemma. BMJ Case Rep. 2011;2011doi: 10.1136/bcr.09.2011.4835. PMID: 22674600.

211. Stroumsa D, Ben-David E, Hiller N, et al. Severe Clostridial Pyomyoma following an Abortion Does Not Always Require Surgical Intervention. Case Rep Obstet Gynecol. 2011;2011:364641. doi: 10.1155/2011/364641. PMID: 22567505.

212. Deshpande G, Kaul R, P M. A case of torsion of gravid uterus caused by leiomyoma. Case Rep Obstet Gynecol. 2011;2011:206418. doi: 10.1155/2011/206418. PMID: 22567496.

213. Lazarov N, Lazarov L, Lazarov S. [Angioleiomyoma utery in a female patient with damaged health condition. Diagnostic and terapeutic difficulties]. Akush Ginekol (Sofiia). 2011;50(4):54-8. PMID: 22479899.

214. Xu GQ, Chen HT, Xu CF, et al. Esophageal granular cell tumors: report of 9 cases and a literature review. World J Gastroenterol. 2012 Dec 21;18(47):7118-21. doi: 10.3748/wjg.v18.i47.7118. PMID: 23323018.

215. Desai P, Patel P. Fibroids, infertility and laparoscopic myomectomy. J Gynecol Endosc Surg. 2011 Jan;2(1):36-42. doi: 10.4103/0974-1216.85280. PMID: 22442534.

216. Trehan N. Laparoscopic myomectomy: methods to control bleeding. J Gynecol Endosc Surg. 2011 Jan;2(1):33-5. doi: 10.4103/0974-1216.85278. PMID: 22442533.

217. Sinha R, Sundaram M, Mahajan C, et al. Laparoscopic myomectomy with uterine artery ligation: review article and comparative analysis. J Gynecol Endosc Surg. 2011 Jan;2(1):3-10. doi: 10.4103/0974-1216.85272. PMID: 22442527.

218. Gordts S. New developments in reproductive surgery. Best Pract Res Clin Obstet Gynaecol. 2013 Jun;27(3):431-40. doi: 10.1016/j.bpobgyn.2012.11.004. PMID: 23291212.

219. Bonduki CE, Feldner Jr PC, Silva J, et al. Pregnancy after uterine arterial embolization. Clinics (Sao Paulo). 2011;66(5):807-10. PMID: 21789384.

220. Taniguchi F, Higaki H, Azuma Y, et al. Gonadotropin-releasing hormone analogues reduce the proliferation of endometrial stromal cells but not endometriotic cells. Gynecol Obstet Invest. 2013;75(1):9-15. doi: 10.1159/000343748. PMID: 23147672.

221. Zhang L, Wang ZB. High-intensity focused ultrasound tumor ablation: review of ten years of clinical experience. Front Med China. 2010 Sep;4(3):294-302. doi: 10.1007/s11684-010-0092-8. PMID: 21191835.

222. Marret H, Bleuzen A, Guerin A, et al. [French first results using magnetic resonance-guided focused ultrasound for myoma treatment]. Gynecol Obstet Fertil. 2011 Jan;39(1):12-20. doi: 10.1016/j.gyobfe.2010.08.038. PMID: 21185759.

223. Einstein MH, Barakat RR, Chi DS, et al. Management of uterine malignancy found incidentally after supracervical hysterectomy or uterine morcellation for presumed benign disease. Int J Gynecol Cancer. 2008 Sep-Oct;18(5):1065-70. doi: 10.1111/j.1525-1438.2007.01126.x. PMID: 17986239.

224. Takamizawa S, Minakami H, Usui R, et al. Risk of complications and uterine malignancies in women undergoing hysterectomy for presumed benign leiomyomas. Gynecol Obstet Invest. 1999;48(3):193-6. doi: 10172. PMID: 10545745.

225. Oduyebo T, Rauh-Hain AJ, Meserve EE, et al. The value of re-exploration in patients with inadvertently morcellated uterine sarcoma. Gynecol Oncol. 2014 Feb;132(2):360-5. doi: 10.1016/j.ygyno.2013.11.024. PMID: 24296345.

226. Graebe K, Garcia-Soto A, Aziz M, et al. Incidental power morcellation of malignancy: A retrospective cohort study. Gynecol Oncol. 2015 Feb;136(2):274-7. doi: 10.1016/j.ygyno.2014.11.018. PMID: 25740603.

227. Tan-Kim J, Hartzell KA, Reinsch CS, et al. Uterine sarcomas and parasitic myomas after laparoscopic hysterectomy with power morcellation. Am J Obstet Gynecol. 2014 Dec 11doi: 10.1016/j.ajog.2014.12.002. PMID: 25499259.

228. Sinha R, Hegde A, Mahajan C, et al. Laparoscopic myomectomy: do size, number, and location of the myomas form limiting factors for laparoscopic myomectomy? J Minim Invasive Gynecol. 2008 May-Jun;15(3):292-300. doi: 10.1016/j.jmig.2008.01.009. PMID: 18439500.

229. Tan A, Salfinger S, Tan J, et al. Morcellation of occult uterine malignancies: an Australian single institution retrospective study. Aust N Z J Obstet Gynaecol. 2015 Oct;55(5):503-6. doi: 10.1111/ajo.12401. PMID: 26314239.

230. Seidman MA, Oduyebo T, Muto MG, et al. Peritoneal dissemination complicating morcellation of uterine mesenchymal neoplasms. PLoS One. 2012;7(11):e50058. doi: 10.1371/journal.pone.0050058. PMID: 23189178.

231. Zhang J, Zhang J, Dai Y, et al. Clinical characteristics and management experience of unexpected uterine sarcoma after myomectomy. Int J Gynaecol Obstet. 2015 Aug;130(2):195-9. doi: 10.1016/j.ijgo.2015.01.009. PMID: 26117552.

232. Bojahr B, De Wilde RL, Tchartchian G. Malignancy rate of 10,731 uteri morcellated during laparoscopic supracervical hysterectomy (LASH). Arch Gynecol Obstet. 2015 Sep;292(3):665-72. doi: 10.1007/s00404-015-3696-z. PMID: 25820974.

233. Theben JU, Schellong AR, Altgassen C, et al. Unexpected malignancies after laparoscopic-assisted supracervical hysterectomies (LASH): an analysis of 1,584 LASH cases. Arch Gynecol Obstet. 2013 Mar;287(3):455-62. doi: 10.1007/s00404-012-2559-0. PMID: 23053310.

234. Brown J, Taylor K, Ramirez PT, et al. Laparoscopic supracervical hysterectomy with morcellation: should it stay or should it go? J Minim Invasive Gynecol. 2015 Feb;22(2):185-92. doi: 10.1016/j.jmig.2014.09.005. PMID: 25242233.

235. Brohl AS, Li L, Andikyan V, et al. Age-stratified risk of unexpected uterine sarcoma following surgery for presumed benign leiomyoma. Oncologist. 2015 Apr;20(4):433-9. doi: 10.1634/theoncologist.2014-0361. PMID: 25765878.

236. Zhang J, Li T, Zhang J, et al. Clinical Characteristics and Prognosis of Unexpected Uterine Sarcoma After Hysterectomy for Presumed Myoma With and Without Transvaginal Scalpel Morcellation. Int J Gynecol Cancer. 2016 Jan 20doi: 10.1097/igc.0000000000000638. PMID: 26807642.

237. Cormio G, Loizzi V, Ceci O, et al. Unsuspected diagnosis of uterine leiomyosarcoma after laparoscopic myomectomy. J Obstet Gynaecol. 2015 Feb;35(2):211-2. doi: 10.3109/01443615.2014.937332. PMID: 25057886.

238. Lin KH, Torng PL, Tsai KH, et al. Clinical outcome affected by tumor morcellation in unexpected early uterine leiomyosarcoma. Taiwan J Obstet Gynecol. 2015 Apr;54(2):172-7. doi: 10.1016/j.tjog.2015.03.001. PMID: 25951723.

239. Perri T, Korach J, Sadetzki S, et al. Uterine leiomyosarcoma: does the primary surgical procedure matter? Int J Gynecol Cancer. 2009 Feb;19(2):257-60. doi: 10.1111/IGC.0b013e31819a1f8f. PMID: 19396005.

240. Raine-Bennett T, Tucker LY, Zaritsky E, et al. Occult Uterine Sarcoma and Leiomyosarcoma: Incidence of and Survival Associated With Morcellation. Obstet Gynecol. 2016 Jan;127(1):29-39. doi: 10.1097/aog.0000000000001187. PMID: 26646120.

241. Morice P, Rodriguez A, Rey A, et al. Prognostic value of initial surgical procedure for patients with uterine sarcoma: analysis of 123 patients. Eur J Gynaecol Oncol. 2003;24(3-4):237-40. PMID: 12807231.

Appendix H. Estimates of Subsequent Treatment for Uterine Fibroids

Table H-1. Estimated probability of subsequent treatment for fibroids following medical management

Next Intervention		None	IUD	UAE	MRgFUS	Myomectomy	Hysterectomy
Age	**Followup**						
30	6	0.99 (0.98, 0.99)	0.00 (0.00, 0.00)	0.00 (0.00, 0.00)	0.00 (0.00, 0.00)	0.00 (0.00, 0.00)	0.01 (0.01, 0.02)
	12	0.98 (0.96, 0.99	0.00 (0.00, 0.00)	0.00 (0.00, 0.00)	0.00 (0.00, 0.00)	0.00 (0.00, 0.00)	0.02 (0.01, 0.04)
	24	0.94 (0.89, 0.97)	0.00 (0.00, 0.00)	0.00 (0.00, 0.00)	0.00 (0.00, 0.00)	0.00 (0.00, 0.00)	0.06 (0.03, 0.11)
40	6	0.98 (0.98, 0.99)	0.00 (0.00, 0.00)	0.00 (0.00, 0.00)	0.00 (0.00, 0.00)	0.00 (0.00, 0.00)	0.02 (0.01, 0.02)
	12	0.97 (0.96, 0.98)	0.00 (0.00, 0.00)	0.00 (0.00, 0.00)	0.00 (0.00, 0.00)	0.00 (0.00, 0.00)	0.03 (0.02, 0.04)
	24	0.91 (0.89, 0.94)	0.00 (0.00, 0.00)	0.00 (0.00, 0.00)	0.00 (0.00, 0.00)	0.00 (0.00, 0.00)	0.09 (0.06, 0.11)
50	6	0.98 (0.96, 0.99)	0.00 (0.00, 0.00)	0.00 (0.00, 0.00)	0.00 (0.00, 0.00)	0.00 (0.00, 0.00)	0.02 (0.01, 0.04)
	12	0.96 (0.94, 0.98)	0.00 (0.00, 0.00)	0.00 (0.00, 0.00)	0.00 (0.00, 0.00)	0.00 (0.00, 0.00)	0.04 (0.02, 0.06)
	24	0.89 (0.85, 0.92)	0.00 (0.00, 0.00)	0.00 (0.00, 0.00)	0.00 (0.00, 0.00)	0.00 (0.00, 0.00)	0.12 (0.08, 0.15)

Table H-2. Estimated probability of subsequent treatment for fibroids following uterine artery embolization

Next Intervention		None	IUD	UAE	MRgFUS	Myomectomy	Hysterectomy
Age	**Followup**						
30	6	0.66 (0.46, 0.81)	0.00 (0.00, 0.01)	0.13 (0.03, 0.32)	0.00 (0.00, 0.00)	0.18 (0.05, 0.38)	0.00 (0.00, 0.00)
	12	0.64 (0.48, 0.78)	0.00 (0.00, 0.00)	0.10 (0.02, 0.22)	0.00 (0.00, 0.00)	0.24 (0.10, 0.41)	0.01 (0.00, 0.02)
	24	0.56 (0.43, 0.69)	0.00 (0.00, 0.00)	0.05 (0.01, 0.11)	0.00 (0.00, 0.00)	0.37 (0.23, 0.51)	0.01 (0.00, 0.04)
40	6	0.93 (0.90, 0.94)	0.00 (0.00, 0.01)	0.04 (0.03, 0.06)	0.00 (0.00, 0.00)	0.01 (0.01, 0.02)	0.02 (0.01, 0.03)
	12	0.92 (0.90, 0.94)	0.00 (0.00, 0.00)	0.03 (0.02, 0.04)	0.00 (0.00, 0.00)	0.02 (0.01, 0.03)	0.03 (0.02, 0.04)
	24	0.88 (0.84, 0.92)	0.00 (0.00, 0.00)	0.02 (0.01, 0.03)	0.00 (0.00, 0.00)	0.03 (0.01 to 0.06)	0.06 (0.04, 0.10)
50	6	0.90 (0.58, 0.97)	0.03 (0.00, 0.38)	0.01 (0.00, 0.02)	0.00 (0.00, 0.00)	0.00 (0.00, 0.00)	0.05 (0.02, 0.10)
	12	0.89 (0.77, 0.96)	0.01 (0.00, 0.14)	0.01 (0.00, 0.01)	0.00 (0.00, 0.00)	0.00 (0.00, 0.00)	0.08 (0.04, 0.14)
	24	0.81 (0.70, 0.90)	0.00 (0.00, 0.02)	0.00 (0.00, 0.01)	0.00 (0.00, 0.00)	0.00 (0.00, 0.01)	0.18 (0.09, 0.29)

Table H-3. Estimated probability of subsequent treatment for fibroids following myomectomy

Next Intervention		None	IUD	UAE	MRgFUS	Myomectomy	Hysterectomy
Age	**Followup**						
30	6	0.97 (0.84, 1.00)	0.00 (0.00, 0.01)	0.00 (0.00, 0.00)	0.00 (0.00, 0.00)	0.02 (0.00, 0.14)	0.00 (0.00, 0.02)
	12	0.97 (0.85, 1.00)	0.00 (0.00, 0.00)	0.00 (0.00, 0.00)	0.00 (0.00, 0.00)	0.03 (0.00, 0.14)	0.00 (0.00, 0.01)
	24	0.93 (0.77, 1.00)	0.00 (0.00, 0.00)	0.00 (0.00, 0.00)	0.00 (0.00, 0.00)	0.07 (0.01, 0.22)	0.00 (0.00, 0.01)
40	6	1.00 (0.99, 1.00)	0.00 (0.00, 0.00)	0.00 (0.00, 0.00)	0.00 (0.00, 0.00)	0.00 (0.00, 0.00)	0.00 (0.00, 0.01)
	12	1.00 (0.99, 1.00)	0.00 (0.00, 0.00)	0.00 (0.00, 0.00)	0.00 (0.00, 0.00)	0.00 (0.00, 0.00)	0.00 (0.00, 0.00)
	24	1.00 (0.99, 1.00)	0.00 (0.00, 0.00)	0.00 (0.00, 0.00)	0.00 (0.00, 0.00)	0.00 (0.00, 0.01)	0.00 (0.00, 0.01)
50	6	0.60 (0.00, 1.00)	0.00 (0.00, 0.13)	0.00 (0.00, 0.05)	0.00 (0.00, 0.01)	0.00 (0.00, 0.00)	0.00 (0.00, 0.14)
	12	1.00 (0.84, 1.00)	0.00 (0.00, 0.01)	0.00 (0.00, 0.01)	0.00 (0.00, 0.00)	0.00 (0.00, 0.00)	0.00 (0.00, 0.09)
	24	1.00 (0.89, 1.00)	0.00 (0.00, 0.00)	0.00 (0.00, 0.00)	0.00 (0.00, 0.00)	0.00 (0.00, 0.00)	0.00 (0.00, 0.06)

Appendix I. Summary of Existing Systematic Reviews

Medical Interventions

Table I-1. Existing reviews of medical interventions for uterine fibroids (8 reviews)

Author, Year	Intervention	Inclusion Criteria	Outcome(s)	# Studies Included	Key Findings
Peitsidis et al. 2014[1]	Medical -Tranexamic acid	Women of reproductive age with symptomatic fibroids Administration of tranexamic acid Literature from 1950 to 2014	Menorrhagia Periprocedural blood loss	5 studies 349 women; of these 206 patients treated with tranexamic acid and 101 patients allocated to placebo groups	Only 5 included studies Presence of bias related to size and location of fibroids Tranexamic acid may reduce blood loss perioperatively in myomectomies
Kamath et al. 2014[2]	Medical -GnRH analogues	Women undergoing hysteroscopic resection of submucous fibroids RCTs Literature from 1980 to July 2012	Menstrual symptoms	2 studies Study 1: 47 patients (24 intervention; 23 control) Study 2: 39 patients (20 intervention; 19 control)	Only 2 included studies No significant difference in symptom relief Inadequate evidence to show support for routine use
Chen et al. 2011[3]	Medical -GnRH agonists	Comparison of GnRH agonist pretreatment with placebo or no pretreatment RCTs Literature from January 1950 to June 2010	Intraoperative blood loss Transfusion Duration of surgery	3 RCTs encompassing 7 reports Included 168 women, 85 received GnRH and 83 who did not	GnRH pretreatment had no effect on operative time Intraoperative blood loss was statistically lowered
Steinauer et al. 2004[4]	Medical -Mifepristone	Mifepristone Literature from 1985 to 2002	Leiomyoma or uterine size	6 studies All before and after clinical trials comparing pretreatment and posttreatment leiomyoma or uterine volume	Small sample sizes in studies Mifepristone helped to reduce leiomyoma size Improvement in symptoms
Lethaby et al. 2002[5]	Medical -GnRH analogues (GnRHa)	GnRHa administered prior to surgery Literature from 1980 to 2000 RCTs	Uterine and fibroid volume Duration of operation Complications	GnRHa vs no therapy (14 studies) GnRHa vs placebo (6 studies) GnRHa vs lynestrenol (1 study)	Pre- and post-operative hemoglobin and hematocrit significantly improved Reduction in uterine and fibroid volume Pelvic symptoms were reduced but with adverse events GnRHa beneficial in correction of preoperative iron deficiency anemia

Table I-1. Existing Reviews of Medical Interventions for Uterine Fibroids (8 reviews), continued

Author, Year	Intervention	Inclusion Criteria	Outcome(s)	# Studies Included	Key Findings
Deng et al. 2012[6]	Medical -Selective estrogen receptor modulators (SERMs)	Women with confirmed uterine fibroids Women of reproductive age RCTs	Fibroid size Quality of life Symptoms Adverse events	3 studies, number of participants ranged from 25 to 100	Raloxifene used in all included studies Included studies were of poor quality Use of SERMs show reduction of fibroid size No included studies reported quality of life
Song et al. 2013[7]	Medical -Aromatase inhibitors	Use of aromatase inhibitors for uterine fibroids RCTs	Fibroid size Symptoms Adverse events	1 study with 70 participants	Only 1 included study No evidence of relief of symptoms Study failed to report important clinical outcomes
Moroni et al. 2015[8]	Medical -Add back therapy for GnRH analogue treatment	Women with symptomatic uterine fibroids RCTs	Quality of life Bone density Vasomotor symptoms Uterine volume and bleeding	14 studies Data extracted from 12 studies with 622 participants	Most (9/12) assessed as high risk of bias Maximum followup was 6 months Some evidence that add back with tibolone improves quality of life

Procedural Interventions

Table I-2. Existing reviews of procedural interventions for uterine fibroids (2 reviews)

Author, Year	Intervention Category	Inclusion Criteria	Outcome(s)	Included Studies	Key Findings
Clark, N et al 2014[9]	MRI-guided focused ultrasound	MRgFUS for treatment of uterine fibroids	Symptoms Subsequent reproductive outcomes Pregnancy	39 (subset of 10 included in meta-analysis) Case reports, case series, reviews and retrospective evaluations	Symptom severity scores improved from baseline 56.3 to 31.0 after 6 months (95% CI: 23.9-38.2) 35 pregnancies reported Average time to conception was 8 months after procedure
Gizzo et al, 2014[10]	MRI-guided focused ultrasound myomectomy	Studies reporting data of myomectomy by MRgFUS	Number of fibroids treated Fibroid volume UFS-QOL Fertility Harms	38 studies including case reports, retrospective and prospective case series (included approximately 2500 women)	Most frequently reported complications skin burns, abdominal pain, sciatic nerve paresthesia or leg pain. UFS-QOL scores improved at 3, 6 and 12 months following treatment

Levonorgestrel Intrauterine Device (IUD)/Levonorgestrel Intrauterine System (LNG-IUS)

Table I-3. Systematic reviews of LNG-IUS (4 reviews)

Author, Year	Intervention Category	Inclusion Criteria	Outcome(s)	Included Studies	Key Findings
Jiang W, Shen Q, Chen M, et al. 2014[11]	LNG-IUS	Premenopausal women with symptomatic uterine leiomyoma Search dates: database inception through July 2013	Fibroid and bleeding outcomes Adverse effects	11 studies; sample sizes ranging from 10 to 104	Fibroid and bleeding outcomes uterine volume: decreased menstrual blood loss: reduced hemoglobin: increased ferritin: increased hematocrit: increased leiomyoma volume: no change Adverse effects Device expulsion increased with leiomyoma size (larger than 3cm) not associated with leiomyoma location Irregular bleeding/ spotting Observed at the beginning of the follow-up period and then decreased
Varma R, Sinha D, Gupta JK. 2006[12]	LNG-IUS	Observational and experimental studies of LNG-IUS Search dates: 1996 to 2005	Fibroid and bleeding outcomes	3 RCTs; 7 observational studies for fibroids or fibroid related menorrhagia	Fibroid and bleeding outcomes menstrual blood loss: decreased 84–90% hemoglobin: increased 2–3 g/dl fibroid size: inconsistent (decreased and no change)
Zapata LB, Whiteman MK, Tepper NK, et al. 2010[13]	LNG-IUS	Women with uterine fibroids IUD (copper or levonorgestrel-releasing) use and uterine fibroids Search dates: database inception through June 2009	Fibroid and bleeding outcomes Expulsion rates	11 studies	Fibroid and bleeding outcomes menstrual blood loss: decreased (11 studies) among women using IUD hemoglobin, hematocrit and ferritin levels increased LNG-IUD expulsion rates women with uterine fibroids: 0-20% (2 cohort studies, fair to poor quality; 6 noncomparative studies) women without uterine fibroids: 0 - 3% (2 cohort studies, fair to poor quality)

Table I-3.Systematic Reviews of LNG-IUS (4 reviews), continued

Author, Year	Intervention Category	Inclusion Criteria	Outcome(s)	Included Studies	Key Findings
Sangkomkamhang US, Lumbiganon P, Laopaiboon M, et al. 2013[14]	LNG-IUS	Premenopausal women with uterine fibroids	Fibroid symptoms and characteristics Quality of life Recurrence Adverse events Cost effectiveness	3 RCTs with 187 women	No evidence of effectiveness of progestogens Limited evidence of effectiveness of LNG-IUS Small sample sizes and few studies

Uterine Artery Embolization (UAE)

Table I-4. Existing reviews of UAE interventions for uterine fibroids (5 reviews)

Author, Year	Intervention Category	Inclusion Criteria	Outcome(s)	Included Studies	Key Findings
Das et al, 2014[15]	UAE, comparison of embolic agents	Reproductive age women Uterine artery embolization for uterine fibroids.	UFS-QOL Imaging outcomes Fibroid infarction rate Fibroid volume	5 RCTs (295 women) 5 non-RCTs (617 women)	No evidence for superiority of any embolic agent
Martin et al, 2013[16]	UAE	Uterine artery embolization	Complication Reintervention	8 RCTs with 350 participants 76 non-RCTs with 11,195 participants 41 case studies with 83 participants	Significantly lower rates of major complications with UAE compared to surgery (2 RCTs) Increased risk (ORs ranging from 2.7-10.4) of reintervention for UAE ((3 RCTs) UAE failure (4%), fever (4%), and postembolization syndrome (2.9%)
Toor et al, 2012[17]	UAE	Women treated with UAE for uterine fibroids Minimum followup of 1 month	Complication Reintervention	54 studies with 8159 participants including 7 RCTs, 37 prospective cohorts and 10 retrospective	Rate of major complications was 2.9% (95% CI 2.2-3.8%) The rate of follow up hysterectomy to resolve complication was 0.7% (95% CI 0.5-0.9%) Reintervention rates were 5.3%
Van der Kooji et al, 2011[18]	UAE vs surgery	Premenopausal women with heavy bleeding due to symptomatic fibroids Controlled trials comparing UAE vs surgery	Procedure results Return to activities Symptom status Quality of life Complication Reintervention	4 RCTs with 515 participants	UAE associated with less blood loss, and quicker return to normal activities. Long-term quality of life results were comparable for UAE and surgical groups Higher reintervention rate following UAE

Table I-4. Existing reviews of UAE interventions for uterine fibroids (5 reviews), continued

Author, Year	Intervention Category	Inclusion Criteria	Outcome(s)	Included Studies	Key Findings
Gupta et al, 2014[19]	UAE vs medical or surgical comparator	Women with symptomatic uterine fibroids RCTs comparing UAE to any medical or surgical therapy	Patient satisfaction Live birth	7 RCTs with 793 participants	No differences in patient satisfaction up to 2 or 5 years Higher rate of reintervention for UAE within 2 years No differences in risk of major complications Higher rate of minor complications associated with UAE Limited data on live births

Uterine Sparing Interventions

Table I-5. Existing reviews uterine sparing interventions for uterine fibroids (1 review)

Author, Year	Intervention	Inclusion Criteria	Outcome(s)	# Studies Included	Key Findings
Panagiotopoulou et al. 2014[20]	Uterine sparing	Premenopausal women with fibroids who wished to preserve their uterus RCTs Literature from 1948 to 2013	Patient satisfaction Re-intervention rate Reproductive outcomes Recovery time Complications Length of hospital stay	5 studies 436 women were included 3 studies comparing UAE with LUAO 2 studies comparing UAE with myomectomy	UAE better patient satisfaction Evidence of fertility/pregnancy outcomes poor Myomectomy requires longer hospital stay and recovery time

Surgical Interventions

Table I-6. Existing reviews of surgical interventions for uterine fibroids (3 reviews)

Author, Year	Intervention Category	Inclusion Criteria	Outcome(s)	Included Studies	Key Findings
Nieboer, et al 2009[21]	Hysterectomy (vaginal, abdominal, laparoscopic assisted	Women undergoing hysterectomy for benign disease including uterine fibroids RCTs comparing abdominal, vaginal, and laparoscopic assisted hysterectomy	Return to normal activities Satisfaction and quality of life Intraoperative visceral injury Major complications Operation time Intraoperative complications Costs	34 RCTs (4495 women) 6 studies specifically included women with symptomatic UF	Vaginal hysterectomy associated with faster return to normal activities, fewer infections, and shorter hospital stay compared to abdominal hysterectomy. Laparoscopic assisted vaginal hysterectomy associated with faster return to normal activities, less blood loss, and shorter hospital stay More urinary or bladder injuries in LAVH compared to abdominal hysterectomy Data were not available for many long-term outcomes
Yi et al, 2011[22]	Myomectomy (vaginal and laparoscopic)	RCTs comparing laparoscopic and vaginal myomectomy	Operative outcomes including time, blood loss, length of stay, gas recovery time Major and minor complications	4 RCTs (466 women)	Vaginal myomectomy associated with significantly shorter operation time Other differences in outcomes were not statistically significant Data were limited and unavailable for major complications and long-term outcomes
Bhave Chittawar et al. 2014[23]	Myomectomy (laparoscopic or hysteroscopic vs open)	RCTs comparing myomectomy types in premenopausal women with UF	Primary outcomes: postoperative pain, in-hospital adverse events Secondary outcomes: Length of stay, operating time and recurrence	9 RCTs (808 women)	Laparoscopic myomectomy associated with less postoperative pain and shorter hospital stay No differences noted for recurrence rates between laparoscopic vs open procedures

Multiple Interventions

Table I-7. Existing reviews of medical and surgical interventions and procedures for uterine fibroids (1 review)

Author, Year	Intervention Category	Inclusion Criteria	Outcome(s)	Included Studies	Key Findings
Viswanathan, et al 2007[24]	Multiple	Women undergoing treatment (medical, surgical, procedures) for uterine fibroids Controlled trials, prospective trials with historical controls, prospective or retrospective cohort studies, and medium-to-large case series (n > 100) Studies conducted in developed nations	Symptom status, Harms, Treatment complications, Pregnancy and fertility, Sexual function, Quality of life, Fibroid recurrence, Need for subsequent treatment	107 studies addressing prevalence and treatment outcomes	Medical treatment reduced fibroids; weak evidence supported treating submucous fibroids with hyseteroscopy to preserve fertility. Evidence was not sufficient to comment on UAE vs surgical options. No well-conducted trials directly compared treatment options, including expectant management or had longer term followup. Evidence was limited overall

References

1. Peitsidis P, Koukoulomati A. Tranexamic acid for the management of uterine fibroid tumors: A systematic review of the current evidence. World J Clin Cases. 2014 Dec 16;2(12):893-8. doi: 10.12998/wjcc.v2.i12.893 PMID: 25516866

2. Kamath MS, Kalampokas EE, Kalampokas TE. Use of GnRH analogues pre-operatively for hysteroscopic resection of submucous fibroids: a systematic review and meta-analysis. Eur J Obstet Gynecol Reprod Biol. 2014 Jun;177:11-8. doi: 10.1016/j.ejogrb.2014.03.009 PMID: 24702901

3. Chen I, Motan T, Kiddoo D. Gonadotropin-releasing hormone agonist in laparoscopic myomectomy: systematic review and meta-analysis of randomized controlled trials. J Minim Invasive Gynecol. 2011 May-Jun;18(3):303-9. doi: 10.1016/j.jmig.2011.02.010 PMID: 21545958

4. Steinauer J, Pritts EA, Jackson R, et al. Systematic review of mifepristone for the treatment of uterine leiomyomata. Obstet Gynecol. 2004 Jun;103(6):1331-6. doi: 10.1097/01.AOG.0000127622.63269.8b PMID: 15172874

5. Lethaby A, Vollenhoven B, Sowter M. Efficacy of pre-operative gonadotrophin hormone releasing analogues for women with uterine fibroids undergoing hysterectomy or myomectomy: a systematic review. Bjog. 2002 Oct;109(10):1097-108 PMID: 12387461

6. Deng L, Wu T, Chen XY, et al. Selective estrogen receptor modulators (SERMs) for uterine leiomyomas. Cochrane Database Syst Rev. 2012;10:Cd005287. doi: 10.1002/14651858.CD005287.pub4 PMID: 23076912

7. Song H, Lu D, Navaratnam K, et al. Aromatase inhibitors for uterine fibroids. Cochrane Database Syst Rev. 2013;10:Cd009505. doi: 10.1002/14651858.CD009505.pub2 PMID: 24151065

8. Moroni RM, Martins WP, Ferriani RA, et al. Add-back therapy with GnRH analogues for uterine fibroids. Cochrane Database Syst Rev. 2015 Mar 20;3:Cd010854. doi: 10.1002/14651858.CD010854.pub2 PMID: 25793972

9. Clark NA, Mumford SL, Segars JH. Reproductive impact of MRI-guided focused ultrasound surgery for fibroids: a systematic review of the evidence. Curr Opin Obstet Gynecol. 2014 Jun;26(3):151-61. doi: 10.1097/gco.0000000000000070 PMID: 24751998

10. Gizzo S, Saccardi C, Patrelli TS, et al. Magnetic resonance-guided focused ultrasound myomectomy: safety, efficacy, subsequent fertility and quality-of-life improvements, a systematic review. Reprod Sci. 2014 Apr;21(4):465-76. doi: 10.1177/1933719113497289 PMID: 23868442

11. Jiang W, Shen Q, Chen M, et al. Levonorgestrel-releasing intrauterine system use in premenopausal women with symptomatic uterine leiomyoma: a systematic review. Steroids. 2014 Aug;86:69-78. doi: 10.1016/j.steroids.2014.05.002 PMID: 24832215

12. Varma R, Sinha D, Gupta JK. Non-contraceptive uses of levonorgestrel-releasing hormone system (LNG-IUS)--a systematic enquiry and overview. Eur J Obstet Gynecol Reprod Biol. 2006 Mar 1;125(1):9-28. doi: 10.1016/j.ejogrb.2005.10.029 PMID: 16325993

13. Zapata LB, Whiteman MK, Tepper NK, et al. Intrauterine device use among women with uterine fibroids: a systematic review. Contraception. 2010 Jul;82(1):41-55. doi: 10.1016/j.contraception.2010.02.011 PMID: 20682142

14. Sangkomkamhang US, Lumbiganon P, Laopaiboon M, et al. Progestogens or progestogen-releasing intrauterine systems for uterine fibroids. Cochrane Database Syst Rev. 2013;2:Cd008994. doi: 10.1002/14651858.CD008994.pub2 PMID: 23450594

15. Das R, Champaneria R, Daniels JP, et al. Comparison of embolic agents used in uterine artery embolisation: a systematic review and meta-analysis. Cardiovasc Intervent Radiol. 2014 Oct;37(5):1179-90. doi: 10.1007/s00270-013-0790-0 PMID: 24305981

16. Martin J, Bhanot K, Athreya S. Complications and reinterventions in uterine artery embolization for symptomatic uterine fibroids: a literature review and meta analysis. Cardiovasc Intervent Radiol. 2013 Apr;36(2):395-402. doi: 10.1007/s00270-012-0505-y PMID: 23152035

17. Toor SS, Jaberi A, Macdonald DB, et al. Complication rates and effectiveness of uterine artery embolization in the treatment of symptomatic leiomyomas: a systematic review and meta-analysis. AJR Am J Roentgenol. 2012 Nov;199(5):1153-63. doi: 10.2214/ajr.11.8362 PMID: 23096193

18. van der Kooij SM, Bipat S, Hehenkamp WJ, et al. Uterine artery embolization versus surgery in the treatment of symptomatic fibroids: a systematic review and metaanalysis. Am J Obstet Gynecol. 2011 Oct;205(4):317.e1-18. doi: 10.1016/j.ajog.2011.03.016 PMID: 21641570

19. Gupta JK, Sinha A, Lumsden MA, et al. Uterine artery embolization for symptomatic uterine fibroids. Cochrane Database Syst Rev. 2014;12:Cd005073. doi: 10.1002/14651858.CD005073.pub4 PMID: 25541260

20. Panagiotopoulou N, Nethra S, Karavolos S, et al. Uterine-sparing minimally invasive interventions in women with uterine fibroids: a systematic review and indirect treatment comparison meta-analysis. Acta Obstet Gynecol Scand. 2014 Sep;93(9):858-67. doi: 10.1111/aogs.12441 PMID: 24909191

21. Nieboer TE, Johnson N, Lethaby A, et al. Surgical approach to hysterectomy for benign gynaecological disease. Cochrane Database Syst Rev. 2009(3):Cd003677. doi: 10.1002/14651858.CD003677.pub4 PMID: 19588344

22. Yi YX, Zhang W, Guo WR, et al. Meta-analysis: the comparison of clinical results between vaginal and laparoscopic myomectomy. Arch Gynecol Obstet. 2011 Jun;283(6):1275-89. doi: 10.1007/s00404-011-1836-7 PMID: 21234758

23. Bhave Chittawar P, Franik S, Pouwer AW, et al. Minimally invasive surgical techniques versus open myomectomy for uterine fibroids. Cochrane Database Syst Rev. 2014;10:Cd004638. doi: 10.1002/14651858.CD004638.pub3 PMID: 25331441